Images of Hematology

Blood Research Educational Material

BLOOD RESEARCH
Volume 50 · Number 2 · June 2015
http://dx.doi.org/10.5045/br.2015.50.2.71

Gelatinous transformation of the bone marrow in hepatocellular carcinoma

Jeonghyun Chang, Chan-Jeoung Park

Department of Laboratory Medicine, University of Ulsan College of Medicine and Asan Medical Center, Seoul, Korea

Correspondence to Chan-Jeoung Park, M.D., Ph.D., Department of Laboratory Medicine, Asan Medical Center and University of Ulsan College of Medicine, 88, Olympic-ro 43-gil, Songpa-gu, Seoul 138-736, Korea, E-mail: cjpark@amc.seoul.kr

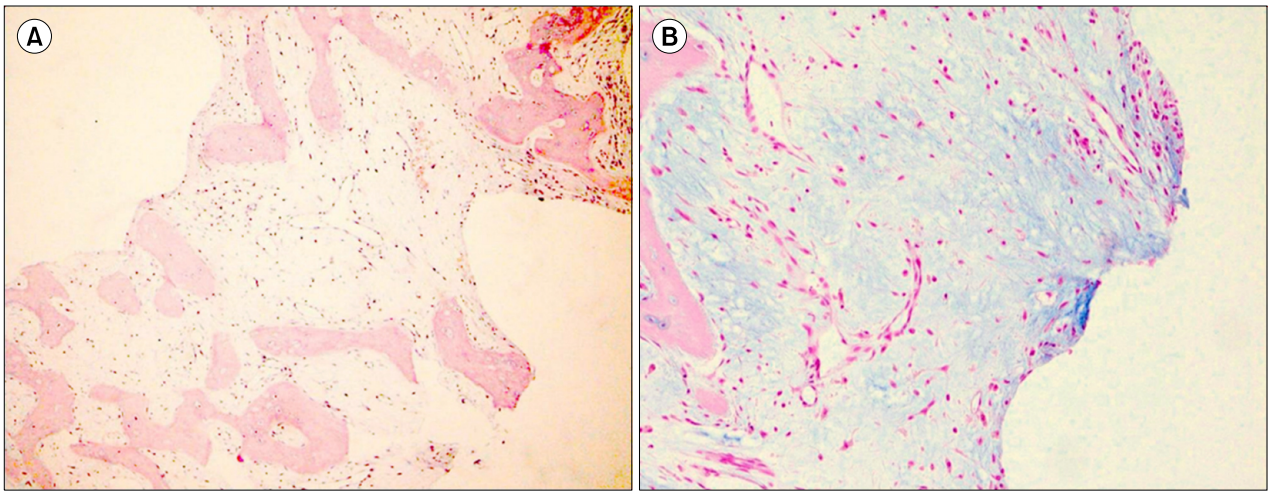

A 52-year-old woman with a history of hepatocellular carcinoma with bone metastasis (T6, L5-S1) was referred for pancytopenia after undergoing radiation therapy and transarterial chemoembolization. Splenomegaly and compact lipiodol retention in liver segment V was found on computed tomography. Her hemoglobin level was 10.8 g/dL; platelet count, 23,000/μL; white blood cell count, 1.9×10^3/μL; and mean corpuscular volume, 87.1 fL. The leukocyte differential smear revealed 48.6% segmented neutrophils, with toxic signs; 24.4% lymphocytes; 24.4% monocytes; 1.3% eosinophils; and 1% basophils. Normocytic normochromic anemia with frequent fragmented red blood cells was diagnosed. A bone marrow (BM) aspirate revealed trilineage hematopoietic components with prominent toxic granules in granulocytic series and poorly stained acellular material. BM biopsy showed a hypocellular marrow (10% cellularity); remarkable fat atrophy; and extracellular deposits of amorphous, smooth, pinkish (**A**, hematoxylin-eosin staining, ×100), and bluish (**B**, Alcian blue staining, ×200) gelatinous material that was negative on periodic acid–Schiff staining. These features were consistent with BM gelatinous transformation. The patient died of multiorgan failure and metabolic acidosis 5 days after the BM examination. BM gelatinous transformation, also known as "starvation marrow," can be induced by severe malnutrition in patients with malignancies, anorexia nervosa, malabsorption, and alcoholism.