

Grey-matter abnormalities in boys with Tourette syndrome: magnetic resonance imaging study using optimised voxel-based morphometry

ANDREA G. LUDOLPH, FREIMUT D. JUENGLING, GERHARD LIBAL, ALBERT C. LUDOLPH, JÖRG M. FEGERT and JAN KASSUBEK

Summary The genesis of Tourette syndrome is still unknown, but a core role for the pathways of cortico-striatal-thalamic-cortical circuitry (CSTC) is supposed. Volume-rendering magnetic resonance imaging data-sets were analysed in 14 boys with Tourette syndrome and 15 age-matched controls using optimised voxel-based morphometry. Locally increased grey-matter volumes (corrected $P < 0.001$) were found bilaterally in the ventral putamen. Regional decreases in grey matter were observed in the left hippocampal gyrus. This unbiased analysis confirmed an association between striatal abnormalities and Tourette syndrome, and the hippocampal volume alterations indicate an involvement of temporolimbic pathways of the CSTC in the syndrome.

Declaration of interest None.

There is mounting evidence that Tourette syndrome is an inherited developmental alteration of synaptic neurotransmission within the cortico-striatal-thalamic-cortical circuitry (CSTC). Abnormalities in the striatum and in medial temporal structures have repeatedly been found in imaging studies using nuclear medicine techniques. To investigate morphological alterations *in vivo*, a number of region-based volumetric analyses of structural magnetic resonance imaging (MRI) data in patients of various ages with Tourette syndrome have been performed, but these differ considerably in their core findings with respect to basal ganglia volumes (Gerard & Peterson, 2003). In our study the whole-brain three-dimensional MRI analysis technique of voxel-based morphometry, which avoids the biases inherent in operator-dependent techniques, was applied in boys with Tourette syndrome to

test the specific hypothesis that differences exist between patients with this disorder and healthy controls in the striatum and medial temporal areas.

METHOD

The protocol was approved by the ethics committee of the University of Ulm, and written informed consent was obtained from the parents of all participants. Fourteen patients (mean age 12.5 years) were investigated; only boys were included to control for possible gender effects. The criteria for a definite diagnosis of Tourette syndrome according to the Tourette Syndrome Classification Study Group (1993) were applied to all patients. Stimulants were the only medication used by the patients ($n=4$). For clinical characterisation, the German version of the Yale Global Tic Severity Scale (YGTSS; Steinhausen, 2002) was applied. Attention-deficit hyperactivity disorder (ADHD) comorbidity was assessed using the DSM-IV criteria checklist (American Psychiatric Association, 1994); the mean value was 6.6 (s.d.=5.6). To provide an age-matched MRI control database, MRI scans of 15 healthy boys (mean age 13.4 years) without any neurological or psychiatric diagnosis were acquired. Patients and controls were well matched for age, handedness and IQ.

High-resolution, whole-head three-dimensional MRI data for all patients and controls were collected on the same 1.5 T clinical scanner (Siemens, Erlangen, Germany) and processed in the same way using methods implemented in Statistical Parametric Mapping software (SPM2; <http://www.fil.ion.ucl.ac.uk/spm>). Voxel-based morphometry was performed according to the principles described by Good *et al* (2001) as the 'optimised' protocol. First, all images were normalised by use of an affine-only procedure and a template built from children aged 5–18 years by researchers

from the Imaging Research Center at Cincinnati Children's Hospital Medical Center; see <http://www.irc.chmcc.org>. After creation of customised tissue probability maps, the MRI data were segmented, cleaned, normalised to the study-specific template, segmented and cleaned a second time, then modulated by the Jacobian determinants and finally smoothed (6 mm isotropic Gaussian kernel) (Good *et al*, 2001).

Within the framework of the general linear model, the grey-matter images of the Tourette syndrome group were statistically compared with the normal database in a parametric group analysis. Data were analysed in SPM for effects of diagnosis, including individual total grey-matter volume, age and individual scores on the DSM-IV criteria checklist for ADHD as covariates of no interest and individual YGTSS values as the covariate of interest. To detect whether each voxel in the patient data had a greater or lesser grey-matter volume than in controls, the appropriate two contrasts were calculated. For general analysis of effects in areas with an *a priori* hypothesis – the basal ganglia (striatum) and mesiotemporal regions – significance was set at $P < 0.001$, uncorrected for multiple comparisons, and then a small-volume correction was made using a 10 mm radius volume of interest (Wilke *et al*, 2004).

RESULTS

In the optimised voxel-based morphometry analysis, both contrasts 'patients > controls' and 'controls > patients' yielded significant results at a threshold of small-volume corrected $P < 0.001$. Patients were found to have regional increases in grey-matter volumes in the area of the ventral putamen bilaterally ($x, y, z=25, 13, (-5)$ and $(-20), 17, (-6)$ respectively) (Fig. 1(A)). In the search for syndrome-associated regions of decreased grey-matter volumes, significant mesiotemporal voxel clusters were localised in the bilateral hippocampal area ($x, y, z=27, (-19), (-17)$ and $(-20), (-19), (-21)$ respectively) (Fig. 1(B)). In the covariance analysis including disease severity, these two areas of increased and of decreased grey-matter density were both found to covary significantly with YGTSS at $P < 0.001$.

DISCUSSION

The morphological changes in striatal and left mesiotemporal (hippocampal) areas

detected correspond to integral components of the CSTC involving its temporolimbic associations. These results are consistent with functional neuroimaging data, since early functional imaging studies identified different parts of CSTC (including temporolimbic, sensorimotor, orbitofrontal and association pathways) to be altered with respect to metabolism and blood flow (Peterson, 2001). Later radioligand studies of presynaptic/synaptic function and the post-synaptic dopaminergic system achieved inconsistent findings, with partly decreased, partly increased and partly normal striatal bindings (cf. Gerard & Peterson, 2003). Our data do not provide evidence that the frequent comorbidity of Tourette syndrome and ADHD, which was present but mild in our patients according to DSM-IV checklist criteria, was relevant for the involvement of limbic pathways, since the individual ADHD values were covaried out.

The change in putamen volume is in general agreement with previous investigations; note that the putaminal volume changes in our study were local increases in grey matter. Previous investigations of functional networks in Tourette syndrome using [$^{15}\text{H}_2\text{O}$]-positron emission tomography (PET) or functional MRI (Peterson *et al*, 1998; Stern *et al*, 2000) suggested that basal ganglia seem to be overactive (disinhibited), in accordance with a more recent study using [^{11}C]dihydrotrabenazine-PET to quantify striatal monoaminergic innervation in this syndrome which showed increased binding in the ventral striatum (Albin *et al*, 2003). Thus, it seems plausible that in the course of the disorder the increased activity might be mirrored by increased signal properties due to neuronal volume changes, at least in a subset of patients. It has to be kept in mind that children and not adults were investigated

ANDREA G. LUDOLPH, MD, Department of Child and Adolescent Psychiatry, University of Ulm, Germany; FREIMUT D. JUENGLING, MD, Department of Nuclear Medicine, University of Bern, Switzerland; GERHARD LIBAL, MD, Department of Child and Adolescent Psychiatry, University of Ulm; ALBERT C. LUDOLPH, MD, Department of Neurology, University of Ulm; JÖRG M. FEGERT, MD, Department of Child and Adolescent Psychiatry, University of Ulm; JAN KASSUBEK, MD, Department of Neurology, University of Ulm, Germany

Correspondence: Jan Kassubek, MD, Department of Neurology, University of Ulm, Oberer Eselsberg 45, 89081 Ulm, Germany. Tel: + 49 731 1771206; Fax: + 49 731 1771202; e-mail: jan.kassubek@uni-ulm.de

(First received 13 January 2005, final revision 5 June 2005, accepted 1 September 2005)

in our study and that previous volumetric studies in affected children mostly found no reduction of basal ganglia volumes, although a large-scale volumetric study reported reduced volumes of the caudate nuclei, but not of lenticular nuclei (Peterson *et al*, 2003).

The ventral striatum which we found to be altered in our patient cohort is thought of as the part of the basal ganglia participating in temporolimbic pathways of the CSTC. We found the left hippocampal gyrus to be a part of the limbic system significantly decreased in volume, a finding not described previously in Tourette syndrome or in ADHD to our knowledge. The hippocampal cortex is a polymodal convergence area and a core component of the limbic system loops of the CSTC (Peterson, 2001). This constellation implies that two elements of this pathway were found to be altered in volume in our study and that the temporolimbic CSTC pathway seems to be important for Tourette-related symptoms. This finding is strongly supported by the significant covariance of tic severity and the striatal and hippocampal volume changes.

Using voxel-based morphometric analysis as a sensitive and unbiased comparison of regional brain morphology, we found evidence for grey-matter changes in temporolimbic CSTC pathways which

might be the morphological correlate of a dopaminergic hyperfunction. Our finding of decreased hippocampal grey-matter volumes needs to be correlated with neuropsychological deficits in patients with Tourette syndrome in future studies. The results of this type of analysis may be useful in recognising regions that are of particular relevance to a specific disorder, even when the neuro-morphometric abnormalities are subtle.

ACKNOWLEDGEMENT

We thank Mrs Sonja Fuchs for help with acquisition of the MRI data.

REFERENCES

- American Psychiatric Association (1994)** *Diagnostic and Statistical Manual of Mental Disorders* (4th edn) (DSM-IV). Washington, DC: APA.
- Albin, R. L., Koeppe, R. A., Bohnen, N. I., et al (2003)** Increased ventral striatal monoaminergic innervation in Tourette syndrome. *Neurology*, **61**, 310–315.
- Gerard, E. & Peterson, B. S. (2003)** Developmental processes and brain imaging studies in Tourette syndrome. *Journal of Psychosomatic Research*, **55**, 13–22.
- Good, C. D., Johnsrupe, I. S., Ashburner, J., et al (2001)** A voxel-based morphometric study of ageing in 465 normal adult human brains. *NeuroImage*, **14**, 21–36.
- Peterson, B. S. (2001)** Neuroimaging studies of Tourette syndrome: a decade of progress. *Advances in Neurology*, **85**, 179–196.
- Peterson, B. S., Skudlarski, P., Anderson, A.W., et al (1998)** A functional magnetic resonance imaging study of tic suppression in Tourette syndrome. *Archives of General Psychiatry*, **55**, 326–333.
- Peterson, B. S., Thomas, P., Kane M.J., et al (2003)** Basal ganglia volumes in patients with Gilles de la Tourette syndrome. *Archives of General Psychiatry*, **60**, 415–424.
- Steinhausen, H.-C. (2002)** *Psychiatric Disorders in Children and Adolescents* (in German). Munich: Urban & Fischer.
- Stern, E., Silbersweig, D. A., Chee, K. Y., et al (2000)** A functional neuroanatomy of tics in Tourette syndrome. *Archives of General Psychiatry*, **57**, 741–748.
- Tourette Syndrome Classification Study Group (1993)** Definitions and classification of tic disorders. *Archives of Neurology*, **50**, 1013–1016.
- Wilke, M., Kowatch, R. A., DelBello, M. P., et al (2004)** Voxel-based morphometry in adolescents with bipolar disorder: first results. *Psychiatry Research*, **131**, 57–69.

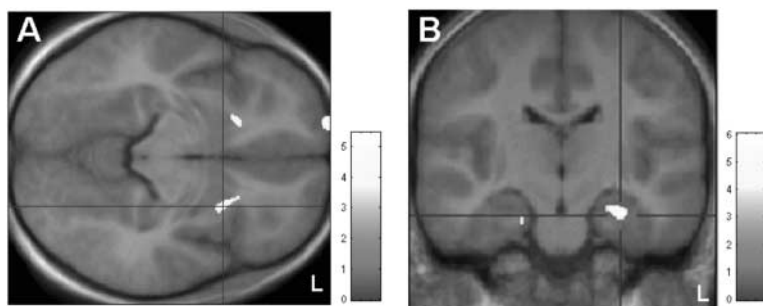


Fig. 1 Voxel-based morphometric analysis. (A) Patients > controls: areas showing significantly increased grey matter (at small-volume corrected $P < 0.001$) localised in the ventral putamen bilaterally; clusters are superimposed on the study-specific template in axial view. (B) Controls > patients: display of clusters showing significantly decreased grey matter (at small-volume corrected $P < 0.001$), superimposed on the study-specific template, in coronal view. Z-scores are indexed by the grey-scale bar.

BJPpsych

The British Journal of Psychiatry

Grey-matter abnormalities in boys with Tourette syndrome: magnetic resonance imaging study using optimised voxel-based morphometry

ANDRÉA G. LUDOLPH, FREIMUT D. JUENGLING, GERHARD LIBAL, ALBERT C. LUDOLPH, JÖRG M. FEGERT and JAN KASSUBEK

BJP 2006, 188:484-485.

Access the most recent version at DOI: [10.1192/bjp.bp.105.008813](https://doi.org/10.1192/bjp.bp.105.008813)

References

This article cites 9 articles, 1 of which you can access for free at:
<http://bjp.rcpsych.org/content/188/5/484#BIBL>

Reprints/ permissions

To obtain reprints or permission to reproduce material from this paper, please write to permissions@rcpsych.ac.uk

You can respond to this article at

[/letters/submit/bjprcpsych;188/5/484](http://letters.submit/bjprcpsych;188/5/484)

Downloaded from

<http://bjp.rcpsych.org/> on June 9, 2017
Published by The Royal College of Psychiatrists
