

BENIGN RETROPERITONEAL SCHWANNOMA – A RARE CASE REPORT

***Konrad Wroński¹, Janusz Kaczor¹, Zbigniew Masłowski¹, Leszek Frąckowiak², Michał Frąckowiak³, Przemysław Stefaniak¹**

¹Department of Surgical Oncology, Hospital Ministry of Internal Affairs with Warmia and Mazury Oncology Centre, Olsztyn, Poland
Head of Department: Andrzej Lachowski, MD

²Department of Public Health and Epidemiology, University of Warmia and Mazury in Olsztyn, Poland
Head of Department: Professor Anna Abramczyk, MD, PhD

³Faculty of Medicine, Medical University in Gdańsk, Poland
Dean of University: Professor Janusz Moryś, MD, PhD

Summary

Retroperitoneal schwannoma is an extremely rare benign neoplasm, except for patients suffering from Von Recklinghausen's disease. Most schwannomas (neurilemmomas, neurinomas) are tumors that develop slowly from the Schwann cells. Schwannomas are observed in adult population aged 20-50. Women are affected nearly two times as often as men. Retroperitoneal schwannomas are benign, encapsulated, slow-growing tumors. The majority of retroperitoneal schwannomas are asymptomatic and are often diagnosed incidentally during abdomen ultrasound or computer tomography. Malignant schwannomas are large in size and aggressive. The most common symptoms include abdominal pain and abdominal distention. Because of the rarity of retroperitoneal schwannomas, it is necessary for the radiologist to establish the diagnosis before the operation as well as to have a qualified pathologist available to examine the needle biopsy specimen. Radical surgical resection of the retroperitoneal schwannoma is the best treatment option. Aggressive surgery is not recommended in case of benign retroperitoneal schwannomas.

The authors present a case of a 58-year-old white man who was admitted to the hospital with the diagnosis of retroperitoneal schwannoma. The patient had been suffering from the pain in the right lumbar region for 5 months. He underwent surgical excision of the tumor and was discharged five days after surgery. After the operation, the symptoms were alleviated. The author also presents literature review on retroperitoneal schwannomas.

Keywords: retroperitoneal schwannoma, surgery, treatment

INTRODUCTION

Retroperitoneal schwannoma is an extremely rare benign neoplasm, except for patients suffering from Von Recklinghausen's disease. Most schwannomas (neurilemmomas, neurinomas) are tumors that slowly develop from the Schwann cells (1, 2). Schwannomas are observed in adult population aged 20-50 (2, 3). Women are affected nearly two times as often as men (2, 3).

CASE REPORT

A 58-year-old white man was referred to the Department of Surgical Oncology of Hospital Ministry of Internal Affairs with Warmia and Mazury Oncology Centre in Olsztyn due to a retroperitoneal tumor diagnosed in computer tomography. The patient reported pain in the right lumbar region that had first started 5 months before. There was no trauma history of the right lumbar region. He had no other symptoms. The medical history was negative for drug abuse, weight loss and loss of appetite. He had never undergone any surgical

procedures. Family history of cancer was positive – the patient's father suffered from leukemia and died of it aged 82.

The patient did not report pain of the right lumbar region on physical examination. Blood tests were all within normal limits. Ultrasound examination revealed pathological hypoechogenic mass of size 47 x 34 x 43 mm located in the right lower abdominal region. Computer tomography of the pelvis revealed a pathological solid mass of size 45 x 44 x 55 millimeters in the right retroperitoneal region (fig. 1). Histopathological examination of the thick-needle aspiration biopsy specimen under the control of computer tomography was performed before the surgical procedure. The patient was preoperatively diagnosed with schwannoma.

Complete surgical excision of the tumor was performed without damage to the main neuro-vascular structures of the retroperitoneum. The material was sent for routine histopathological examination. The surgery lasted 60 minutes.

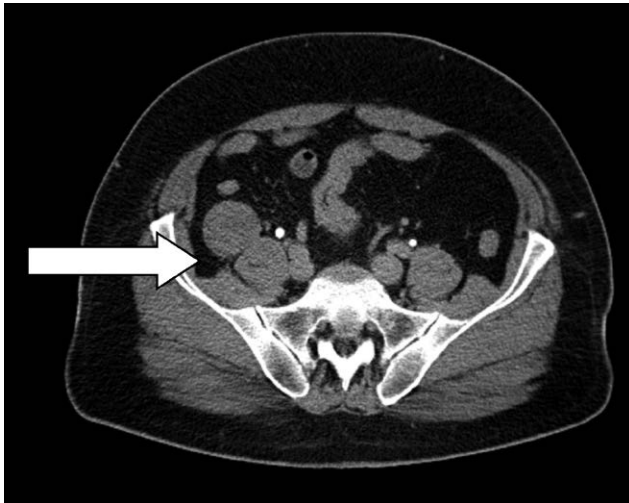


Fig. 1. Axial CT image demonstrates a retroperitoneal mass of size 45 x 44 x 55 millimeters on the right side

Histopathological examination showed areas with nuclear palisading which are typical for schwannomas. The Ki-67 proliferation index was very low in the examined specimen. The specimen underwent immunochemical examinations and occurred to be S-100 positive and CD-34 negative. The patient felt good after the surgery and did not report any pain. After the surgery, the symptoms were alleviated. The postoperative period was uncomplicated and the patient was discharged five days after the procedure.

DISCUSSION

Retroperitoneal schwannomas are rare benign neoplasms which comprise up to 6% of primary retroperitoneal tumors (4). Retroperitoneal schwannomas are usually located in the paravertebral space or in the presacral region (5). Schwannomas have a predilection for head and neck, but also are observed in upper and lower extremities (1-3).

Schwannomas are benign encapsulated slow-growing tumors. The majority of retroperitoneal schwannomas are asymptomatic and are often diagnosed incidentally during abdomen ultrasound or computer tomography (4, 5). Malignant schwannomas are large in size and aggressive. The most common symptoms are abdominal pain and abdominal distention (3-5). Other symptoms include secondary hypertension, hematuria, and renal colic and depend on the location of the tumor (3, 5).

Because of the rarity of retroperitoneal schwannomas, it is necessary for the radiologist to establish the diagnosis before the operation as well as to have a qualified pathologist available during the surgical procedure to examine the needle biopsy specimen. Ultrasound and computer tomography of abdomen and pelvis are useful for the differential diagnosis of the

retroperitoneal tumors (6). Magnetic resonance is an excellent examination tool, which helps to choose the best treatment strategy during surgery. On T1-weighted images, schwannoma has intermediate signal intensity similar to the muscles, but on T2-weighted images, the tumor is characterized by high signal intensity (7). If heterogeneous enhancement is observed, it suggests cystic or necrotic forms of schwannoma (7). In computer tomography, calcification was reported in 23% of cases of retroperitoneal schwannomas, and cystic degeneration was observed in up to 66% of cases (8). Histopathological examination usually shows areas of nuclear palisading that are typical for schwannomas. Immunochemical examination positive for S-100 protein and negative for CD-34 antigen is also typical for schwannoma (1-3, 5).

Radical surgical resection of the retroperitoneal schwannoma is the best treatment option, which is a reason why the tumor should be differentiated from neurofibroma before surgery. On magnetic resonance imaging, neurofibromas are more heterogenous on T1- and T2-weighted images than schwannomas. However, the definitive diagnosis is provided by the pathologist (9).

The risk of malignant transformation for schwannomas is about 5%, and for neurofibromas – 15-16% (10). The prognosis of benign retroperitoneal schwannoma is good. Local resection is generally sufficient, but metastatic cases were reported after resection (3). Aggressive surgery is not recommended in benign cases. Possibility of atraumatic tumour resection does not eliminate the risk of developing postoperative neurological deficits. Incidence of neurological deficits after radical operation of schwannoma are observed between 1.5 and 80 percent (11-14). Significantly high percentage of complications are observed in short-term observations. The most frequent complication is recurrence because of incomplete excision, which is observed in 5-10% of cases (11). Therefore, follow up is important in this patient. The authors of this article recommend to follow the patient up every three months in the first three years, and every six months for the next two years. Periodic ultrasound of the abdomen and pelvis, as well computed tomography with contrast of the abdomen and pelvis once a year and chest X-rays appear to be justified in the outpatient follow-up.

CONCLUSIONS

1. Radical surgical resection is an effective treatment option.
2. Adjuvant chemotherapy and radiotherapy have added benefits in case of malignant schwannomas.
3. Follow up has an important role in the case described.

References

1. Fierro N, D'ermo G, Di Cola G et al.: Posterior mediastinal schwannoma. *Asian Cardiovasc Thorac Ann* 2003; 11: 72-73. 2. Guerrissi JO: Solitary benign schwannomas in major nerve systems of the head and neck. *J Craniofac Surg* 2009; 20: 957-961. 3. Wong CS, Chu TY, Tam KF: Retroperitoneal schwannoma: a common tumour in an uncommon site. *Hong Kong Med J* 2010; 16(1): 66-68. 4. Lane RH, Stephens DH, Reiman HM: Primary retroperitoneal neoplasms: CT findings in 90 cases with clinical and pathologic correlation. *AJR* 1989; 152: 83-89. 5. Kapan M, Onder A, Gumus M et al.: Retroperitoneal schwannoma. *JSCR* 2011; 10: 1. 6. Goh BKP, Tan Y, Chung YA et al.: Retroperitoneal schwannoma. *Am J Surg* 2006; 192: 14-18. 7. Kralick F, Koenigsberg R: Sciatica in a patient with unusual peripheral nerve sheath tumors. *Surg Neurol* 2006; 66: 634-637. 8. Hughes MJ, Thomas JM, Fisher C et al.: Imaging features of retroperitoneal and pelvic schwannomas. *Clinical Radiology* 2005; 60(8): 886-893. 9. Suh JS, Abenzoza P, Galloway HR

et al.: Peripheral (extracranial) nerve tumors: correlation of MR imaging and histologic findings. *Radiology* 1992; 183: 341-346. 10. Wright BA, Jackson D: Neural tumors of the oral cavity. A review of the spectrum of benign and malignant oral tumors of the oral cavity and jaws. *Oral Surg Oral Med Oral Pathol* 1980; 49: 509-522. 11. Kim SM, Seo SW, Lee JY et al.: Surgical outcome of schwannomas arising from major peripheral nerves in the lower limb. *International Orthopaedics* 2012; 36(8): 1721-1725. 12. Park MJ, Seo KN, Kang HJ: Neurological deficit after surgical enucleation of schwannomas of the upper limb. *J Bone Joint Surg Am – Series B* 2009; 91(11): 1482-1486. 13. Sawada T, Sano M, Ogihara H et al.: The relationship between pre-operative symptoms, operative findings and postoperative complications in schwannomas. *Journal of Hand Surgery* 2006; 31(6): 629-634. 14. Donner TR, Voorhies RM, Kline DG: Neural sheath tumors of major nerves. *J Neurosurg* 1994; 81(3): 362-373. 15. Song JY, Kim SY, Park EG et al.: Schwannoma in the retroperitoneum. *J Obstet Gynaecol* 2007; 33: 371-375.

Conflict of interest

None

Received: 15.07.2016

Accepted: 18.07.2016

Correspondence to:

*Konrad Wroński

General Surgery Consultant

Surgical Oncology Consultant

Public Health Consultant

Department of Surgical Oncology

Hospital Ministry of Internal Affairs with Warmia and Mazury

Oncology Centre, Olsztyn, Poland

al. Wojska Polskiego 37, 10-228 Olsztyn, Poland

tel.: +48 505-818-126

e-mail: konradwronski@wp.pl