

**Research Article****Congenital Adrenal Hyperplasia due to 21- $\alpha$ -Hydroxylase Deficiency in Saudi Arabia****Nasir A. M. Al Jurayyan<sup>1</sup>, Hessah M.N. Al Otaibi<sup>2</sup>, Amer O. Al Ali<sup>3</sup>, Osamah A. Al Ayed<sup>4</sup>, Amal A. Al Hakami<sup>5</sup>, Sharifa D. A. Al Issa<sup>6</sup>, Haya M. Bin Nafisah<sup>7</sup>**<sup>1</sup>Professor of Pediatric and Consultant Pediatric Endocrinologist, College of Medicine and King Khalid University Hospital, King Saud University, Riyadh, Saudi Arabia<sup>2</sup>Consultant Pediatric Endocrinologist, College of Medicine and King Khalid University Hospital, King Saud University, Riyadh, Saudi Arabia<sup>3</sup>Senior Fellow in Pediatric Endocrinology, College of Medicine and King Khalid University Hospital, King Saud University, Riyadh, Saudi Arabia<sup>4,5</sup>Fellow in Pediatric Endocrinology College of Medicine and King Khalid University Hospital King Saud University, Riyadh, Saudi Arabia<sup>6</sup>Senior Registrar in Pediatric Endocrinology, College of Medicine and King Khalid University Hospital, King Saud University, Riyadh, Saudi Arabia<sup>7</sup>Resident in Pediatric Endocrinology, College of Medicine and King Khalid University Hospital, King Saud University, Riyadh, Saudi Arabia**\*Corresponding author**

Dr. Nasir A.M. Al Jurayyan

Email: [njurayyan@gmail.com](mailto:njurayyan@gmail.com)

---

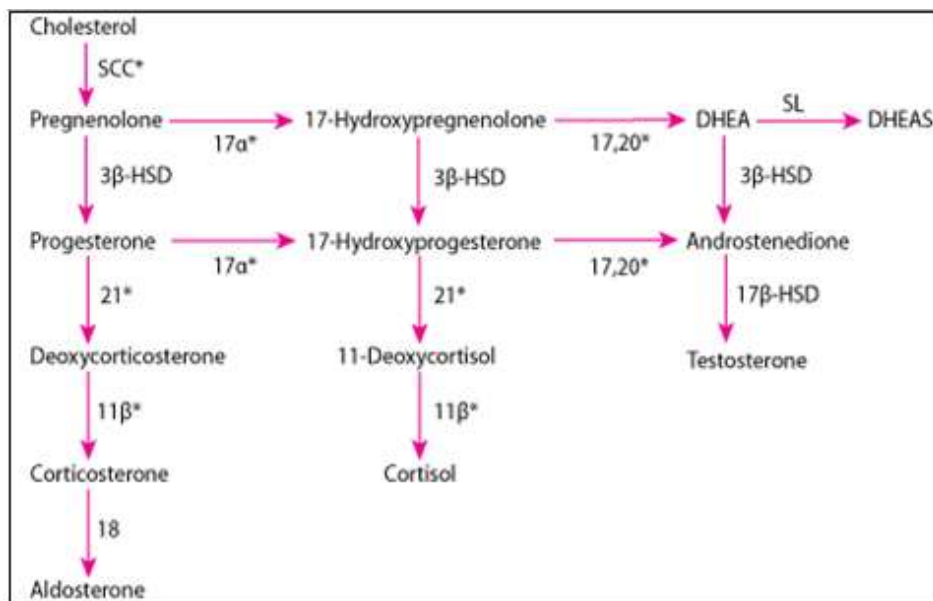
**Abstract:** Congenital adrenal hyperplasia (CAH) due to 21- $\alpha$ -hydroxylase deficiency is a common endocrine disorder accounting for more than 90 percent of CAH cases. As a result to the hormonal imbalance salt-wasting may occur, and predisposes affected females to prenatal development of genital ambiguity. This article discusses the clinical presentation, diagnosis and management of this disorder and highlights new developments, including genotype-phenotype correlations, screening, gene-specific pre-natal diagnosis and pre-natal therapy.**Keywords:** Congenital adrenal hyperplasia, Saudi Arabia, 21- $\alpha$ -hydroxylase, Deficiency.

---

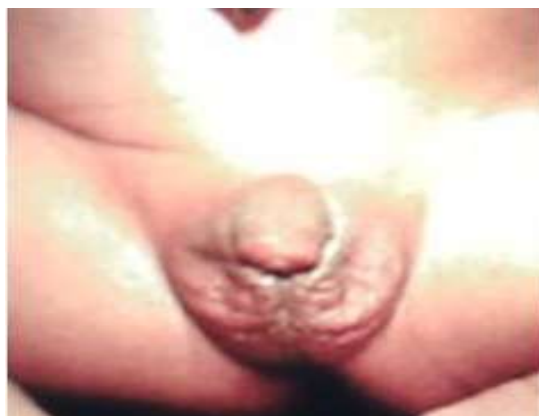**INTRODUCTION**

Congenital adrenal hyperplasia (CAH) is a group of autosomal recessive disorders due to deficiency of one of the five enzymes required for synthesis of cortisol in the adrenal cortex (Fig. 1). The enzymes involved are 21- $\alpha$ -hydroxylase, 11- $\beta$ -hydroxylase, 17-hydroxylase, 3 $\beta$ -hydroxysteroid dehydrogenase, and 20,22-desmolase. The most common enzyme defect is 21-hydroxylase that accounts for almost 90% of cases. The fundamental defect in CAH is the inability to synthesize cortisol adequately. Inefficient cortisol synthesis signals the hypothalamus and pituitary to increase corticotrophin releasing hormone (CRH) and adrenocorticotrophin hormone (ACTH). As a result, the adrenals become hyperplastic and produce an excess amount of sex hormone precursors, which do not require 21-hydroxylase for their synthesis. These precursors, progesterone and 17-hydroxyprogesterone, are further metabolized to active androgens, testosterone, and dihydrotestosterone, and to a lesser extent oestrogens-oestosterone and oestradiol. The

effect is prenatal virilization of girls and rapid somatic growth with early epiphyseal fusion in both genders the so called "simple virilization". This can be associated with a life-threatening hyponatremic dehydration and hyperkalaemia and are called "salt-wasters" (Fig. 2) [1-13]. A mild non-classical forms (late onset) occurs with partial enzyme deficiency. The females usually present late in life with signs of androgen excess and without neonatal genital ambiguity. Clinical features in childhood may include precocious puberty and may present as an adult and may be presented with hirsutism, menstrual irregularity, infertility and acne. Some patients remain asymptomatic. They may present as well with precocious sexual development. The 21-hydroxylase gene CYP21 is located on the short arm of chromosome 6. A pseudo-gene CYP21 p is located downstream close to CYP21. Diseases resulting from mutations are due to CYP21 p acquiring portions of CYP 21. Many mutations causing disease have been reported [14, 15].



**Fig. 1: Schematic structure for biosynthesis of adrenal cortex hormones (glucocorticoids, mineral-corticoids and sex steroid hormone)**



**Fig. 2: A newborn baby girl (46 XX) with congenital adrenal hyperplasia due to 21 hydroxylase deficiency. Note: The fused labioscrotal folds and hypertrophy of clitoris**

This report highlights and discusses the deficiency of steroid 21- $\alpha$ -hydroxylase congenital adrenal hyperplasia in Saudi Arabia.

**METHODOLOGY**

In Saudi Arabia, there is no unified referral system and more than hundred qualified pediatric endocrinologist work across the country. Currently, there is no disease registry, however, limited studies, and the clinical experience indicated that the disease is quite prevalent.

During the period January 1989 to December 2014, 103 (95 Saudi and 8 non-Saudi) children were diagnosed to have congenital adrenal hyperplasia at the main author – NJ – Endocrine Pediatric Service of King Khalid University Hospital (KKUH), Riyadh, Saudi Arabia.

Diagnosis of CAH was suspected based on clinical grounds, and confirmed by detailed

chromosomal, hormonal, and radiological investigations. Diagnosis of 21-hydroxylase deficiency was confirmed hormonally by high plasma concentration of 17-hydroxyprogesterone.

The salt-wasting was confirmed by the presence of hyponatremia, hyperkalemia, natriuria with high serum renin activity and low serum aldosterone concentration. All hormones were measured commercially by Biocentia Laboratory, Germany. Chromosomal analysis, abdominal ultrasound, genitography or magnetic resonance imaging (MRI) were performed when appropriate [16-19]. Data were retrospectively reviewed.

**RESULTS**

There were 76 (80%) patients with congenital adrenal hyperplasia due to 21- $\alpha$ -hydroxylase deficiency, among the 95 Saudi patients. They were 34 males and 42 females patients aged ranged between newborn to 13 years. Salt-wasting was the associated

clinical characteristic presented in 71 (93.4%) patients (Table 1). All patients were having elevated serum 17-hydroxy progesterone (Table 2). There were 42 neonatal or infant deaths among our patients. No genetic studies were done in our patients. Four of the 46 XX patients were initially assigned male sex, which were later reassigned females. One patient with simple

virilization conceived successfully and delivered by caesarean section. Seven of 11 female patients had irregular menses and discovered to have polycystic ovaries and excess androgens. Four of the six male patients tested showed testicular adrenal rest tumours by ultrasound with slight elevation of androstenedione.

**Table 1: Clinical characteristics of 76 patients with congenital adrenal hyperplasia due to 21 $\alpha$ -hydroxylase deficiency at the time of presentation.**

Genetic sex and number	Ambiguous genitalia	Precocious baby	Salt-wasting	Sex of rearing
Male = 34	-	2	32	M = 38 F = 26
Female = 42	38	4	39	UD = 12

M=Male, F=Female, UD = Undetermined sex

**Table 2: The biochemical profile, mean (range) in 76 patients with CAH due to 21 $\alpha$ -hydroxylase deficiency.**

Normal range	ACTH 5-18 Pmol/L	Cortisol 150-685 nmol/L	17-OH progesterone 0.6 – 4.2 nmol/L	Testosterone 0.1-0.4 nmol
Mean (range)	41.7 (9-102)	112 (60-250)	194 (44-920)	1.43 (0.2-2.3)

ACTH – Adrenocorticotrophic hormone

\* 71 patients were salt-waster with low aldosterone and high plasma renin activity

## DISCUSSION

Congenital adrenal hyperplasia (CAH) due to 21-hydroxylase deficiency is an autosomal recessive disorder found in about 1 in 15,000 live births. The exact prevalence in Saudi Arabia is unknown, however, there is an impression fostered by the clinical experience and the limited hospital based studies that it is not a rare disorder. [15, 20-25]. The calculated incidence of the disease was estimated to be 1 in 5,000 live births [21]. The recently introduced universal screening for CAH reported an incidence of one in 6,400 live births [26]. Neonatal screening programmes are well-established worldwide [27-30]. No genetic studies were done in this series, however, it was shown by Mohamed *et al.* [15] in another series from the eastern region of Saudi Arabia the pattern of CYP 21A2 gene mutations.

Virilizing CAH is the most common cause of genital ambiguity, and 90-95% of CAH cases are caused by 21-hydroxylase deficiency. Diagnosis of CAH due to 21-hydroxylase deficiency is usually established by elevated serum 17-hydroxyprogesterone (17-OHP) [31].

Al Awan *et al.* [32] demonstrated the clinical ability of adrenal ultrasonography in the diagnosis of congenital adrenal hyperplasia, as well as others [33-34].

Newborn males with 21-hydroxylase usually show increased phallus size, pigmented scrotum and

bilateral testes or even passed unnoticed and present with neonatal death [35]. This could explain the predominance of females affected in our series. Newborn females with classic virilizing CAH, manifest variable degrees of genital ambiguity that is caused by high systemic level of adrenal androgens.

Medical treatment of CAH in childhood consists of replacement with oral hydrocortisone usually administered as 10-15 mg/m<sup>2</sup>/day in 2-3 divided doses (Alternatively drugs such as prednisone and dexamethasone used in adults). However, a stress dose must be given during surgery or severe acute illness. These drugs serve to suppress ACTH and thereby control excess adrenal androgen synthesis. Salt-wasting patients also require sodium chloride and mineralocorticoid replacement. The Florinef (9 $\alpha$ FF) is often administered orally in a dose of 50-200 mg/day accompanied by 1-2 grams of sodium chloride [5-7, 10, 36-38].

Surgical correction is a complex clinical situation that requires a multi-disciplinary approach. The type of surgical repair performed must be tailored according to each individual patient's anatomy [39-44]. Reconstruction is generally initiated between the age of 3 and 6 months.

Severely virilized patients may initially be assigned as males, as in this series, and once such assignment has been male, it may be difficult to reverse. Among (46 XX) congenital adrenal hyperplasia patient,

due to 21 hydroxylase deficiency patients, four were raised wrongly as males, none of them, refused sex-re-assignment. A multi-disciplinary team consisting of a pediatric endocrinologist, pediatric surgeon or urologist, plastic surgeon, geneticist, and a psychologist should collaborate in managing such patients. The issue should be discussed clearly and openly with patients and should be raised as female as they could have high fertility rate [16-18].

Fertility in females with congenital adrenal hyperplasia due to 21 hydroxylase deficiency reduced especially in classic salt-waster. Several factors have been suggested such as androgen excess, secondary polycystic ovaries syndrome, and psycho-social factors. Adequate glucocorticoid therapy and improvement of surgical and psychosocial management could contribute to optimize fertility. Majority of our female patients have irregular menstrual cycles and polycystic ovaries, however, one with simplevirilizing CAH, had successfully conceived with a good outcome [45-50]. However, fertility in males is poorly studied. While in one series showed normal fertility, others reported substantially reduced fertility [50-51].

Testicular adrenal rest tumours increase with age in CAH. The prevalence of these tumours is variable, ranging from 30 to 95% of patients depending on the selection of patients and methods of detection. Their impact on fertility has not yet completely established. Four of our six patients whom we studied demonstrated testicular adrenal rest tumours, (unpublished data) and indicated the poor control [52-56].

Prenatal diagnosis and treatment with oral dexamethasone given to the mother has been implemented for more than 25 years and was successful in ameliorating genital ambiguity in all pregnancies at 25% risk for classical CAH [57-66]. In utero gene-specific diagnosis guides the treatment of the affected female fetus. Finally, the future guidelines and strategic in the management of children with congenital adrenal hyperplasia could prevent the long-term consequences of the disease [67].

#### ACKNOWLEDGEMENT

The authors would like to thank Ms. Loida M. Sese for typing the manuscript, and extend their thanks and appreciations to Miss Hadeel Nasir Al Jurayyan from Princess NouraBintAbdulrahman University, Riyadh, Saudi Arabia for her help and technical support.

#### REFERENCES

1. New MI; Congenital adrenal hyperplasia. In De Groot LJ editor; Endocrinology. 3<sup>rd</sup> edition. Saunders, Philadelphia, 1995: 1813-1835.

2. Miller WL; Congenital adrenal hyperplasia. *Endocrinol Metab Clin North Am.*, 1991; 20: 721-749.
3. Cutler GB Jr., Laue L; Congenital adrenal hyperplasia due to 21 hydroxylase deficiency. *N Engl J Med.*, 1990; 323(26): 1806-1813.
4. Levine LS; Congenital adrenal hyperplasia. *Pediatr Rev.*, 2000; 21(8): 159-171.
5. Clayton PE, Miller WL, Oberfield SE, Ritzen EM, Sippell WG, Speiser PW; Consensus statement on 21-hydroxylase deficiency from the European Society for Medication Endocrinology and the Lawson Wilkins Pediatric Endocrine Society. *Horm Res.*, 2002; 58: 188-195.
6. Speiser PW, White PC; Congenital adrenal hyperplasia due to steroid 21-hydroxylase deficiency. *Clin Endocrinol.*, 1998; 49(4): 411-417.
7. Antal Z, Zhou P; Congenital adrenal hyperplasia: diagnosis, evaluation and management. *Pediatr Rev.*, 2009; 30(7): 49-57.
8. White PC, Speiser PW; Congenital adrenal hyperplasia due to 21 hydroxylase deficiency. *Endocr Rev.*, 2000; 21(3): 245-291.
9. Bachelot A, Chakthoura Z, Rouxiel A, Dulon J, Touraine P; Classical forms of congenital adrenal hyperplasia due to 21 hydroxylase deficiency in adults. *Horm Res.*, 2008; 69(4): 2013-2211.
10. Forest MG; Recent advances in the diagnosis and management of congenital adrenal hyperplasia due to 21 hydroxylase deficiency. *Hum Reprod Update*, 2004; 10(6): 469-485.
11. Miller WL; Genetics, diagnosis and management of 21-hydroxylase deficiency. *J Clin Endocrinol Metab.*, 1994; 28: 241-246.
12. Maitra A, Shirwalkar H; Congenital adrenal hyperplasia. Biochemical and molecular perspectives. *Indian J Experimental Biology*, 2003; 41(7): 701-709.
13. Peter S, Mc Diagean G, Sandiford P, Smith T; Congenital adrenal hyperplasia in Bahamas due to 21-hydroxylase deficiency. *West Indian Med J.*, 2006; 55(2): 110-112.
14. Rabbani B, Mahdieh N, Ashtiani MA, Akbari MA, Rabbani A; Molecular diagnosis of congenital adrenal hyperplasia in Iran: focusing on CYP21 A2 gene. *Iran J Pediatr.*, 2011; 21(2): 139-150.
15. Mohamed S, El Kholy S, Al Jurayyan N, Al Nemri AM, Abu Amero KK; A CYP 21 A2 gene mutation in patients with congenital adrenal hyperplasia. Molecular genetic report from Saudi Arabia. *Saudi Med J.*, 2015; 36(1): 113-116.
16. Al Jurayyan NAM; Ambiguous genitalia, two decades of experience: clinical management and sex assignment. *J Taibah University Med Sci.*, 2010; 5(1): 13-20.

17. Al Jurayyan NA; Ambiguous genitalia: two decades of experience. *Ann Saudi Med.*, 2011; 31(3): 284-288.
18. Al Jurayyan NAM; Disorders of sex development: diagnostic approach and management options – an Islamic perspective. *Malaysian J Med Sci*, 2011; 18(3): 4-12.
19. Al Jurayyan NA; Imaging of disorders of sex development. *Ann Saudi Med.*, 2013; 33(4): 363-367.
20. Al Herbish AS, Al Jurayyan NA, Abo Bakr AM, Abdullah MA; Congenital adrenal hyperplasia due to 21-hydroxylase deficiency: consequences of delayed diagnosis – can it be prevented. *Saud Med J.*, 1996; 17(1): 66-69.
21. Al Jurayyan NA, Al Herbish AS, Abo Bakr, Al Rabiaah AA, Al Samarra AL, Jawad AJ *et al.*; Congenital adrenal hyperplasia in a referral hospital in Saudi Arabia: epidemiology, pattern and clinical presentation. *Ann Saudi Med.*, 1995; 15(5): 447-450.
22. Salman H, Abanamy A, Ghassan B, Khalid M; Congenital adrenal hyperplasia. *Ann Saudi Med.*, 1991; 11(1): 9-14.
23. Abdullah MA, Katugampola M, Al-Habib S, Al-Jurayyan N, Al-Samarrai A, Al-Nuaim A *et al.*; Ambiguous genitalia: medical, socio-cultural and religious factors affecting management in Saudi Arabia. *Ann Trop Pediatr.*, 1991; 11(4): 343-348.
24. Al Jurayyan NA; Congenital adrenal hyperplasia in Saudi Arabia. The biochemical characteristics. *Int J Health Sci Res.*, 2015; 5(5): 98-102.
25. Al Jurayyan NA, Osman HA; The increased prevalence of congenital adrenal hyperplasia in Saudi Arabia: the role of consanguinity and multiple siblings involvement. *Eur J Res Med Sci.*, 2015; 3(1): 31-34.
26. National Newborn Screening Program; Ministry of Health Report 2012. Saudi Arabia, 2014.
27. Pang S, Wallace MA, Hofman L, Thuline HC, Dorche C, Lyon IC *et al.*; Worldwide experience in newborn screening for classical congenital adrenal hyperplasia due to 21-hydroxylase deficiency. *Pediatrics*, 1988; 81(6): 866-874.
28. Van der Kamp HJ, Wit JM; Neonatal screening for congenital adrenal hyperplasia. *Eur J Endocrinol.*, 2004; 151 (S3): 71-75.
29. White PC; Neonatal screening for congenital adrenal hyperplasia. *Nat Rev Endocrinol.*, 2009; 5(9): 490-498.
30. Speiser PW, New MI; Prenatal diagnosis and treatment of congenital adrenal hyperplasia. *J Pediatr Endocrinol.*, 1994; 7131: 183-190.
31. Marumudi E, Khadgawat R, Surana V, Shabir I, Joseph A, Ammini AC; Diagnosis and management of classical congenital adrenal hyperplasia. *Steroids*, 2013; 78(8): 741-746.
32. Al Alwan I, Navarro O, Daneman D, Daneman A; Clinical utility of adrenal ultrasonography in the diagnosis of congenital adrenal hyperplasia. *J Pediatr.*, 1999; 135: 71-75.
33. Avni EF, Rypens F, Smet MH, Galetty E; Sonographic demonstration of congenital adrenal hyperplasia in the neonate : the cerebri for pattern. *Pediatr Radiol.*, 1993; 23(2): 88-90.
34. Chambrier ED, Heinrichs C, Avni FE; Sonographic appearance of congenital adrenal hyperplasia in utero. *J Ultrasound in Medicine*, 2002; 21(1): 97-100.
35. Grosse SD, Van Vliet G; How many deaths can be prevented by new born screening for congenital adrenal hyperplasia. *Horm Res.*, 2007; 67(6): 284-291.
36. Forest MG; Recent advances in diagnosis and management of congenital adrenal hyperplasia due to 21-hydroxylase. *Human reproduction Update*, 2004; 10(6): 469-485.
37. New MI, White PC, Pang S, Duponel B, Speiser PW; The adrenal hyperplasia. In Scriver CR, Beaudet AL, Sly WS, Valle D editors; *The Metabolic Basis of Inherited Disease*. 6<sup>th</sup> edition, Mc Graw Hill, New York, 1989: 1881.
38. Lamberts SW, Bruining HA, De Jong FH; Corticosteroid therapy in severe illness. *N Eng J Med.*, 1997; 337: 1285-1292.
39. Poppas DP; Clitroplasty in congenital adrenal hyperplasia. *Ad Exp Med Biol.*, 2011; 707: 49-50.
40. Shoeir HM, El Ghazaly WM, Badrawy AT, El Zeiny M; Feminizing genitoplasty in congenital adrenal hyperplasia: the value of urogenital sinus mobilizing. *Ann Pediatr Surg.*, 2012; 8(4): 111-115.
41. Farkas A, Chertin B; Feminizing genitoplasty in patients with 46 XX. Congenital adrenal hyperplasia. *J Pediatr Endocrinol Metab.*, 2001; 14(6): 13-22.
42. Donahoe PK, Gustafson ML; Early one-stage surgical reconstructive of the extremely high vaginal patients with congenital adrenal hyperplasia. *J Pediatr Surg.*, 1994; 29(2): 357-58.
43. Koldt-Wolke F; Timing of surgery for feminizing genitoplasty in patients suffering from congenital adrenal hyperplasia. *Endocr Dev.*, 2014; 27: 203-209.
44. Sturm RM, Durbin-Johnsen B, Kurzrock EA; Congenital adrenal hyperplasia: Current surgical management at academic medical centers in the United States. *J Urol.*, 2015; 193(5 Suppl):1796-801.
45. Hagenfeldt K, Janson PO, Holmdahl G, Falhammar H, Filipsson H, Frisen L *et al.*; Fertility and pregnancy outcome in women with congenital adrenal hyperplasia due to 21-hydroxylase deficiency. *Hum Reprod.*, 2008; 23(7): 1607-1613.
46. Mulaikal RM, Migeon CJ, Rock JA; Fertility rates in female patients with congenital adrenal

- hyperplasia due to 21-hydroxylase deficiency. *N Engl J Med.*, 1987; 316(4): 178-182.
47. Speiser PW, White PC; Congenital adrenal hyperplasia. *N Engl J Med.*, 2003; 349: 776-788.
  48. Claahsen-Vander Grinten HL, Stikkelbroeck NM, Sweep CG, Hermus AR, Otten BJ; Fertility in patients with congenital adrenal hyperplasia. *J Pediatr Endocrinol Metab.*, 2006; 19(5): 677-685.
  49. Merke DP, Bornstein SR; Congenital adrenal hyperplasia. *Lancet*, 2005; 365(9477): 2125-2136.
  50. Cabrera MS, Vogiatzi MG, New MI; Long-term outcome in adult males with classic congenital adrenal hyperplasia. *J Clin Endocrinol Metab.*, 2001; 86(7): 3070-3078.
  51. Jaaskelainen J, Kiekara O, Hippelainen M, Voutilainen R; Pituitary gonadal axis and child rate in males with classical 21-hydroxylase deficiency. *J Endocrinol Invest.*, 2000; 23(1): 23-27.
  52. Claahsen-Vander Grenten HL, Sweep FC, Blickman JG, Hermus AR, Otten BJ; Prevalence of testicular adrenal rest tumors in male children with congenital adrenal hyperplasia due to 21-hydroxylase deficiency. *Eur J Endocrinol.*, 2007; 157(3): 339-344.
  53. Rich MA, Keating MA, Levin HS, Robert K; Tumours of the adrenogenital syndrome: an aggressive conservative approach. *J Urol.*, 1995; 160(5): 1838-1841.
  54. Bonaccorsi AC, Adler I, Figueiredo JG; Male infertility due to congenital adrenal hyperplasia: testicular biopsy findings, hormonal evaluation, and therapeutic results in three patients. *Fertility and Sterility*, 1987; 47(4): 664-670.
  55. Cutfield R, Bateman JM, Odell WD; Infertility caused by bilateral testicular masses secondary to congenital adrenal hyperplasia (21-hydroxylase deficiency). *Fertility and Sterility*, 1983; 40(6): 809-814.
  56. Tiryaki T, Aycan Z, Huecumenglu S, Atayurt H; Testis sparing surgery for steroid unresponsive testicular tumours of the congenital adrenal hyperplasia. *Pediatr Surg Int.*, 2005; 21(10): 853-855.
  57. Tajima T, Fujieda K; Prenatal diagnosis and treatment of steroid 21-hydroxylase deficiency. *Clin Pediatr Endocrinol.*, 2008; 17(4): 95-102.
  58. Nimkarn S, New MI; Prenatal diagnosis and treatment of congenital adrenal hyperplasia. *Pediatr Endocrinol Rev.*, 2006; 4(2): 99-105.
  59. Speiser PW, New MI; Prenatal diagnosis and treatment of congenital adrenal hyperplasia. *J Pediatr Endocrinol.*, 1994; 7(3):183-190.
  60. Mercè Fernández-Balsells M, Muthusamy K, Smushkin G, Lampropulos JF, Elamin MB, Abu Elnour NO *et al.*; Murad MH; Prenatal dexamethasone use for the prevention of virilization in pregnancies at risk for classical congenital adrenal hyperplasia because of 21-hydroxylase (CYP21) deficiency: a systematic review and meta-analyses. *Clin Endocrinol.*, 2010; 73(4): 436-444.
  61. Meyer-Bahlbury HF, Dolezal C, Haggerty R, Silverman M, New MI; Cognitive outcome of offspring from dexamethasone-treated pregnancies at risk for congenital adrenal hyperplasia due to 21-hydroxylase deficiency. *Eur J Endocrinol.*, 2012; 167(1): 103-110.
  62. Ritzen EM; Prenatal treatment of congenital adrenal hyperplasia: a commentary. *Trends Endocrinol Metab.*, 1998; 9(7): 293-295.
  63. New MI, Carlson A, Obeid J, Marshall I, Cabrera MS, Goseco A *et al.*; Prenatal diagnosis for congenital adrenal hyperplasia in 532 pregnancies. *J Clin Endocrinol Metab.*, 2001; 86(12): 5651-5657.
  64. Songya P, Clark AT, Freeman LC, Dolan LM, Immken L, Mueller OT *et al.*; Maternal side effects of prenatal dexamethasone therapy for fetal congenital adrenal hyperplasia. *J Clin Endocrinol Metab.*, 1992; 75(1): 249-253.
  65. Al Herbish AS; Prevention of ambiguous genitalia in congenital adrenal hyperplasia. *Ann Saudi Med.*, 1996; 16(3): 320-322.
  66. Nimkarn S, New MI; Prenatal diagnosis and treatment of congenital adrenal hyperplasia. *Horm Res.*, 2007; 67: 53-60.
  67. Merke DP, Bornstein SR, Avila NA, Chrousos GP; Future directions in the study and management of congenital adrenal hyperplasia due to 21 hydroxylase deficiency. *Ann Intern Med.*, 2002; 136(4): 320-324.