JSCR
Journal of Surgical Case Reports
http://jscr.co.uk

Endoscopic gastric pouch plication - a novel endoluminal incision free approach to revisional bariatric surgery

Authors: Chiranjiv S Virk, I Michael Leitman and Elliot R Goodman.
Location: Beth Israel Medical Centre, New York, USA.
Citation: Virk CS, Leitman M, Goodman ER. Endoscopic gastric pouch plication - a novel endoluminal incision free approach to revisional bariatric surgery. JSCR. 2010 2:1

ABSTRACT

10-40% of Roux-en-Y gastric bypass (RYGB) patients regain significant weight after Roux-en-Y gastric bypass surgery due to dilation of the pouch and/or the gastrojejunal (GJ) anastomosis. Traditional revision surgery is associated with significant morbidity (e.g. post-anastomotic GJ leak) where less invasive endoluminal procedures may represent safer alternatives. The present article reports a case of the safe and successful use of endoluminal gastric pouch plication (EGPP) using the StomaphyX™ device to correct both a dilated gastric pouch and a dilated gastrojejunostomy in a post-RYGB patient who regained significant weight.

INTRODUCTION

Roux-en-Y gastric bypass (RYGB) surgery remains the gold-standard operation worldwide for weight loss. Many studies report excess percentage weight loss of 50-80% over a 24-month period. However weight regain has been reported to be as high as 25-30% of initial excess weight loss. Weight regain after gastric bypass is multifactorial, involving both behavioral and technical factors. Anatomic causes such as gastric pouch and gastrojejunal (GJ) dilation are common; gastro-gastric fistula is much less common. Up to 12% of patients will have some type of surgical revision following gastric bypass surgery due to weight gain or post-operative symptoms such as intractable dumping related to stomal dilation. Revisional gastric bypass surgery is associated with a much higher morbidity and mortality than primary gastric bypass procedures. Newer technologies such as transoral endoscopic plication have recently been employed to minimize post-operative morbidity. The present case study highlights such an endoluminal revision. (1, 2, 3)

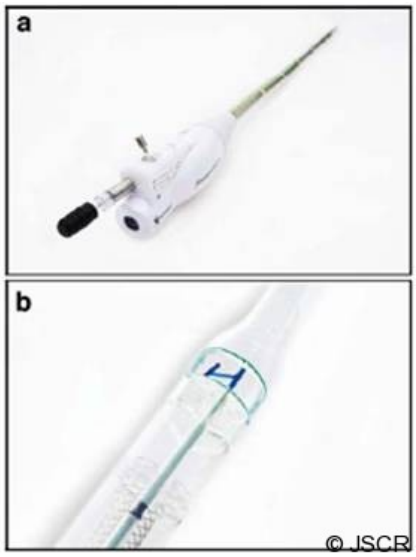

CASE REPORT

This 47-year-old man underwent a RYGB with a 30cc pouch, a 12mm circular stapled GJ and a 150cm long Roux limb in 2005. He lost 75kg with a reduction of BMI of 23.3 (63.7 to 40.4), achieving his lowest weight 3.25 years after his RYGB. The patient started experiencing dumping syndrome and regained 7kg in weight over the next 11 months, going up to a BMI of 42.5. An upper GI series x-ray showed an enlarged gastric pouch. An oesophago-gastro-duodenoscopy (*OGD*) showed a dilated GJ with loss of restriction. As an alternative to an open or laparoscopic revision, the patient elected to undergo endoluminal surgery using the StomaphyX™ device. The procedure was carried out under general anesthesia. An upper endoscopy was first performed to identify the anatomical landmarks of the pouch. The pouch length was noted to be 7 cm. The GJ was again observed to be widely dilated. The endoscope was then inserted through the shaft of the StomaphyX™ device, and the device and endoscope were introduced in tandem transorally into the pouch under continuous visualization. Once inside the pouch, vacuum was employed to draw large folds of gastric pouch wall tissue into the lumen of the device. With the gastric pouch wall on suction, the pouch wall was circumferentially plicated with serial firings of 6mm 3-0 polypropylene fasteners. This plication was in performed at two levels, one at 1 cm above the GJ anastomosis and one at 1 cm below the gastro-oesophageal junction. In total, 22 fasteners were delivered. A completion endoscopy was performed after the plication which showed that the 7-cm pouch had been reduced to 3 cm in length. The luminal diameter as well as the width of the GJ anastomosis was also significantly narrowed. The procedure took 40 minutes to perform with minimal intra-operative bleeding. There were no perioperative or postoperative complications.

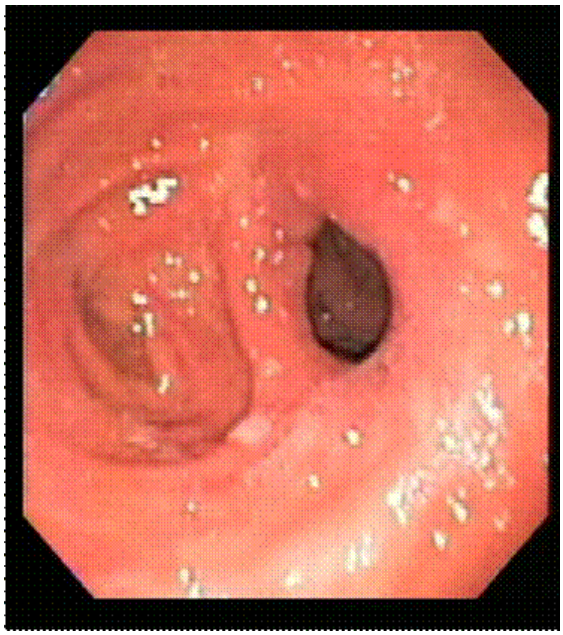

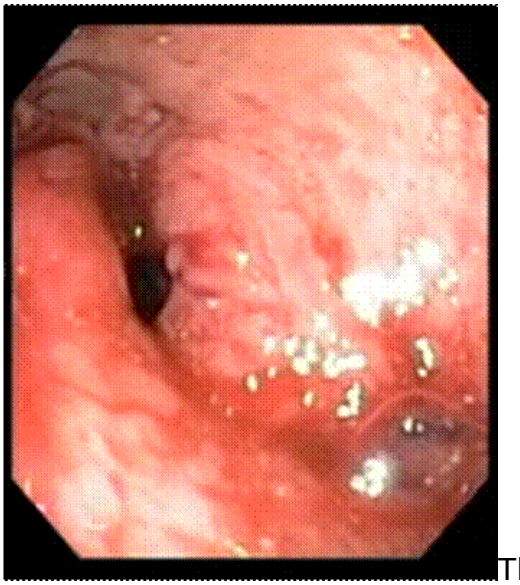

The patient was discharged home the next day. Six weeks after the procedure, the patient had lost 12kg in weight and no longer complained of any dumping syndrome. An upper GI series x-ray obtained 2 months after the pouch plication procedure revealed reduction in the size of the gastric pouch and a delay in emptying of contrast from the gastric pouch into the jejunum.

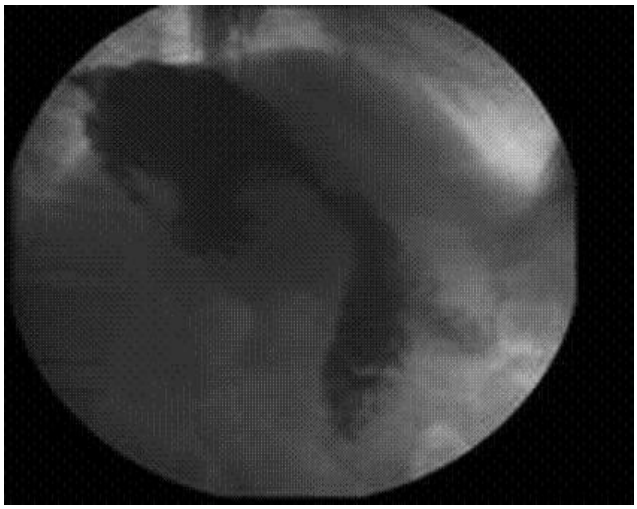

DISCUSSION

The case presented in this paper demonstrates a successful reduction in gastric pouch length, luminal diameter and GJ anastomotic width using the StomaphyX™ device. Gastric pouch emptying into the jejunum was also slowed down after the procedure, correlating with the patient's subjective observation of earlier satiety since the plication and the resolution of his dumping syndrome. EGPP with the StomaphyX™ device is fast and safe. It eliminates the risk of post-operative bleeding, GJ leak, wound infection and incisional hernia seen with more traditional forms of pouch revision. This natural orifice technique is an effective treatment for refractory dumping syndrome after RYGB without the need to perform open or laparoscopic revision. A recent retrospective analysis of 124 patients from three centres at a median 6 months follow up after EGPP demonstrated a mean 43% loss of regained excess body weight (unpublished data from author). While early results look promising, long-term randomized prospective studies need to be carried out in order to validate the effectiveness, safety and durability of EGPP with StomaphyX™.

REFERENCES

1. Thompson CC, Slattery J, Bundga ME, Lautz DB. Peroral endoscopic reduction of dilated

gastrojejunal anastomosis after Roux-en-Y gastric bypass: a possible new option for patients with weight regain. Surg Endosc. 2006 Nov;20(11):1744-8. Epub 2006 Oct 5
2. Overcash WT, Natural orifice surgery (NOS) using StomaphyX for repair of gastric leaks after bariatric revisions. Obes Surg 2008 Jul;18(7):882-5. Epub 2008 Apr 26.
3. Mikami D, Needleman B, Narula V, Durant J, Melvin WS, Natural orifice surgery: initial US experience utilizing the StomaphyX(TM) device to reduce gastric pouches after Roux-en-Y gastric bypass. Surg Endosc 2009 Jul 25. .