ORIGINAL RESEARCH

Randomized clinical study comparing metallic and glass fiber post in restoration of endodontically treated teeth

Olaide S. Gbadebo, Deborah M. Ajayi, Oyekunle O. Dosumu Oyekunle, Peter O. Shaba[1]

Departments of Restorative Dentistry, Faculty of Dentistry, University of Ibadan, Oyo State, [1]Faculty of Dental Sciences, University of Lagos, Lagos, Nigeria

ABSTRACT

Background: Post-retained crowns are indicated for endodontically treated teeth (ETT) with severely damaged coronal tissue. Metallic custom and prefabricated posts have been used over the years, however, due to unacceptable color, extreme rigidity and corrosion, fiber posts, which are flexible, aesthetically pleasing and have modulus of elasticity comparable with dentin were introduced.

Aim: To compare clinical performance of metallic and glass fiber posts in restoration of ETT.

Materials and Methods: 40 ETT requiring post retained restorations were included. These teeth were randomly allocated into 2 groups. Twenty teeth were restored using a glass fiber-reinforced post (FRP) and 20 others received stainless steel parapost (PP), each in combination with composite core buildups. Patients were observed at 1 and 6 months after post placement and cementation of porcelain fused to metal (PFM) crown. Marginal gap consideration, post retention, post fracture, root fracture, crown fracture, crown decementation and loss of restoration were part of the data recorded. All teeth were assessed clinically and radiographically. Fisher's exact test was used for categorical values while log-rank test was used for descriptive statistical analysis.

Results: One tooth in the PP group failed, secondary to decementation of the PFM crown giving a 2.5% overall failure while none in the FRP group failed. The survival rate of FRP was thus 100% while it was 97.5% in the PP group. This however was not statistically significant (log-rank test, $P = 0.32$).

Conclusion: Glass FRPs performed better than the metallic post based on short-term clinical performance.

Received : 19-07-12
Review completed : 09-05-13
Accepted : 12-06-13

Key words: Endodontically treated teeth, fiber-reinforced posts, posts, randomized clinical study

The restoration of the endodontically treated tooth (ETT) represents a key factor during treatment planning because of its impact on the long-term prognosis of the tooth.[1] The pulpless tooth is usually associated with substantial loss of coronal and radicular tooth structure from pre-existing restorations, dental caries, trauma and endodontic access preparation.[2] It is generally assumed that this loss of hard tissue leads to reduced load carrying capacity of ETT.[3] Hence, posts are indicated for ETT that are highly susceptible to fracture because of their insufficient coronal tooth structure.[4-6] Traditionally, prefabricated posts were made with metal, which are at times visible through the structure of ETT especially in the anterior region.[7] Having high rigidity, metal posts appear to vibrate at high frequencies when loaded with lateral forces.[8] The focusing of these forces in unpredictable "critical points" may determine longitudinal fractures of the root or metal corrosion[9,10] and consequently lead to loss of the tooth.[11-13] Some researchers[14,15] have suggested that as these metallic materials have much higher moduli of elasticity than that of the supporting dentin, this mismatch in the moduli could lead to stress concentrating in the cement lute, leading to its failure. This has led to a search for a plastic-based material that has a modulus closer to that of dentin.[16]

Carbon-fiber post, among the many prefabricated fiber post-and-core systems was proposed by Duret *et al.,* in 1990;[17] to reduce the failure rate of post-retained restored teeth. These relatively recent posts are made of equally aligned carbon-fibers attached to an epoxy resin matrix and present an interesting property "anisotropic behavior" with the material having different physical responses when

Address for correspondence:
Dr. Gbadebo S Olaide
E-mail: olaaris2k1@yahoo.com

Access this article online	
Quick Response Code:	Website: www.ijdr.in
	DOI: 10.4103/0970-9290.131126

loaded in different directions. This characteristic is of clinical relevance, as it may strongly reduce the possibility of root fracture and decementation.[11] The objective is to create a "cement-post-core" system with homogeneous properties and physical characteristics similar to tooth tissues.[18,19] In addition, quartz and glass fiber posts embedded in a filled resin matrix have been developed to fulfill aesthetic requirements.[20] Also, restoration of ETT with metal-free, physicochemically homogeneous materials with similar physical properties as dentin, has become a major objective in dentistry.[21]

Researchers and manufacturers have introduced several post-and-core restorations with the aim of providing reliable systems for reconstruction of ETT.[8] In spite of these efforts, it is still difficult to predict the clinical survival times of treated teeth restored with posts and cores. The prognosis may be related to several factors, including the type of material used for the post and core; the shape, dimensions and length of the post and the kind of cement used.

The use of fiber post in comparison with conventional metallic post in restoration of structurally compromised ETT in a developing country like ours is yet to be documented thus, this prospective randomized clinical study was set out to observe and compare the performance of glass fiber posts with metallic stainless steel posts in the restoration of ETT.

MATERIALS AND METHODS

The study was carried out in the Conservation Clinic, Dental Centre University College Hospital, a tertiary hospital in an urban city of Ibadan capital of Oyo state Nigeria. Teeth that had been successfully treated endodontically, required post retained restoration as final coronal restoration and had a minimum of 2 mm coronal tooth structure cervically for ferrule effect were recruited for the study between April 2010 and June 2011. Ethical approval was obtained from University of Ibadan/University College Hospital Ethical Review Committee (UI/EC/10/0026).

One hundred and seventy ETT were assessed in 153 patients during the period of study out of which 40 teeth in 30 patients met the inclusion criteria and were included and randomly allocated using the ballot box into 2 intervention groups. Every alternate patient with a single tooth for restoration picked from the ballot box to choose the type of post to be used for restoration. Hence, consecutive patient automatically had the second type of post for the restoration. In addition, patients that had two teeth treated picked the type of post for the first tooth to be treated and the second type, automatically selected for the second tooth. Thus, each patient with more than one tooth had the two different types of post cemented in them. Group one comprised of teeth treated with metallic stainless steel post while teeth in group two were restored with glass fiber-reinforced posts. The teeth included: 23 (57.5%) central incisors, 6 (15%) lateral incisors, 7 (17.5%) premolars and 4 (10%) molars [Table 1], all in occlusion with natural teeth. In the 40 teeth treated, 75% presented with single canal (the incisors and a mandibular premolar), 15% had 2 canals while 10% had 3 canals. However, only one canal in each tooth received a post (palatal canal in the upper premolars and distal canal in the lower molar).

Clinical procedure

Prior to canal preparation, both clinical and radiographic examinations of each tooth were done to ascertain its suitability for post placement. An appropriate size of glass fiber or stainless steel parapost (PP) post was selected for each canal based on the pre-operative radiograph. The tooth was isolated using rubber dam and provisional restorations removed. Canal preparation was carried out with peso reamer, removing gutta-percha in the canals leaving a minimum of 4 mm at the apex for maintenance of apical seal and canal refinement completed with the drill for the appropriate size of the post selected. The length of the post was checked and reduced to the appropriate length for each tooth using a diamond bur (on fast handpiece) which was kept perpendicular to the long axis of the post in case of the fiber post to avoid damaging the fiber structure and its mechanical characteristics. The length of the posts was at least equal to the length of the clinical crown, ensuring the apical gutta-percha seal of 4 mm.[18]

The canals were cleaned with sodium hypochlorite solution to remove dentin shavings and immediately rinsed off with normal saline after, which canals were dried with paper points. A self-etch primer (Bond Boost: Premier Co., Ltd.,) was applied in the canal with a microbrush and the excess blotted with paper point. Dentin adhesive was applied with a microbrush both inside the canal and on the surface of the post and cured. A dual cure luting composite (IntegraCem: Premier Co Ltd) mixed according to manufacturer's instruction, was applied in the canal with a file and also on the post, which was immediately placed in the prepared canal gently allowing excess cement to flow out to prevent hydrostatic pressure build up in the canal. Post was held in place for about 10 s for initial set and excess cement removed. The composite resin was further cured with composite light curing machine (Smartlite dentsply) of wavelength 450-500 nm applied for 40 s. A total of 20 stainless steel posts were cemented in 20

Table 1: Distribution of tooth type restored in the two groups

Tooth	Group 1 Parapost (%)	Group 2 Glass fiber post (%)	*N* (%)
Central incisors	12 (30)	11 (27.5)	23 (57.5)
Lateral incisors	3 (7.5)	3 (7.5)	6 (15)
Premolars	2 (5)	5 (12.5)	7 (17.5)
Molars	3 (7.5)	1 (2.5)	4 (10)
Total	20 (50)	20 (50)	40 (100)

teeth and also 20 glass fiber posts cemented in 20 teeth. A periapical radiograph was taken at this point to assess the post alignment after cementation. A core of composite was built on the coronal portion of the cemented post and prepared for porcelain fused to metal (PFM) crown. A polyvinyl siloxane impression of the prepared tooth was taken and opposing arch impression taken in alginate. A temporary crown of polycarbonate for anterior teeth or acrylic for posterior teeth was cemented with the temporary cement (TempBond Kerr, Italy), for a minimum of 2 weeks, to allow for completion of the laboratory fabrication of the PFM crown. The PFM crown was cemented in place after about 2 weeks with zinc phosphate cement. A periapical radiograph was taken at cementation and all the clinical parameters recorded. These were also repeated at 1 and 6 months' review.

Based on criteria used by some clinical studies,[2,8,22] the outcome was considered successful if the post and core were *in situ* with no displacement or detachment of the post, no crown or prosthesis decementation and no post, core or root fracture, intact marginal integrity without catching of the explorer or visible crevice, immobility of the final prosthesis (crown), no loss of restoration, absence of endodontic and periradicular conditions requiring endodontic retreatment. Subjective symptoms reported by the patients were considered potential signs of failure. All the cases were treated by one operator.

Two dentists (the researcher and a specialist conservative dentist) evaluated the clinical performance of the restored teeth. Each tooth was assessed both clinically and radiographically after 1 month and 6 months post cementation of PFM crown. The second observer was however blinded.

Statistical analysis

All data were analyzed using the statistical package for the social sciences statistical package version 15 (IBM). Comparisons between the two post groups with regard to the frequency of failures were performed for the 1 month and 6 months follow-ups using the Fisher exact test. Kaplan Meier survival curves were constructed for both groups for descriptive purpose and survival compared with a log-rank test. Inter examiners variability was measured with Kappa. Level of significance was set at 0.05.

RESULTS

A total of 30 patients aged 18-74 years with a mean age of 38.2 ± 16.8 years (standard deviation) were recruited for the study and 40 teeth which met the inclusion criteria were evaluated in these patients. A great majority of the teeth (72.5%) were anterior teeth while the least treated (10%) were molars. Out of these cases, 38 teeth were available (19 in each group) at 1 month review, out of which only a case in metallic post group had slight opening of crevice on probing the margin while all the teeth in the fiber post group were intact. At 6 month review, a tooth in each group had minimal crevice at the margin out of the 16 in group one and 18 teeth in group two that were available for review [Table 2]. At the end of the 6 month review, a total of 10% and 5.6% marginal failure was recorded in group one and two respectively. The difference in the changes recorded in the marginal integrity of the teeth in the two groups at 1 month and 6 months were however, not statistically significant ($P = 1.0$ at 1 month and $P = 0.5$ at 6 months) [Table 2]. In view of crown mobility, a tooth with grade 2 mobility due to core fracture leading to loss of crown retention was recorded in group one accounting for 5.3% of cases with PP and 2.6% of overall cases at 1 month review while a tooth (a central) in each group had grade 1 mobility at 6 month review (this was however, taken as potential failure). All the other teeth in the two groups were intact at the 6 months review. None of the teeth available for review in the 2 groups both at 1 month and 6 month reviews, had fractured PFM restoration, fractured root or post, loss of post retention [Tables 2 and 3]). On radiographic assessment, all the teeth in the two groups had no new or increase in size of periapical radiolucency during the 1 month and 6 months review [Table 3]. The periodontal tissues were healthy in all the cases and no subjective symptoms reported.

Overall survival at 6 months

One tooth in stainless steel PP group failed secondary to decementation of the final coronal restoration-the PFM crown giving a 2.5% overall failure while none in the glass fiber post group failed in terms of loss of post-core-crown retention. This thus gives a 97.5% success in the PP group and a 100% success in the glass fiber post group for the 6 months period they were both reviewed.

Table 2: Clinical evaluation of the teeth

Baseline		1 month			6 months		
	T	*A*	*P*	*T*	*A*	*P*	*T*
Marginal integrity							
Group 1	20	18	1	19	15	1	16
Group 2	20	19	0	19	17	1	18
			P=1.0			*P*=0.5	
Mobility of the crown							
Group 1	20	18	1	19	15	1	16
Group 2	20	19	0	19	17	1	18
			-			*P*=1.0	
Fracture of coronal restoration							
Group 1	20	19	0	19	16	0	18
Group 2	20	19	0	19	18	0	18
Lost restoration							
Group 1	20	19	0	19	16	0	16
Group 2	20	19	0	19	18	0	18
Crown retention							
Group 1	20	18	1	19	16	0	16
Group 2	20	19	0	19	18	0	18
Failure of core							
Group 1	20	18	1	19	16	0	16
Group 2	20	19	0	19	18	0	18

A=Absence of defect, *P*=Presence of defect, *T*=Total

Survival statistical analysis at 6 months: In this study, no statistical difference was found in the frequency of failure at 6 month review and log-rank test used to compare the survival also showed no statistical difference. Log-rank test was $P = 0.14$, when marginal failure was considered, $P = 0.51$ when mobility was considered and 0.32 when core retention was considered. The Kaplan Meier curve [Figures 1 and 2] showed the 2 groups running almost parallel for the period they were observed indicating equal behavior in the 2 groups. The independent examiners' assessment was measured with kappa which gave a score of 0.97 showing strong agreement between the two observers.

DISCUSSION

The present study was set out to observe and compare the clinical performance of two types of prefabricated posts one of which i.e., glass fiber post is relatively new and becoming increasingly popular in restoration of ETT and in its use as an alternative to the metallic post especially in the aesthetic part of the mouth.

The observed 10% change in the marginal fit of a tooth in the metallic post group at 1 month and at 6 months as against 5.6% of the non-rigid glass fiber post group, was not statistically significant. This is in agreement with findings of Rosentritt *et al.*,[23] and Ni[24] who similarly observed minor differences in the marginal fit of teeth restored with these two types of posts. The marginal defect was mainly seen on the labial surface of the tooth with the palatal margin intact which is also in accordance with a report of Ni.[24] The greater percentage seen in the metallic post group may be due to the rigidity of the post. However, besides the rigidity of the post, other factors such as fitness between post and the canal, the final restoration and direction of load may influence the marginal integrity of the restoration.[24] The marginal defect observed in only one tooth (5.6%) in the glass fiber post group is in accordance with the clinical study by Garcia-Gordoy and Ferrari[25] which recorded an excellent performance of teeth restored with glass fiber post with only 2 (5.6%) of the cases presenting with crown dislodgement and poor marginal integrity at 6 months review. The possibility of flexing of fiber post when tooth is under function has been documented to be a favorable property of the post.[18,26] However, excessive flexion can also open the margins leading to caries, endodontic leakage and apical reinfection.[18] This could be the explanation for the tooth with marginal defect in the glass fiber post group. Although the teeth with slight marginal defect observed in this study were intact when other parameters were assessed, the defect can be taken as a potential failure of the restoration.

The grade 2 mobility of the PFM crown in group one at 1 month review of the study was possibly due to the slight defect in marginal fit of the crown secondary to error in fabrication of the crown. This however might have led to leakages thereby causing cementation failure. In this case, the PFM crown was however, removed at the review and recemented with better marginal fit after the margin of the crown was corrected in the laboratory. This tooth was still functioning satisfactorily as at the 6th month review. The mobility recorded in an anterior tooth in group one was not

Table 3: Radiographic evaluation of the teeth

Baseline		1 month			6 months		
	T	*A*	*P*	*T*	*A*	*P*	*T*
Post-retention							
Group 1	20	19	0	19	16	0	16
Group 2	20	19	0	19	18	0	18
Post-fracture							
Group 1	20	19	0	19	16	0	16
Group 2	20	19	0	19	18	0	18
Root fracture							
Group 1	20	19	0	19	16	0	16
Group 2	20	19	0	19	18	0	18
Peri-apical radiolucency							
Group 1	20	19	0	19	16	0	16
Group 2	20	19	0	19	18	0	18

A=Absence of defect, *P*=Presence of defect, *T*=Total

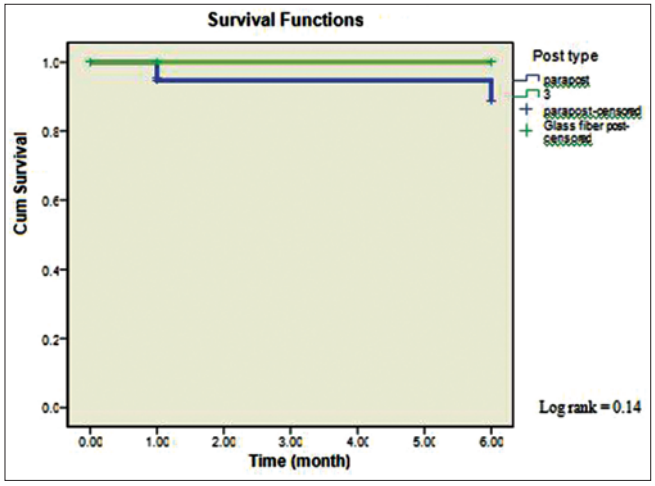

Figure 1: Kaplan Meier survival graph for marginal integrity

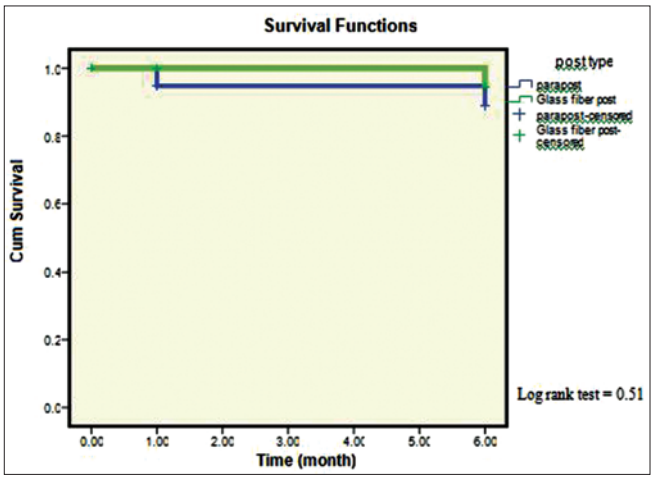

Figure 2: Kaplan Meier survival graph for mobility of crown

statistically different from the single case seen in group two at 6 months review ($P = 1.0$) and it is in accordance with a clinical study[16] where slight mobility of the crowns were recorded in cast post and carbon-fiber group with no case of mobility in the glass fiber post group after 12 month review of the study. However, in the present study, the teeth with mobility in the two groups at 6 months were those that showed slight marginal defect on probing at the same visit. This can thus be recorded as potential failure for the teeth and thus the need for further follow-up.

Though some studies have reported post debonding as most frequent failure in post retained restorations[27,28] and others have reported post fracture as most frequent failure,[29] the present study, observed that all the treated cases reviewed had intact post with no post decementation or post fracture experienced. This also has been the report of few clinical studies,[3,30] on comparison of metallic post and glass fiber posts, where no post fracture or post decementation was recorded after at least 6 month's review. All the posts in this study were cemented with dual cure resin composite, which has been reported to show good retention with little or no marginal leakage, good marginal seal preventing reinfection of the tooth and loss of post retention and acceptable fracture resistance when used to cement prefabricated posts.[30-32] The increased seal may be attributed to the bonding of the resin and post to the root dentin. This may however, be the reason for the good retention recorded both clinically and radiographically over the review period in this study, with no incidence of decementation and microleakage around the restored teeth recorded in relation to the two types of post used as it has been previously documented and demonstrated that resin-based cements have greater retention than do conventional cements, like zinc phosphate.[32,33]

The present study also showed good radiographic result for all the teeth in the two groups in view of periapical lesion, with no case of new periapical lesion recorded. Rather, reduction in lesion present before endodontic treatment and coronal restoration was observed, which indicated good healing. The success recorded in the study, is in keeping with some clinical studies,[30,34] where no significant association was found between periapical lesions and intra-radicular posts. On the contrary, a retrospective study[35] reported a 1.2% failure of fiber posts retained restoration due to the presence of periapical lesion.This was endodontic failure found on radiographic examination with the teeth asymptomatic and not due to technical failures from the post.

A case of fracture of core seen in group one at 1 month was in the tooth that had marginal failure and Grade 2 mobility. The tooth was however, restored back to function with no subsequent failure at further reviews. The initial core failure recorded was due to loss of adhesive bond between the core material and the post. This is similar to findings of Malferarri *et al.*,[8] who reported failure of the core off the post secondary to loss of adhesion of the core to the post.

The absence of root fracture in all the teeth during the study period is in agreement with some clinical studies[2,8,35] on fiber post, which reported no root fracture during the period of their various studies. Also, studies[21,29,36,37] have reported less root fracture in glass fiber post than metallic posts in restoration of ETT due to the near dentin modulus of elasticity of the fiber post which gives it increased resistance to root fracture when compared with metallic post. This result may also be due to the fact that teeth with a minimum of 2 mm tooth tissue coronally for ferrule which has been documented to be more important in prevention of root fracture,[18,38] were considered. It could also be due to the types of posts used in the present study i.e., parallel sided metallic prefabricated posts, which have been reported to have higher resistance to fracture when compared with tapered[39] and glass fiber post which has been reported to show no significant difference in their fracture resistance whether parallel or tapered.[3] Also, glass fiber posts have demonstrated the ability to fracture at the coronal portion of a tooth restoration with the presence of catastrophic forces without fear of root fracture[7] and this may be the single most compelling reason for their use and recorded success.[26]

The success rate of 100% for glass fiber post in the present study is in agreement with Naumann *et al.*,[32] who recorded no failure during their study period, but higher than some other clinical studies who have reported failure rate of glass fiber post as low as 1.7%[8] to as high as 13%.[2] The success rate of 97.5% for the metallic post in the present study is high compared with 75.6% recorded by Schmitter *et al.*,[36] This could however, be due to the fact that a parallel sided passive prefabricated metallic post, which has been documented to have better retention and less failure in terms of fracture of post or root fracture[40] was used as against the screw metallic post used by Schmitter *et al.*[36]

The Kaplan Meier survival analysis in the present study showed no significant difference in the clinical behavior of the 2 groups during the 6 month study period. The glass fiber posts were observed to have had equally good clinical performance within this period when compared with metallic posts. This is in agreement with some clinical studies on survival of glass fiber post,[3,29] that recorded equal performance of the fiber posts within the first 6 months of review and reported no statistical significant difference when Kaplan Meier survival analysis was done. Though the glass fiber post is technique sensitive in application, it is easy to manipulate clinically and when aesthetics is the utmost concern in restoration, glass fiber post should be highly considered.

CONCLUSION

Over a 6 month period, the rehabilitation of ETT using prefabricated glass fiber posts and metallic posts showed comparable clinical results.

The clinical performance of the glass fiber post was slightly better than that of metallic post within the 6 months study period although this was not found to be statistically significant. However a long term review of the restorations will be required for further assessment.

REFERENCES

1. Evidence-based review of clinical studies on restorative dentistry. J Endod 2009;35:1111-5.
2. Mannocci F, Bertelli E, Sherriff M, Watson TF, Ford TR. Three-year clinical comparison of survival of endodontically treated teeth restored with either full cast coverage or with direct composite restoration. J Prosthet Dent 2002;88:297-301.
3. Naumann M, Blankenstein F, Dietrich T. Survival of glass fibre reinforced composite post restorations after 2 years: An observational clinical study. J Dent 2005;33:305-12.
4. Sorensen JA, Martinoff JT. Intracoronal reinforcement and coronal coverage: A study of endodontically treated teeth. J Prosthet Dent 1984;51:780-4.
5. Assif D, Gorfil C. Biomechanical considerations in restoring endodontically treated teeth. J Prosthet Dent 1994;71:565-7.
6. Morgano SM. Restoration of pulpless teeth: Application of traditional principles in present and future contexts. J Prosthet Dent 1996;75:375-80.
7. El-Ela OA, Atta OA, El-Mowafy O. Fracture resistance of anterior teeth restored with a novel nonmetallic post. J Can Dent Assoc 2008;74:441.
8. Malferrari S, Monaco C, Scotti R. Clinical evaluation of teeth restored with quartz fiber-reinforced epoxy resin posts. Int J Prosthodont 2003;16:39-44.
9. Goodacre CJ, Spolnik KJ. The prosthodontic management of endodontically treated teeth: A literature review. Part I. Success and failure data, treatment concepts. J Prosthodont 1994;3:243-50.
10. Ozkurt Z, Işeri U, Kazazoğlu E. Zirconia ceramic post systems: A literature review and a case report. Dent Mater J 2010;29:233-45.
11. Trabert KC, Cooney JP. The endodontically treated tooth. Restorative concepts and techniques. Dent Clin North Am 1984;28:923-51.
12. Morgano SM, Milot P. Clinical success of cast metal posts and cores. J Prosthet Dent 1993;70:11-6.
13. Duret B, Reynaud M, Duret F. New concept of coronoradicular reconstruction: The Composipost (1). Chir Dent Fr 1990;60:131-41 contd.
14. King PA, Setchell DJ, Rees JS. Clinical evaluation of a carbon fibre reinforced carbon endodontic post. J Oral Rehabil 2003;30:785-9.
15. Brown D. Fibre-reinforced materials. Dent Update 2000;27:442-8.
16. Preethi G, Kala M. Clinical evaluation of carbon fiber reinforced carbon endodontic post, glass fiber reinforced post with cast post and core: A one year comparative clinical study. J Conserv Dent 2008;11:162-7.
17. Duret B, Reynaud M, Duret F. A new concept of corono-radicular reconstruction, the Composipost (2). Chir Dent Fr 1990;60:69-77.
18. Wagnild GW, Mueller KI. The restoration of endodontically treated tooth. In: Cohen S, Hargreaves KM, editors. Pathways of the Pulp. 9th ed. St. Louis, Missouri 63043 USA: Mosby Elsevier Inc.; 2006. p. 794-809.
19. Cormier CJ, Burns DR, Moon P. *In vitro* comparison of the fracture resistance and failure mode of fiber, ceramic, and conventional post systems at various stages of restoration. J Prosthodont 2001;10:26-3.
20. Gutmann JL. The dentin-root complex: Anatomic and biologic considerations in restoring endodontically treated teeth. J Prosthet Dent 1992;67:458-67.
21. Akkayan B, Gülmez T. Resistance to fracture of endodontically treated teeth restored with different post systems. J Prosthet Dent 2002;87:431-7.
22. Hommez GM, Coppens CR, De Moor RJ. Periapical health related to the quality of coronal restorations and root fillings. Int Endod J 2002;35:680-9.
23. Rosentritt M, Sikora M, Behr M, Handel G. *In vitro* fracture resistance and marginal adaptation of metallic and tooth-coloured post systems. J Oral Rehabil 2004;31:675-81.
24. Ni CW. Influence of Post–Core Systems in endodontically treated teeth on alveolar bone loss, 2008. p. 1-65. Available from: www.lib.ncku.edu.tw/www2008/search/eresource_en.html.
25. Garcia-Gordoy F, Ferrari M. Clinical trial of fiber posts luted with a self-adhesive cement. Int Dent S Afr 2010;12:14-20.
26. Bateman G, Ricketts DN, Saunders WP. Fibre-based post systems: A review. Br Dent J 2003;195:43-8.
27. Turker SB, Alkumru HN, Evren B. Prospective clinical trial of polyethylene fiber ribbon-reinforced, resin composite post-core buildup restorations. Int J Prosthodont 2007;20:55-6.
28. Bandeca MC, El-Mowarfy O, Shebl A, PortoNeto S. Nonmetallic post-endodontic restorations: A systematic review. Int J Dent 2010;9:57-62.
29. Naumann M, Blankenstein F, Kiessling S, Dietrich T. Risk factors for failure of glass fiber-reinforced composite post restorations: A prospective observational clinical study. Eur J Oral Sci 2005;113:519-24.
30. Ghavamnasiri M, Hosseini SA, Farzaneh H. A clinical evaluation on adhesive post in extensive composite restoration. J Dent Tehran Univ Med Sci 2003;16:46-55.
31. Teixeira EC, Teixeira FB, Piasick JR, Thompson JY. An *in vitro* assessment of prefabricated fiber post systems. J Am Dent Assoc 2006;137:1006-12.
32. Naumann M, Sterzenbac G, Alexandra F, Dietrich T. Randomized controlled clinical pilot trial of titanium vs. glass fiber prefabricated posts: Preliminary results after up to 3 years. Int J Prosthodont 2007;20:499-503.
33. Hedlund SO, Johansson NG, Sjögren G. Retention of prefabricated and individually cast root canal posts *in vitro*. Br Dent J 2003;195:155-8.
34. Rosalem CG, Mattos CM, Guerra SM. Association between intra-radicular posts and periapical lesions in endodontically treated teeth. J Appl Oral Sci 2007;15:225-9.
35. Ferrari M, Vichi A, Mannocci F, Mason PN. Retrospective study of the clinical performance of fiber posts. Am J Dent 2000;13:9B-13.
36. Schmitter M, Rammelsberg P, Gabbert O, Ohlmann B. Influence of clinical baseline findings on the survival of 2 post systems: A randomized clinical trial. Int J Prosthodont 2007;20:173-8.
37. Giovani AR, Vansan LP, de Sousa Neto MD, Paulino SM. *In vitro* fracture resistance of glass-fiber and cast metal posts with different lengths. J Prosthet Dent 2009;101:183-8.
38. Salameh Z, Sorrentino R, Papacchini F, Ounsi HF, Tashkandi E, Goracci C, *et al*. Fracture resistance and failure patterns of endodontically treated mandibular molars restored using resin composite with or without translucent glass fiber posts. J Endod 2006;32:752-5.
39. Isidor F, Brøndum K. Intermittent loading of teeth with tapered, individually cast or prefabricated, parallel-sided posts. Int J Prosthodont 1992;5:257-61.
40. Schwartz RS and Robbins JW. Post placement and restoration of endodontically treated teeth: A literature review. J Endo 2004;30:289-301.

How to cite this article: Gbadebo OS, Ajayi DM, Dosumu Oyekunle OO, Shaba PO. Randomized clinical study comparing metallic and glass fiber post in restoration of endodontically treated teeth. Indian J Dent Res 2014;25:58-63.

Source of Support: Nil, **Conflict of Interest:** None declared.