

## Case Report: An Ectopic Case of *Tunga* spp. Infection in Peru

Vicente Maco, Vicente P. Maco, and Eduardo Gotuzzo\*

*Institute of Tropical Medicine Alexander von Humboldt, Universidad Peruana Cayetano Heredia, Lima, Peru; Clínica Quirúrgica Guadalupe, Lima, Peru; Hospitales de la Solidaridad, Lima, Peru*

**Abstract.** Tungiasis is a neglected ectoparasitism of impoverished areas in South America and sub-Saharan Africa. The sand flea *Tunga* spp. preferably infests the soles and the periungueal and interdigital regions of the feet. Ectopic tungiasis is rare, even in highly endemic areas. We describe a case of an indigenous patient in Peru who presented with a nodular lesion in the extensor aspect of the knee and whose biopsy was compatible with *Tunga* spp. This is the first documented case of knee tungiasis in an endemic country. The historical, clinical, histological, and current epidemiological aspects of tungiasis in Peru are discussed here.

### INTRODUCTION

Tungiasis is an endemic zoonotic ectoparasitism caused by the penetration of the pregnant female sand flea *Tunga* spp. into the skin. Two species, *Tunga penetrans* (Linnaeus) and *Tunga trimamillata* (Pampiglione and others), cause human tungiasis; infection by the latter has been reported only in Ecuador and Peru.<sup>1,2</sup> In Peru, the sand flea is also termed *nigua* (from the Arawak) or *pique* (from the Quechua), and it most commonly affects individuals living in poverty-stricken villages or suburban areas. The most vulnerable are those who walk barefoot or wear sandals, and tungiasis affects the lower extremities of the victims. Although Peruvian physicians and other care providers have been aware of tungiasis for centuries, little is actually known about the current epidemiology of tungiasis in Peru.<sup>3</sup>

Several cases, mainly in travelers returning from endemic areas, have been reported throughout the world.<sup>4–7</sup> Large prospective studies in Brazilian favelas or shantytowns have shown that the prevalence of tungiasis may be as high as 40%. However, the majority of case series and in particular, one of the largest case series from an endemic area reported that the prevalence of ectopic tungiasis is 6%.<sup>8,9</sup>

Tungiasis can be a crippling disease, leading to secondary superinfection with other bacteria, cellulitis, abscess, tetanus, auto-amputations, thrombophlebitis, and sepsis.<sup>9,10</sup> We present a rare case of knee tungiasis diagnosed by an excisional biopsy, and this information reflects the disinterest and lack of knowledge of this ectoparasitism among health-care providers in areas of Lima, Peru.

### CASE REPORT

The Hospitales de la Solidaridad (Hospitals of Solidarity) belong to a local government-funded network of hospitals in urban and suburban areas of Lima; these hospitals serve a massive number of uninsured individuals mainly from poor neighborhoods and pueblos jóvenes or asentamientos humanos (shantytowns). Since their opening in 2003, the hospitals have provided care to individuals unable to afford the high prices for medical care. From 10 of 23 hospitals in the network, we obtained and examined 47,686 paraffin-embedded tissue samples of diverse pathologies collected between 2008 and

2009; 1,665 (0.28%) skin biopsies were received during this time frame. Five cases of tungiasis were diagnosed; one case with an unusual topography is described here.

Briefly, the patient was an 8-year-old mestizo female from Villa El Salvador, a district located approximately 25 km south of Lima. In the past, Villa El Salvador was a vastly rugged, sandy, inhabited terrain. In the early 1970s, hundreds of immigrant families migrated there because of the expansion of terrorism, unending poverty, and lack of education systems in the Andes; the migration continued for three decades. The area remains one of the poorest districts in Lima with 46.6% of the residents living in poverty. About 86,000 marginalized individuals live in shantytowns without basic services such as electricity, supply of clean water, and sewage systems. Built on unpaved, muddy streets, their dwellings are constructed with cane mats, cardboard, and metal plates.

The patient's main complaint was a painful nodule on her left knee that she noticed about 3 weeks before her evaluation. On physical examination, a 5-mm nodule with a central 3-mm crater-like erosion and central black dot, surrounded by a whitish halo and mild erythema, was found on the extensor aspect of her right knee. As the nodule progressively increased in size, the patient sought medical attention and was examined by a general practitioner who inspected her skin in its entirety. No other skin lesions were documented. The isolated knee nodule was biopsied, and the sample was sent, under the presumptive diagnosis of skin malignancy, to our Department of Pathology.

**Histopathological findings.** On gross examination, a firm and rounded crater-like nodule, measuring 0.5 × 0.5 × 0.4 cm with a central black dot, was found. After bisecting the specimen, we noted the numerous oval, whitish egg-like structures and sent the specimen for tissue processing (Figure 1).

On microscopic examination, the epidermis showed acanthosis, hyperkeratosis, parakeratosis, hypergranulosis, spongiosis, papillomatosis, and a hemorrhagic area in the dermis. An ovoid, basophilic cuticle with a cellular layer underneath (hypodermal cells) was noticed (Figure 2B, arrow). We observed multiple structures suggestive of eggs in different stages of development (Figure 2B, arrowhead), tracheal rings, and part of the digestive tract compatible with *Tunga* spp. within the cystic lesion. According to the Fortaleza classification, the time of tissue collection after the onset of symptoms (about 3 weeks), the absence of a watchglass-like appearance, and the histological patterns on the epidermis, such as spongiosis, categorized this lesion as substage 4a (early involution of lesion).<sup>11</sup> Because the manipulation of the sample by the patient and the sampling technique used by the health provider

\* Address correspondence to Eduardo Gotuzzo, Instituto de Medicina Tropical Alexander von Humboldt, Honorio Delgado 430, Ingeniería, San Martín de Porres, Lima, Peru. E-mail: egh@upch.edu.pe

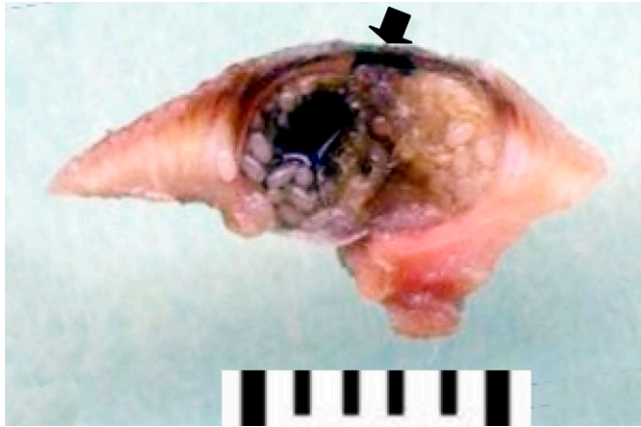


FIGURE 1. Macroscopy. A 3-mm crater-like nodule with a central black dot revealed numerous eggs after a transverse excision. Also note the posterior end (arrow) of the pregnant female flea on the transverse section. This figure appears in color at [www.ajtmh.org](http://www.ajtmh.org).

resulted in inadequate and distorted tissue sections, further attempts to identify either of the two species of *Tunga* (*T. penetrans* or *T. trimamillata*) based on the histological features of the internal anatomical organs described by Pampiglione and others<sup>12</sup> were limited.

#### COMMENTS

The sand flea, endemic to the Americas, was accidentally introduced to Africa and the rest of the Eastern hemisphere as a result of transoceanic voyages during the 19th century.<sup>2,8,13</sup> It was first mentioned by the Spanish chronicler Fernandez de Oviedo y Valdes in 1526 and then, by numerous chroniclers, explorers, and travelers to Central and South American countries in the following centuries.

Evidence of its existence in Peru dates back to the Incan civilization and the Spanish conquest of the Americas. In the pre-Columbian era, autochthonous Peruvian inhabitants of the coast depicted tungiasis and several other dermatologic insults on ornaments and pottery called huacos; the pictorials included anthropomorphic figures examining the soles of their feet on which there were holes attributed to the parasite and individuals extracting the sand flea from their feet with

pointed objects.<sup>3,14,15</sup> Moreover, the first reference to tungiasis in the local literature was made by the Peruvian Indian Phelipe Guaman Poma de Ayala (ca. 1535–1619) in his manuscript *First New Chronicle and Good Government*, a manuscript in part written in rough Spanish and in other parts, in Quechua and Aymara.<sup>16</sup> In rewriting the history of Christendom to include autochthonous people, he allegorically described a series of insect plagues, including the pique niua, as God's punishment to the indigenous population:

“Also called a miracle of God is the punishment and pestilence of mice on the plains and the great damage done by birds in the field throughout the Cordillera of the North Sea, as well as the death of many people of hunger and pestilence of mosquitoes, flies, skeeters, lice, fleas, pique niua.”

Even in populations with high indices of infestation, ectopic tungiasis is rare. In poor neighborhoods such as the favela of Serviluz, Fortaleza, Brazil, where the infestation level is high, the prevalence of ectopic tungiasis may be up to 5.5%, and it mostly affects the hands of children under 15 years old.<sup>9</sup> In an outbreak of tungiasis in rural Haiti, only 11.36% of 132 individuals infected had the flea appear in locations other than the feet.<sup>17</sup> The most common ectopic topography appears on the hands, although it has been observed on the thigh, elbow, breast, inguinal areas, gluteal region, trunk, abdomen, face, eyelid, testes, penis, pubis, and wrist.<sup>2,5,9,18,19</sup> Our case is the first human tungiasis located on the knee, an unusual area.

The ectopic location of this parasite is unusual, because it is well-known that the flea is a poor jumper. In its attempt to reach a host and penetrate the epidermis, the pregnant female jumps a height of between 15 and 35 cm.<sup>17,20</sup> As a result, the most common site of penetration is the foot. However, Heukelbach and others<sup>9</sup> have observed that fleas are able to run across the skin at speeds of 10 mm/second, and this may explain the atypical sites of parasitism.<sup>9</sup> Whereas ectopic tungiasis presents almost exclusively in patients with multiple lesions, the case reported here is a child who presented with an isolated ectopic lesion.<sup>10</sup>

Epidemiological data describing this parasitosis in Peru are scanty, reflecting the lack of interest among local care providers. To illustrate this, a thorough search on PubMed, Scielo, LILACS, and MedLine produced no articles on the epidemiology of tungiasis in Peru; the exceptions were a letter to the editor about a new species *T. trimamillata* found in animals (but not in humans) from northern Piura and an isolated case

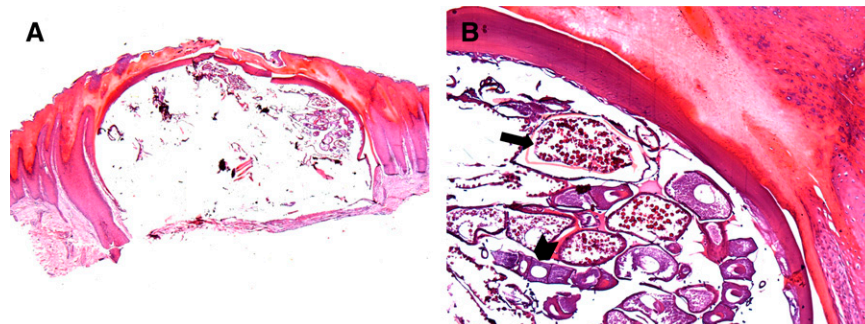


FIGURE 2. Histological features of ectopic tungiasis in an 8-year-old child from a Peruvian shantytown. **A** represents a disrupted basophilic chitinous structure burrowed into the stratum corneum that was compatible with the *Tunga* spp. exoskeleton (hematoxylin and eosin, 40 $\times$ ). The head, usually located in the epidermal–dermal junction, was not found because of sampling techniques. **B** shows a thick cuticle, which is a hypodermal layer (arrow) with many eggs (arrowhead) inside and part of the digestive tract (hematoxylin and eosin, 200 $\times$ ). This figure appears in color at [www.ajtmh.org](http://www.ajtmh.org).

report of an individual from Huaura, Lima, who presented with 15 black tender nodules in both feet.<sup>1,21</sup> We found a succinct reference on parasitic and venomous arthropods; among them, tungiasis was reported to be distributed in coastal areas and highlands, infecting men, swine, and dogs.<sup>22</sup> Anecdotally, one Peruvian patient with a pruritic papule on her foot was reported in Switzerland.<sup>23</sup>

According to Feldmeier and others,<sup>24</sup> the histological findings of hyperplasia, hyperkeratosis and inflammation in our patient are among the prevailing characteristics of tungiasis. Although other parts of the exoskeleton were not recovered because of improper biopsy techniques, the multiple eggs in different stages of development and the cuticle with a hypodermal layer enabled us to diagnose the parasite. As previously suggested, these features are important clues in diagnosing tungiasis, because the pregnant flea's architecture can be deformed by manipulation of the host or inadequate tissue-processing techniques.<sup>25</sup>

Over the last decade, tungiasis has regained the interest of the scientific community<sup>26</sup> with the discovery of a new species of *Tunga* and the publication of several Brazilian studies of ectoparasitism epidemiology, histopathology, and biology. To avoid the use of the improper diagnostic methods described in this case, the recognition of the ectoparasitism among health-care providers in Peru should be emphasized. This can be achieved by performing epidemiological studies to understand the current status of this ancient parasitism in Peru, and these studies may lead to identification and intervention campaigns to prevent future infections.

Received January 15, 2010. Accepted for publication March 2, 2010.

Acknowledgments: The authors thank Pr. Dr. Manuel Tantalean from the Parasitology Laboratory, School of Veterinary Medicine and Zootechnia, Universidad Peruana Cayetano Heredia, Lima, Peru, for reviewing this article.

Authors' addresses: Vicente Maco and Eduardo Gotuzzo, Instituto de Medicina Tropical Alexander von Humboldt, Universidad Peruana Cayetano Heredia, Lima, Peru, E-mails: vicente\_maco@hotmail.com and egh@upch.edu.pe. Vicente P. Maco, Department of Pathology, Hospitales de la Solidaridad and Clinica Quirurgica Guadalupe, Chorrillos, Lima, Peru, E-mail: vmaco@speedy.com.pe.

## REFERENCES

- Fioravanti ML, Gustinelli A, Onore G, Pampiglione S, Trentini M, 2006. Presence of *Tunga trimamillata* (Insecta, Siphonaptera) in Peru. *Parasite* 13: 85–86.
- Pampiglione S, Fioravanti ML, Gustinelli A, Onore G, Mantovani B, Luchetti A, Trentini M, 2009. Sand flea (*Tunga* spp.) infections in humans and domestic animals: state of the art. *Med Vet Entomol* 23: 172–186.
- Guerra F, 1990. Nosologia precolombina. *La Medicina Precolombina*. Madrid: Instituto de Cooperacion Iberoamericana, 89–114.
- Goldman L, 1976. Tungiasis in travelers from tropical Africa. *J Am Med Assoc* 236: 1386.
- Sanusi ID, Brown EB, Shepard TG, Grafton WD, 1989. Tungiasis: report of one case and review of the 14 reported cases in the United States. *J Am Acad Dermatol* 5: 941–944.
- Van Buskirk C, Burd EM, Lee M, 2006. A painful, draining black lesion on the right heel. *Clin Infect Dis* 43: 65–66.
- Hager J, Jacobs A, Orengo IF, Rosen T, 2008. Tungiasis in the United States: a travel souvenir. *Dermatol Online J* 14: 3.
- Heukelbach J, Araujo Sales de Oliveira F, Hesse G, Feldmeier H, 2001. Tungiasis: a neglected health problem of poor communities. *Trop Med Int Health* 6: 267–272.
- Heukelbach J, Wilcke T, Eisele M, Feldmeier H, 2002. Ectopic localization of tungiasis. *Am J Trop Med Hyg* 67: 214–216.
- Heukelbach J, 2005. Tungiasis. *Rev Inst Med Trop Sao Paulo* 47: 307–313.
- Eisele M, Heukelbach J, Van Marck E, Mehlhorn H, Meckes O, Franck S, Feldmeier H, 2003. Investigation on the biology, epidemiology, pathology and control of *Tunga penetrans* in Brazil: I. Natural history of tungiasis in man. *Parasitol Res* 90: 87–99.
- Pampiglione S, Fioravanti ML, Gustinelli A, Onore G, Rivasi F, Trentini M, 2005. Anatomy of *Tunga trimamillata* (Insecta, Siphonaptera, Tungidae) and developmental phases of the gravid female. *Parasite* 12: 241–250.
- Jeanselme E, 1937. Maladies Exotiques de la Peau et du Tissu Conjonctif—Puce Chique. Joyeux C, Sice A, eds. *Précis de Médecine Coloniale*. Paris: Libraires de l'Académie de Médecine, 438–441.
- Moodie RL, 1919. New observations in paleopathology. *Ann Med Hist* 2: 241–247.
- Moodie RL, 1920. Studies in paleopathology: the diseases of the ancient Peruvians and some account of their surgical practices. *Surgical Clinics of Chicago* 4: 211–231.
- Guaman Poma de Ayala, 1615/1616. Primer Capitvlo d los Ingas: Armas Propias. El Primer Nueva Corónica y Buen Gobierno. Available at: <http://www.kb.dk/permalink/2006/poma/info/en/frontpage.htm>. Accessed November 2009.
- Joseph JK, Bazile J, Mutter J, Shin S, Ruddle A, Ivers L, Lyon E, Farmer P, 2006. Tungiasis in rural Haiti: a community-based response. *Trans R Soc Trop Med Hyg* 100: 970–974.
- Connor DH, 1976. Diseases caused by arthropods—tungiasis. Binford CH, Connor DH, eds. *Pathology of Tropical and Extraordinary Diseases, An Atlas*, Vol. 2. Washington, DC: Armed Forces Institute of Pathology, 610–614.
- Heukelbach J, Sahebali S, Van Marck E, Sabóia Moura RC, Feldmeier H, 2004. An unusual case of ectopic tungiasis with pseudoepitheliomatous hyperplasia. *Braz J Infect Dis* 8: 465–468.
- Samlaska CP, 1994. Arthropod infestations and vectors of disease. James WD, ed. *Military Dermatology*. Washington, DC: Armed Forces Institute of Pathology, 183–196.
- Beltran MF, 2005. Tungiasis y *Tunga penetrans*. *Rev Peru Med Exp Salud Publica* 22: 323–324.
- Guillen Z, Tantalean M, 1995. Artropodos parasitos y venenosos del Peru. *Theorema* 6: 16–17.
- Marazza G, Campanelli A, Kaya G, Braun RP, Saurat JH, Pigué V, 2009. *Tunga penetrans*: description of a new dermoscopic sign—the radial crown. *Arch Dermatol* 145: 348–349.
- Feldmeier H, Eisele M, Van Marck E, Mehlhorn H, Ribeiro R, Heukelbach J, 2004. Investigations on the biology, epidemiology, pathology and control of *Tunga penetrans* in Brazil: IV. Clinical and histopathology. *Parasitol Res* 94: 275–282.
- Smith MD, Procop GW, 2002. Typical histologic features of *Tunga penetrans* in skin biopsies. *Arch Pathol Lab Med* 126: 1714–1716.
- Feldmeier H, Heukelbach J, 2009. Epidermal parasitic skin diseases: a neglected category of poverty-associated plagues. *Bull World Health Organ* 87: 152–159.