



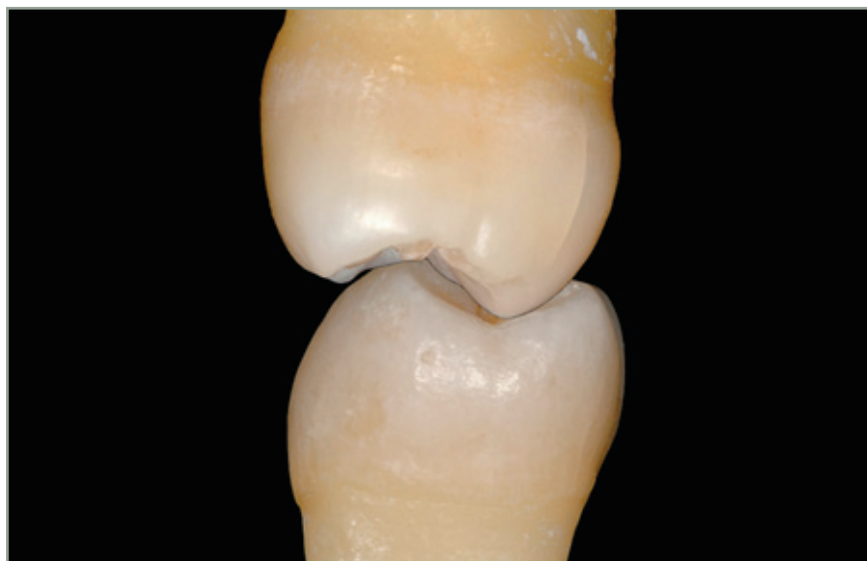Bio-Emulation: Biomimetically Emulating Nature Utilizing a Histo-Anatomic Approach; Structural Analysis

Panaghiotis Bazos, DDS

Emulation, Athens, Greece

Pascal Magne, DMD, MSc, PhD

Don and Sybil Harrington Professor of Esthetic Dentistry,
Herman Ostrow School of Dentistry,
University of Southern California, Oral Health Center,
Los Angeles, CA, USA



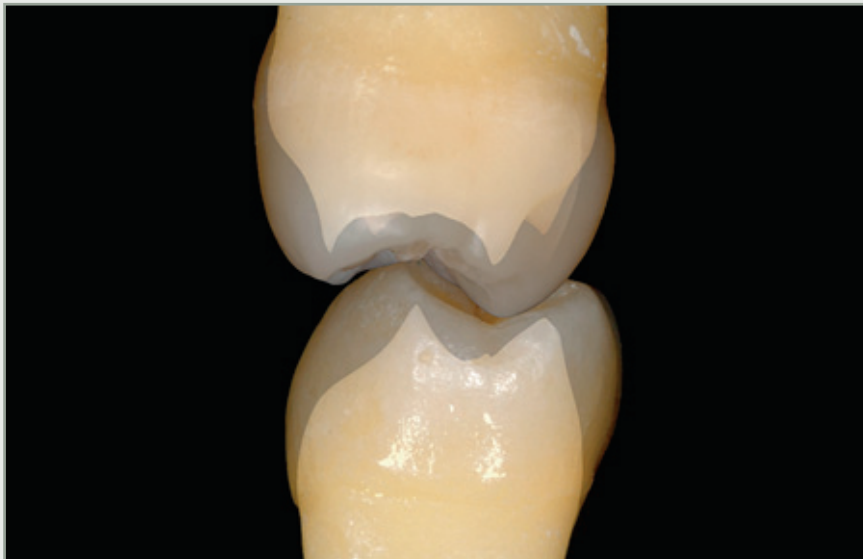Correspondence to: Panaghiotis Bazos
33 Vasilissis Sophias Avenue 106 75 Athens, Greece
Tel: +30 210 722 2329; e-mail: p_bazos@mac.com




A thorough understanding of the histo-anatomic structures and dynamic light interaction of the natural dentition provides dental practitioners with the ultimate strategic advantage with regard to optical integration of the final restoration. The first part of this article will attempt to provide insight on the three-dimensional coronal configuration of natural teeth and on the utilization of this knowledge in the clinical and technical restorative approach.

The main goals for this article are to identify and reveal previously unreported histo-anatomic interrelationships and to explain existing ones: the sigmoid curve distribution (convex enamel/concave dentin), the distinction between dentino-enamel “junction” (DEJ, visual interface) and dentinoenamel “complex” (DEC, functional interphase), and the structural significance of DEC preservation.

(Eur J Esthet Dent 2011;6:8–19)





Introduction

In the modern dental practice, the restoration and tooth should form a structurally adhesive and optically cohesive medium, which has the ability to withstand repetitive multi-axial bio-mechanical force loads over a prolonged period of time.

By means of the evolution, advancement, and refinement of adhesive dental technology^{1,2} with regard to the bonding materials available on the market in conjunction with the validated clinical protocols at hand,^{3,4} clinicians and technicians have the ability to biomimetically reproduce the union between synthetic dental materials and natural anatomic tooth structures.⁵

With the perpetual improvement of dental restorative materials, their properties now include optical light transmission and color dynamics, adding to the plethora of choices. With a multitude of shades, translucencies, opacities, effects and stratification techniques,⁶⁻¹¹

the dental professional endeavors to faithfully emulate¹²⁻¹⁴ the naturally intact tooth, which serves as the model, mentor and measure.

Despite the aforementioned significant advancements and improvements, re-creating the anatomical form and optical features of the intact tooth remains an arduous, challenging and at times elusive task, both within the clinical and technical dental realms. In order to optimize the optical integration of modern composite resins and silica-based ceramics for restorative dental emulation, a thorough understanding of the coronal elements (enamel/dentino-enamel junction (DEJ)/dentin), their three-dimensional configuration and respective spatial inter-relationships, is deemed compulsory.

Methodology

To ascertain the morphologic relationship between the exterior surface of

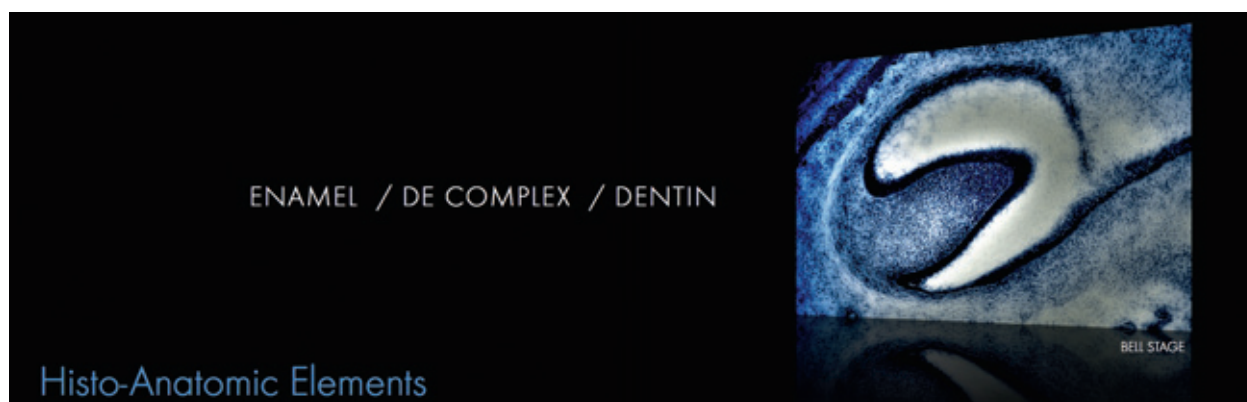

Fig 1 Bell Stage: Histo-differentiation is the process of transforming a mass of similar-looking epithelial cells into morphologically and functionally distinct components (enamel/dentinoenamel complex/dentin). Morpho-differentiation is the process whereby individual tooth buds attain recognizable shapes (incisor vs molar).



the enamel layer and the DEJ, the teeth were submerged in 10% hydrochloric acid (HCl, Mallinckrodt Baker Inc, Phillipsburg, NJ, USA) under ultrasonic vibration for 20 minutes, which led to selective enamel demineralization.

Subsequently, the teeth were soaked in distilled water for 1 hour in order to neutralize the acid and facilitate handling. The specimens were photographed (D200, Nikon Inc, Melville, NY, USA) on a custom fabricated tripod jig (XX-Halter, Novoflex, Memmingen, Germany) maintaining standardized illumination, exposure settings and perspective, prior to and after the acid treatment, in order to ensure proper alignment of the superimposed images.

DEJ as the structural epicenter

One must examine the significance of the DEJ as an important factor in the understanding of the developmental adaptation of the surface pattern of enamel expression.

During odontogenesis, this junctional interface serves as the histologic blueprint (Fig 1), representing a complex interdigitation zone between two distinct anisotropic calcified tissues with different biochemical compositions (Fig 2): *i)* enamel serving as the structural protective shell and *ii)* dentin serving as the structural dampening core (Fig 3a). The enamel and dentin demarcation is due to the difference of birefringence

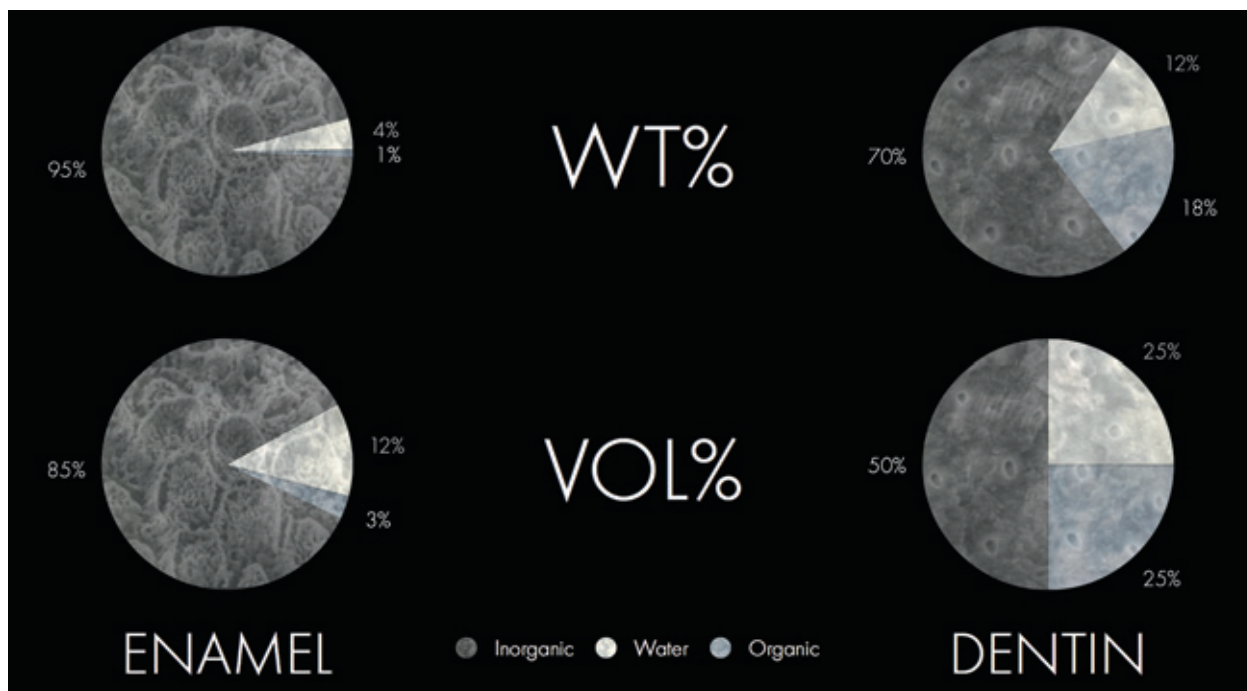


Fig 2 Enamel is the densely mineralized brittle yet hard outer shell of the tooth that envelopes/engulfs the softer dentin core; carbonate-rich hydroxyapatite crystals are arranged in enamel rods. Dentin, conversely, is a collagen-rich apatite reinforced bio-composite that is resilient yet tougher than enamel and similar at the nanostructural level to bone. It has a unique structural architecture consisting of dentinal tubules surrounded by peritubular dentin cylinders of randomly orientated apatite crystallites, embedded in an intertubular dentin matrix.

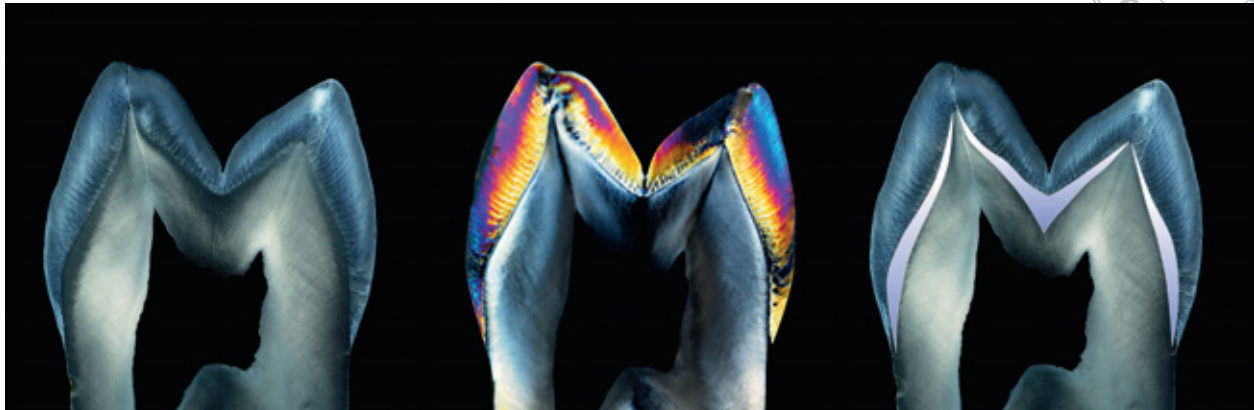

Fig 3 The DEJ, when examined histologically, provides a visual interface, yet when examined on a bio-mechanical level it is regarded as a functional interphase. Seen above is a 0.5 mm buccal/lingual histological section of a maxillary first premolar that was submerged in distilled water and photographed on a black background **(a)**. The same specimen was photographed by transmissive cross-polarized illumination **(b)**. The extended dentin-enamel complex is highlighted **(c)**.

between the tissues (Fig 3b). The DEJ is less mineralized than either enamel or bulk dentin, conversely being richer than either in organic matrix. Microscopically, a bi-scalloped surface topography is present, establishing a complex zone capable of plastic deformation while being collagen fibril-reinforced.¹⁵

Considerable interest has been shown in the interconnectivity of the inner aprismatic enamel, the DEJ and the outer layer of dentin, known as the “mantle dentin” approximately 150 microns in thickness, which is synthesized at the onset of dentinogenesis.¹⁶ This extended dentin-enamel complex (DEC) has been histologically described¹⁷ and observed as a functionally graded interphase between two vastly bio-mechanically different tissues that provides crack tip shielding.¹⁸ This is partially accomplished by a localized reduction in density and mineralization, in both enamel and dentin as they approximate their junction¹⁹ (Fig 3c).

Microstructure: enamel vs dentin

The microstructure of enamel is dominated by hydroxyapatite crystal-rich enamel rods, cemented together by an organic matrix protein polymer. Brittle yet stiff, enamel undergoes only minimal deformation while transferring loads to the underlying dentin. The key to the unusual properties of enamel lies in its unique three-dimensional structural arrangement, which consists of very long rods of carbonated apatite arranged in directional bundles. These bundles are progressively interwoven at higher hierarchical levels. The rise in crack growth resistance is largely attributed to a combination of mechanisms, which include crack bridging, crack bifurcation and crack curving, induced by prism decussation of the inner enamel.²⁴

The microstructure of coronal dentin appears to be that of a mineralized collagen fiber bio-composite, the intertubular dentin being the matrix and the dentin

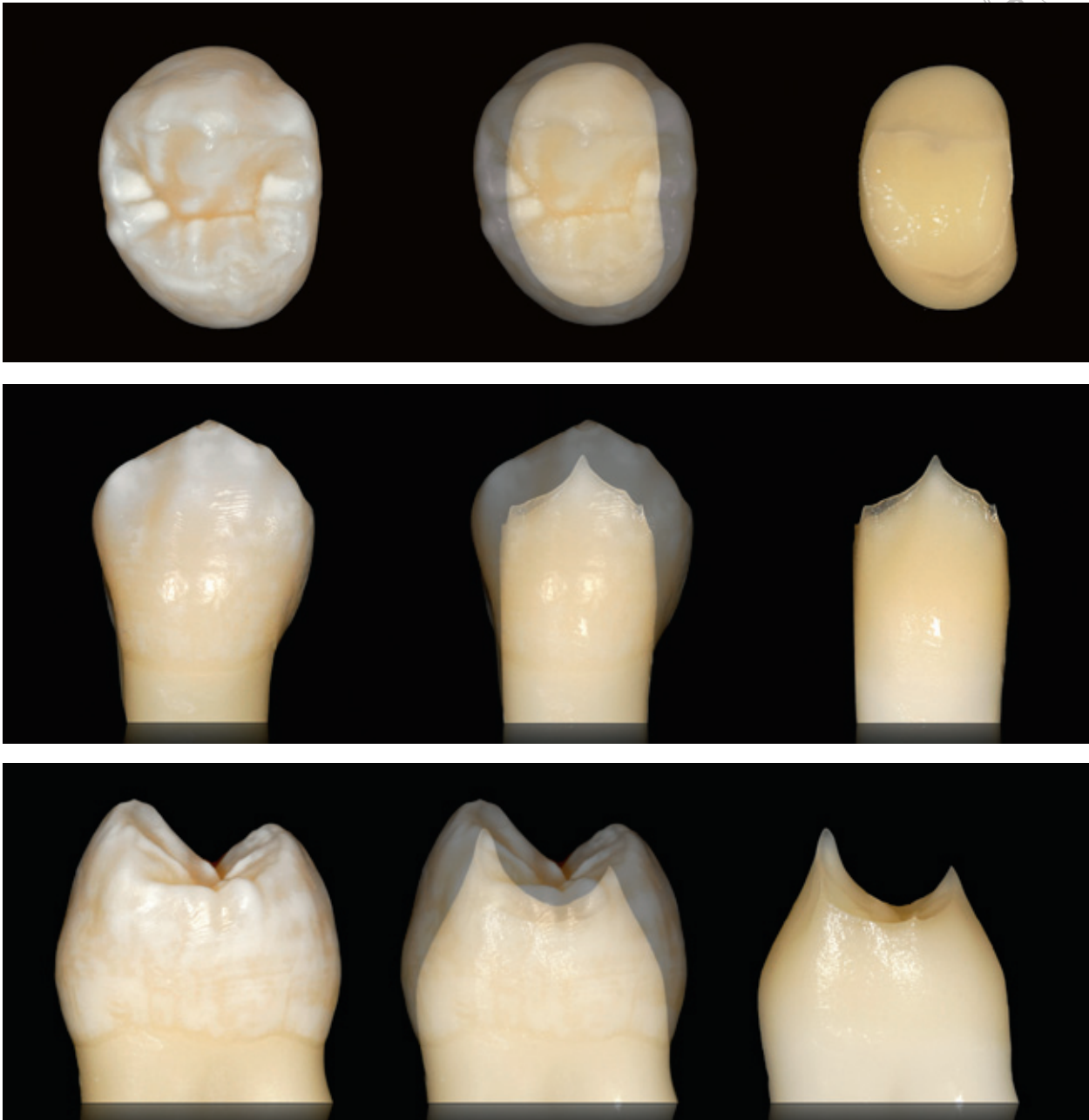


Fig 4 The coronal dentin surface can be considered a three-dimensional configuration of the DEJ.²⁰ When macroscopically observed, a high degree of conformity exists between the gross form of the DEJ and the overlying enamel surface,²¹⁻²³ the significant exception being the localized enamel thickness on the buccal and lingual middle thirds of the crown, forming a transitional sigmoid curve distribution.

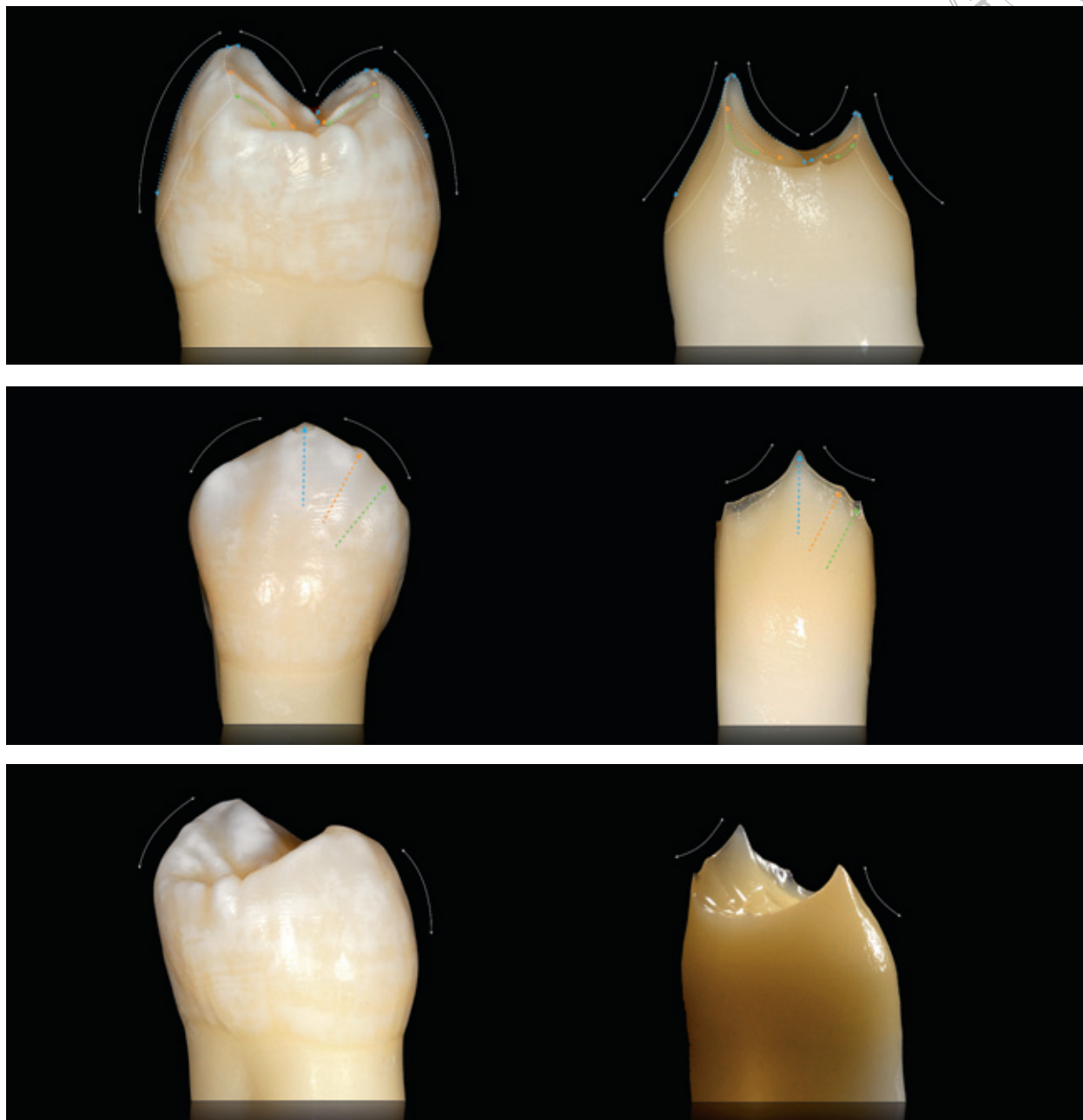


Fig 5 Convex contours of the enamel surface are evident when viewed from the proximal surface, providing a contrast to the sharp, concave relief of the dentin surface. Congruency of micro-expressions between enamel and dentin surface characteristics are depicted by the colored arrows. Maxillary first premolar depicted.



Not for Publication

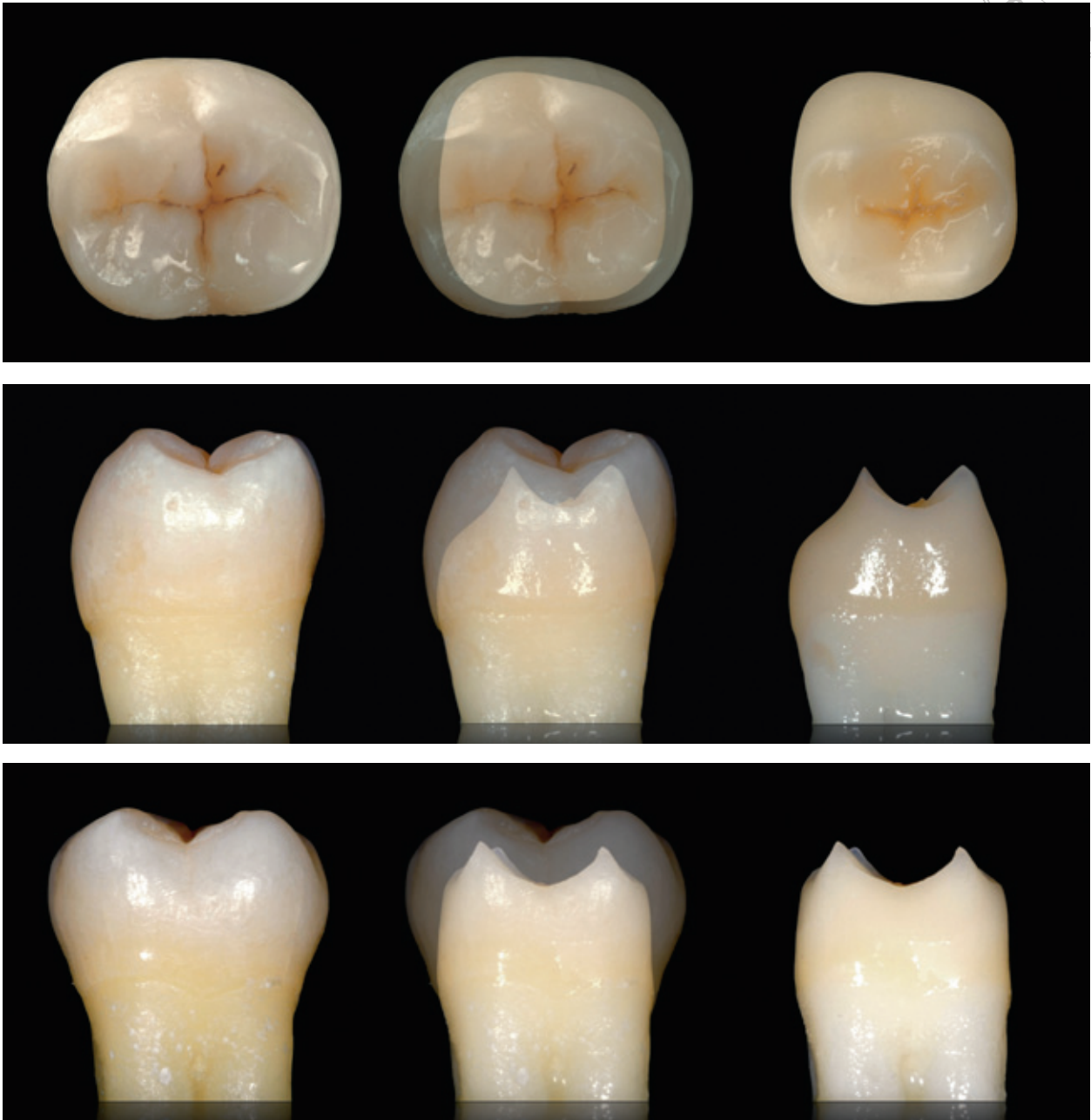


Fig 6 A pronounced dentin concavity is present on the buccal surface at the junction of the cervical and middle third of the posterior dentition, forming a sigmoid curve. This localized enamel overexpression may present a selective bio-mechanical reinforcement mechanism to the compressive loads experienced in the posterior dentition. Mandibular second molar depicted.

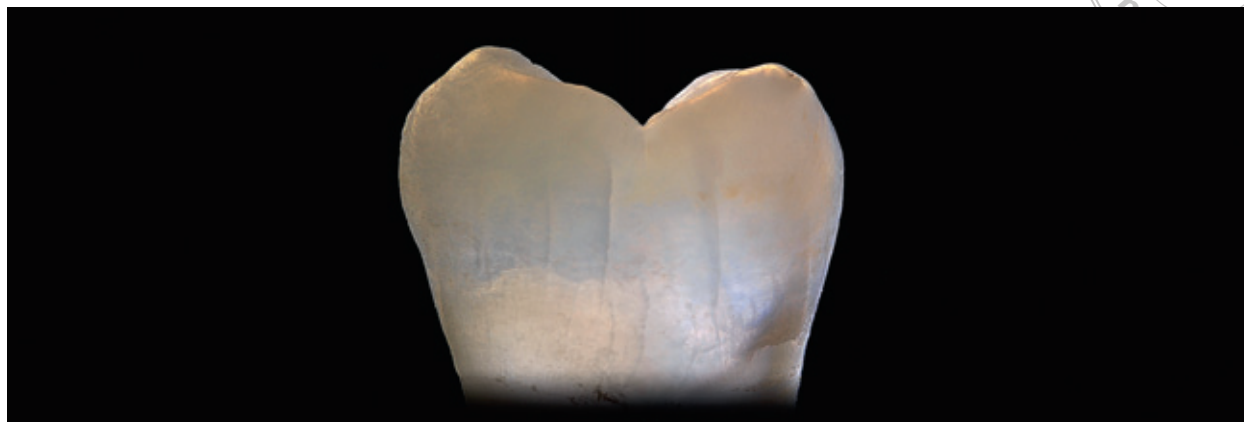


Fig 7 The above molar was extracted due to periodontal reasons. Upon trans-illumination, multiple crack extensions are observed, yet they are contained only within the enamel layer. Since the process is gradual, the cracks will be continuously replenished with protein rich oral fluids, thereby utilizing a self-healing mechanism.

tubule lumens with their associated cuffs of peritubular dentin forming the cylindrical fiber reinforcement. Dentin possesses both elastic and plastic material properties, which vary significantly from region to region. Uncracked-ligament bridging presents as the prevalent crack shielding mechanism observed in the hydrated dentin core.²⁵

Macrostructure: convex enamel vs concave dentin

Most topographic structures are related to the different functional roles of the enamel and dentin surfaces. The robust, rounded convex contours of the enamel surface provide strength to a tissue subjected to direct masticatory stresses and occlusal loads. In contrast, the sharp, concave relief of the dentin surface provides a stable support for the enamel shell (Figs 5 and 6).

From a bio-mechanical viewpoint, harmony between the ectodermal and mesodermal tissues was necessary for

the selective adaptation of teeth, with the DEC proving to be the most intricate of mechanisms, imparting the structural efficiency of an interconnecting network, where the various structural elements function in unison rather than remaining independent from each other. The DEC therefore is considered a functional shielding mechanism, that should be preserved whenever possible during clinical restorative procedures.

Bio-mechanical forces are thus allowed to transmit freely through the surfaces, dissipating throughout this structurally fluid medium. As a consequence, controlled crack extensions are frequently expected to form and progress steadily during a lifetime. This occurrence is validated in the intact teeth of older adults, particularly in trans-illuminated views (Fig 7).

Lacking awareness of this structurally advantageous non-uniform distribution of enamel/dentin gives rise to optical integration nuances. This frequently puzzles the restorative team due to the



fact that traditional dental morphology curriculums focus primarily on external enamel surface characteristics, oversimplifying the subsurface union with dentin, thus assuming uniform distribution. Hence the visual correlations between the enamel/dentin elements are deemed of significant value (Table 1). Stone replicas (Pearl White, GC Fuji Rock EP, Alsip, IL, USA) were made in order to better assess surface topography and characteristics (Fig 8).

Discussion

The purpose of this quest is to assist dental clinicians, technicians and students in these disciplines, using proper visualization and sound understanding of spatial ordering among the enamel and dentin structural elements. Once this is mastered, reconstruction of the dentition takes on proficient and predictable qualities.

With the fact that the design of the intact tooth is unrivaled on a micro-structural level, one must be inspired to endeavor towards macro-structural emulation with the current bio-materials available.

Armed with this knowledge of the Bio-Emulation model, commencing direct and indirect adhesive dental restorations takes on a refined and intuitive manner, rather than an over-simplified automated one. The refinement is not that of simplification, yet one that thrives on a thorough understanding of the innate structural complexity of the intact tooth; it relies on powerful yet efficient spatial ordering principles of the analogous dental structures.

Table 1 Visual observations of the posterior enamel/dentin surface correlations.

Morphologic features	Enamel surface	Dentin surface
Marginal ridges	Rounded	Sharp
Buccal cusp/s	Rounded	Sharp
Lingual cusp/s	Rounded	Sharp
Buccal surface	Convex	Concave ^{26,27}
Lingual surface	Convex	Concave
Occlusal fissures	Present	Absent

With the advent of adhesive dental technology, the restorative team is enabled to provide minimally invasive treatment, without being obligated to sacrifice additional tooth structure in an effort to establish traditional fundamental requirements of resistance and retention.

This knowledge may be universally applied as a foundation for developing novel stratification techniques when fabricating restorations in either composite resins or etchable ceramics, with either conventional (refractory die or thermo-pressed) or contemporary (CAD/CAM or 3D printing) methodologies.

Conclusion

This article presented essential histo-anatomic elements, such as the sigmoid curve distribution (convex enamel/concave dentin), the distinction between dentinoenamel “junction” and dentinoenamel “complex” and the structural significance of DEC preservation.

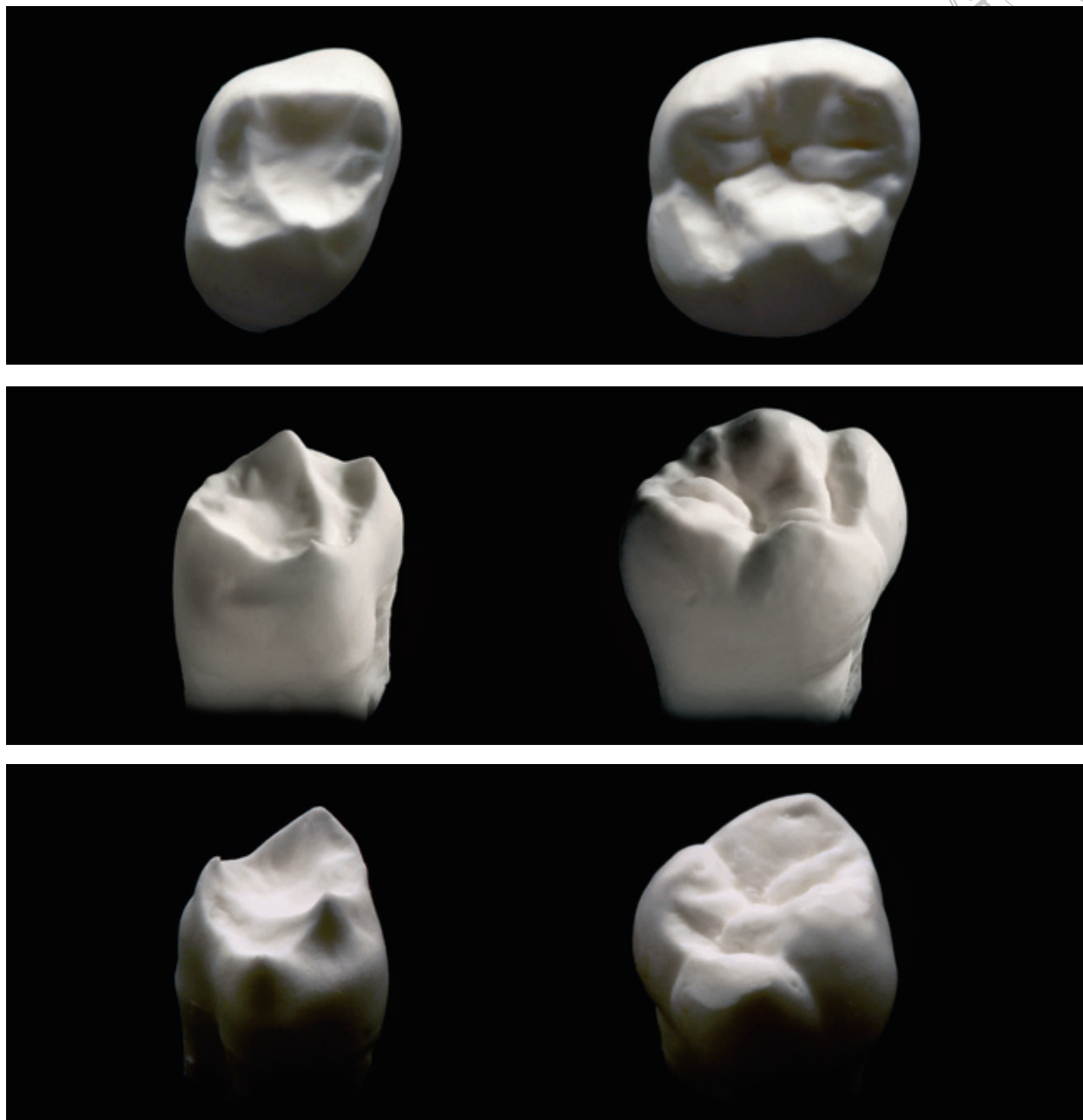



Fig 8 Stone replicas facilitate visual assessment and rumination of the variability between enamel and dentin surface topography. Thorn-like dentin tips are connected by sharp ridges, defining a constricted occlusal table when compared to that of the enamel counterpart. This cognitive paradigm shift may enable pathways towards improving current restorative stratification techniques and inspiring new bio-material innovations by structural and optical design. Maxillary first molar depicted.



Acknowledgement

One may only marvel at the wonders of our Creator. "I praise you, for I am fearfully and wonderfully made. Wonderful are your works; my soul knows it very well." Psalm 139:14

References

1. Nakabayashi N, Kojima K, Masuhara E. The promotion of adhesion by the infiltration of monomers into tooth substrates. *J Biomed Mater Res* 1982;16:265-273.
2. Nakabayashi N, Nakamura M, Yasuda N. Hybrid layer as a dentin-bonding mechanism. *J Esthet Dent* 1991;3:133-138.
3. Kanca J. A method for bonding to tooth structure using phosphoric acid as a dentin-enamel conditioner. *Quintessence Int* 1991;22:285-290.
4. Magne P. Immediate dentin sealing: a fundamental procedure for indirect bonded restorations. *J Esthet Restor Dent* 2005;17:144-54.
5. Magne P, Douglas WH. Rationalization of esthetic restorative dentistry based on biomimetics. *J Esthet Dent* 1999;11:5-15.
6. Vanini L, Mangani FM. Determination and communication of color using the five color dimensions of teeth. *Pract Proced Aesthet Dent* 2001;13:19-26.
7. Magne P, Holz J. Stratification of composite restorations: Systematic and durable replication of natural esthetics. *Pract Periodontics Aesthet Dent* 1996;8:61-68.
8. Dietschi D. Layering concepts in anterior composite restorations. *J Adhes Dent* 2001;3:71-80.
9. McLaren EA. The skeleton buildup technique: a systematic approach to the three-dimensional control of shade and shape. *Pract Periodontics Aesthet Dent* 1998;10:587-597.
10. Fahl N Jr. A polychromatic composite layering approach for solving a complex Class IV/direct veneer-diastema combination: part I. *Pract Proced Aesthet Dent* 2006;18:641-645; quiz 646.
11. Fahl N Jr. A polychromatic composite layering approach for solving a complex Class IV/direct veneer-diastema combination: part I. *Pract Proced Aesthet Dent* 2007;19:17-22.
12. Sieber C. *Voyage - Visions in Color and Form*. Chicago: Quintessence Publishing, 1994.
13. Winter R. Visualizing the natural dentition. *J Esthet Dent* 1993;5:102-117.
14. Kataoka S. *Nature's Morphology: An Atlas of Tooth Shape and Form*. Chicago: Quintessence Publishing, 2002.
15. Lin CP, Douglas WH, Erlandsen SL. Scanning electron microscopy of Type I collagen at the dentin enamel junction of human teeth. *J Histochem Cytochem* 1993;41:381-388.
16. Herr P, Holz J, Baume LJ. Mantle dentine in man - a quantitative microradiographic study. *J Biol Buccale* 1986;14:139-146.
17. Goldberg M, Septier D, Bourd K et al. The dentino-enamel junction revisited. *Connect Tissue Res* 2002;43:482-489.
18. Imbeni V, Kruzic JJ, Marshall GW, Marshall SJ, Ritchie RO. The dentin-enamel junction and the fracture of human teeth. *Nat Mater* 2005;4:229-232.
19. Weatherell, Composition of Dental Enamel. *Br Med Bull* 1975;31:115-119.
20. Staley R. Dentin Crown Surface of Human Adult Incisor Teeth. *J Dent Res* 1968;47:824-828.
21. Kraus B. Morphologic Relationships Between Enamel and Dentin Surfaces of Lower First Molar Teeth. *J Dent Res* 1952;31:248-256.
22. Sakai T. Morphologic Study of the Dentinoenamel Junction of the Mandibular First Premolar. *J Dent Res* 1967;46(Suppl 5):927-932.
23. Nager G. Der Vergleich zwischen des räumlichen Verhalten des Dentinkronenreliefs und dem Schmelzrelief der Zahnkrone. *Acta Anat* 1960;42:226-250.
24. Bajaj D, Arola D. Role of prism decussation on fatigue crack growth and fracture of human enamel. *Acta Biomater* 2009;5:3045-3056.
25. Kinney JH, Marshall SJ, Marshall GW. The mechanical properties of human dentin: a critical review and re-evaluation of the dental literature. *Crit Rev Oral Biol Med* 2003;14:13-29.
26. Re GJ, Pruitt D, Childers JM, Norling BK. Effect of Mandibular Molar Anatomy on the Buccal Class I Cavity Preparation. *J Dent Res* 1983;62:997-1001.
27. Bronner FJ. Engineering principles applied to Class II cavities. *J Dent Res* 1930;10:115-119.

Copyright of European Journal of Esthetic Dentistry is the property of Quintessence Publishing Company Inc. and its content may not be copied or emailed to multiple sites or posted to a listserv without the copyright holder's express written permission. However, users may print, download, or email articles for individual use.