

BRIEF REPORT

Lack of Cyclophilin B in Osteogenesis Imperfecta with Normal Collagen Folding

Aileen M. Barnes, M.S., Erin M. Carter, M.S., Wayne A. Cabral, B.A., MaryAnn Weis, B.S., Weizhong Chang, Ph.D., Elena Makareeva, Ph.D., Sergey Leikin, Ph.D., Charles N. Rotimi, Ph.D., David R. Eyre, Ph.D., Cathleen L. Raggio, M.D., and Joan C. Marini, M.D., Ph.D.

SUMMARY

Osteogenesis imperfecta is a heritable disorder that causes bone fragility. Mutations in type I collagen result in autosomal dominant osteogenesis imperfecta, whereas mutations in either of two components of the collagen prolyl 3-hydroxylation complex (cartilage-associated protein [CRTAP] and prolyl 3-hydroxylase 1 [P3H1]) cause autosomal recessive osteogenesis imperfecta with rhizomelia (shortening of proximal segments of upper and lower limbs) and delayed collagen folding. We identified two siblings who had recessive osteogenesis imperfecta without rhizomelia. They had a homozygous start-codon mutation in the peptidyl-prolyl isomerase B gene (*PPIB*), which results in a lack of cyclophilin B (CyPB), the third component of the complex. The proband's collagen had normal collagen folding and normal prolyl 3-hydroxylation, suggesting that CyPB is not the exclusive peptidyl-prolyl *cis-trans* isomerase that catalyzes the rate-limiting step in collagen folding, as is currently thought.

OSTEOPENESIS IMPERFECTA IS A BONE DYSPLASIA CHARACTERIZED BY REDUCED bone mass, bone fragility, and growth deficiency.¹ Affected persons may also have macrocephaly, blue sclerae, and dentinogenesis imperfecta. The updated Silience classification of osteogenesis imperfecta^{2,3} (described in Table 1 in the Supplementary Appendix, available with the full text of this article at NEJM.org) reflects the current concept that this is a type I collagen-related disorder.

Most cases of osteogenesis imperfecta are caused by autosomal dominant defects in the genes that encode type I collagen, *COL1A1* or *COL1A2*.⁴ Type I collagen is the most abundant protein in bone and skin extracellular matrix. It contains two alpha-1 ($\alpha 1(I)$) chains and one alpha-2 ($\alpha 2(I)$) chain, which fold into a triple helix from the carboxyl end to the amino end. These collagen chains contain glycine residues in every third position that are crucial for proper folding of the helix; substitutions for glycines delay helical folding and cause overmodification by increasing the length of time these chains are exposed to modifying enzymes in the endoplasmic reticulum.⁵ Prolyl 4-hydroxylase (P4H) and lysyl hydroxylase (LH) modify multiple proline and lysine residues, respectively, along the collagen helix, which are important for collagen stability and cross-linking.⁶ In contrast, the collagen prolyl 3-hydroxylation complex, consisting of P3H1 (also known as leucine- and proline-enriched proteoglycan 1 [LEPRE1]), CRTAP, and CyPB, modifies the $\alpha 1(I)$ Pro986 residue.^{7,8} Although the function of this modification remains unknown, a deficiency of either P3H1 or

From the National Institute of Child Health and Human Development (A.M.B., W.A.C., W.C., E.M., S.L., J.C.M.) and the National Human Genome Research Institute (C.N.R.) — both at the National Institutes of Health, Bethesda, MD; the Hospital for Special Surgery, New York (E.M.C., C.L.R.); and the Orthopaedic Research Laboratories, University of Washington, Seattle (M.W., D.R.E.). Address reprint requests to Dr. Marini at the Bone and Extracellular Matrix Branch, NICHD, National Institutes of Health, Bldg. 10, Rm. 10N260, 9000 Rockville Pike, Bethesda, MD 20892, or at oidoc@helix.nih.gov.

This article (10.1056/NEJMoa0907705) was published on January 20, 2010, at NEJM.org.

N Engl J Med 2010;362:521-8.

Copyright © 2010 Massachusetts Medical Society.

CRTAP causes severe or lethal autosomal recessive osteogenesis imperfecta, which accounts for 5 to 7% of all severe cases of osteogenesis imperfecta.³

Null mutations of *CRTAP* or *LEPRE1* cause severe osteogenesis imperfecta with rhizomelia,⁸⁻¹³ classified, respectively, as type VII (Online Mendelian Inheritance in Man [OMIM] number, 610682) and type VIII (OMIM number 610915). These mutations lead to a deficiency of these two components of the complex and a reduction in or absence of $\alpha 1(I)$ Pro986 hydroxylation. Unexpectedly, a lack of the complex causes collagen overmodification by P4H and LH. We hypothesized that the delay in helical folding is due to the unavailability of the complex to shuttle CyPB to the carboxyl end of the helix, rather than to the absence of the 3-hydroxylation modification itself. CyPB, a ubiquitous peptidyl-prolyl *cis-trans* isomerase (PPIase), is currently thought to catalyze the prolyl isomerization that is the rate-limiting step in collagen folding.^{14,15}

We describe here two siblings who had autosomal recessive osteogenesis imperfecta due to a homozygous mutation in the start codon of *PP1B*. The lack of CyPB results in moderate osteogenesis imperfecta without rhizomelia, associated with normal $\alpha 1(I)$ Pro986 hydroxylation and normal modification of the collagen helix. Our findings suggest that CyPB is not the unique rate-limiting PPIase for type I collagen folding in vivo.

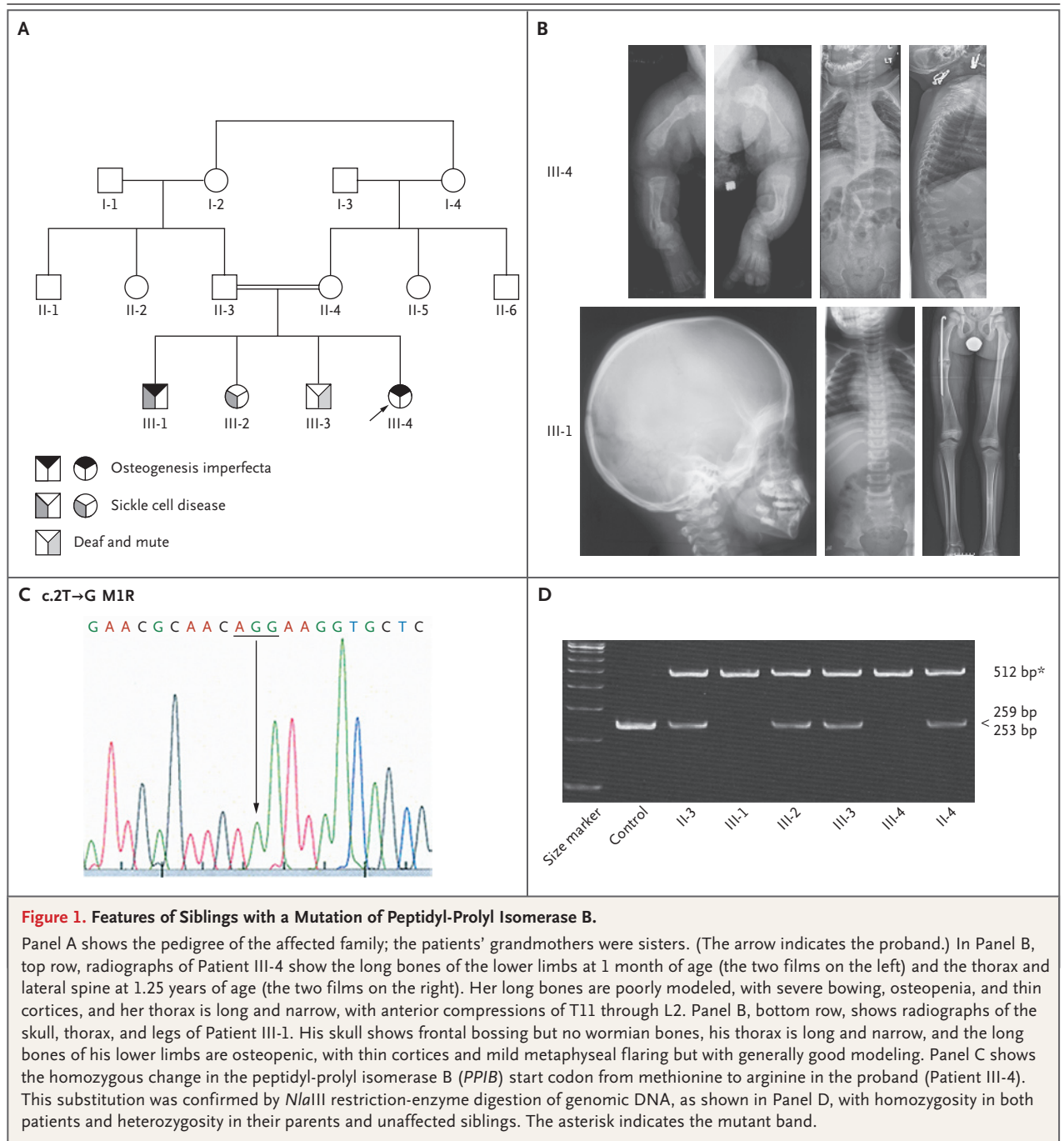
CASE REPORTS

The patients were siblings with moderately severe osteogenesis imperfecta who were born to consanguineous Senegalese parents residing in New York City (Fig. 1A). Both children had white sclerae and normal dentition. They did not have rhizomelia or severe deformity of the long bones, and their skin was normal in appearance and extensibility. Although they had moderate axial growth deficiency, their hand length and segmental proportions were appropriate for their age. Gross motor development was moderately delayed, owing to low muscle tone and weakness, but both children had attained ambulation. Results of hearing and vision tests, and echocardiographic assessment were normal. Their intellectual development was normal (see the Supplementary Appendix). No bone samples were obtained during orthopedic procedures.

The proband (Patient III-4) was a 4-year-old girl who was delivered at term by cesarean section ow-

ing to the breech position. She weighed 2720 g (6 lb) (10th percentile) at birth and had a wide anterior fontanelle; bilateral fractures of the humeri, radii, ulnae, femora, and tibiae were noted on radiographs. She was able to sit independently at the age of 2.75 years and was able to walk at the age of 3.5 years with the use of long leg braces and a walker. Postnatal fractures began to occur when she reached 6 months of age; she sustained six long-bone fractures and underwent four lower-extremity osteotomy procedures. Her growth curve fell below normal by the age of 6 months. At 28 months of age, her weight and length were both at the 50th percentile for a normal 9-month-old girl. She had generalized, moderate ligamentous laxity, triangular facies with a high-bossed forehead, and proptosis. An umbilical hernia was noted at the age of 5 months. She had bilateral pes planus. Skeletal radiographs obtained when she was a newborn revealed osteoporotic long bones, with undertubulation and bowing of the femora and tibiae (Fig. 1B, top row). By the age of 15 months, the vertebral bodies of T11 through L2 showed substantial anterior compression. At 33 months, long-bone undertubulation had improved but was still present in the femoral metaphyses. The z score for L1 to L4 on dual-energy x-ray absorptiometry (DXA) was -3.9 at the age of 3.5 years.

The proband's sibling (Patient III-1) was a 12-year-old boy who also had sickle cell disease, although he had had no sickle cell crises that required hospitalization. Despite this coexisting disease, his osteogenesis imperfecta was milder than that of the proband. He was the product of a term pregnancy and weighed 2268 g (5 lb) at birth (<5th percentile). His first fracture occurred at the age of 3 months, after which he had more than eight long-bone fractures of the lower extremities and underwent four osteotomy procedures. Spontaneous ambulation did not occur until 2 years of age. His growth was moderately delayed; at the age of 12.3 years, his height and weight were the same as those of an average 8-year-old. He had a head circumference of 49 cm at 11 years of age (25th percentile). He was hospitalized with pneumonia at age 11. The physical examination was notable for generalized, moderate ligamentous laxity, proptosis, a prominent sagittal suture, a flattened occiput, a narrow thorax, and bilateral pes planus. Skeletal radiographs showed generalized osteopenia but not rhizomelia (Fig. 1B, bot-



tom row). The long bones had thin cortices and normal diaphyseal modeling; the femoral metaphyses were mildly undertubulated. The vertebrae were not compressed (Fig. 1 in the Supplementary Appendix). When he was 11 years old, the z score on DXA of L1 to L4 was -1.3 .

METHODS

GENETIC ANALYSIS

We screened genomic DNA (gDNA) of dermal fibroblasts, leukocytes, or both from the proband and her affected brother, as well as gDNA from

their parents and unaffected siblings. Sequencing of complementary DNA and genomic DNA (gDNA) from the proband revealed no mutations in *COL1A1*, *COL1A2*, *CRTAP*, or *LEPRE1*.

The five exons and flanking intronic sequences of *PPIB* gDNA from the proband were sequenced, and the *PPIB* mutation was confirmed by restriction-enzyme digestion. This mutation was not found in DNA samples from 115 healthy West African subjects (230 chromosomes) or in multiple single-nucleotide-polymorphism (SNP) databases. The expression levels of *PPIB*, *CRTAP*, and *LEPRE1* in fibroblasts, which share a mesodermal origin with osteoblasts, were examined by means of a real-time reverse-transcriptase-polymerase-chain-reaction (RT-PCR) assay normalized to glyceraldehyde-3-phosphate dehydrogenase (*GAPDH*) messenger RNA expression (Assays-on-Demand, Applied Biosystems).

IN VITRO BIOCHEMICAL TESTS

The details of collagen biochemical assessments in dermal fibroblasts are provided in the Supplementary Appendix. Western blots of cell lysates were probed with antibodies to CyPB (Abcam), *CRTAP*, or P3H1 (Abnova) and were scanned on a LI-COR Odyssey machine. Amino acid chromatography and electrospray mass spectrometry were performed.⁹

IMMUNOFLUORESCENCE MICROSCOPY

Cells from the proband and a 5-year-old control subject were stained with antibodies to CyPB, P3H1, *CRTAP*, glucose-regulated protein 94 (GRP94) (Abcam), or protein disulfide isomerase (PDI) (Stressgen). Secondary antibodies conjugated to fluorophores of different wavelengths were used to examine protein colocalization by means of confocal microscopy.

RESULTS

IDENTIFICATION OF THE *PPIB* MUTATION

The proband and her affected sibling were homozygous for a c.2T→G mutation in *PPIB* (Fig. 1C). Homozygosity for the mutation in affected children and heterozygosity in parents and unaffected siblings were confirmed by the elimination of an *Nla*III restriction site (Fig. 1D). This mutation results in substitution of an arginine for the methionine start codon (Met1),¹⁶ and this alteration is expected to eliminate the initiation of translation.

PPIB EXPRESSION AND *PPIB* IN FIBROBLASTS

PPIB transcripts in the proband were about 55% of the normal level on the basis of real-time RT-PCR assay (Table 1) and were unaffected by the use of emetine to inhibit nonsense-mediated decay.

CyPB protein was undetectable in the proband fibroblast lysate (Fig. 2A) and concentrated media (data not shown) on Western blotting with the use of three different antibodies; no CyPB staining was present on immunofluorescence (Fig. 2B). *PPIB* transcript levels were normal, and CyPB protein levels were moderately reduced in fibroblasts obtained from the proband's father (Fig. 2A and Table 1).

EFFECT OF LACK OF CYPB ON THE PROLYL 3-HYDROXYLASE COMPLEX AND COLLAGEN FOLDING

In cells that were homozygous and those that were heterozygous for the *PPIB* mutation, *CRTAP* and *LEPRE1* transcript levels were moderately elevated as compared with levels in the control cells (Table 1). Interestingly, Western blotting showed that *CRTAP* and P3H1 protein levels in the proband were about half the normal levels (Fig. 2A); these decreases were confirmed on immunofluorescence microscopy (Fig. 2C and 2D and Table 1). The proband's father had normal levels of *CRTAP* and P3H1 proteins.

The homozygous *PPIB* mutation did not affect type I collagen modification and folding. Tandem mass spectrometry revealed normal 3-hydroxylation of 98% of $\alpha 1(I)$ Pro986 residues (Table 1, and Fig. 2A in the Supplementary Appendix). Furthermore, collagen helical modification appeared to be normal in homozygous mutant cells, since tandem mass spectrometry showed that prolyl 4-hydroxylation and lysyl hydroxylation of specific tryptic peptides from $\alpha 1(I)$ and $\alpha 2(I)$ chains was in the normal range, and amino acid chromatography yielded normal proportions of hydroxylated lysine residues (Table 1). Gel electrophoresis of collagen from the proband showed near-normal width and baseline of the alpha-chain bands (Fig. 2E), and collagen thermal stability was normal (Fig. 2B in the Supplementary Appendix).

DISCUSSION

We identified two siblings with moderately severe, autosomal recessive osteogenesis imperfecta caused by a homozygous start-codon mutation in *PPIB*, the gene that encodes CyPB.¹⁶ Osteogenesis imperfecta

Table 1. Effect of the *PPIB* Mutation on Components of the 3-Hydroxylation Complex and Collagen Modification.*

Variable	Proband	Father	Control
mRNA expression†			
<i>PPIB</i>	0.56±0.10	1.04±0.08	—
<i>CRTAP</i>	1.44±0.19	1.42±0.22	—
<i>LEPRE1</i>	1.82±0.21	1.80±0.34	—
Protein‡			
CyPB	<0.01	0.61±0.25	—
<i>CRTAP</i>	0.63±0.12	1.13±0.21	—
<i>P3H1</i>	0.34±0.10	1.29±0.11	—
Hydroxylation (%)			
Lysine residues in type I collagen modified by LH§	19.7	—	17.7–22.0
α1(I)Pro986 residues with 3-hydroxylation¶	98	—	94–97

* Plus-minus values are means ±SD. *CRTAP* denotes cartilage-associated protein, CyPB cyclophilin B, *LEPRE1* leucine- and proline-enriched proteoglycan 1, LH lysyl hydroxylase, mRNA messenger RNA, *P3H1* prolyl 3-hydroxylase 1, and *PPIB* the gene encoding peptidyl-prolyl isomerase B.

† The relative expression of each mRNA was normalized to glyceraldehyde-3-phosphate dehydrogenase expression and then compared with the relative mRNA expression of a control fibroblast cell line (which was arbitrarily set to 1). These tests were performed in triplicate on three separate samples.

‡ The level of each protein was normalized to actin levels and then compared with normalized protein levels from a control fibroblast cell line (which was arbitrarily set to 1). This test was performed on three samples.

§ The percentage of hydroxylated lysine residues of type I collagen was determined by high-performance liquid chromatography.

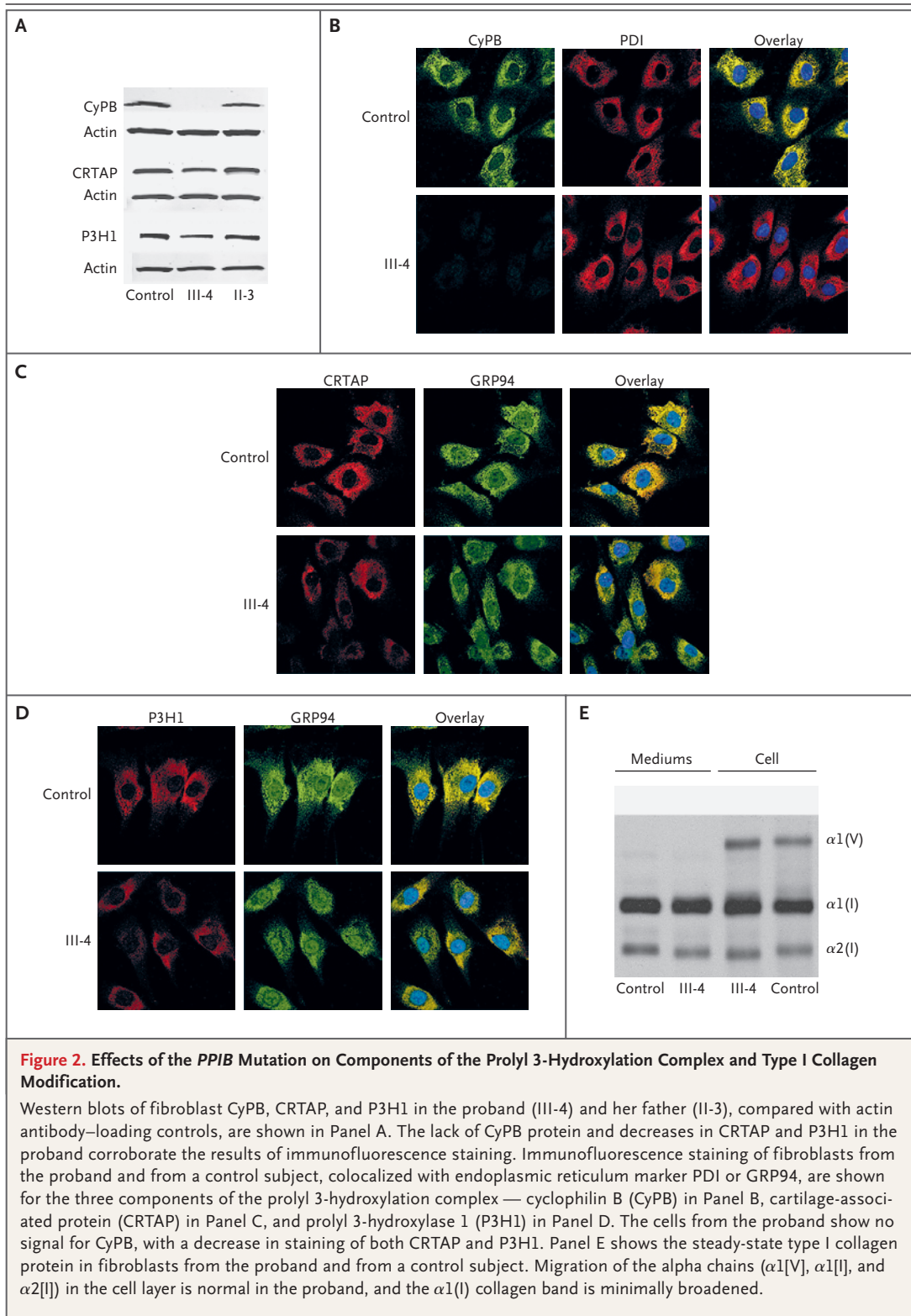
¶ The percentage of α1(I)Pro986 that underwent 3-hydroxylation was determined by mass spectrometry of tryptic peptides.

caused by the absence of CyPB is much milder than the severe or lethal osteogenesis imperfecta caused by a deficiency of *P3H1* or *CRTAP*,⁸⁻¹³ although all three of these proteins comprise the prolyl 3-hydroxylation complex in the endoplasmic reticulum.^{7,8} Unexpectedly, type I collagen folding is not delayed by the absence of CyPB, as it is with *P3H1* or *CRTAP* deficiency.⁸⁻¹⁰ This finding provides an important insight into collagen peptidyl-prolyl isomerization in vivo.

The two siblings had a novel *PPIB* mutation. A missense *PPIB* mutation (Gly31Arg) has been reported in horses in association with a degenerative skin disease¹⁷; the equine skeletal phenotype and collagen biochemical features were not reported. The patients described here had normal results on skin examination. Patients who lack CyPB, a condition that we propose to designate as type IX osteogenesis imperfecta, have low bone mass and multiple long-bone fractures, requiring osteotomy and placement of intramedullary rods, but attain ambulation. A lack of CyPB does not cause the rhizomelia or extreme growth delay that is found when *P3H1* or *CRTAP* is absent, nor

does it result in the abnormalities of the growth plate^{11,18} that are seen in cases of severe autosomal dominant or recessive osteogenesis imperfecta. The osteoporosis in type IX osteogenesis imperfecta is much less severe than that in types VII and VIII (DXA z scores of -1.3 and -3.9 in type IX vs. average DXA z scores of -6 to -7 in types VII and VIII), although extremely short stature in types VII and VIII also contributes to a very low z score on DXA. Both siblings had white sclerae and normal dentition, which are also found in patients with *P3H1* or *CRTAP* deficiency. Their hand length was proportionate for their age, as is seen in *P3H1* deficiency,¹⁰ but without the metacarpal shortening. The differences in the severity of skeletal dysplasia and relative stature between our two patients may in part reflect homozygosity for other genes due to parental consanguinity.

The distinctions between the phenotype of CyPB absence and the phenotype of *P3H1* or *CRTAP* deficiency correlate with two important biochemical differences in type I collagen. In the absence of *P3H1* or *CRTAP*, α1(I)Pro986 3-hydroxylation is decreased and collagen folding is delayed,



resulting in overmodification of the helical lysine and proline residues.³ In contrast, the lack of CyPB is associated with normal levels of $\alpha 1(I)$ Pro986 3-hydroxylation and helical proline 4-hydroxylation and lysine hydroxylation.

The cyclophilins are a family of ubiquitous intracellular proteins that differ in their subcellular location and their binding affinity for the immunosuppressive drug cyclosporine.¹⁹ All isoforms possess peptidyl-prolyl *cis-trans* isomerase activity, converting the *cis* conformation of prolines to the *trans* conformation necessary for proper folding. *Cis-trans* isomerization is the rate-limiting step in the folding of the collagen helix, which contains approximately 20% proline residues. CyPB, the cyclophilin that resides in the endoplasmic reticulum,¹⁶ has been shown to isomerize prolyl bonds for type III collagen *in vitro*.²⁰ Chick fibroblasts treated with cyclosporine exhibit delayed collagen folding with excess hydroxylation of helical proline and lysine residues¹⁵; this finding suggests, but does not prove, that CyPB is the major isomerase for collagen folding, since cyclosporine inhibits multiple proteins.

We hypothesized that one role of the prolyl 3-hydroxylation complex may be to position CyPB at the carboxyl end of the collagen helix, where folding is initiated. Recently, the complex has been shown *in vitro* to have both chaperone and PPIase activity; the PPIase activity is almost entirely due to CyPB and can be inhibited by cyclosporine.²¹ The mutation in our patients resulted in a lack of CyPB and a partial secondary reduction in the P3H1-CRTAP complex. However, sufficient complex remained for the normal 3-hydroxylation of $\alpha 1(I)$ Pro986 residues. In this situation, the normal folding of type I collagen strongly suggests that

CyPB is not the major type I collagen-folding isomerase or that redundancy exists for this function. The milder skeletal phenotype of our patients as compared with patients who have type VII or VIII osteogenesis imperfecta, may reflect the presence of Pro986 hydroxylation and proper collagen folding, as well as partial availability of P3H1 and CRTAP for their matrix functions. The loss of other functions of CyPB, including collagen transport in the intracellular secretory pathway,²² might also contribute to the phenotype.

These unexpected data open fundamental questions concerning the function of the 3-hydroxylation modification, the role of CyPB in the complex, and the identity of the major collagen isomerase. It is tempting to speculate that FKBP65, another PPIase that resides in the endoplasmic reticulum and binds to collagen,²³ may be the major isomerase or that FKBP65 and CyPB have redundant functions. FKBP65 is partially inhibited by both cyclosporine and FK506, both of which delay collagen folding.^{24,25} To date, all probands with normal type I collagen folding have an intact P3H1-CRTAP complex and normal $\alpha 1(I)$ Pro986 hydroxylation. Perhaps 3-hydroxylation triggers a conformational change of the collagen substrate or 3-hydroxylation complex that facilitates binding of FKBP65.

Supported by intramural funding from the National Institute of Child Health and Human Development (to Drs. Marini and Leikin) and the National Human Genome Research Institute Center for Research on Genomics and Global Health (to Dr. Rotimi) and by grants (AR37318, AR36794, and HD22657, to Dr. Eyre; and DK-54001, to Dr. Rotimi) from the National Institutes of Health.

No potential conflict of interest relevant to this article was reported.

We thank the family members for their participation in the study and Dr. Adebowale Adeyemo for his help in facilitating the screening of racially matched controls.

REFERENCES

1. Marini JC. Osteogenesis imperfecta. In: Behrman RE, Kliegman RM, Jensen HB, eds. *Nelson textbook of pediatrics*. 17th ed. Philadelphia: W.B. Saunders, 2004: 2336-8.
2. Silience DO, Senn A, Danks DM. Genetic heterogeneity in osteogenesis imperfecta. *J Med Genet* 1979;16:101-16.
3. Marini JC, Cabral WA, Barnes AM, Chang W. Components of the collagen prolyl 3-hydroxylation complex are crucial for normal bone development. *Cell Cycle* 2007;6:1675-81.
4. Marini JC, Forlino A, Cabral WA, et al. Consortium for osteogenesis imperfecta mutations in the helical domain of type I collagen: regions rich in lethal mutations align with collagen binding sites for integrins and proteoglycans. *Hum Mutat* 2007; 28:209-21.
5. Raghunath M, Bruckner P, Steinmann B. Delayed triple helix formation of mutant collagen from patients with osteogenesis imperfecta. *J Mol Biol* 1994;236:940-9.
6. Myllyharju J, Kivirikko KI. Collagens, modifying enzymes and their mutations in humans, flies and worms. *Trends Genet* 2004;20:33-43.
7. Vranka JA, Sakai LY, Bächinger HP. Prolyl 3-hydroxylase 1, enzyme characterization and identification of a novel family of enzymes. *J Biol Chem* 2004;279:23615-21.
8. Morello R, Bertin TK, Chen Y, et al. CRTAP is required for prolyl 3-hydroxylation and mutations cause recessive osteogenesis imperfecta. *Cell* 2006;127:291-304.
9. Barnes AM, Chang W, Morello R, et al. Deficiency of cartilage-associated pro-

- tein in recessive lethal osteogenesis imperfecta. *N Engl J Med* 2006;355:2757-64.
10. Cabral WA, Chang W, Barnes AM, et al. Prolyl 3-hydroxylase 1 deficiency causes a recessive metabolic bone disorder resembling lethal/severe osteogenesis imperfecta. *Nat Genet* 2007;39:359-65. [Erratum, *Nat Genet* 2008;40:927.]
 11. Baldrige D, Schwarze U, Morello R, et al. CRTAP and LEPRE1 mutations in recessive osteogenesis imperfecta. *Hum Mutat* 2008;29:1435-42.
 12. Willaert A, Malfait F, Symoens S, et al. Recessive osteogenesis imperfecta caused by LEPRE1 mutations: clinical documentation and identification of the splice form responsible for prolyl 3-hydroxylation. *J Med Genet* 2009;46:233-41.
 13. Van Dijk FS, Nesbitt IM, Nikkels PG, et al. CRTAP mutations in lethal and severe osteogenesis imperfecta: the importance of combining biochemical and molecular genetic analysis. *Eur J Hum Genet* 2009;17:1560-9.
 14. Bächinger HP, Bruckner P, Timpl R, Prockop DJ, Engel J. Folding mechanism of the triple helix in type-III collagen and type-III pN-collagen: role of disulfide bridges and peptide bond isomerization. *Eur J Biochem* 1980;106:619-32.
 15. Steinmann B, Bruckner P, Superti-Furga A. Cyclosporin A slows collagen triple-helix formation in vivo: indirect evidence for a physiologic role of peptidyl-prolyl cis-trans-isomerase. *J Biol Chem* 1991;266:1299-303.
 16. Price ER, Zydowsky LD, Jin MJ, Baker CH, McKeon FD, Walsh CT. Human cyclophilin B: a second cyclophilin gene encodes a peptidyl-prolyl isomerase with a signal sequence. *Proc Natl Acad Sci U S A* 1991;88:1903-7.
 17. Tryon RC, White SD, Bannasch DL. Homozygosity mapping approach identifies a missense mutation in equine cyclophilin B (PPIB) associated with HERDA in the American Quarter Horse. *Genomics* 2007;90:93-102.
 18. Obafemi AA, Bulas DI, Troendle J, Marini JC. Popcorn calcification in osteogenesis imperfecta: incidence, progression, and molecular correlation. *Am J Med Genet A* 2008;146A:2725-32.
 19. Wang P, Heitman J. The cyclophilins. *Genome Biol* 2005;6:226.
 20. Bächinger HP. The influence of peptidyl-prolyl cis-trans isomerase on the in vitro folding of type III collagen. *J Biol Chem* 1987;262:17144-8.
 21. Ishikawa Y, Wirz J, Vranka JA, Nagata K, Bächinger HP. Biochemical characterization of the prolyl 3-hydroxylase 1.cartilage-associated protein.cyclophilin B complex. *J Biol Chem* 2009;284:17641-7.
 22. Smith T, Ferreira LR, Hebert C, Norris K, Sauk JJ. Hsp47 and cyclophilin B traverse the endoplasmic reticulum with procollagen into pre-Golgi intermediate vesicles: a role for Hsp47 and cyclophilin B in the export of procollagen from the endoplasmic reticulum. *J Biol Chem* 1995;270:18323-8.
 23. Ishikawa Y, Vranka J, Wirz J, Nagata K, Bächinger HP. The rough endoplasmic reticulum-resident FK506-binding protein FKBP65 is a molecular chaperone that interacts with collagens. *J Biol Chem* 2008;283:31584-90.
 24. Bächinger HP, Morris NP, Davis JM. Thermal stability and folding of the collagen triple helix and the effects of mutations in osteogenesis imperfecta on the triple helix of type I collagen. *Am J Med Genet* 1993;45:152-62.
 25. Zeng B, MacDonald JR, Bann JG, et al. Chicken FK506-binding protein, FKBP65, a member of the FKBP family of peptidyl-prolyl cis-trans isomerases, is only partially inhibited by FK506. *Biochem J* 1998;330:109-14.

Copyright © 2010 Massachusetts Medical Society.