cases treated by diathermy coagulation, of which 11 showed satisfactory results.

More recently, Weve, using a uni-polar electrode and a current of only a few milliamperes, has been localizing the hole in relation to a micro-puncture by immediate ophthalmoscopy.

Safar has been working on much the same lines as Weve and has introduced a variety of different electrodes with one or many needle points, 2 mm. long. He also uses his minute 'nails' which he implants in the selected area of the sclero-choroid by holding them in an insulated forceps and pressing them against the sclera with the terminal of the active electrode. A series of these 'nails' are arranged in a circle around the hole, or in the form of a semi-circle if the tear is at the ora. The 'nails' should be about 3 mm. apart and should be left in position until the requisite number of punctures has been made. In cases in which a tear or hole cannot be found a retinal detachment can often be cured by applying diathermy punctures in that part of the retina in which the detachment commenced. The 'nails' are removed together and the sub-retinal fluid allowed to drain away. It is important to see that this fluid has escaped so that apposition of the retina and choroid takes place, resulting in adhesion of these two layers and closure of the hole. To cure a retinal detachment Safar like many others considers it is necessary to produce an inflammation in the choroid in the region of the retinal tear but the injury to the retina and choroid should be as little as possible. This is best accomplished by diathermy puncture, as it produces minute scars such as are seen in mild choroiditis.

Up to 1932 Safar has reported 39 unselected cases treated by diathermal micro-puncture and has had 24 successful results.

At present it would appear that electro-coagulation by diathermy will be the method of choice in the future for the treatment of retinal detachment for the reason that its application can be modified and its dosage graduated. Whatever line of treatment is adopted it should always be remembered that the three important factors are—irritation to produce an adhesive choroiditis, evacuation of the sub-retinal fluid, and rapid reattachment of the retina to the choroid.

Careful preliminary examination of each case, localization of the hole or tear, and strict attention to detail at the time of operation and the after treatment are necessary if the best results are to be obtained. At the same time I would like to emphasize the fact that however carefully the measurements to localize the hole are made they are bound to be inaccurate; and also it is possible to be either too conservative in treatment or actually to do too much. Both result in partial improvement or no unimprovement, the

(*Continued at foot of next column*)

PRIMARY CARCINOMA OF THE GALL-BLADDER

By VISHWA NATH, M.A., M.D., F.R.C.P.I. D.P.H., D.T.M. & H.

Department of Pathology, King Edward Medical College, Lahore

A. S., a Sikh, aged 48 years, was admitted to the Mayo Hospital, Lahore, on the 20th of July 1932, suffering from ascites, œdema of the lower extremities and jaundice. He complained of pain in the right hypochondrium which was also tender to palpation. The duration of the disease was stated to be six months, during which time the patient had gradually but progressively grown worse. The total white blood cell count was 13,000 per c.mm. of which 85 per cent were polymorphonuclear leucocytes. Blood films showed no parasites. Fever and cholæmic symptoms were present and the latter increased rapidly. The patient died on the 24th of July—4 days after admission to hospital. Throughout his stay in hospital he suffered from retention of urine which had to be relieved by catheter.

The clinical diagnosis was malignant disease of the liver.

At autopsy I found a tall emaciated Sikh, intensely icteric, presenting the appearance of 'black jaundice'. The abdomen was greatly distended with fluid and the lower extremities and scrotum tense with œdema. No enlargement of supra-clavicular lymphatic glands was found.

No naked-eye abnormality was detected in the lungs or tracheo-bronchial and mediastinal glands. The heart presented no abnormality except for two 'milk spots' on its anterior surface.

The peritoneal cavity contained 8 pints of intensely bile-stained fluid. The peritoneum, both visceral and parietal, was found to be free from localized or diffuse thickening.

The liver was not enlarged; it was soft, almost diffluent, and of deep-green colour. Its surface was slightly wrinkled; but no surface abnormality indicative either of cirrhosis or a new growth was seen.

The gall-bladder was felt to be hard; this was due to marked thickening of its wall. It was difficult to separate it properly, its neck, the cystic and common bile ducts and the head of the pancreas being all parts of a hard mass, so the stomach was ligatured off and separated at the pyloric end, and the duodenum similarly separated off the jejunum at its distal end.

(*Continued from previous column*)

former from the production of irritation insufficient to cause an adhesive choroiditis, the latter from too much inflammatory exudate poured out between the retina and the choroid.

The liver, the gall-bladder, the pancreas and the duodenum were then removed together.

The cut surface of the liver was deep green to greenish brown in colour and showed no cirrhotic or neoplastic change. The gall-bladder was somewhat adherent to the fossa where it is lodged on the liver, but there was no grossly observable neoplastic change in the contiguous hepatic substance.

The gall-bladder was then opened. It contained only a small amount of thick viscid greenish bile. No gall-stones were found. Its fundus was found to be the seat of an infiltrative growth which projected noticeably into the viscus on a sessile base (figure 1). It showed no strict delimitation but faded away into the much-thickened wall of the viscus. The growth diminished in hardness as you approached towards the neck, where it was soft and friable, and extended into and almost obliterated the cystic duct. The common bile duct could not be dissected out. It was imbedded in a hard mass into which were fused the lymph glands of the porta hepatis and also the head of the pancreas. The duodenum was firmly adherent to the mass, but its lumen was free from any nodule or ulceration indicative of mucosal involvement.

Fig. 1.—A. Portion of liver. Green and wrinkled. B. Thickened gall-bladder showing growth in the fundus. C. Duodenal mucosa covering the tumour mass involving the head of the pancreas. D. Portion of tumour mass.

There was no evidence of malignant disease of the peritoneum and no marked enlargement of mesenteric lymph glands. The ascites was evidently due to pressure of the growth on the portal vein and not to malignant peritonitis. The stomach and the intestines showed no abnormality and the examination of the spleen, genito-urinary and nervous systems also gave negative result. Careful naked-eye examination of different viscera failed to show any secondary deposits.

Histological examination showed nothing of pathological interest, except in the liver and the parts involved in the new growth.

Section of the liver showed dilated bile ducts and a relative increase of pericholangeitic connective tissue. Small areas of necrosis of liver parenchyma were also in evidence.

Sections were taken from different parts of the new growth in the gall-bladder, and from the mass involving the head of the pancreas and the cystic and sub-pyloric glands. Sections from the growth in the fundus show it to be a squamous-celled carcinoma, exhibiting typical flat squamous cells (figure 2) and sections from the mass involving the head of the pancreas show a typical scirrhus carcinoma with considerable fibrosis and islands of spheroidal cells.

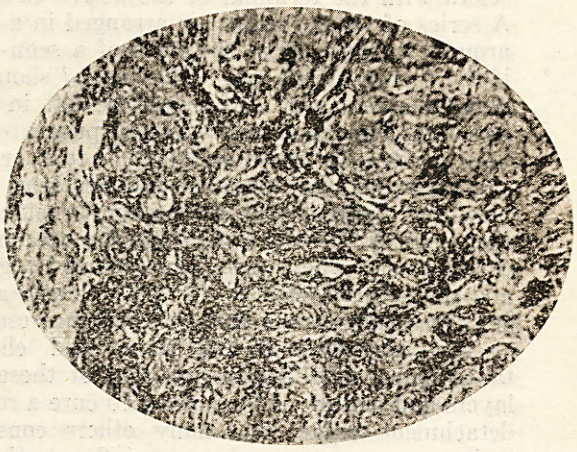

Fig. 2.—Photomicrograph from a section taken from the growth in the fundus, showing squamous cell metaplasia.

A large hyperchromatic cell is seen near the centre (figure 3).

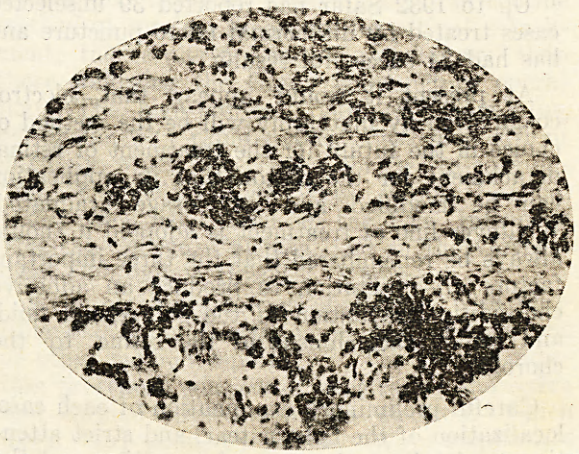

Fig. 3.—Photomicrograph showing masses of spheroidal cells enclosed by mature fibrous tissue.

Evidently this new growth had its origin in the fundus of the gall-bladder and extended therefrom to the common bile duct and the head of the pancreas. Although the pancreas is more commonly the seat of primary carcinoma and secondary growths in it are rare, primary carcinoma of the head of the pancreas leads, according to Courvoisier's law, to a much dilated and

thin-walled gall-bladder, which was not a feature of this case. Metastases very commonly occur from a pancreatic carcinoma in the liver and the peritoneum; there were no metastases in this case. I have also been unable to find mention of any case in the available literature where a primary carcinoma of the head of the pancreas had extended to the gall-bladder and showed squamous metaplasia in that situation.

On the other hand squamous metaplasia in primary carcinoma of the gall-bladder, though not of common occurrence, is met with not infrequently and the same may be said of secondary involvement of the pancreas in primary carcinoma of the gall-bladder. In the gall-bladder too, like the pancreas, it is primary carcinoma which is the commonest growth and the fundus its commonest site. Ewing (1928), quoting Musser, gives an analysis of one hundred cases of primary carcinoma of the gall-bladder in which the liver was found involved in 54, abdominal lymphatic glands in 16, lungs or pleura in 10 and pancreas and adrenals occasionally.

Besides these two uncommon features, squamous metaplasia and involvement of the pancreas, the case under discussion also showed no metastases in the liver and no gall-stones. This last feature deserves special consideration. The association of gall-stones with cancer of the gall-bladder is considered to be very intimate. It is regarded as an important illustration of the rôle of chronic irritation in the production of cancer. Graham (1931) says cancer of the gall-bladder is not a rare disease but forms 8 to 10 per cent of all carcinomata and, on the basis of the gall-stones gall-bladder-cancer relationship, recommends early removal of the viscus in all cases of cholelithiasis. Leitch (1924) states that over 10 per cent of adults have gall-stones and that 5 per cent of these develop cancer of gall-bladder. He asserts that gall-stones are present in practically all cases of cancer of the gall-bladder. Ewing (1928) quotes Musser as saying that gall-stones are found in 69 per cent of cases who have cancer of gall-bladder, and Janowski puts it at 100 per cent. Watts (1922) in the study of a series of 525 operations on the gall-bladder found primary carcinoma in 20, *i.e.*, 3.8 per cent, and of these 20 cases gall-stones were found only in 10.

Osler and McCrae (1926–28) state that in the Massachussets General Hospital, Boston, U.S.A., of 2,631 operations performed on the gall-bladder during 30 years, 63, *i.e.*, 2.4 per cent, showed primary carcinoma of the gall-bladder and in these latter only 36 per cent showed gall-stones.

In the Mayo Hospital, Lahore, of a series of 129 operations done on the gall-bladder, 92 showed gall-stones and 11 were found to have carcinoma, but in the latter number presence of gall-stones was recorded only in 2. Of these

(*Continued at foot of next column*)

NEPHROLITHIASIS OF THE HORSE-SHOE KIDNEY

By P. N. RAY, B.A., M.B. (Cal.), F.R.C.S. (Eng.)
Hony. Junior Visiting Surgeon, Calcutta Medical College Hospitals

By the term horse-shoe kidney is meant the fusion of the kidneys across the vertebral column. The band of union, or the isthmus, passes commonly between the lower and rarely between the upper poles across the abdominal aorta and the inferior vena cava. The isthmus varies from a band of fibrous tissue to a definite bridge of renal parenchyma. According to statistics compiled from the post-mortem room, the incidence of the horse-shoe kidney varies from 1 in 1,590 to 1 in 500 cases (0.06 per cent

(*Continued from previous column*)

11 cases 7 showed metastases in the liver and one showed extention to the stomach. In addition there was one case of malignant disease of the common bile duct.

Seven out of the above 12 cases of cancer were females and 5 were males. The average age incidence was 39.7 years, the limits being 30 and 55 years.

Of the 92 cases of cholelithiasis 29 were Europeans and 63 were Indians. The average age of patients in the former group was 40 years and in the latter 32.6 years. In the former group there were 22 females to 7 males, and in the latter 48 to 15.

In the Indian group, 41 cases were amongst Hindus—30 females and 11 males, 19 amongst Mohammedens—16 females and 4 males, and two amongst females of other communities. In spite of their lower numerical strength in the population the higher incidence of cholelithiasis amongst Hindus may be related to their fat-rich dietary.

It has been suggested that in cases of carcinoma of gall-bladder where no gall-stones are found the stones may have passed out, or that metabolic and infective factors causing mural irritation in that viscus may even in the absence of gall-stones lead to cancer. Squamous metaplasia probably indicates a more persistent operation of the irritant than that which obtains in forms of carcinomata representing cellular structure more closely allied to the lining epithelium of the viscus.

REFERENCES

Ewing, J. (1928). *Neoplastic Diseases.* Philadelphia: W. B. Saunders.

Graham, E. A. (1931). Prevention of Carcinoma of Gall-bladder. *Ann. Surg.*, Vol. XCIII, p. 317.

Leitch, A. (1924). Gall-stones and Cancer of the Gall-bladder. *Brit. Med. Journ.*, Vol. II, p. 451.

Osler, W., and McCrae, T. (1926–28). *A System of Medicine.* London: Henry Kimpton.

Watts, S. H. (1922). Primary Carcinoma of Gall-bladder. *Virginia Med. Monthly*, Vol. XLIX, p. 175.