CORRELATION BETWEEN STANDARD AUTOMATED PERIMETRY GLOBAL INDICES AND HEIDELBERG RETINA TOMOGRAPH PARAMETERS

CORRELACIÓN ENTRE LOS ÍNDICES GLOBALES DE LA PERIMETRÍA AUTOMATIZADA CONVENCIONAL Y LOS PARÁMETROS TOPOGRÁFICOS PAPILARES (HEIDELBERG RETINA TOMOGRAPH II)

PÉREZ-ÍÑIGO A[1], POLO V[1], LARROSA JM[1], FERRERAS A[1], SÁNCHEZ-CANO A[2], MARTÍNEZ-DE-LA-CASA JM[3], HONRUBIA FM[1]

ABSTRACT

Purpose: To correlate the optic nerve head topographic parameters measured by the Heidelberg Retina Tomograph II (HRT) with the perimetric indices of standard automated perimetry (SAP).
Methods: This study included 101 normal subjects, 247 ocular hypertensive eyes (increased intraocular pressure with normal SAP) and 102 glaucomatous subjects (IOP above 21 mm Hg and abnormal standard automated perimetry). Only one eye was randomly chosen from each subject for the study. The visual field was evaluated by means of Humphrey Field Analyzer (24-2 full threshold strategy). The HRT II (Heidelberg Engineering) was used to acquire and measure the optic disc topographic parameters. Pearson correlations between topographic data and perimetric indices were performed for the total sample and each group of patients. The distribution of values obtained in the samples was normal.
Results: A significant correlation was found between several optic disc parameters and the global indi-

RESUMEN

Objetivo: Correlacionar los parámetros estructurales del nervio óptico obtenidos mediante Heidelberg Retina Tomograph II (HRT) con los índices perimétricos de la perimetría automatizada convencional.
Metodos: Se incluyeron 101 sujetos normales, 247 hipertensos oculares [presión intraocular (PIO) elevada con perimetría automatizada convencional normal] y 102 sujetos glaucomatosos (PIO>21 mmHg y perimetría automatizada convencional alterada). Solo se incluyó un ojo de cada sujeto para el análisis. La perimetría automatizada se realizó mediante un perímetro Humphrey Field Analyzer (umbral completo, 24-2). El estudio papilar se realizó mediante láser confocal de barrido Heidelberg Retina Tomograph (HRT II). Se realizó un estudio de los coeficientes de correlación (Pearson) entre los parámetros topográficos papilares y los índices perimétricos en el total de sujetos y en cada uno de los grupos de estudio, ya que las muestras presentaban una distribución de sus valores ajustada a la normalidad.

Received: 6/6/05. Accepted: 6/6/07.
[1] Ph.D. in Medicine. Miguel Servet University Hospital. Zaragoza. Spain.
[2] Graduate in Physical Sciences, optics specialty. Miguel Servet University Hospital. Zaragoza. Spain.
[3] Ph.D. in Medicine. University Clinical Hospital. Madrid. Spain.
This paper was partially funded by the National Network of Cooperative Research: Prevention of Blindness, Glaucoma sub-project.

Correspondence:
M.ª Aránzazu Pérez Íñigo
Paseo Sagasta, 15, 9.º C
50008 Zaragoza
Spain
E-mail: aperezinigo@hotmail.com

ces of SAP. Rim area, rim volume, cup/disc area ratio, rim/disc area ratio, cup shape measurement, RNFL cross-sectional area, and discriminant functions FSM and RB, showed the strongest correlation with the visual field indices in the total and glaucoma groups (RIM AREA: total group: r=0.32; p=4.14x10^{-11} / glaucoma group: r=0.28; p=0.004. RIM VOLUME: total group: r=0.26; p=1.55x10^{-7} / glaucoma group: r=0.26; p=0.006). The ocular hypertensive group showed few significant correlations.

Conclusions: The correlations found between standard automated perimetry and HRT defined topographic parameters allow a better understanding of glaucomatous damage and make decision-making easier *(Arch Soc Esp Oftalmol 2007; 82: 401-412).*

Key words: Glaucoma, diagnosis, HRT, optic nerve head, perimetry.

Resultados: Se observaron correlaciones significativas entre varios parámetros de la cabeza del nervio óptico y los índices globales de la perimetría automatizada convencional. En el total de sujetos y en el grupo glaucoma, las correlaciones más fuertes con los índices del campo visual se obtuvieron con el área (total: r=0,32; p=4,14x10^{-11}/glaucoma: r=0,28; p=0,004) y volumen del anillo neurorretiniano (total: r=0,26; p=1,55x10^{-7}/glaucoma: r=0,26; p=0,006), el cociente de área excavación/disco y anillo/disco, el índice de morfología papilar, el área de corte de la capa de fibras nerviosas de la retina y las funciones discriminantes FSM y RB. El grupo de hipertensión ocular obtuvo pocas correlaciones significativas.

Conclusiones: Las correlaciones observadas entre la perimetría automatizada convencional y HRT II, permiten mejorar el conocimiento del daño glaucomatoso y facilitan la toma de decisiones con los resultados de todas las pruebas de las que disponemos en la actualidad.

Palabras clave: Glaucoma, diagnóstico, HRT, nervio óptico, perimetría.

INTRODUCTION

Simple chronic glaucoma is a progressive neuropathy characterized by the existence of structural alterations at the level of the optic nerve and the fibrous nerve layer of the retina as well as functional loss at the level of the visual field (1-5). The exploration of the field of vision and the clinical evaluation of the optic nerve have constituted a cornerstone in the evolved control of the disease (6-13).

The Heidelberg Retinal Tomograph —HRT II— is a new generation film screen confocal laser that allows the retrieval of morphometric images of the optic nerve, performing an objective and reproducible papillary analysis, minimizing the subjectivity of the operator (14-18).

In this comparative study of diverse image analysis techniques performed by Nakla et al (19), the diagnostic precision of the HRT and the qualitative evaluation of the stereoscopic photographs of the papilla were greater than that of the OCT and the analyzer of the fibrous nerve layer GDx. In other studies, however, no significant differences were found in the area below the ROC curve among the best parameters of each instrument, but there was greater sensitivity with HRT and OCT than with the GDx (20).

The goal of the present study is to establish if the measures obtained in this study of the papilla with the HRT II adequately correlate with the overall indices of the field of vision (MD and CPSD) obtained with conventional automated perimetry (AP) in normal, ocular and glaucomatous hypertension subjects.

SUBJECTS, MATERIALS, AND METHOD

Subjects

A total of 450 eyes from 450 subjects were included in this study. Each subject, regardless of group, fulfilled a series of inclusion criteria: age between 30 and 80 years, visual acuity equal to or greater than 8/10 (Snellen scale), refraction defect inferior to 5.00 diopter (D) of spherical equivalent and 3.00 D cylinder and transparent optical media.

Informed consent was obtained from the patients, explaining the diagnostic tests that would be performed.

Individuals were excluded if they had a previous history of pathology, surgery or optical trauma, systemic diseases with ophthalmological repercussion, if it was impossible to perform or assess any of the tests included in the examination protocol (perimeter study, HRT,…) or if any of the inclusion criteria was not met.

The subjects included were classified into three study groups: normal or control, ocular hypertension (OHT) and simple chronic glaucoma.

— *Control Group* (n = 101 eyes). All fulfilled the inclusion criteria. The intraocular pressure (IOP) had to be higher than 21 mm Hg in any of the determinations.

— *OHT Group* (n = 247 eyes). These presented, on at least two occasions, IOP findings greater than 21 mm Hg, as well as a normal AP study. Pachymetry was performed on all subjects in this group. The mean value obtained was 567.7±36.9µm.

— *Glaucoma Group* (n = 102 eyes). Presented elevated tension figures (IOP > 21 mm Hg) and the existence of field measurement defects in the AP.

To avoid the influence of papillary morphometric data in the analysis of the results, subjects with glaucoma were not selected on the basis of the clinical evaluation of the papilla. Subjects were classified as glaucomatous based on the AP evaluation (diagnostic benchmark).

Examination Procedure

Once the selection criteria were applied, the protocol performed included:

— Conventional Automated Perimetry *(AP),* performed with the «HUMPHREY 630» Field Analyzer (24-II, STACPAC 2). The selection criteria to define a perimetry as altered were the presence of groups of points or «clusters» with significant declines in sensitivity (at least three continuous points in the same hemifield with a significance level of $p<0.05$ or a group of at least two continuous points in the same hemifield with a significance level of $p<0.01$) (21) and/or a statistically significant Corrected Pattern Standard Deviation (CPSD), at levels of $p<0.02$ and/or the presence of Glaucoma Hemifield Test (GHT) was outside normal limits.

— *Confocal laser scanning. Heidelberg Retina Tomograph —HRT II.*

The topographic study of the papilla was performed using a confocal scanning laser (HRT version II) that enables the retrieval of a topographical image of the papilla through a series of images or optical slices at different depths.

From the reconstructed three-dimensional image, a researcher delimited the contour of the optical disc. This was always established by the same ophthalmologist, a specialist in glaucoma with experience in papillary planimetry (JML). The delimitation was performed without information about the inclusion group of the subject nor the research. The contour of the optical disc was defined as the border between the optical nerve content and the Elschnig scleral ring.

After this, the programme established a reference plane, 50 microns below the retinal contour in the temporal sector between 350º and 356º (22).

The HRT II incorporates a papillary analysis programme (Heidelberg Eye Explorer version 1.3.0.0) that calculates multiple structural parameters of the optic nerve. Thus, from the papillary contour and the reference plane, the programme has the quantitative morphological results for the following papillary parameters (23):

— Rim area, cup area, ring area, cup area/rim ratio, ring area/rim ratio, cup volume, ring volume, mean cup depth, maximum cup depth, contour height variation, morphological index of the cup («cup shape measure» or CSM), thickness of the retinal fibrous nerve layer, cross-section of the retinal fibrous nerve layer, cup/horizontal papilla ratio, cup/vertical papilla ratio, maximum contour elevation, maximum contour depression, Superior Temporal modulation contour line, Inferior Temporal modulation contour line, average variability, reference height.

Additionally, the programme incorporates the following discriminant functions:

— *FSM discriminant function:* Proposed by FS Mikelberg (24). Includes CSM, variation in the contour height and the neuroretinal ring volume, and

— *RB discriminant function:* Proposed by R. Bathija (25). Includes CSM, the variation in contour height, the thickness of the retinal fibrous nerve layer and neuroretinal ring volume.

Statistics

The correlations between these structural parameters and the overall indices of the visual field AP were established in each group of subjects.

For this, a correlation analysis was performed. Subsequent to the study of the quantitative variables a Kolmogorov-Smirnov test was performed proving that the study samples presented a distribution of values that adjusted to normality. The Pearson correlation coefficient measures the intensity of the linear relationship between both variables where parametric tests are used. SPSS 11.0 software (SPSS Inc, Chicago, Illinois, USA) was used for statistical data processing and the Microsoft Word programme for word processing.

RESULTS

A total of 450 eyes from 450 subjects were included in the study, 101 controls, 247 with ocular hypertension and 102 with glaucoma. The descriptive characteristics of the populations included are shown in Table I. In comparing these characteristics between groups, statistically significant differences

Tabla I. Características de la población

	Control Group (n=101)		OHT Group (n=247)		Glaucoma Group (n=102)	
	Mean	SD	Meam	SD	Meam	SD
Age	55.53 (3)	12.78	53.7 (3)	12.39	62.9(1.2)	9.70
A.V.	0.857	0.188	0.94	0.09	0.85	0.12
Basal IOP	14.6 (2.3)	2.79	23.8 (1)	3.21	24.2 (1)	4.53
Cup	0.87/5 (2.3)	0.82/5	2.55/5 (1,3)	0.95/5	3.46/5 (1.2)	1.12/5
CC-MD	-0.56 (3)	1.54	-0.38 (3)	1.29	-6.81 (1.2)	6.79
CC-CPSD	1.03 (3)	1.06	1.11 (3)	0.90	4.95 (1.2)	3.75

Statistically significant differences (1) with respect to control group; (2) with respect to the Hypertensive group; (3) with respect to the Glaucoma Group.

Table II. Correlation coefficient (Pearson r) and significance level between the different papillary morphology parameters evaluated with the HRT II and the visual field indices of the conventional automated perimetry (MD and CPSD) in the totality of the sample subjects

	MD		CPSD	
	Pearson Correlation	P	Pearson Correlation	P
cup area	-0.264	0.00	0.226	0.00
rim area	**0.325**	0.00	**-0.036**	0.00
cup/disc area ratio	-0.338	0.00	0.335	0.00
rim/disc area ratio	0.338	0.00	-0.335	0.00
cup volume	-0.177	0.00	0.203	0.00
rim volume	0.261	0.00	-0.284	0.00
mean cup depth	-0.054	0.28	0.097	0.06
maximum cup depth	0.077	0.13	-0.061	0.23
height variation contour	0.038	0.45	-0.070	0.17
cup shape measure	**-0.386**	0.00	**0.379**	0.00
mean RNFL thickness	0.338	0.00	-0.356	0.00
RNFL cross sectional area	0.325	0.00	-0.357	0.00
horizontal cup/disk ratio	-0.136	0.01	0.149	0.00
vertical cup/disk ratio	-0.294	0.00	0.282	0.00
maximum contour elevation	-0.188	0.01	0.139	0.01
maximum contour depression	-0.126	0.00	0.061	0.23
CLM temporal-superior	0.319	0.00	-0.303	0.00
CLM temporal-inferior	0.352	0.00	-0.402	0.00
average variability (SD)	-0.162	0.00	0.114	0.03
reference height	0.039	0.44	-0.108	0.03
FSM discriminant function value	**0.362**	0.00	**-0.363**	0.00
RB discriminant value	**0.419**	0.00	**-0.445**	0.00

existed in the average IOP values, papillary cup, and in the values of overall perimetric indices (MD and CPSD).

In the analysis performed on all of the sample population included in the study (normal, ocular hypertensive and glaucomatous subjects), a significant correlation has been shown (Pearson's correlation coefficient r, $p<0.01$) among the majority of the papillary parameters, except the rim area, mean depth and maximum cup, and the variation of contour height and the field of vision indices (MD and CPSD) of AP (Table II).

Of the different parameters evaluated, ring area, cup morphology index and the FSM and RB discriminant functions have shown the highest correlations with field of vision (MD and CPSD) (Fig. 1).

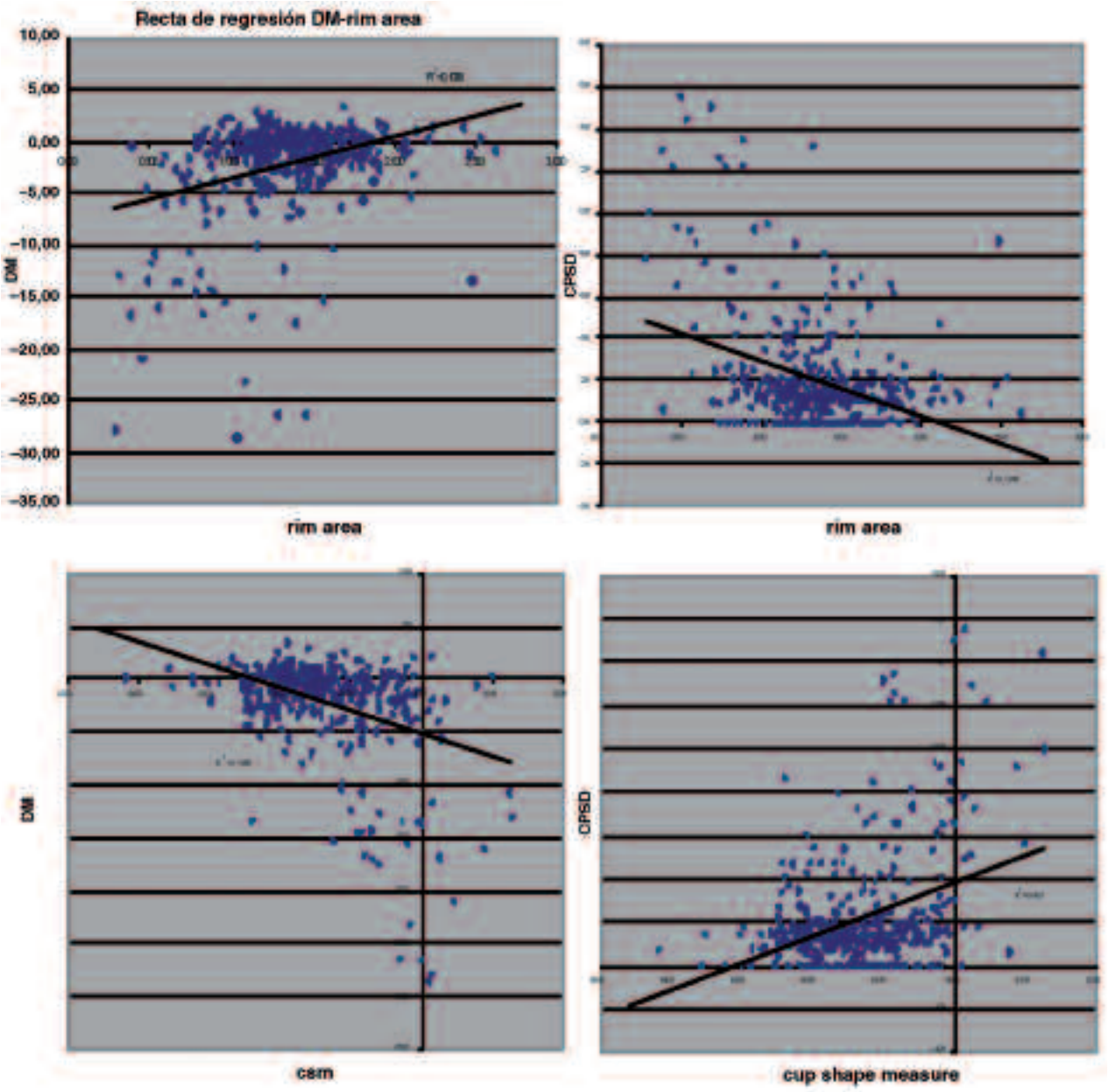

Fig. 1: Regression line resulting from the correlation between the ring area, the cup morphology index, (cup shape measure), the FSM and RB discriminant functions and the field of vision indices of the conventional automated perimetry (MD and CPSD) in all of the sample subjects.

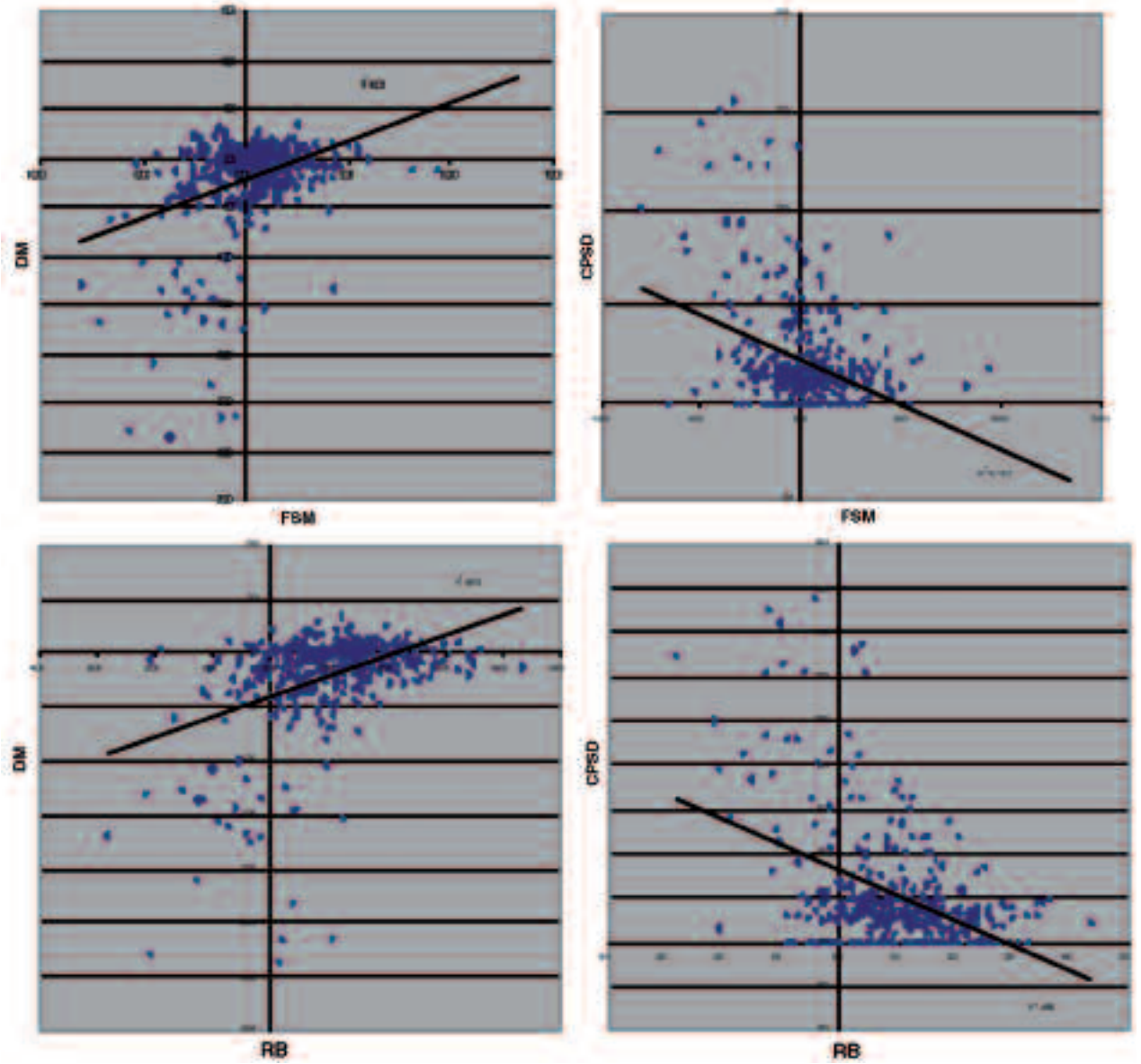

Fig. 1 (cont.).

Analyzing the correlation between the papillary parameters and the field of vision indices in the group of normal subjects, no significant correlation was shown in any of these parameters and the AP indices.

On the contrary, in relation to the population with glaucoma, a significant correlation has been shown (Pearson's correlation coefficient, $p<0.05$) between the field of vision indices (MD and CPSD) of the AP and the cup and ring, the cup area/rim ratio, ring volume, CSM, average thickness of the RNFL, the cross-section of the RNFL, vertical cup area/rim ratio, the modulation of the superior and inferior temporal contour line and the FSM and RB discriminant functions (Table III). Among all these parameters, CSM, vertical cup/rim ratio and the FSM and RB discriminant functions have shown higher correlations with the visual field indices (MD and CPSD) (Fig. 2).

Within the group of subjects with ocular hypertension, the only correlation that has been shown to be close to being significant with the

CPSD of the AP visual field indices was between the cup area/rim ratio and the ring area/rim ratio (Table IV).

DISCUSSION

Despite the different nature of the structural parameters obtained with the HRT II and the functional data of the various examination methods of the visual field, a correlation might intuitively be expected between the results of both types of tests, and this will be dependent on the type of sample selected.

In our study, we performed an analysis of the different sample groups, the correlation between the structural parameters through HRT II, and the AP indices (MD and CPSD).

With regard to these results, the fact that we only obtained significant correlations when we included subjects in the study with altered perimetry (glaucomas) is probably explained by the amplitude of the range of numeric values obtained by this group in the MD and CPSD indices, something that does not occur in any of the other groups where normal, i.e. closely defined, results are obtained, It is thus not possible to establish a correlation from the numeric values of the HRT parameters as these vary widely.

Taking into account that the relationship model between anatomy and function does not always have to be linear in all the distribution spans and that this distribution depends on the sample used, studies could be conducted to include quadratic and cubic adjustments that might show a better correlation between the parameters used.

In comparing our results with other authors who have also studied these subjects, we can say that Eid et al, Mistlberger et al, Tsai et al, Iester et al and Brigatti et al (26-30) also obtain significant correlations in different parameters, but in all their works these are found in either the group of subjects with glaucoma or else in the complete population sample. None of them found a correlation in normal subjects or in those with ocular hypertension. A work from Iester et al (31) shows there is a correlation with two of the structural parameters obtained in the group of ocular hypertensives (with normal field of vision), and the perimetry indices of. These were ring area and ring volume.

If we focus on the parameters in which each author obtains the highest correlation we can say

Table III. Correlation coefficients (Pearson r) and significance level between the different papillary morphology parameters evaluated with the HRT II and the visual field indices of the conventional automated perimetry (MD and CPSD) in the glaucomatous subjects

	MD		CPSD	
	Pearson Correlation	P	Pearson Correlation	P
cup area	-0.281	0.004	0.212	0.034
rim area	0.286	0.004	-0.341	0.000
cup disc area ratio	-0.338	0.001	0.336	0.001
rim/disc area ratio	0.338	0.001	-0.336	0.001
cup volume	-0.122	0.222	0.183	0.067
rim volume	0.268	0.006	-0.276	0.005
mean cup depth	-0.038	0.704	0.124	0.216
maximum cup depth	0.082	0.414	-0.061	0.544
height variation contour	-0.042	0.676	0.028	0.780
cup shape measure	**-0.434**	0.000	**0.450**	0.000
mean RNFL thickness	0.318	0.001	-0.338	0.001
RNFL cross sectional area	0.295	0.003	-0.337	0.001
horizontal cup/disk ratio	-0.156	0.118	0.184	0.065
vertical cup/disk ratio	-0.362	0.000	0.332	0.001
maximum contour elevation	-0.206	0.038	0.120	0.233
maximum contour depression	-0.242	0.014	0.145	0.149
CLM temporal-superior	0.319	0.001	-0.268	0.007
CLM temporal-inferior	0.295	0.003	-0.405	0.000
average variability (SD)	-0.130	0.194	0.088	0.379
reference height	-0.030	0.763	-0.102	0.311
FSM discriminant function value	**0.378**	0.000	**-0.390**	0.000
RB discriminant function value	**0.384**	0.000	**-0.429**	0.000

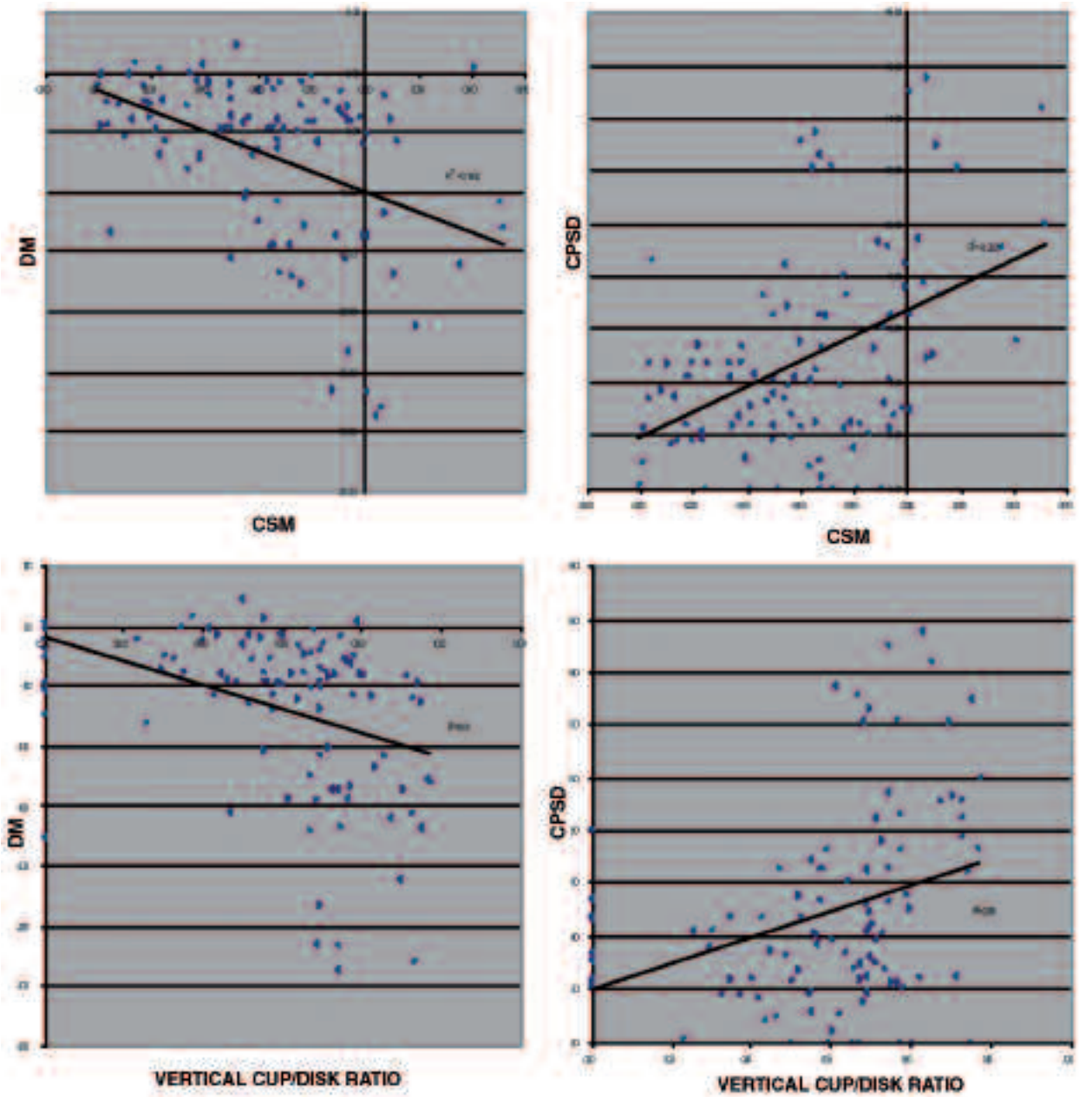

Fig. 2: Regression line resulting from the correlation between the cup/vertical disc quotient, the cup morphology index (cup shape measure), the discriminant function FSM and the discriminant function RB and the visual field indices.

that Brigatti et al (30) observed statistically significant correlations of CSM with both MD and CPSD. According to Iester and Mikelberg (31), the neuroretinal ring area is the parameter with the greatest correlation with CPSD and to a lesser extent with MD. Mistlberger (27) found a correlation between the thickness of the RNFL and the MD. Uchida et al (32) fundamentally discuss the good correlation of CSM with the MD and CPSD.

The papillary topographs can obtain the sectorial results of the characteristics of the optic nerve. This possibility has been enabled by sectors of the papillary topographic characteristics and their correlation with the field of vision indices (29). The results

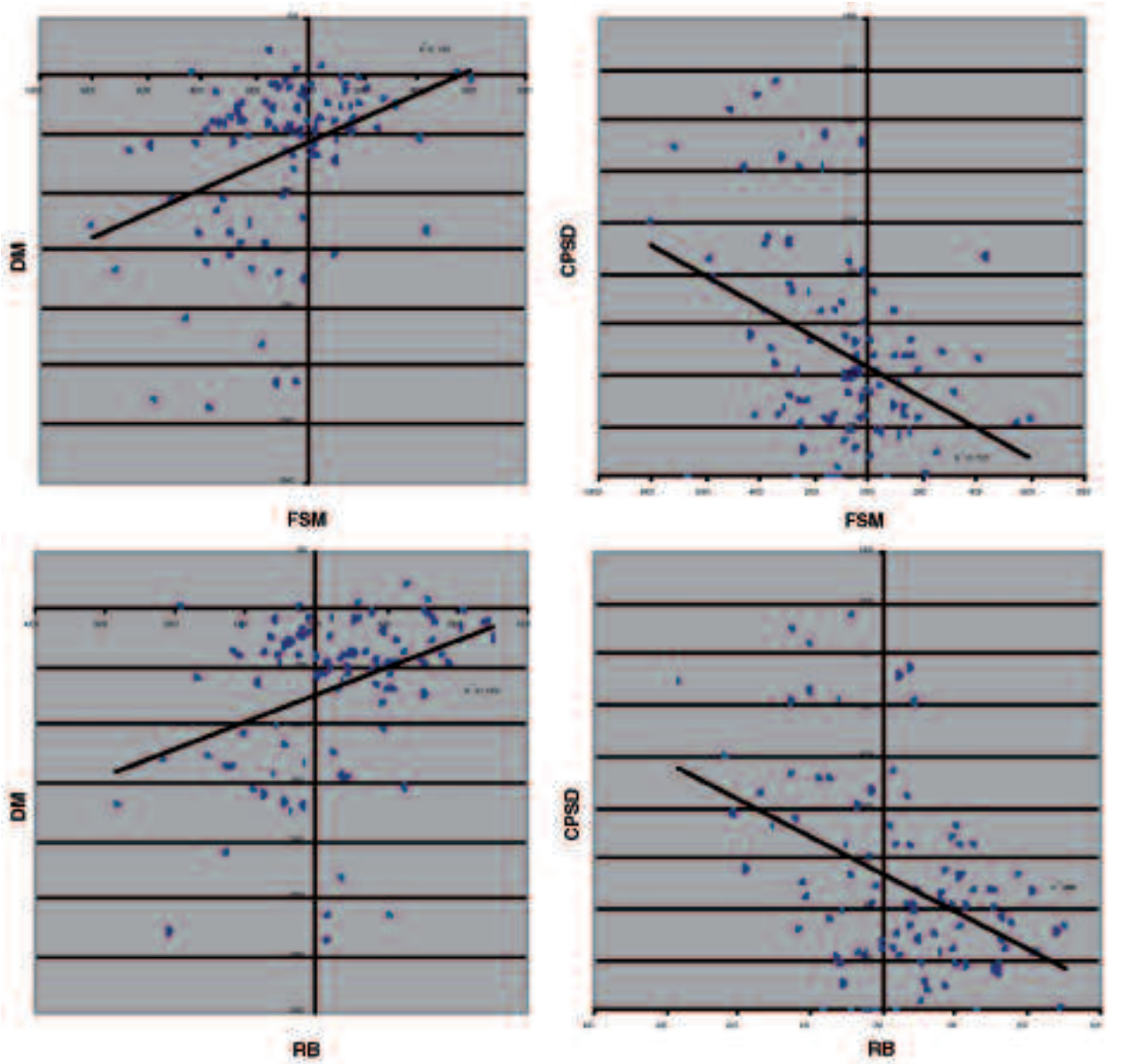

Fig. 2 (cont.).

of this study offer stronger correlations between the papillary topographic parameters of the inferior and superior sectors and the indices of the corresponding field of vision regions, while the nasal and temporal sectors obtained weaker correlations. The narrowest correlations were obtained among the topographic parameters of the inferior sector of the MD of the superior hemifield. The sectorial parameters that showed the strongest associations were the CSM and the cup area. Other authors such as Antón et al (33) have analyzed the topographic relation between specific locations of the glaucomatous visual field and damage to the optic nerve. In their study, they conclude that the retinal nerve cross-section area/rim ratio is a useful parameter to demonstrate focal damage of the ring, and the inter-individual variability seems to compensate the configuration of the head of the optic nerve.

This study establishes the existence of a significant correlation (though not very strong) between structural and functional parameters in the group of glaucomatous subjects in our wide population sam-

Table IV. Correlation coefficients (Pearson r) and significance level between the different papillary morphology parameters evaluated with the HRT II and the visual field indices of the conventional automated perimetry (MD and CPSD) in the ocular hypertensive subjects

	MD		CPSD	
	Pearson Correlation	P	Pearson Correlation	P
cup area	0.037	0.677	-0.160	0.074
rim area	-0.129	0.151	0.069	0.443
cup/disc area ratio	0.077	0.390	**-0.172**	0.054
rim/disc area ratio	-0.077	0.390	**0.172**	0.054
cup volume	0.054	0.545	-0.145	0.106
rim volume	-0.157	0.079	0.004	0.965
mean cup depth	0.097	0.282	-0.162	0.069
maximum cup depth	0.106	0.236	-0.161	0.071
height variation contour	-0.107	0.235	-0.109	0.223
cup shape measure	-0.010	0.915	-0.052	0.561
mean RNFL thickness	-0.063	0.481	-0.072	0.423
RNFL cross sectional area	-0.089	0.319	-0.076	0.395
horizontal cup/disk ratio	0.111	0.217	-0.112	0.211
vertical cup/disk ratio	0.087	0.330	-0.135	0.131
maximum contour elevation	-0.071	0.431	-0.121	0.178
maximum contour depression	-0.115	0.198	-0.152	0.088
CLM temporal-superior	-0.019	0.835	-0.024	0.792
CLM temporal-inferior	-0.033	0.713	-0.061	0.495
average variability (SD)	-0.140	0.117	-0.115	0.201
reference height	-0.095	0.288	-0.133	0.137
FSM discriminant function value	-0.109	0.226	0.103	0.251
RB discriminant function value	0.006	0.941	-0.051	0.573

ple. This could support the theory that in subjects with glaucoma the local functional damage is already established and there is greater consistency with the structural damage of the optic nerve and RNFL, something that does not occur in hypertensive or normal subjects, who have normal visual fields. In the group of ocular hypertensive subjects, alterations were observed in some structural parameters obtained by the HRT II, which makes one think of an anatomical defect earlier than the functional damage in this group of subjects and this explains the poor correlation between the indices in both tests.

In general, the existing correlations enable the improvement of the knowledge of glaucomatous damage and facilitate decision making from a consistent position with the results of all the functional and structural tests that we currently have available.

REFERENCES

1. *Jonas JB, Fernandez MC, Sturmer J. Pattern of glaucomatous neuroretinal rim loss. Ophthalmology 1993; 100: 63-68.*
2. *Polo V, Abecia E, Pablo LE, Pinilla I, Larrosa JM, Honrubia FM. Short-wavelength automated perimetry and retinal nerve fiber layer evaluation in suspected cases of glaucoma. Arch Ophthalmol 1998; 116: 1295-1298.*
3. *Sommer A, Katz J, Quigley HA, Miller NR, Robin AL, Richter RC, et al. Clinically detectable nerve fiber atrophy predeces the onset of glaucomatous field loss. Arch Ophthalmol 1991; 109: 77-83.*
4. *Heijl A, Lindgren G, Olsson J, Asman P. Visual field interpretation with empiric probability maps. Arch Ophthalmol 1989; 107: 204-208.*
5. *Polo V, Larrosa JM, Pinilla I, Perez S, Gonzalvo F, Honrubia FM. Predictive value of short-wavelength automated perimetry: a 3-year follow-up study. Ophthalmology 2002; 109: 761-765.*
6. *Balazsi AG, Drance SM, Schulzer M, Douglas GR. Neuroretinal rim area in suspected glaucoma and early chronic open-angle glaucoma. Correlation with parameters of visual function. Arch Ophthalmol 1984; 102: 1011-1014.*
7. *Airaksinen PJ, Drance SM, Schulzer M. Neuroretinal rim area in early glaucoma. Am J Ophthalmol 1985; 99: 1-4.*
8. *Tuulonen A, Airaksinen PJ. Initial glaucomatous optic disk and retinal nerve fiber layer abnormalities and their progression. Am J Ophthalmol 1991; 111: 485-490.*
9. *Airaksinen PJ, Tuulonen A, Alanko HI. Rate and pattern of neuroretinal rim area decrease in ocular hypertension and glaucoma. Arch Ophthalmol 1992; 110: 206-210.*
10. *Jonas JB, Konigsrereuther KA. Optic disc appearance in ocular hypertensive eyes. Am J Ophthalmol 1994; 117: 732-740.*
11. *Heilj A, Bengtsson B. The effect of perimetric experience in patients with glaucoma. Arch Ophthalmol 1996; 114: 19-22.*

12. *Quigley HA, Addicks EM, Green WR. Optic nerve damage in human glaucoma. III. Quantitative correlation of nerve fiber loss and visual field defect in glaucoma, ischemic neuropathy, papilledema, and toxic neuropathy. Arch Ophthalmol 1982; 100: 135-146.*
13. *Sommer A, Katz J, Quigley HA, Miller NR, Robin A, Richter RC, et al. Clinically detectable nerve fiber atrophy precedes the onset of glaucomatous field loss. Arch Ophthalmol 1991; 109: 77-83.*
14. *Garway-Heath DF, Poinoosawmy D, Wollstein G, Viswanathan A, Kamal D, Fontana L, et al. Inter- and intraobserver variation in the analysis of optic disc images: comparison of the Heidelberg retina tomograph and computer assisted planimetry. Br J Ophthalmol 1999; 83: 664-669.*
15. *Rohrschneider K, Burk RO, Kruse FE, Volcker HE. Reproducibility of the optic nerve head topography with a new laser tomographic scanning device. Ophthalmology 1994; 101: 1044-1049.*
16. *Janknecht P, Funk J. Optic nerve head analyser and Heidelberg retina tomograph: accuracy and reproducibility of topographic measurements in a model eye and in volunteers. Br J Ophthalmol 1994; 78: 760-768.*
17. *Weinreb RN, Lusky M, Bartsch DU, Morsman D. Effect of repetitive imaging on topographic measurements of the optic nerve head. Arch Ophthalmol 1993; 111: 636-638.*
18. *Hatch WV, Flanagan JG, Williams-Lyn DE, Buys YM, Farra T, Trope G E. Interobserver agreement of Heidelberg retina tomograph parameters. J Glaucoma 1999; 8: 232-237.*
19. *Nakla M, Nduaguba C, Rozier M, Joudeh M, Hoffman D, Caprioli J. Comparison of imaging techniques to detect glaucomatous optic nerve damage. Invest Ophthalmol Vis Sci 1999; 40: S397.*
20. *Zangwill LM, Bowd C, Berry CC, Williams J, Blumenthal EZ, Sanchez-Galeana CA, et al. Discriminating between normal and glaucomatous eyes using the Heidelberg Retina Tomograph, GDx Nerve Fiber Analyzer, and Optical Coherence Tomograph. Arch Ophthalmol 2001; 119: 985-993.*
21. *Caprioli J. Automated perimetry in glaucoma. Am J Ophthalmol 1991; 111: 235-239.*
22. *Vihanninjoki K, Burk RO, Teesalu P, Tuulonen A, Airaksinen PJ. Optic disc biomorphometry with the Heidelberg Retina Tomograph at different reference levels. Acta Ophthalmol Scand 2002; 80: 47-53.*
23. *Saruhan A, Orgul S, Kocak I, Prunte C, Flammer J. Descriptive information of topographic parameters computed at the optic nerve head with the Heidelberg retina tomograph. J Glaucoma 1998; 7: 420-429.*
24. *Mikelberg FS, Parfitt CM, Swindale NV, Graham SL, Drance SM, Gosine R. Ability of the Heidelberg retina tomograph to detect early glaucomatous visual field loss. J Glaucoma 1995; 4: 242-247.*
25. *Bathija R, Zangwill L, Berry CC, Sample PA, Weinreb RN. Detection of early glaucomatous structural damage with confocal scanning laser tomography. J Glaucoma 1998; 7: 121-127.*
26. *Eid TM, Spaeth GL, Katz LJ, Azuara-Blanco A, Agusburger J, Nicholl J. Quantitative estimation of retinal nerve fiber layer height in glaucoma and the relationship with optic nerve head topography and visual field. J Glaucoma 1997; 6: 221-230.*
27. *Mitslberger A, Liebmann JM, Greenfield DS, Pons ME, Hoh ST, Ishikawa H, et al. Heidelberg retina tomography and optical coherence tomography in normal, ocular-hypertensive and glaucomatous eyes. Ophthalmology 1999; 106: 2027-2032.*
28. *Tsai CS, Zangwill L, Sample PA, Garden V, Bartsch DU, Weinreb RN. Correlation of peripapillary retinal height and visual field in glaucoma and normal subjects. J Glaucoma 1995; 4: 110-116.*
29. *Iester M, Swindale NV, Mikelberg FS. Sector-based analysis of optic nerve head shape parameters and visual field indices in healthy and glaucomatous eyes. J Glaucoma 1997; 6: 371-376.*
30. *Brigatti L, Caprioli J. Correlation of visual field with scanning confocal laser optic disc measurements in glaucoma. Arch Ophthalmol 1995; 113: 1191-1194.*
31. *Iester M, Mikelberg FS, Courtright P, Drance SM. Correlation between the visual field indices and Heidelberg retina tomograph parameters. J Glaucoma 1997; 6: 78-82.*
32. *Uchida H, Brigatti L, Caprioli J. Detection of structural damage from glaucoma with confocal laser image analysis. Invest Ophthalmol Vis Sci 1996; 37: 2393-2401.*
33. *Anton A, Yamagishi N, Zangwill L, Sample PA, Weinreb RN. Mapping structural to functional damage in glaucoma with standard automated perimetry and confocal scanning laser ophthalmoscopy. Am J Ophthalmol 1998; 125: 436-446.*