



Review

EAONO/JOS Joint Consensus Statements on the Definitions, Classification and Staging of Middle Ear Cholesteatoma

Matthew Yung, Tetsuya Tono, Ewa Olszewska, Yutaka Yamamoto, Holger Sudhoff, Masafumi Sakagami, Jeff Mulder, Hiromi Kojima, Armağan İncesulu, Franco Trabalzini, Nuri Özgirgin

The Ipswich Hospital NHS Trust, Heath Road, Suffolk, United Kingdom IP4 5PD (MY)

Department of Otolaryngology-Head and Neck Surgery, University of Miyazaki 5200 Kihara, Kiyotake, Miyazaki 889-1692, Japan (TT)

Department of Otolaryngology, Medical University of Białystok ul. Skłodowskiej 24 A, 15-276 Białystok, Poland (EO)

Department of Otorhinolaryngology, Jikei University School of Medicine, 3-25-8 Nishi-shinbashi, Minato-ku, Tokyo 105-8461, Japan (YY)

Department of Otorhinolaryngology, Bielefeld Academic Teaching Hospital, Bielefeld, Germany (HS)

Department of Otolaryngology, Hyogo College of Medicine, Hyogo, Japan (MS)

Philip van Leydenlaan 15 Radboud University Hospital, 6500 HB Nijmegen, Netherlands (JM)

Department of Otorhinolaryngology, Jikei University School of Medicine, 3-25-8 Nishishinbashi,

Minatoku, Tokyo 105-8461, Japan (HK)

Department of Otolaryngology-Head and Neck Surgery, Eskişehir Osmangazi University School of Medicine, Eskişehir, Turkey (Aİ)

Department of Otolaryngology, Meyer Children's Hospital, Florence, Italy (FT)

Department of Otolaryngology, Bayındır Hospital, Ankara, Turkey (NÖ)

The European Academy of Otolology and Neurotology (EAONO) has previously published a consensus document on the definitions and classification of cholesteatoma. It was based on the Delphi consensus methodology involving the broad EAONO membership. At the same time, the Japanese Otological Society (JOS) had been working independently on the "Classification and Staging of Cholesteatoma." EAONO and JOS then decided to collaborate and produce a joint consensus document. The EAONO/JOS joint consensus on "Definitions, Classification and Staging of Middle Ear Cholesteatoma" was formally presented at the 10th International Conference on Cholesteatoma and Ear Surgery in Edinburgh, June 5–8, 2016. The international otology community who attended the consensus session was given the chance to debate and give their support or disapproval. The statements on the "Definitions of Cholesteatoma" received 89% approval. The "Classification of Cholesteatoma" received almost universal approval (98%). The "EAONO/JOS Staging System on Middle Ear Cholesteatoma" had a majority of approval (75%). Some international otologists wanted to see more prognostic factors being incorporated in the staging system. In response to this, the EAONO/JOS steering group plans to set up an "International Otology Outcome Working Group" to work on a minimum common otology data set that the international otology community can use to evaluate their surgical outcome. This will generate a large database and help identify relevant prognostic factors that can be incorporated into the staging system in future revisions.

KEYWORDS: Definitions, classification, staging, cholesteatoma

The aims of the European Academy of Otolology and Neurotology/Japan Otological Society (EAONO/JOS) Joint Consensus Statements on Definition, Classification and Staging are as follows:

1. The definitions provide terminologies in the description of cholesteatoma.
2. The classification categorized cholesteatoma into distinct categories to facilitate the comparison of surgical outcomes across reports.
3. The staging system reflects the severity of the cholesteatoma, the difficulty to achieve complete removal, and the subsequent restoration of normal function.

The authors wish to present the final consensus first, followed by an explanation of the methodology on how the EAONO/JOS consensus was reached by the steering group.

The clinical classification of middle ear mucosa is summarized in Figure 1.

Corresponding Address: Matthew Yung E-mail: matthewyung@btconnect.com

Submitted: 12.12.2016

Accepted: 15.12.2016

Available Online Date: 06.01.2017

Definitions and Statements on Cholesteatoma

1. Cholesteatoma is a mass formed by the keratinizing squamous epithelium in the tympanic cavity and/or mastoid and subepithelial connective tissue and by the progressive accumulation of keratin debris with/without a surrounding inflammatory reaction.
2. Cholesteatoma consists of matrix (keratinizing squamous epithelium), perimatrix (varying thickness of the subepithelial connective tissue), and keratin debris.
3. The pathophysiology of cholesteatoma is not completely understood.
4. Recurrent infections and inflammatory reactions at the subepithelial connective tissue of cholesteatoma contribute to bone resorption in the adjacent area.
5. Cholesteatoma is diagnosed with a detailed otologic history, physical examination by otomicroscopy, and endoscopy with or without imaging.
6. Cholesteatoma is classified into two general categories: congenital and acquired.
7. Acquired cholesteatoma is characterized by clinical symptoms/signs that are the result of growth with/without destruction of the adjacent structures:
 - with or without tympanic membrane retraction and/or perforation,
 - with or without otorrhea,
 - with or without hearing deterioration,
 and/or CT/MRI findings (soft tissue masses, focal areas of bony erosion of the middle ear, and mastoid)
8. A retraction pocket can develop into acquired cholesteatoma when it loses its ability of self-cleaning and starts the accumulation of keratin debris.
9. Acquired cholesteatoma is not present at birth.
10. Acquired cholesteatoma might develop from a retraction pocket of the pars flaccida, pars tensa, or both and from basal cell invasion through the basilar membrane and could be a sequela of the dysfunction of middle ear pressure regulation. Acquired cholesteatoma can also develop secondary to tympanic membrane perforation as a result of previous chronic otitis media, trauma, or iatrogenic causes.
11. Congenital cholesteatoma is typically an expanding cystic mass with keratinizing squamous epithelium located medial to the intact tympanic membrane, is assumed to be present at birth, but is usually diagnosed during infancy or in early childhood in patients with no prior history of otorrhea, perforation, or previous ear surgery.
12. A history of previous bouts of otitis media or an effusion does not exclude congenital cholesteatoma.
13. Congenital cholesteatoma is usually located at the anterosuperior quadrant of the middle ear. However, it may be located at the posterosuperior quadrant or other locations.
14. The clinical presentation of congenital cholesteatoma is determined by the location and extent of the lesion. It may be characterized by
 - ± a white mass medial to an intact tympanic membrane,
 - ± hearing loss when enlarged to fill the middle ear or erodes the ossicles,
 - ± extremely rarely with pain,
 and/or CT/MRI findings (usually as a round soft tissue mass at the anterosuperior quadrant, the posterosuperior quadrant, or other locations)
15. Cholesteatoma recidivism includes both residual and recurrent cholesteatoma. It is essential to differentiate them.
16. Residual cholesteatoma results from the incomplete surgical removal of the cholesteatoma matrix.
17. Recurrent cholesteatoma results from the reformation of the retraction pocket after a complete previous surgical cholesteatoma removal.
18. Cholesteatoma is classified into acquired, congenital, and unclassifiable (cholesteatoma whose origin cannot be accurately determined).

Acquired cholesteatoma is further subclassified into

1. retraction pocket cholesteatoma
 - a) pars flaccida (attic cholesteatoma)
 - b) pars tensa cholesteatoma
 - c) combination of pars flaccida and pars tensa cholesteatoma
2. non-retraction pocket cholesteatoma
 - a) cholesteatoma secondary to tympanic perforation (the so-called secondary acquired cholesteatoma)
 - b) cholesteatoma following trauma and/or otologic procedures

Post-surgical cholesteatoma may be residual or recurrent, although these are not mutually exclusive.

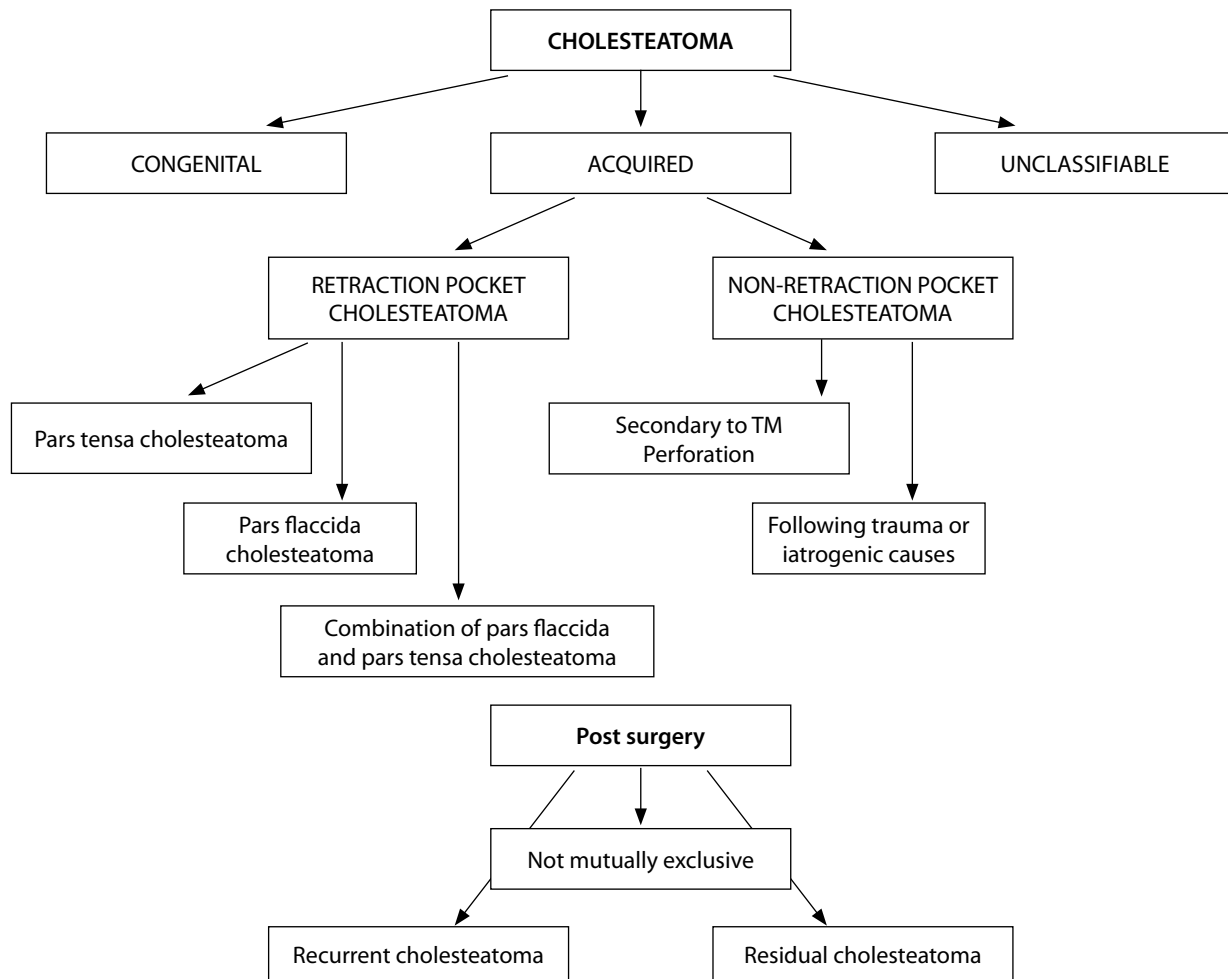


Figure 1. Schematic drawing of the clinical classification of middle ear cholesteatoma

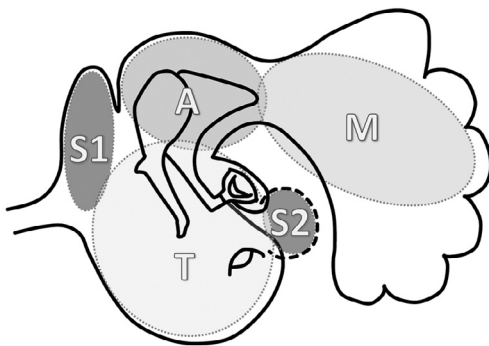


Figure 2. Divisions of the middle ear space using the STAM system

Staging of Middle Ear Cholesteatoma

1. Divisions of the middle ear space (STAM system)

In order to simplify the extent of cholesteatoma, the middle ear and mastoid space are divided into four sites: difficult access sites (S), tympanic cavity (T), attic (A), and mastoid (M). The difficult access sites (S) includes S1, the supratubal recess (also called the anterior epitympanum or protympanum) and S2, the sinus tympani. The posterior border of the attic is the posterior end of the incus short process or the fossa incudis. The mastoid includes the antrum and mastoid cells.

Divisions of the middle ear space using the STAM system is illustrated in Figure 2.

2. The EAONO/JOS staging system applies to four types of middle ear cholesteatoma

(Pars flaccida cholesteatoma, pars tensa cholesteatoma, congenital cholesteatoma, and cholesteatoma secondary to a tensa perforation)

Stage I: Cholesteatoma localized in the primary site*

* The site of cholesteatoma origin, i.e., the attic (A) for pars flaccida cholesteatoma; the tympanic cavity (T) for pars tensa cholesteatoma, congenital cholesteatoma, and cholesteatoma secondary to a tensa perforation

Stage II: Cholesteatoma involving two or more sites

Stage III: Cholesteatoma with extracranial complications or pathologic conditions including

Facial palsy,
Labyrinthine fistula: with conditions at risk of membranous labyrinth,
Labyrinthitis,
Postauricular abscess or fistula,
Zygomatic abscess,
Neck abscess,

Canal wall destruction: more than half the length of the bony ear canal,
Destruction of the tegmen: with a defect that requires surgical repair, and
Adhesive otitis: total adhesion of the pars tensa.

Stage IV: Cholesteatoma with intracranial complications including

Purulent meningitis,
Epidural abscess,
Subdural abscess,
Brain abscess,
Sinus thrombosis, and
Brain herniation into the mastoid cavity.

The staging system does not apply to petrous bone cholesteatoma.

3. Staging systems for respective cholesteatoma types

- 1) Pars flaccida cholesteatoma (attic cholesteatoma)
Stage I: Cholesteatoma localized in the attic
Stage II: Cholesteatoma involving two or more sites
Stage III: Cholesteatoma with extracranial complications
Stage IV: Cholesteatoma with intracranial complications
- 2) Pars tensa cholesteatoma, cholesteatoma secondary to a tensa perforation, and congenital cholesteatoma
Stage I: Cholesteatoma localized in the tympanic cavity
Stage II: Cholesteatoma involving two or more sites
Stage III: Cholesteatoma with extracranial complications
Stage IV: Cholesteatoma with intracranial complications

Background on the Collaboration Between EAONO and JOS on the Definitions, Staging, and Classification of Middle Ear Cholesteatoma

The European Academy of Otolology and Neurotology (EAONO) has previously published a document on the definitions and classification of cholesteatoma. They were published in 2015 and are summarized in Appendix 1^[1]. The statements were based on the Delphi consensus methodology involving the broad EAONO membership. At the same time, the Japan Otological Society (JOS) had been working independently on the "Classification and Staging of Cholesteatoma." Its recommendations were formulated by the JOS steering board alone and are summarized in Appendix 2^[2-15].

The respective steering group of EAONO and JOS decided to work together to produce a single consensus document on the "Definitions, Classification, and Staging of Middle Ear Cholesteatoma" to globalize the system. The first EAONO/JOS steering group meeting was held in 2015 at the 30th Politzer Society Meeting in Niigata. The final version of the "Joint EAONO/JOS Consensus on the Definitions, Classification, and Staging of Middle Ear Cholesteatoma" was the end product of many rounds of discussions and refinements over a 12-month period.

Formulation of a Joint EAONO/JOS Consensus on the Definitions, Classification, and Staging of Middle Ear Cholesteatoma

a. Methodology

Six European otologists of the original EAONO steering group (Matthew Yung, Ewa Olszewska, Nuri Özgürin, Holger Sudhoff, Jef Mulder, and Armağan İncesulu) and four Japanese otologists of the original JOS steering group (Tetsuya Tono, Masafumi Sakagami, Yutaka Yamamoto, and Hiromi Kojima) participated in the joint EAONO/JOS steering group to work on the consensus project. Collec-

tively, these 10 members produced the first draft of the document by consensus (Draft 1).

b. Consensus among steering group members (Draft 1):

1. Definitions of Cholesteatoma-The definitions provide terminologies in the description of cholesteatoma. Except for some minor changes in the narratives, the original EAONO statements on definitions of cholesteatoma were adopted. These changes include
 - The revised EAONO/JOS statement "Congenital cholesteatoma is usually located at the anterosuperior quadrant of the middle ear. However, it may be located at the posterosuperior quadrant or other locations" is an amendment to the original EAONO statement to reflect the fact that many congenital cholesteatomas in Japan were found at the posterosuperior quadrant.
 - The term "chronic otitis media with or without cholesteatoma" in the original 2015 EAONO document was dropped from the joint consensus as the term is not universally accepted.
2. Classification of Middle Ear Cholesteatoma-The classification categorized cholesteatoma into distinct categories to facilitate the comparison of surgical outcome across reports. The classification proposed originally by EAONO and JOS independently were compared, modified, and merged:
 - The terms "primary acquired" and "secondary acquired" were dropped as they are historical terms and are confusing. In the joint EAONO/JOS classification, acquired cholesteatoma was divided into retraction pocket cholesteatoma and non-retraction pocket cholesteatoma.
 - The joint EAONO/JOS classification applies only to "Middle Ear Cholesteatoma" as the inclusion of petrous cholesteatoma makes the classification and staging system too complex.
 - Cholesteatoma was classified as "congenital," "acquired," and "unclassifiable." The last category was not present in the original 2015 EAONO classification. In certain large or open cholesteatomas, it may not be possible to ascertain whether they are "congenital" or "acquired."
 - "Suspected congenital cholesteatoma" from the original JOS classification was dropped.
3. Staging of Middle Ear Cholesteatoma-The staging system reflects the severity of the cholesteatoma, the difficulty to achieve complete removal, and the subsequent restoration of the normal function. The EAONO/JOS steering group modified the original JOS staging system and adopted the new version as the EAONO/JOS staging system.
 - "Retraction pocket" was dropped from the original JOS staging system because it is not cholesteatoma by definition.
 - Stages 1 and 2 are based on sites of cholesteatoma involvement. Stage 2 represents the involvement of multiple sites.
 - The original sites of protympanum, tympanic cavity, attic, and mastoid proposed by JOS (symbolized as PTAM as illustrated in Figure 3) were changed to STAM (S1: supratubal recess, S2: sinus tympanum, tympanic cavity, attic, and mastoid) in the joint EAONO/JOS staging system.
 - Stage 3 represents extracranial extension, and stage 4 represents intracranial extension. These extensions are specified in the joint EAONO/JOS staging system.

International Feedback of the Proposed EAONO/JOS Consensus

The 10th International Conference on Cholesteatoma and Ear Surgery, June 5–8, 2016 (Chole2016) provided the opportunity for the EAONO/JOS steering group to gauge the international acceptance of the proposed EAONO/JOS “Definitions, Classification, and Staging of Middle Ear Cholesteatoma.” Over 1000 delegates from 54 countries attended Chole2016, with 23 national otology societies presenting mini-symposia. The EAONO/JOS steering group went through several rounds of international feedback assist in producing the final version.

- One month before Chole2016, the draft EAONO/JOS consensus document was sent to the presidents and/or the representatives of various national otology societies. Specific comments were received from the British Society of Otology, American Otological Society, Australian Otological Society, German HNO, and Canadian Otological Society. They were mostly in agreement with the EAONO/JOS proposal and only minor adjustments were made in response to these comments (Draft 2).
- Draft 2 of the EAONO/JOS consensus document was formally presented at a consensus session at Chole2016 (Staging and Classification of Cholesteatoma). The delegates present at the consensus session were given the chance to debate and comment on the definitions, classification, and staging of the proposed document section by section. Their feedback was recorded, considered, and refinement was made to the document (Draft 3).
- As it took a few days for the EAONO/JOS steering group to produce Draft 3 in response to the comments received at Chole2016, the delegates were invited to provide follow up feedback later on. Those agreed to be contacted again had their ID code (on the conference badge) scanned. Draft 3 was then sent to each international delegate together with a standardized feedback form electronically. Their approval/disapproval of Draft 3 and the reasons for disapproval were recorded.
- Analysis of international feedback on the “Definitions of Cholesteatoma” (Table 1).

Altogether, 47 international delegates provided follow up feedback on Draft 3. Of these, 3 were trainee otolaryngologists. Their responses were, therefore, excluded from the analysis.

Eighty-nine percent of the international delegates gave their approval to the statements on definition. Five (5) comments were given as the reason for disapproval:

- Reason given by one UK delegate: On Terminology-commented that the title should be specified as “Middle Ear Cholesteatoma.” The EAONO/JOS steering group agreed and made the change as suggested.
- Reason given by one Australian delegate: On Terminology-the term “middle ear and mastoid” in Statement 1 should be changed to “tympanic cavity and mastoid.” This was thought to be reasonable and change was made accordingly. The same delegate also proposed to incorporate petrous cholesteatoma as a form of congenital cholesteatoma. The EAONO/JOS steering group did not agree to making such a change because not all petrous cholesteatomas are congenital.

Table 1. International comments on EAONO/JOS Definitions of Cholesteatoma at Chole 2016 (44 responses)

Country	Number of responses	Approve proposed definitions	Disapprove proposed definitions
UK	7	6	1
Japan	8	8	0
Sweden	3	3	0
Australia	3	1	2
Bulgaria	2	2	0
Denmark	2	2	0
Netherlands	2	2	0
Italy	2	2	0
Poland	2	1	1
New Zealand	2	2	0
Switzerland	1	1	0
Brazil	1	0	1
Norway	1	1	0
Russia	1	1	0
Algeria	1	1	0
India	1	1	0
France	1	1	0
Singapore	1	1	0
South Africa	1	1	0
Vietnam	1	1	0
Spain	1	1	0
Total =	Total = 44	Total = 39 (89%)	Total = 5 (11%)

- No reason given from another Australian delegate.
- Reason given by one Polish delegate: On Terminology-the term “middle ear and mastoid” in Statement 1 should be changed to “tympanic cavity and mastoid.” This was thought to be reasonable and was amended accordingly.
- Reason given by one Brazilian delegate: Two of the statements in Draft 3 were repetitive and the delegate recommended one of them to be deleted. The EAONO/JOS agreed and deleted one of the statements.

All the above amendments were regarded as minor and the EAONO/JOS steering group felt that they did not change the essence of the “Definitions of Middle Ear Cholesteatoma.”

- Analysis of international feedback on the “Classification of Cholesteatoma” (Table 2).

It was very encouraging to see 98% of the international delegates gave their approval on the “Classification of Middle Ear Cholesteatoma.” The single comment provided by an Australian delegate that led to the disapproval was

- Advised relegating “cholesteatoma secondary to perforation” to “others” as it is rare. EAONO/JOS decided against making this change.

Table 2. International comments on the EAONO/JOS Classification of Cholesteatoma at Chole 2016 (44 responses)

Country	Number of responses	Approve proposed definitions	Disapprove proposed definitions
UK	7	7	0
Japan	8	8	0
Sweden	3	3	0
Australia	3	2	1
Bulgaria	2	2	0
Denmark	2	2	0
Netherland	2	2	0
Italy	2	2	0
Poland	2	2	0
New Zealand	2	2	0
Switzerland	1	1	0
Brazil	1	1	0
Norway	1	1	0
Russia	1	1	0
Algeria	1	1	0
India	1	1	0
France	1	1	0
Singapore	1	1	0
South Africa	1	1	0
Vietnam	1	1	0
Spain	1	1	0
Total =	Total = 44	Total = 43 (98%)	Total = 1 (2%)

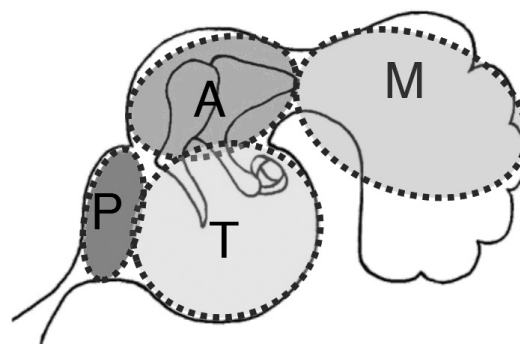
f. Analysis of international feedback on the “Staging of Cholesteatoma” (Table 3).

The EAONO/JOS Staging System on Middle Ear Cholesteatoma received most comments during the consensus session at Chole2016. The debate was mainly on whether it should be simple but easy to use, or more complex to include more prognostic factors. It was, therefore, not surprising that it received less consensus compared to the sections on definitions and classification. Nevertheless, 75% of the international delegates approved the staging system. There were 11 delegates who did not approve the proposed consensus on staging. Their comments were summarized into several themes:

1. The proposed EAONO/JOS staging system was thought by some to be too simplistic. Several responders suggested a TNM style staging system to incorporate other prognostic factors that may influence surgical outcome (Netherland, 1; UK, 1; Switzerland, 1; Norway, 1; and Algeria, 1). Several other responders suggested increasing the number of stages, i.e., more than 4 stages to accommodate more prognostic factors (UK, 1; Italy, 1; South Africa, 1.)
2. On the other hand, one responder (Australia, 1) proposed an alternative staging system that was even simpler than the EAONO/JOS staging system. This was at odds with the others who wanted a more complex system.

Table 3. International comments on the EAONO/JOS Staging of Cholesteatoma at Chole 2016 (44 responses)

Country	Number of responses	Approve proposed definitions	Disapprove proposed definitions
UK	7	5	2
Japan	8	8	0
Sweden	3	3	0
Australia	3	1	2
Bulgaria	2	1	1
Denmark	2	2	0
Netherland	2	1	1
Italy	2	1	1
Poland	2	2	0
New Zealand	2	2	0
Switzerland	1	0	1
Brazil	1	1	0
Norway	1	0	1
Russia	1	1	0
Algeria	1	0	1
India	1	1	0
France	1	1	0
Singapore	1	1	0
South Africa	1	0	1
Vietnam	1	1	0
Spain	1	1	0
Total =	Total = 44	Total = 33 (75%)	Total = 11 (25%)

**Figure 3.** Divisions of the middle ear space using the PTAM system

3. One responder (Bulgaria, 1) recommended changing the term “tensa perforation” to “tympanic perforation” to include pars flaccida as well. This was felt to be reasonable and the change was made accordingly.
4. One responder suggested incorporating petrous cholesteatoma back into the system (Australia, 1). The steering group did not make the change as it made the staging system even more complicated.

Amongst the 11 responders who did not give approval to the EAONO/JOS “Staging of Middle Ear Cholesteatoma,” most were concerned

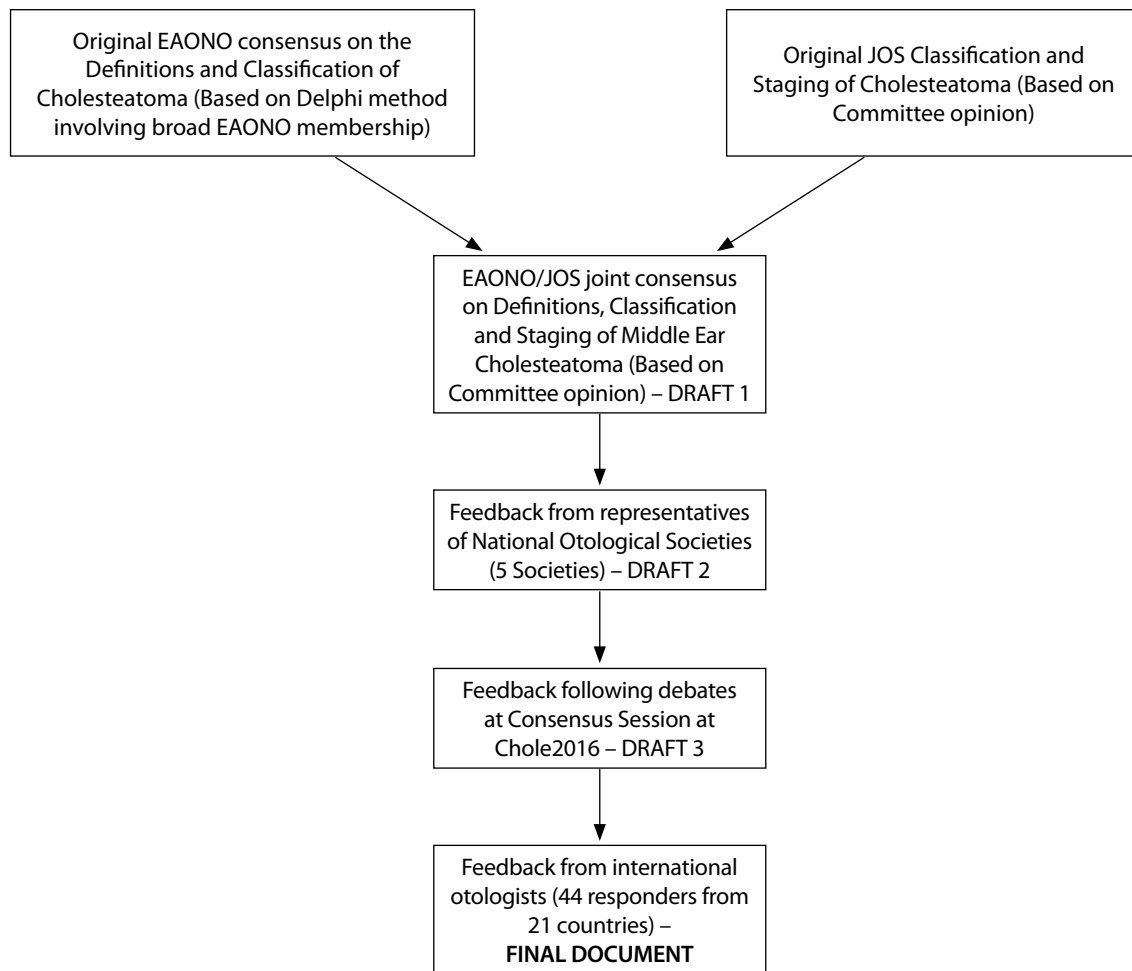


Figure 4. Schematic illustration of the consensus process of the joint EAONO/JOS document on the Definitions, Classification and Staging of Middle Ear Cholesteatoma

about its over-simplicity. Five out of eight recommended a TNM style system to incorporate other parameters such as ossicular status, mucosal status, and pneumatization of the mastoid cells. Three out of eight recommended increasing the number of stages within the system to incorporate extra parameters. However, these responders could not agree as to which parameters should be included as there is a lack of evidence or consensus in the literature. The EAONO/JOS steering group felt that a more complex staging system may result in even more controversy. Therefore, the staging system was kept simple at this stage and other prognostic factors may be incorporated in the future only if they are supported by evidence.

The method in reaching the final version of the EAONO/JOS consensus document is summarized in Figure 4.

Plan for the future

The “EAONO/JOS Consensus on Definitions of Middle Ear Cholesteatoma” received 89% international approval. Minor alterations were made that did not alter the essence of the document. The final “EAONO/JOS Consensus Document on the Classification of Middle Ear Cholesteatoma” received almost universal international approval (98%). The “EAONO/JOS Staging System on Middle Ear Cholesteatoma” had a majority of international approval (75%). Some international otologists wanted

to see more prognostic factors incorporated into the staging system. In response to this criticism, the EAONO/JOS steering group plans to set up an “International Otology Outcome Working Group” under the auspices of the Politzer Society. The aim of that group is to agree on a minimum common otology data set that the international otology community can use to evaluate their surgical outcomes. The steering group will facilitate multi-center studies with a large database to identify relevant prognostic factors that could be incorporated into a future revised EAONO/JOS staging system. Such parameters will then be based on evidence and not on personal opinion or sentiment.

Peer-review: Externally peer-reviewed.

Author Contributions: Concept – M.Y., T.T., E.O., Y.Y., H.S., M.S., J.M., H.K., A.I., F.T., N.Ö.; Design – M.Y., T.T., E.O., H.S., J.M., H.K., N.Ö.; Supervision – M.Y., T.T., N.Ö.; Resources – M.Y., F.T., N.Ö.; Data Collection and/or Processing – M.Y., T.T., E.O., Y.Y., H.S., M.S., J.M., N.Ö.; Analysis and/or Interpretation – M.Y., T.T., E.O., Y.Y., H.S., M.S., J.M., N.Ö.; Literature Search – E.O.; Writing Manuscript – M.Y., T.T., E.O.; Critical Review – M.Y., T.T., E.O., Y.Y., H.S., M.S., J.M., H.K., A.I., F.T., N.Ö.

Acknowledgements: The JOS staging system has been developed mainly through the committee based consensus process, with the current committee members, Tetsuya Tono, Masafumi Sakagami, Yutaka Yamamoto, Hiromi Kojima, Keiji Matsuda, Manabu Komori, Naohito Hato, Yuka Morita and Sho Hashimoto and the former committee members, Makito Okamoto, Masaru

Aoyagi, Tsukasa Ito, Hiroshi Hosoi, Takashi Nakagawa, Taeko Okuno, Yasuyuki Hinohira and Yasuo Mishiro. They acknowledge the contribution of JOS members to the vigorous cultivation of the JOS staging system over the past eight years. The criteria set has been approved by the JOS Board of Directors.

Conflict of Interest: No conflict of interest was declared by the authors.

Financial Disclosure: Credit is given to Professor Naoaki Yanagihara for initiating the collaboration between EAONO and JOS.

REFERENCES

1. Olszewska E, Rutkowska J, Özgirgin N. Consensus-Based Recommendations on the Definition and Classification of Cholesteatoma. *J Int Adv Otol* 2015; 11: 81-7. [\[CrossRef\]](#)
2. Matsuda K, Tono T, Kojima H, Yamamoto Y, Sakagami M, Mishiro Y, et al. Practicality analysis of the staging system proposed by the Japan Otological Society for acquired middle ear cholesteatoma: A multicenter study of 446 surgical cases in Japan. *Auris Nasus Larynx* 2016.
3. Kojima H, Yohsida R, Shiwa M, Tanaka Y, Moriyama H. Evaluation of Classification and Staging of Cholesteatoma proposed in 2008 (Japan Otology Society) in pars flaccida cholesteatoma. *Otol Jpn* 2010; 20: 677-83.
4. Ota T, Matsui K, Kure K, Naitou S, Miyoshi Y. Evaluation of the hearing results after tympanoplasty according to the classification of the development degree for attic cholesteatoma. *Otol Jpn* 2010; 20: 164-72.
5. Kitahara T, Mishiro Y, Sakagami M, Kamakura T. Staging-based surgical results in chronic otitis media with cholesteatoma. *Nippon Jibiinkoka Gakkai Kaiho* (Tokyo) 2012; 115: 91-100. [\[CrossRef\]](#)
6. Morita Y, Yamamoto Y, Oshima S, Takahashi K, Nemoto M, Kuwabara Y, et al. Comparison of pathology between pars flaccida cholesteatoma and pars tensa cholesteatoma based on the staging criteria for cholesteatoma 2010 Japan. *Otol Jpn* 2013; 24: 113-7.
7. Hasegawa K, Kunimoto Y, Yazama H, Kuya J, Kitano H. Hearing evaluation after cartilage tympanoplasty for acquired cholesteatoma. *Otol Jpn* 2014; 24: 233-9.
8. Yoshida T, Sone M, Kato K, Nakashima T. An analysis of primary acquired middle ear cholesteatoma. *Otol Jpn* 2014; 24: 227-32.
9. Morita Y, Yamamoto Y, Oshima S, Takahashi K, Nemoto M, Kuwabara Y, et al. Comparison of surgical treatment and outcomes between pars flaccida cholesteatoma and pars tensa cholesteatoma based on the staging criteria for cholesteatoma 2010 Japan. *Otol Jpn* 2014; 24: 181-7.
10. Hasegawa K, Kunimoto Y, Yazama H, Kuya J, Kitano H. Hearing evaluation after cartilage tympanoplasty for acquired cholesteatoma. *Otol Jpn* 2014; 24: 233-9.
11. Yamamoto Y. Current state of usage of the Classification and Staging System of Cholesteatoma proposed by the Japan Otological Society. *Otol Jpn* 2015; 25: 160-3.
12. Sato S, Suzuki R, Ohno T, Yoshida A. Evaluation of hearing after tympanoplasty for pars tensa cholesteatoma according to Japan Otological Society guidelines. *Otol Jpn* 2015; 25: 19-24.
13. Miyahara N, Fukushima N, Hirai T, Miyoshi A, Ariki M. Clinical features of the pediatric acquired cholesteatoma based on the Staging Criteria for Cholesteatoma 2010 Japan. *Nippon Jibiinkoka Gakkai Kaiho* (Tokyo) 2016; 119: 181-6. [\[CrossRef\]](#)
14. Morita Y, Yamamoto Y, Oshima S, Takahashi K, Takahashi S. Pediatric middle ear cholesteatoma: the comparative study of congenital cholesteatoma and acquired cholesteatoma. *Eur Arch Otorhinolaryngol* 2016; 273: 1155-60. [\[CrossRef\]](#)
15. Tono T, Sakagami M, Kojima H, Yamamoto Y, Matsuda K, Komori M, et al. Staging and classification criteria for middle ear cholesteatoma proposed by the Japan Otological Society. *Auris Nasus Larynx* in press, available online at <http://dx.doi.org/10.1016/j.anl.2016.06.012>. [\[CrossRef\]](#)

Appendix 1. EAONO Consensus Statements on the Definitions, Classification and Staging of Cholesteatoma[1]

The Delphi technique was used for the consensus methodology. It is a cyclical process of gathering information, summarizing, and re-submitting the revised statements to the same target population until a consensus is reached. Target agreement among the responders was set at a minimum of 80%, and the cycle of revision and re-submission of the statements were repeated until a consensus was reached on a majority of the statements.

A set of statements was developed by the EAONO steering group on the definitions and classification of cholesteatoma. The draft statements and a questionnaire were sent to the members of EAONO electronically, inviting them to state if they were in agreement with each individual statement and the reason for disagreement. Their responses were evaluated and modified using an online questionnaire and survey software.

The EAONO steering group evaluated the results of the survey and worked via the process of cognitive debriefing.

Out of 364 EAONO members, 123 responded to the first consensus cycle, 77 to the second cycle, and 53 to the third cycle. After three cycles, all statements concerning the definitions of cholesteatoma reached the target 80% consensus. However, the consensus on the classification of cholesteatoma was only 75%, and that on the staging of cholesteatoma was 66%. EAONO then decided to retain the section on definitions and make further revisions on the classification and staging system.

The following are the statements and degree of agreement on each statement of cholesteatoma definition, classification, and staging. These were published in the International Journal of Advanced Otolaryngology in 2015.¹

1. Acquired cholesteatoma is a subcategory of chronic otitis media (80% agreement).
2. Cholesteatoma is a mass formed by the keratinizing squamous epithelium in the middle ear and/or mastoid and subepithelial connective tissue and by the progressive accumulation of keratin debris with/without a surrounding inflammatory reaction (95% agreement).
3. Acquired cholesteatoma is characterized by clinical symptoms that are the result of growth with/without the destruction of adjacent structures:
 - ⇒ tympanic membrane perforation,
 - ⇒ otorrhea,
 - ⇒ hearing deterioration,
 and/or CT/MRI findings (soft tissue masses, focal areas of bony erosion of the middle ear and mastoid) (95% agreement).
4. The term "chronic otitis media with or without cholesteatoma" is appropriate (84% agreement).
5. Cholesteatoma consists of the following: matrix (keratinizing squamous epithelium), perimatrix (varying thickness of subepithelial connective tissue), and keratin debris (97% agreement).
6. The pathophysiology of cholesteatoma is not completely understood (91% agreement).
7. Recurrent infections and inflammatory reactions at the subepithelial connective tissue of cholesteatoma contribute to bone resorption in the adjacent area (88% agreement).
8. Cholesteatoma is diagnosed with a detailed otologic history and a physical examination with otoscopy and/or otomicroscopy with or without imaging (86% agreement).
9. Cholesteatoma is classified into the following two general categories: congenital and acquired (95% agreement).
10. Acquired cholesteatoma is associated with a perforation or a retraction pocket of the tympanic membrane, implantation from trauma, or iatrogenic causes (93% agreement).
11. Acquired cholesteatoma with a ear drum perforation develops from the extension of keratinizing squamous epithelium of the tympanic membrane or external ear canal into the middle ear and/or mastoid (90% agreement).
12. Acquired cholesteatoma with a retraction pocket originates from the external layer of the tympanic membrane retraction pocket when the retraction pocket loses its ability of self-cleaning and starts accumulating keratin debris (97% agreement).
13. Acquired cholesteatoma is not present at birth (93% agreement).
14. Acquired cholesteatomas may be primary or secondary (95% agreement).
15. Primary acquired cholesteatoma develops from the retraction pocket of the pars flaccida, pars tensa, or both and is a sequela of the dysfunction of the regulation of middle ear pressure (86% agreement).
16. Secondary acquired cholesteatoma may develop secondary to a tympanic membrane perforation as a result of acute or chronic otitis media and ear trauma or it may be iatrogenic (93% agreement).
17. Congenital cholesteatoma is an expanding cystic mass with keratinizing squamous epithelium located medial to the intact tympanic membrane, is assumed to be present at birth, but is usually diagnosed during infancy or in early childhood in patients with no prior history of otorrhea, perforation, or previous ear surgery (95% agreement).
18. A history of previous bouts of otitis media or an effusion does not exclude congenital cholesteatoma (97% agreement).
19. Congenital cholesteatoma is usually located at the anterosuperior quadrant of the middle ear. However, it may be located at the posterosuperior quadrant or at other intracranial locations (93% agreement).
20. The clinical presentation of congenital cholesteatoma is determined by the location and extent of the lesion. It may be characterized by the following:
 - ⇒ abnormal otoscopic examination (white mass medial to the intact tympanic membrane),
 - ⇒ rare conductive hearing loss when enlarged to fill the middle ear or erosion of the ossicles,
 - ⇒ pain (extremely rare),
 and/or CT/MRI findings (usually as a round soft tissue mass at the anterosuperior quadrant, rarely with bony erosion) (93% agreement).
21. Pre-cholesteatoma is a stage of the retraction pocket with/without invisible depth or partially visible depth, with/without bony erosion, with early signs of the loss of self-cleaning ability without an apparent accumulation of keratin debris (91% agreement).
22. Cholesteatoma recidivism may be either from residual or recurrent cholesteatoma (95% agreement).
23. Residual cholesteatoma results from the incomplete surgical removal of the epidermal matrix of cholesteatoma (97% agreement).
24. Recurrent cholesteatoma occurs after complete surgical removal as a result of a new pathological process of the tympanic membrane or the dysfunction of the regulation of middle ear pressure (91% agreement).
25. Cholesteatoma recurrence is the redevelopment of cholesteatoma at the same site or at another site after previous surgical removal. It occurs after a period of time during which no cholesteatoma can be detected (97% agreement).
26. The following new classifications of cholesteatoma proposed by the authors based on systemic search of evidence are useful in clinical practice (75% agreement only):
 - Acquired attic cholesteatoma: retraction or perforation of the pars flaccida or Shrapnell's membrane; cholesteatoma extending to the attic and passing through the aditus and eventually reaching the antrum, mastoid, or tympanic cavity
 - Acquired tympanic sinus cholesteatoma: retraction or perforation of posterior-superior pars tensa; cholesteatoma extending to the tympanic sinus and posterior portion of the tympanic membrane
 - Acquired tensa cholesteatoma: retraction, perforation, or total adhesion of the pars tensa of the tympanic membrane involving the tympanic orifice of the auditory tube

Appendix 1. EAONO Consensus Statements on the Definitions, Classification and Staging of Cholesteatoma[1] (Continue)

- Congenital cholesteatoma: cholesteatoma located medial to the intact tympanic membrane
- Recurrent/residual cholesteatoma: redevelopment of cholesteatoma at the same site or in another location after previous surgical removal

27. The following new clinical staging system for cholesteatoma proposed by the authors based on a systemic search of evidence is useful in clinical practice (66% agreement only):

Stage I: middle ear and mastoid cell system involved cholesteatoma without bone erosion.

Stage II: cholesteatoma causes temporal bone erosion without the following complications: 1. facial palsy, 2. intracranial complication, 3. labyrinthine fistulae, 4. large defect of the bony external ear canal, 5. profound sensorineural hearing loss, and 6. total adhesion of the ear drum

Stage III: any cholesteatoma causing at least one of the following complications: 1. facial palsy, 2. intracranial complication, 3. labyrinthine fistulae, 4. large defect of the bony external ear canal, 5. profound sensorineural hearing loss, and 6. total adhesion of the ear drum

As statements 26 and 27 did not receive the target 80% agreement, they were dropped from the original EAONO statements.

Appendix 2. JOS Classification and Staging of Cholesteatoma

The Japan Otological Society (JOS) Steering Group was set up under the auspices of the JOS Committee on Nomenclature. The original version of the staging system was prepared in 2008 for pars flaccida (attic) cholesteatoma. The middle ear space was divided into four sites: protympanum (P), tympanic cavity (T), attic (A), and mastoid (M). Three stages were defined: Stage I-cholesteatoma confined to the attic or tympanic cavity; Stage II-cholesteatoma extends beyond the attic or the tympanic cavity; Stage III-intra- and/or extra-temporal complications are observed. Stages I and II can be further substaged according to the extension of cholesteatoma using the PTAM system. If the cholesteatoma has invaded the protympanum, attic, and mastoid antrum without causing any complications, it is described as "stage II PAM".

The staging systems for pars tensa cholesteatoma were subsequently developed in 2010 with the same principle. The multicenter study conducted by the steering group confirmed that there was a good correlation between the surgical outcome of cholesteatoma and the staging [1]. The system was initially designed exclusively for retraction pocket cholesteatoma, i.e., pars flaccida and pars tensa cholesteatomas. This was extended to include non-retraction cholesteatoma including cholesteatoma secondary to a tensa perforation and congenital cholesteatoma in a subsequent update. Because of the long history of the JOS staging system, they have been used for a number of clinical studies in Japan [2-14].

Original JOS Staging System for Middle Ear Cholesteatoma [15]**1. Divisions of the middle ear space: PTAM system (Figure 3)**

In order to simplify the extent of cholesteatoma, the tympanomastoid space is divided into four sections: protympanum, tympanic cavity, attic, and mastoid.

The protympanum includes the bony Eustachian tube and the supratubal recess. The tympanic cavity consists of the mesotympanum, hypotympanum, and retrotympanum including the tympanic sinus. The posterior border of the attic is the posterior end of the incus short process or fossa incudis. The mastoid includes the antrum and mastoid cells.

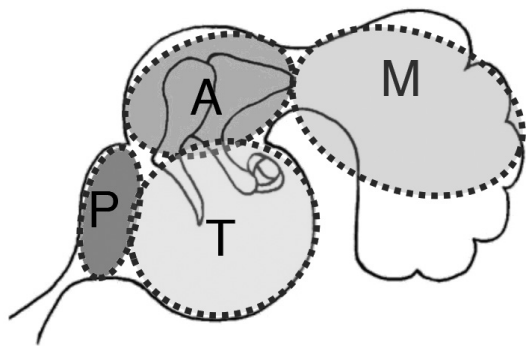


Figure 3. Divisions of the middle ear space using the PTAM system

2. Staging system applicable to the four types of cholesteatoma: pars flaccida cholesteatoma (attic cholesteatoma), pars tensa cholesteatoma, cholesteatoma secondary to a tensa perforation, and congenital cholesteatoma

Stage I: Cholesteatoma localized in the primary site*

*The site of cholesteatoma origin, i.e., the attic for pars flaccida cholesteatoma and the tympanic cavity for pars tensa cholesteatoma, congenital cholesteatoma, and cholesteatoma secondary to a tensa perforation.

Stage II: Cholesteatoma involving two or more sites

Stage III: Cholesteatoma with intratemporal and/or extracranial complications:

facial palsy; labyrinthine fistula: with conditions at risk for membranous labyrinth; labyrinthine disturbance: scale out BC values for more than two speech frequencies (0.5, 1, and 2 kHz); canal wall destruction: more than half the length of the bony ear canal; adhesive otitis: total adhesion of the pars tensa; petrous bone or skull base destruction (PB); and neck abscess.

Stage IV: Cholesteatoma with intracranial complications:

purulent meningitis, epidural abscess, subdural abscess, brain abscess, sinus thrombosis, etc.

3. Subclassification of stage I for respective cholesteatoma types

1) Pars flaccida cholesteatoma (attic cholesteatoma)

Stage I: Cholesteatoma localized in the attic

Stage Ia: A retraction pocket with epithelial self-cleaning function

Stage Ib: A retraction pocket with the persistent accumulation of keratin debris

2) Pars tensa cholesteatoma

Stage I: Cholesteatoma localized in the tympanic cavity

Stage Ia: A retraction pocket with epithelial self-cleaning function

Stage Ib: A retraction pocket with the persistent accumulation of keratin debris

3) Cholesteatoma secondary to a tensa perforation

Stage I: Cholesteatoma localized in the tympanic cavity

Stage Ia: Epithelial invasion confined to the underside of the pars tensa

Stage Ib: Epithelial invasion extending to the tensor tympani tendon and promontorial wall

4) Congenital cholesteatoma

Stage I: Cholesteatoma localized in the tympanic cavity

Stage Ia: Cholesteatoma confined to the anterior half of the tympanic cavity

Stage Ib: Cholesteatoma confined to the posterior half of the tympanic cavity

Stage Ic: Cholesteatoma involving both sides of the tympanic cavity