Neurol Med Chir (Tokyo) 51, 673～677, 2011

Cervical Unilateral Open-Door Laminoplasty With Titanium Miniplates Through Newly Designed Hydroxyapatite Spacers

—Technical Note—

Satoshi TANAKA,[1] Takashi TASHIRO,[1] Akira GOMI,[2] and Hiroshi UJIIE[3]

[1]Department of Neurosurgery, Shioya Hospital, International University of Health and Welfare, Yaita, Tochigi;
[2]Department of Pediatric Neurosurgery, Tochigi Children's Medical Center, Jichi Medical University, Shimotsuke, Tochigi;
[3]Department of Neurosurgery, Tokyo Rosai Hospital, Tokyo

Abstract

A newly designed hydroxyapatite (HA) spacer for cervical laminoplasty is provided with a hole through which the titanium miniplate is passed. A new method of unilateral open-door laminoplasty with titanium miniscrew and miniplate through this HA spacer is described. Twenty-two patients with cervical stenotic disorders were treated by this procedure. Only the predominantly affected side of the laminae is exposed. The supraspinous and interspinous ligaments and the deep muscle layer in the contralateral side are left intact. A 4-mm wide gutter near the intervertebral joint is made and contralateral hinges are made under the deep muscle layer with minimum detachment of these muscles. The opened lamina is fixed with the titanium miniplate passed through the hole in the newly designed HA spacer. Mean operative time for the 22 operations was 193.5 minutes. Mean enlargement of the minimum spinal canal diameter was 50.9%. Neurological outcomes after 3 months were evaluated according to the Japanese Orthopaedic Association (JOA) scoring. Mean recovery rate of JOA score by Hirabayashi's method was 49.5%. Only 2 patients reported postoperative axial neck pain. Our method for unilateral open-door laminoplasty provides adequate decompression and tight fixation of laminae, and is less invasive to the posterior supporting elements of cervical spine.

Key words: unilateral open-door laminoplasty, titanium miniplate, titanium miniscrew, hydroxyapatite spacer, axial pain

Introduction

Laminoplasty is widely used to avoid the disadvantages of cervical laminectomy, including postoperative spinal instability causing kyphotic deformity and recurrent spinal canal compression by postoperative laminectomy membrane.[1,2] Various cervical laminoplasty procedures are available including unilateral open-door laminoplasty,[4] bilateral open-door laminoplasty,[16] and en bloc laminoplasty[12] instead of laminectomy. To avoid complications such as postoperative C5 palsy due to posterior migration of the spinal cord and dislocation of instruments, avoidance of excessive decompression and tight fixation of reconstructed laminae are needed for cervical laminoplasty.[11,14] Preservation of the posterior cervical supporting elements, including the nuchal, supraspinous, and interspinous ligaments, has recently been emphasized to avoid postoperative axial nuchal pain and to maintain lordotic alignment of the cervical spine.[6,10,15] We have developed a newly designed hydroxyapatite (HA) spacer and a new technique for less invasive unilateral open-door laminoplasty which preserves many posterior supporting elements with titanium miniscrews and miniplates passed through a hole in the spacer.

Received February 28, 2011; Accepted June 14, 2011

Materials and Methods

The HA spacer (Apaceram B-4-99-8; HOYA Corp., PENTAX New Ceramics Division, Tokyo) is 8 mm



Fig. 1 Photographs of a hydroxyapatite spacer of 8-cm length with a hole (*upper left*) through which a titanium miniplate (*upper right*) with 6 miniscrew holes can pass (*lower row*).

Table 1 Summary of 22 patients treated by unilateral open-door laminoplasty with titanium miniplates and hydroxyapatite spacer

Age (years)	
range	40–92
mean ± SD	68.4 ± 14.1
Sex	
male	13
female	9
Disease	
cervical spondylosis	20
OPLL	2
No. of enlarged laminae	
2	1
3	5
4	15
Side	
right	11
left	11
Operation time (minutes)	
range	120–324
mean ± SD	193.5 ± 49.2
Preoperative minimum spinal canal diameter (mm)	
range	6–12
mean ± SD	9.5 ± 1.4
Postoperative minimum spinal canal diameter (mm)	
range	9–17
mean ± SD	14.3 ± 1.8
Expansion rate (%)	
range	30.0–88.9
mean ± SD	50.9 ± 16.6
Preoperative JOA score	
range	7–15
mean ± SD	11.5 ± 2.4
Postoperative JOA score	
range	8–17
mean ± SD	14.0 ± 2.5
Recovery rate (%)*	
range	11.1–100
mean ± SD	49.5 ± 28.8

*Recovery rate by Hirabayashi's method.[7] JOA: Japanese Orthopaedic Association, OPLL: ossification of the posterior longitudinal ligament, SD: standard deviation.

× 8 mm × 5 mm with 40% microporosity, and has a hole (Fig. 1 *upper left*) through which the titanium miniplate with 6 miniscrew holes (W. Lorenz 1.5 Neuro System; Medical U&A Inc., Osaka) can pass (Fig. 1 *upper right*).

A total of 22 patients with cervical stenotic myelopathy underwent unilateral open-door laminoplasty between July 2007 and April 2010. The patient characteristics and operative procedures are summarized in Table 1.

A posterior midline skin incision 4–5 cm in length is made according to the required level of laminoplasty. Only the paravertebral muscles in the opening side are dissected from the spinous processes to preserve the supraspinous and interspinous ligaments (Fig. 2A). Unilateral exposure of the laminae and the spinous processes is achieved through subperiosteal detachment of the muscles (Fig. 2B). After the opening side of the laminae is exposed, the spinous processes are cut near the base with a surgical saw and retracted together with the muscular and ligamentous structures to the closing side,[9] whereas the semispinalis cervicis and multifidus muscles are not detached from the closing side of the laminae (Fig. 2C). A high-speed drill with a 3-mm diamond burr is used to create a gutter at the junction of the lamina and the medial aspect of the lateral mass through the outer cancellous bone (Fig. 2D). On the closing side, a gutter that acts as a hinge is also formed under the deep muscle layer with minimum detachment of these muscles at the junction of the lamina and the lateral mass (Fig. 2E). A small portion of each lamina is shaved just medial to the cut edge for reunion with the spinous process (Fig. 2E). The middle and lateral parts of the lamina are opened with a Cloward type vertebral spreader. The open position of the posterior elements is stabilized using a 1.5 mm titanium miniplate passed through the HA spacer hole (Fig. 1 *lower row*). Four titanium miniscrews (5 mm long; W. Lorenz 1.5 Neuro System) are used for each plate (Fig. 3). The detached spinous process is attached to the shaved portion of the lamina with one miniscrew (Fig. 2F).

Results

Satisfactory decompression was achieved in all 22 cases of cervical stenotic myelopathy. Intraoperative blood loss was less than 50 ml in all operations. The narrowed spinal canal was decompressed under direct visualization. Extensive decompression was achieved as required by the titanium miniplates with 6 holes passed through the HA spacer. Fixation of the opened laminae by 4 miniscrews per miniplate was very rigid. No hardware failure or miniscrew

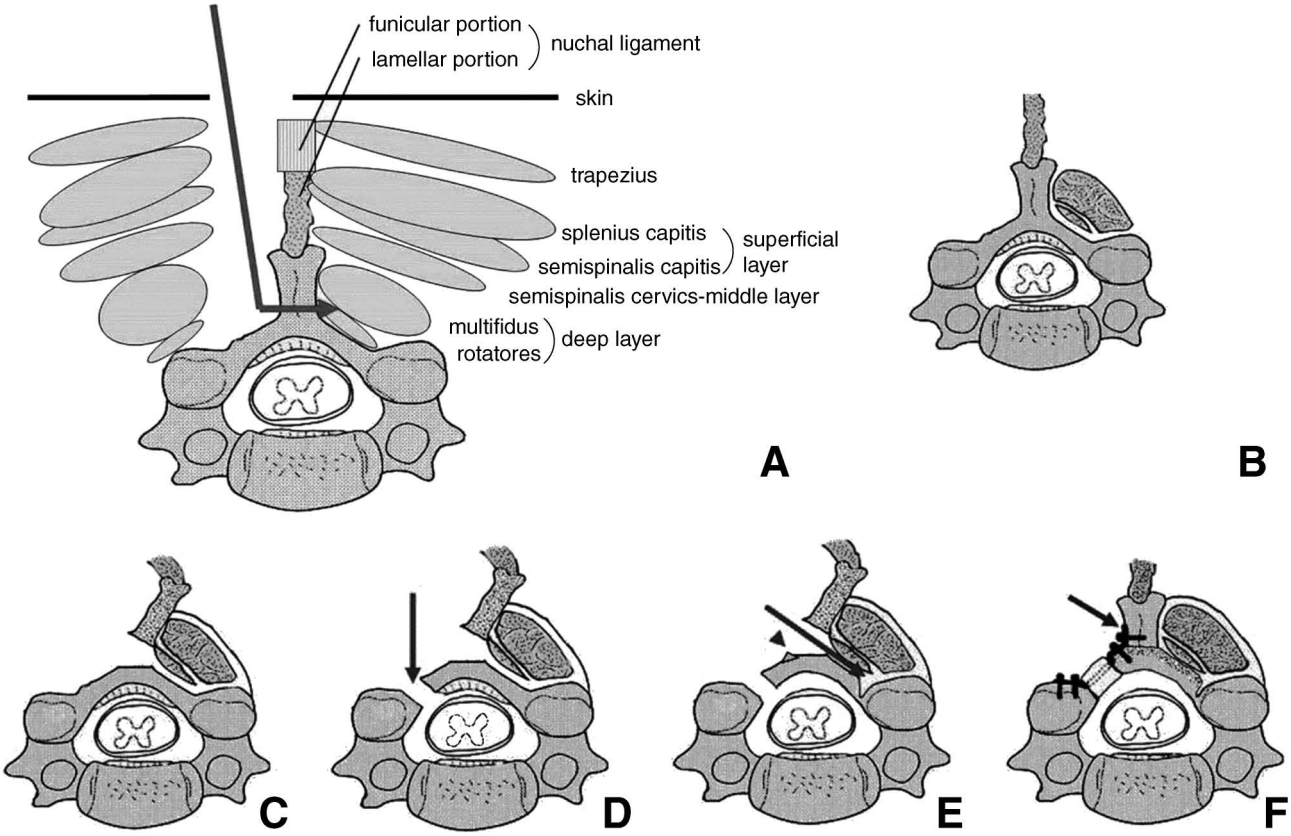

Fig. 2 Schematic drawing illustrating the operative approach of unilateral open-door laminoplasty with titanium miniplates through the hydroxyapatite spacer. A: Route of unilateral open-door laminoplasty. The contralateral paravertebral muscles were completely preserved and not injured. B: Unilateral exposure of the laminae and the spinous processes is achieved through subperiosteal detachment of the muscles. C: The spinous processes are cut near the base with the surgical saw and retracted with muscular and ligamentous structures to the closing side altogether. D: A high-speed drill with a 3-mm diamond burr is used to create a gutter at the junction of the lamina and the medial aspect of the lateral mass (*arrow*) through the outer cancellous bone. E: On the closing side, a gutter that acts as a hinge is also formed under the deep muscle layer at the junction of the lamina and the lateral mass (*arrow*). A small portion of each lamina is shaved just medial to the cut edge for reunion with the spinous process (*arrowhead*). F: The open position of the posterior elements is stabilized using 1.5 mm titanium miniplates with 6 miniscrew holes passed through the hole in the hydroxyapatite spacer. The detached spinous process is attached to the shaved portion of the lamina with one miniscrew (*arrow*).

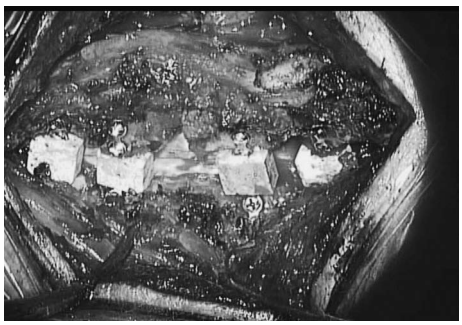

Fig. 3 Intraoperative photograph demonstrating C3–C6 unilateral right-sided open-door laminoplasty with 4 titanium miniplates and 16 titanium miniscrews through 4 hydroxyapatite spacers.

loosening occurred in any patient during the follow-up period ranging from 13 to 45 (mean 36.3) months. No disorder caused by cervical spine alignment such as kyphosis or lordosis has occurred.

Neurological and neuroradiological outcomes of our unilateral open-door laminoplasty are summarized in Table 1. The mean recovery rate 3 months after the operation based on the Japanese Orthopaedic Association score by Hirabayashi's method[7] was 49.5 ± 28.8%. Postoperative computed tomography demonstrated that the reconstructed laminae and spinous processes were in satisfactory positions (Fig. 4). Neuroimaging findings obtained in all 22 patients who underwent unilateral open-door laminoplasty with titanium miniplates through

Fig. 4 Early postoperative three-dimensional computed tomography scan revealing spinal stabilization achieved using titanium miniplates through hydroxyapatite spacers. The replaced spinous processes are positioned along the midline axis.

HA spacers are also summarized in Table 1. The average minimum sagittal canal diameter area increased by 50.9%.

One patient had postoperative newly developed C5 palsy on the opening side but this neurological complication had resolved by 3 months after the operation. Only 2 patients complained at the outpatient clinic of postoperative axial neck pain and/or stiffness 3 months after surgery. No patient reported severe neck pain and/or stiffness that disturbed the activities of daily living.

Discussion

Numerous modified laminoplasty procedures have been reported since open-door laminoplasty was described.[4] Unilateral open-door laminoplasty using a titanium mini-plate and miniscrews achieves unilateral exposure of the laminae and spinous processes sparing the interspinous and supraspinous ligaments.[13] Each lamina is lifted by a contralateral laminar fracture without hinge formation. The open position of the posterior elements is stabilized using titanium miniplates and miniscrews. Although unilateral exposure of the affected laminae is less invasive, contralateral laminar fracture is unstable and dangerous in our experience. To prevent instability of the contralateral lamina fracture, we made a hinge on the contralateral lamina under the muscles without exposing the contralateral lamina.

Bilateral open-door laminoplasty with titanium miniplates and titanium miniscrews uses autologous bone graft between the opened laminae.[14] However, this method seems to be invasive because of fibular or iliac bone removal and bilateral opening. Since many patients have complained of iliac pain after spinal surgery, autologous bone graft has not been widely used in spinal surgery.

HA ceramic is a widely used material in orthopedic and neurosurgical operations.[12] The merit of HA ceramic is the strong ability to bond directly with bone, especially if the HA has high microporosity.[5] This material is also biostable and biocompatible. Bone bonding and ingrowth into porous HA spacers has been verified. However, high microporosity HA ceramic is more fragile than low microporosity HA. This disadvantage of the high microporosity HA spacer was compensated by co-use of the titanium miniplate in our series.

A HA spacer with small holes for titanium miniscrews was used in bilateral open-door laminoplasty.[16] The titanium miniscrews were directly fixed to the laminae through the holes in the spacers. HA may have been too fragile for use of titanium miniscrews in this method.[3] Tiny cracks in the spacers sometimes occurred if the miniscrews were fastened too tightly. Thus, the titanium miniscrew could not be tightly fixed to the spacer since miniscrew fastening was stopped immediately when the miniscrewhead came into contact with the spacer and the hole in the spacer.

Bilateral laminoplasty with HA laminar spacers and titanium miniplates reattached the completely removed lamina with spinous process to the bilateral lateral parts of the lamina with miniplates over two HA spacers.[3] Although the lamina and miniplate were tightly fixed with titanium miniscrews, HA spacers were tied to the miniplates using No. 1–0 nylon suture. In this method, the unsuitability of HA ceramic for fixation with titanium miniscrews was a major problem. Serious postoperative complications have been reported after laminoplasty with HA spacers affixed with nylon sutures.[8] Four cases of delayed dural lacerations were caused by HA spacers which led to tetraparesis following double-door laminoplasty occurred in 130 patients. The spacer must be firmly fixed to the lamina or spinous process with stronger suture materials to avoid injury to the spinal cord.

Recently, a newly designed box-shaped spacer with two arms for fixation entirely made from titanium has been used.[17] Hyperostosis around HA spacers may cause stenosis of the spinal canal and exacerbation of neurological symptoms. Although this titanium spacer with two arms has not been legally approved yet in Japan, this design seems to be very useful for both unilateral and bilateral open-door laminoplasty.

Our method of unilateral open-door laminoplasty

by unilateral exposure of the affected laminae seems to be less invasive because of preservation of the attachment of the contralateral semispinalis cervicis and multifidus muscles. A technique for exposure of the cervical spine laminae has been described in which the attachments of the semispinalis cervicis and multifidus muscles to the spinous process were left untouched.[15] Myoarchitectonic spinolaminoplasty can preserve these bilateral muscles by cutting inside the spinous process.[10] Preservation of posterior cervical supporting elements has recently been emphasized to avoid postoperative axial nuchal pain and to maintain lordotic alignment of the cervical spine.[6]

References

1) Albert TJ, Vacarro A: Postlaminectomy kyphosis. *Spine (Phila Pa 1976)* 23: 2738–2745, 1998
2) Epstein JA: The surgical management of cervical spinal stenosis, spondylosis, and myeloradiculopathy by means of the posterior approach. *Spine (Phila Pa 1976)* 13: 864–869, 1988
3) Goto T, Ohata K, Takami T, Nishikawa M, Tsuyuguchi N, Morino M, Matusaka Y, Nishio A, Inoue Y, Hara M: Hydroxyapatite laminar spacers and titanium miniplates in cervical laminoplasty. *J Neurosurg* 97(3 Suppl): 323–329, 2002
4) Hirabayashi K, Watanabe K, Wakano K, Suzuki N, Satomi K, Ishii Y: Expansive open-door laminoplasty for cervical spinal stenotic myelopathy. *Spine (Phila Pa 1976)* 8: 693–699, 1983
5) Hoogendoorn HA, Renooij W, Akkermans LM, Visser W, Wittebol P: Long-term study of large ceramic implants (porous hydroxyapatite) in dog femora. *Clin Orthop Relat Res* (187): 281–288, 1984
6) Hosono N, Yonenobu K, Ono K: Neck and shoulder pain after laminoplasty. A noticeable complication. *Spine (Phila Pa 1976)* 21: 1969–1973, 1996
7) Japanese Orthopaedic Association: [Japanese Orthopaedic Association scoring system for cervical myelopathy (17–2 version and 100 version)]. *Nippon Seikeigeka Gakkai Zasshi* 68: 490–503, 1994 (Japanese with English translation)
8) Kanemura A, Doita M, Iguchi T, Kasahara K, Kurosaka M, Sumi M: Delayed dural laceration by hydroxyapatite spacer causing tetraparesis following double-door laminoplasty. *J Neurosurg Spine* 8: 121–128, 2008
9) Kihara S, Umebayashi T, Hoshimaru M: Technical improvements and results of open-door expansive laminoplasty with hydroxyapatite implants for cervical myelopathy. *Neurosurgery* 57(4 Suppl): 348–356, 2005
10) Kim P, Murata H, Kurokawa R, Takaishi Y, Asakuno K, Kawamoto T: Myoarchitectonic spinolaminoplasty: efficacy in reconstituting the cervical musculature and preserving biomechanical function. *J Neurosurg Spine* 7: 293–304, 2007
11) Kimura S, Homma T, Uchiyama S, Yamazaki A, Imura K: Posterior migration of cervical spinal cord between split laminae as a complication of laminoplasty. *Spine (Phila Pa 1976)* 20: 1284–1288, 1995
12) Koyama T, Handa J: Cervical laminoplasty using apatite beads as implants. Experiences in 31 patients with compressive myelopathy due to developmental canal stenosis. *Surg Neurol* 24: 663–667, 1985
13) Roselli R, Pompucci A, Formica F, Restuccia D, Di Lazzaro V, Valeriani M, Scerrati M: Open-door laminoplasty for cervical stenotic myelopathy: surgical technique and neurophysiological monitoring. *J Neurosurg* 92(1 Suppl): 38–43, 2000
14) Shaffrey CI, Wiggins GC, Piccirilli CB, Young JN, Lovell LR: Modified open-door laminoplasty for treatment of neurological deficits in younger patients with congenital spinal stenosis: analysis of clinical and radiographic data. *J Neurosurg* 90(2 Suppl): 170–177, 1999
15) Shiraishi T: A new technique for exposure of the cervical spine laminae. Technical note. *J Neurosurg* 96(1 Suppl): 122–126, 2002
16) Takayasu M, Takagi T, Nishizawa T, Osuka K, Nakajima T, Yoshida J: Bilateral open-door cervical expansive laminoplasty with hydroxyapatite spacers and titanium screws. *J Neurosurg* 96(1 Suppl): 22–28, 2002
17) Tani S, Suetsua F, Mizuno J, Uchikado H, Nagashima H, Akiyama M, Isoshima A, Ohashi H, Hirano Y, Abe T: New titanium spacer for cervical laminoplasty: initial clinical experience. Technical note. *Neurol Med Chir (Tokyo)* 50: 1132–1136, 2010

Address reprint requests to: Satoshi Tanaka, MD, Department of Neurosurgery, Shioya Hospital, International University of Health and Welfare, 77 Tomita, Yaita, Tochigi 329–2165, Japan.
e-mail: stanaka-nsu@umin.net