Case Report
http://dx.doi.org/10.6065/apem.2012.17.4.258
Ann Pediatr Endocrinol Metab 2012;17:258-261

Annals of Pediatric Endocrinology & Metabolism
apem

A Case of Type 2 Diabetes Mellitus in Adolescent Presenting with Bell's Palsy

Tai Sung Kim, M.D.,
Won Kyung Cho, M.D.,
Kyoung Soon Cho, M.D.,
So Hyun Park, M.D.,
Seung Hoon Hahn, M.D.,
Min Ho Jung, M.D. and
Byung Kyu Suh, M.D.

Department of Pediatrics,
Bucheon St. Mary's Hospital,
The Catholic University of Korea
School of Medicine, Bucheon, Korea

Bell's palsy is manifested by unilateral facial paralysis, but its cause is not clearly elucidated yet. Though the relationship between Bell's palsy and diabetes mellitus (DM) has been well established in adults, the relationship is not obvious in children and adolescents. Here, we report a case of adolescent Bell's palsy accompanied by DM. In this case, steroids were used for the treatment of Bell's palsy, and the blood glucose level in the patients was well controlled by metformin alone without additional use of insulin. We suggest that the presence of diabetes should be determined by blood test in the childhood and adolescent patients with facial paralysis, especially who are obese. As the use of steroids, however, is associated with the elevated blood glucose levels, it should be used with caution.

Key Words: Bell palsy; Diabetes mellitus; Adolescent

Introduction

Bell's palsy is an idiopathic, acute peripheral-nerve palsy involving the facial nerve, which innervates all the muscles of facial expression, and is named after Sir Charles Bell, who first described the syndrome along with the anatomy and function of the facial nerve1). The annual incidence of Bell's palsy is 15 to 30 per 100,000 persons, with equal numbers of men and women affected[1)] and it accounts for 60 to 75 percent of all cases of unilateral facial paralysis[2)]. The median onset age is 40 years, but the disease may occur at any age[3)]. The incidence is lowest in children under 10 years old, increases from the ages of 10 to 29, remains stable at the ages of 30 to 69, and is highest in people over the age of 70[4)].

The relationship between Bell's palsy and diabetes mellitus (DM) in adult is well known[5)]. And the impaired glucose tolerance is associated with Bell's palsy, and oral glucose tolerance test could identify patients with impaired glucose tolerance among the patients with Bell's palsy[6)]. But, the relationship between adolescent DM and Bell's palsy has not been addressed yet.

We report a case of a 15-year-old male patient who had been diagnosed as DM while being under inpatient investigation for facial paralysis.

Case Report

Patient: male, 15 years old
Chief complaint: right facial paralysis
Past history: no specific findings
Birth history: 3.6 kg, full-term delivery, cesarean delivery
Present illness: He visited our institution for the test and treatment of right facial paralysis which had occurred 2 days prior to visit.

Received: 5 December, 2012
Revised: 20 December, 2012
Accepted: 20 December, 2012

Address for correspondence:
Kyoung Soon Cho, M.D.
Department of Pediatrics,
Bucheon St. Mary's Hospital, The Catholic University of Korea School of Medicine, 327 Sosa-ro 327 beon-gil, Wonmi-gu, Bucheon 420-717, Korea
Tel: +82.32-340-9065
Fax: +82.32-340-2673
E-mail: soon926@hanmail.net

ISSN: 2287-1012(Print)
ISSN: 2287-1292(Online)

Physical examination: His height was 165 cm (50 percentile), the weight was 115 kg (>97 percentile), systolic blood pressure was measured 150 mmHg (>97 percentile), and diastolic blood pressure was measured 100 mmHg (>97 percentile). The body mass index was 42 kg/m^2 with normal vital signs and good general condition. There was no specific finding other than the symptom of right facial paralysis.

Laboratory findings: On the first visit, his blood glucose level was 319 mg/dL with elevated levels of aspartate aminotransferase (AST) and alanine aminotransferase (ALT) (102 U/L [reference, 0-40 U/L], and 180 U/L [reference, 0-40 U/L], respectively). Another test as an inpatient suggested following results: fasting glucose 293 mg/dL, HbA1c 8.4% (reference, 4.1-6.5%), negative for anti-glutamic acid decarboxylase (GAD) antibody, negative for insulin antibody, negative for islet cell antibody, fasting insulin 57 μU/mL (reference, 7-24 μU/mL), fasting C-peptide 13 ng/mL (reference, 0.64-2.83 ng/mL), 2-hour postprandial insulin 105 μU/mL (reference, 16-166 μU/mL), 2-hour postprandial C-peptide 15 ng/mL (reference, 3.2-6.6 ng/mL). Postprandial laboratory values were measured at 2 hours after normal meal. Based on these, he was diagnosed as type 2 DM. With the presence of type 2 DM, high blood pressure and the increase of BMI revealed the patient's metabolic syndrome.

On the brain magnetic resonance imaging (MRI) scan, focal dense contrast was detected at the distal region of internal auditory canal, but no other specific finding was observed (Fig.1). And, there was right facial peripheral neuropathy in electromyography (EMG) (Table 1), therefore the case could be diagnosed as Bell's palsy. Hypercholesterolemia was observed: total cholesterol 271 mg/dL (reference, 120-240 mg/dL), low density lipoprotein (LDL) cholesterol 183 mg/dL (reference, 60-160 mg/dL), high density lipoprotein (HDL) cholesterol 36 mg/dL (reference, 35-65 mg/dL), and triglyceride 183 mg/dL (reference, 30-200 mg/dL). Hepatitis A virus immunoglobulin M (HAV IgM), hepatitis B surface antigen B (HBs Ag), and hepatitis C antibody (HCV antibody) were noted as negative. The liver ultrasonography performed due to elevated liver enzyme levels suggested severe diffuse increase in fine echoes of the liver implying severe fatty liver. Increased levels of liver enzymes are probably attributed to the fatty liver considering the negative findings in HAV IgM, HBs Ag and HCV antibody.

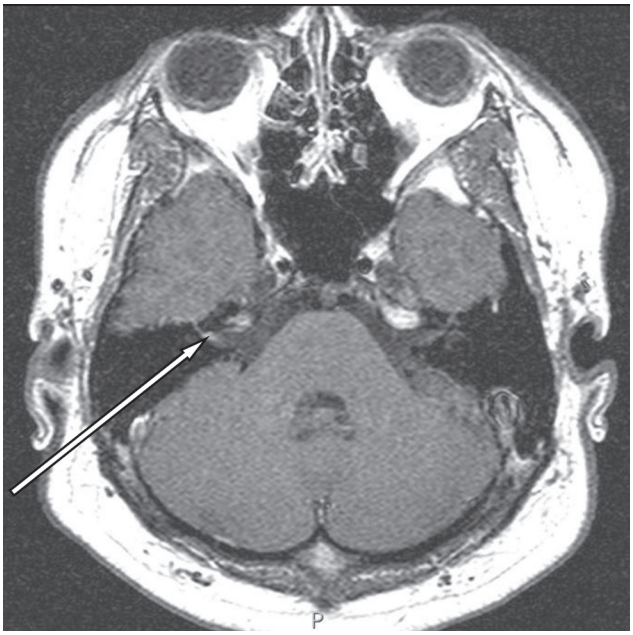

Fig. 1. Magnetic resonance imaging scan shows focal enhancement in the distal portion of the right internal auditory canal without other abnormality.

Treatment and outcome: For the treatment of Bell's palsy, prednisolone (60 mg) was administered, followed by dose reduction in accordance with the patient's improvement and final discontinuation. He showed improvement in symptom of Bell's palsy and then was finally discharged. For type 2 DM, metformin (500 mg) was administered twice daily while being hospitalized. As an outpatient, he continuously received metformin. The laboratory tests at 2 months after initial metformin treatment demonstrated improved findings: HbA1c 6.6%, fasting blood glucose 121 mg/dL, AST 48 U/L (reference, 0-40 U/L), and ALT 118 U/L (reference, 0-40 U/L).

Discussion

Bell's palsy is known as the most common cause of facial paralysis, and it occurs more frequently in pregnant women and diabetes patients with 8% of recurrence rate[7, 8]. Patients with Bell's palsy typically complain of weakness or complete paralysis of all the muscles on one side of the face. The facial creases and nasolabial fold disappear, the forehead unfurrows, and the corner of the mouth droops. The eyelids will not close and the lower lid sags; on attempted closure, the eye rolls upward[1].

Bell's palsy is suspected to be induced by inflammation of facial nerve, but the exact cause of inflammation is not fully understood[1]. Recently, Herpes simplex virus has been thought of as one of the possible causes of Bell's palsy, but the causal

Table 1. Electromyography (EMG) findings are compatible with right facial neuropathy

Motor nerve conduction (facial right)			
Nerve and site	Latency	Amplitude	
Frontalis	4.1 ms	0.3 mV	
Orbicularis oculi	3.1 ms	0.4 mV	
Nasalis	4.2 ms	0.3 mV	
Orbicularis oris	4.0 ms	0.2 mV	
Needle EMG examination			
Muscle	Fibs	*Spontaneous and/or volitional activity* +Wave	*Maximum volitional* activity Pattern
Frontalis right	None	None	Reduced
Orbicularis oculi. Right	None	None	Single unit
Nasalis right	None	None	Single unit
Orbicularis oris	None	None	Single unit

relationship has not been clearly demonstrated[7, 8]. Moreover, various diseases may manifest symptoms similar to those of Bell's palsy, and structural anomaly of ear and salivary gland, Guillain-Barre syndrome, Lyme disease, otitis media, Ramsay Hunt syndrome, sarcoidosis, and some influenza vaccines may display facial paralysis[1].

Clinical manifestations are important for the diagnosis of Bell's palsy. In Bell's palsy, the severity of paralysis reaches its maximum within a few days since the onset of clinical symptoms. If the degree of paralysis is slowly increased over 2 weeks, other diseases than Bell's palsy should be considered[1]. Brain MRI is not routinely indicated, but if it is performed, the most common abnormality seen is contrast enhancement of the distal intracanalicular and labyrinthine segments of the facial nerve; the geniculate ganglion, as well as the proximal and distal tympanic and mastoid portions of the facial nerve, may also be involved[9]. Blood test is not always required for the diagnosis of Bell's palsy. However, a study reported that patients with Bell's palsy showed impaired glucose tolerance in 40% of the subjects who received 2 hour oral glucose tolerance test, and DM in 21% of the subjects, which was significantly higher compared with control group[6]. Another epidemiology study offers evidence that early hyperglycemia is sufficient to damage distal peripheral nerves[10, 11]. Furthermore, nerve degeneration was predisposed in DM patients, which was not associated with age[5]. In the case of paralysis, therefore, it is important to determine diabetes through blood test irrespective of age.

Steroids are clinically used for the treatment of Bell's palsy. The use of steroids in the patients with Bell's palsy was reported to be associated with significant decrease in mild and moderate sequelae in Bell's palsy[12]. In particular, the recovery was delayed and the facial movement remained low in the patients with Bell's palsy and DM compared with those without DM. Thus, there is an opinion that more aggressive treatment is required for Bell's palsy accompanied by DM[13]. As steroids, however, elevate the blood glucose level, a special care should be exercised for the patients with DM. The concurrent use of insulin with high-dose steroids in the patients with Bell's palsy and DM resulted in successful treatment without significant adverse reactions. The treatment effects for facial paralysis were significantly higher in the patients who received steroid treatment than in the patients who did not[14]. As for the case in this report, the patient received steroids for the treatment of Bell's palsy, and his blood glucose level was well controlled by metformin alone without additional administration of insulin.

Recent increase in childhood and adolescent obesity is accompanied by rapid increase in the incidence of impaired glucose tolerance and type 2 DM, which suggests that the incidence of DM complications would increase too. Neuropathy is one of the most common complications of DM. However, it is not clear whether facial paralysis in DM patients should be considered as Bell's palsy accompanied by DM, or diabetic neuropathy caused by DM complication. Meral E, et al.[6, 15] reported that Bell's palsy in DM patients is not likely to occur as a part of diabetic neuropathy.

Collectively, we diagnosed type 2 DM in the patient who visited our hospital complaining of facial paralysis, and we suggest that the presence of DM should be determined even in the childhood and adolescent patients with facial paralysis, especially who are obese.

References

1) Tiemstra JD, Khatkhate N. Bell's palsy: diagnosis and management. Am Fam Physician 2007;76:997-1002.
2) Adour KK, Byl FM, Hilsinger RL, Jr., Kahn ZM, Sheldon MI. The true nature of Bell's palsy: analysis of 1,000 consecutive patients. Laryngoscope 1978;88:787-801.
3) Katusic SK, Beard CM, Wiederholt WC, Bergstralh EJ, Kurland LT. Incidence, clinical features, and prognosis in Bell's palsy, Rochester, Minnesota, 1968-1982. Ann Neurol 1986;20:622-7.
4) Gilden DH. Clinical practice. Bell's Palsy. N Engl J Med 2004;351:1323-31.
5) Adour K, Wingerd J, Doty HE. Prevalence of concurrent diabetes mellitus and idiopathic facial paralysis (Bell's palsy). Diabetes 1975;24:449-51.
6) Bosco D, Plastino M, Bosco F, Consoli A, Labate A, Pirritano D, et al. Bell's palsy: a manifestation of prediabetes? Acta Neurol Scand 2011;123:68-72.
7) Linder T, Bossart W, Bodmer D. Bell's palsy and Herpes simplex virus: fact or mystery? Otol Neurotol 2005;26:109-13.
8) Stjernquist-Desatnik A, Skoog E, Aurelius E. Detection of herpes simplex and varicella-zoster viruses in patients with Bell's palsy by the polymerase chain reaction technique. Ann Otol Rhinol Laryngol 2006;115:306-11.
9) Sartoretti-Schefer S, Wichmann W, Valavanis A. Idiopathic, herpetic, and HIV-associated facial nerve palsies: abnormal MR enhancement patterns. AJNR Am J Neuroradiol 1994; 15:479-85.
10) Smith AG, Singleton JR. The diagnostic yield of a standardized approach to idiopathic sensory-predominant neuropathy. Arch Intern Med 2004;164:1021-5.
11) Smith AG, Singleton JR. Impaired glucose tolerance and neuropathy. Neurologist 2008;14:23-9.
12) Berg T, Bylund N, Marsk E, Jonsson L, Kanerva M, Hultcrantz M, et al. The effect of prednisolone on sequelae in Bell's palsy. Arch Otolaryngol Head Neck Surg 2012;138: 445-9.
13) Kanazawa A, Haginomori S, Takamaki A, Nonaka R, Araki M, Takenaka H. Prognosis for Bell's palsy: a comparison of diabetic and nondiabetic patients. Acta Otolaryngol 2007;127:888-91.
14) Saito O, Aoyagi M, Tojima H, Koike Y. Diagnosis and treatment for Bell's palsy associated with diabetes mellitus. Acta Otolaryngol Suppl 1994;511:153-5.
15) Kiziltan ME, Akalin MA, Sahin R, Uluduz D. Peripheral neuropathy in patients with diabetes mellitus presenting as Bell's palsy. Neurosci Lett 2007;427:138-41.

벨 마비를 주소로 내원한 소아청소년에서 진단된 제 2형 당뇨병

김태성 · 조원경 · 조경순 · 박소현 · 한승훈 · 정민호 · 서병규
가톨릭대학교 의과대학 소아청소년과학교실

벨 마비는 원인은 확실히 밝혀져 있지 않지만 한쪽 안면 근육 마비를 증상을 나타내는 질환으로써 성인에서 당뇨병과의 연관관계는 잘 보고되어 있다. 그러나 소아청소년에서는 벨 마비를 주소로 내원한 환아에서 당뇨병으로 진단된 보고는 찾아 볼 수 없었다. 저자들은 벨 마비를 주소로 내원한 청소년에서 제 2형 당뇨병을 진단하고 치료 하였기에 이를 보고한다. 본 증례에서는 벨 마비를 치료 하는데 있어 스테로이드를 사용했으며 인슐린 치료 없이 메포민만으로 혈당조절이 잘 되었다. 안면 신경 마비를 주소로 내원한 환아에서 특히 비만인 경우에는 혈당 검사를 통해 당뇨병 유무를 확인 해야 할 것으로 생각된다.