

## reviews

# Lymphoid Interstitial Pneumonia\*

## A Narrative Review

Jeffrey J. Swigris, DO; Gerald J. Berry, MD; Thomas A. Raffin, MD, FCCP; and Ware G. Kuschner, MD, FCCP

Lymphoid interstitial pneumonia (LIP) is regarded as both a disease and a nonneoplastic, inflammatory pulmonary reaction to various external stimuli or systemic diseases. It is an uncommon condition with incidence and prevalence rates that are largely unknown. Liebow and Carrington originally classified LIP as an idiopathic interstitial pneumonia in 1969. Although LIP had since been removed from that category, the most recent consensus classification sponsored by the American Thoracic Society and the European Respiratory Society recognizes that some cases remain idiopathic in origin, and its clinical, radiographic, and pathologic features warrant the return of LIP to its original classification among the idiopathic interstitial pneumonias. LIP also belongs within a spectrum of pulmonary lymphoproliferative disorders that range in severity from benign, small, airway-centered cellular aggregates to malignant lymphomas. It is characterized by diffuse hyperplasia of bronchus-associated lymphoid tissue. The dominant microscopic feature of LIP is a diffuse, polyclonal lymphoid cell infiltrate surrounding airways and expanding the lung interstitium. Classically, LIP occurs in association with autoimmune diseases, most often Sjögren syndrome. This has led to consideration of an autoimmune etiology for LIP, but its pathogenesis remains poorly understood. Persons who are seropositive for HIV, and children in particular, are at increased risk of acquiring LIP. Some studies suggest causal roles for both HIV and Epstein-Barr virus. The incidence of LIP is approximately twofold greater in women than men. The average age at diagnosis is between 52 years and 56 years. Symptoms of progressive cough and dyspnea predominate. There is great variability in the clinical course of LIP, from resolution without treatment to progressive respiratory failure and death. Although LIP is often regarded as a steroid-responsive condition, and oral corticosteroids continue to be the mainstay of therapy, response is unpredictable. Approximately 33 to 50% of patients die within 5 years of diagnosis, and approximately 5% of cases of LIP transform to lymphoma.

(*CHEST* 2002; 122:2150–2164)

**Key words:** HIV; lung diseases, interstitial; lymphoproliferative disorders; Sjögren syndrome

**Abbreviations:** BALT = bronchus-associated lymphoid tissue; CXR = chest radiograph; DILS = diffuse infiltrative lymphocytosis syndrome; EBV = Epstein-Barr virus; FBB = follicular bronchitis/bronchiolitis; HLA = human leukocyte antigen; HP = hypersensitivity pneumonitis; HTLV = human T-lymphotropic virus; LIP = lymphoid interstitial pneumonia; MALT = mucosal-associated lymphoid tissue; MHC = major histocompatibility complex

### BIOLOGY OF LUNG LYMPHOID TISSUE

This section reviews the distribution and function of mucosal-associated lymphoid tissue (MALT) in both healthy and antigen-challenged human lungs. It details the potential of the lung to formulate an immune response to inhaled and circulating antigen, and outlines how lymphoid interstitial pneumonia (LIP) is a morphologic manifestation of this response.

\*From the Division of Pulmonary and Critical Care Medicine (Drs. Swigris and Raffin), Stanford University, Stanford, CA; the Department of Pathology (Dr. Berry), Stanford University, Stanford, CA; and Veterans Affairs Palo Alto Health Care System (Dr. Kuschner), Palo Alto, CA.

Manuscript received October 22, 2001; revision accepted April 29, 2002.

Correspondence to: Jeffrey J. Swigris, DO, Stanford University Medical Center, Division of Pulmonary and Critical Care Medicine, 300 Pasteur Dr, Stanford, CA 94305-5236, e-mail: jjswig@pol.net

## Lymphocytes

Lymphoid tissue is uncommon in normal adult human lungs,<sup>1</sup> but is frequently observed in other mammalian groups such as rats, rabbits, and sheep (Fig 1). In nonsmoking adults, the majority of lung lymphoid tissue is contained in poorly organized aggregates predominantly located at bronchial divisions and adjacent to distal respiratory bronchioles.<sup>2</sup> Additionally, small numbers of lymphoid cells are occasionally found scattered beneath and between cells composing bronchial walls.<sup>3</sup> These cells and other “preactivated” lymphocytes that reside alongside the alveolar lumen act as a kind of “lymphoid first defense” against inhaled antigen.<sup>4</sup> The mechanism by which circulating lymphoid cells initially populate these areas involves the contact of cell surface “homing receptors,”<sup>5</sup> such as integrins, onto specific intrapulmonary vascular adhesion mole-

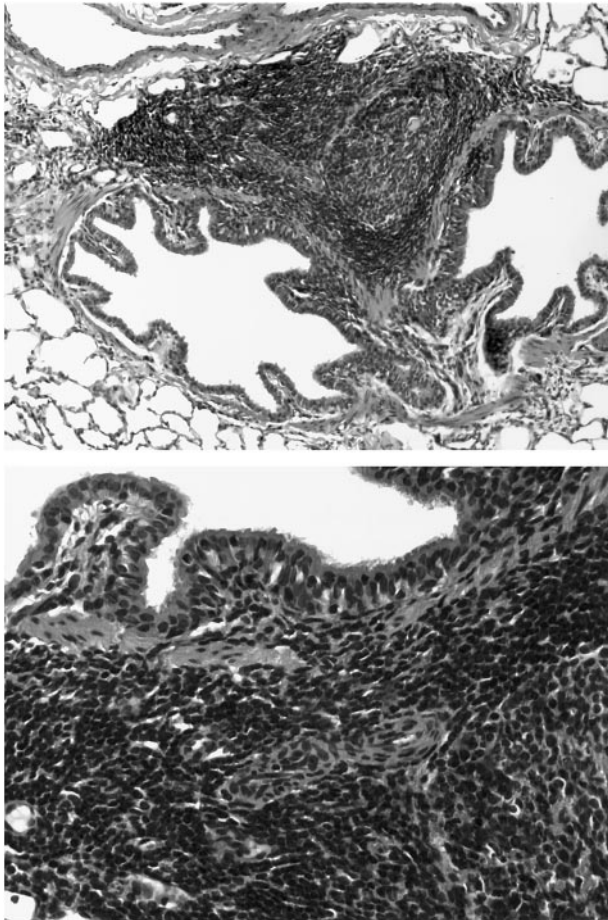


FIGURE 1. *Top*: Low-power magnification of BALT in bronchial division point of normal ovine lung tissue. Unencapsulated collections of lymphoid cells including a small follicular structure are present (hematoxylin-eosin, original  $\times 150$ ). *Bottom*: High-power magnification showing intramucosal lymphocytes and aggregates within the lamina propria and submucosal tissues (hematoxylin-eosin, original  $\times 400$ ).

cules,<sup>4</sup> such as addressins on postcapillary venular endothelial cells or high endothelial venules.<sup>6</sup> Approximately 60% of lung lymphoid cells are B cells, and the rest are T lymphocytes.<sup>7</sup> In total, the constellation of unencapsulated lymphoid follicles, cellular collections, and loosely distributed mucosal lymphocytes constitute the bronchus-associated lymphoid tissue (BALT) or “pulmonary microtonsils.” Some investigators have placed the lymphoid aggregates found along the pleura and septae within this category, although these sites lack an epithelial component. BALT is more frequently and easily identified in neonates and infants than adults.<sup>8</sup> BALT can remain as these simple collections of cells sparsely populating areas of bronchi, or it can be driven to dense proliferation encompassing entire airway walls and/or the lung interstitium. In such states, where BALT activity is stimulated, distinct lymphoid follicles with germinal centers are formed and become increasingly conspicuous.

BALT plays an essential role in the prevention of infection by inhaled microorganisms, by serving as the pulmonary site for secondary lymphoid differentiation, where naïve lymphocytes initially contact inhaled antigen to become antigen-specific memory or immune-effector cells.<sup>4</sup> Once primed by antigen, memory cells circulate throughout the BALT compartment and the remaining lung parenchyma, awaiting exposure to the same provoking antigen.<sup>4</sup> The complex interaction of lymphocytes with fibroblasts, dendritic cells, epithelial cells, and macrophagic cells requires various types of lymphocytes, including antigen-reactive, effector, and regulatory B-cell and T-cell lymphocytes.<sup>9</sup>

## Lymphoepithelium

Overlying and intricately associated with BALT is a specially adapted pseudostratified mucosal layer of attenuated epithelial cells with few ciliated and rare goblet cells (Fig 1),<sup>10</sup> but increased numbers of cells with surface microvilli.<sup>11</sup> The mucosa surface appears dome shaped and is infiltrated by T cells with CD8+ cells outnumbering CD4+ cells. This compilation of specialized epithelium, underlying BALT, and nearby efferent lymphatic vessels that drain to hilar nodes comprise what was formerly known as the “pulmonary sump,”<sup>12</sup> an environment tailored to inhaled antigen-host immune interactions.

Inhaled antigens are most likely to be deposited on and adhere to mucosa at sites of airway branching and, not surprisingly, where BALT is most dense. The reason for the deposition in these areas is twofold: first, because of their mid-lumen position impaction is more likely to occur at airway branch points; and secondly, the unique airway cell surface

in these areas is ideal for antigen adherence and absorption. In addition to these functions, the lymphoepithelium takes part in antigen transport and processing.<sup>13</sup> It promotes antigen contact with antigen-presenting cells and then allows their transport across the epithelial surface to BALT.<sup>4</sup> Interestingly, despite its integral role in pulmonary immune surveillance, BALT does not express the secretory component of IgA and differs from other mucosa-associated lymphoid tissues such as those in the GI tract (gut-associated lymphoid tissue).<sup>14</sup>

### *BALT Proliferations*

The deposition of inhaled antigen on airway lymphoepithelium initiates T-cell and B-cell effector mechanisms that serve to prevent infection and also to protect the lung from excessive local parenchymal injury by down-regulating both nonspecific and immune-mediated inflammation.<sup>9</sup> Antigen-presenting cells in the lung process inhaled antigens and induce naïve T cells to accumulate, develop antigen specificity, and proliferate.<sup>15</sup> In the central processing phase, preactivated intra-alveolar lymphocytes undergo clonal expansion.<sup>4</sup> Local interstitial lymphocytes respond similarly once antigen is presented by antigen-presenting cells, such as interdigitating and follicular dendritic cells and macrophages.<sup>4</sup> In the effector phase, T cells and B cells migrate into areas of ongoing inflammation or infection,<sup>16–18</sup> populate surrounding BALT compartments, and proliferate along with locally activated cells.<sup>10</sup> Lung high endothelial venules help traffic in memory T cells,<sup>19</sup> similarly to how circulating naïve lymphoid cells are initially recruited into the BALT compartment, in a process utilizing numerous lymphocyte (including leukocyte function-associated antigen 1 and integrins<sup>4</sup>) and endothelial ligands (including vascular cell adhesion molecule 1<sup>20</sup> and others<sup>21</sup>). Cytokines released from active, proliferating cells induce subpopulations of lymphocytes to enlist either immune-effector (eg, cytotoxicity, Ig synthesis) or immunomodulator functions. Finally, circulating monocytes and blood lymphocytes are recruited into the milieu to further heighten the immune response.

It is the extent of immune activation and nature of the lymphoid proliferation, which results in a continuum of morphologic patterns, from localized benign hyperplasia to diffuse malignant neoplasms. Localized or nodular lymphoid proliferations in the lung include intrapulmonary lymph nodes, pulmonary hyalinizing granuloma, plasma cell granuloma-histiocytoma complex (inflammatory myofibroblastic tumor), Castleman disease, nodular amyloidosis/light-chain deposition disease, and nodular lymphoid

hyperplasia (pseudolymphoma).<sup>22</sup> LIP is a manifestation of benign diffuse lymphoid proliferation in the lung.

### *LIP as Diffuse BALT Hyperplasia*

While this conceptual model of BALT hyperplasia provides a basis for characterizing and understanding an entire spectrum of lymphoid processes evolving in the lung,<sup>1</sup> many questions remain. For example, why do these processes occur in some people and not others with similar clinical characteristics? Why does proliferation, at times, cease in its earliest stage<sup>23</sup> as localized, airway-centered aggregates, while at other times there is progression to widespread interstitial processes such as LIP, or further still, a malignant lymphoma? Multiple factors, including unique host susceptibility and host immune dysregulation, are likely involved.

Presently, the entire continuum of small lymphocytic proliferations in the lung is thought to arise from BALT.<sup>10,22</sup> Conventional terminologies have provided suitable pathologic descriptions of these proliferations, but have failed to capture the essential feature of BALT as their tissue origin. New terminology based on the extent and location of lymphoid proliferation, with emphasis on BALT as the source, has been proposed<sup>19</sup> and widely (though not universally) accepted.<sup>1,10,22</sup> The spectrum of acquired benign diffuse proliferations of BALT now includes follicular bronchitis/bronchiolitis (FBB), diffuse lymphoid hyperplasia, and LIP.

## PATHOGENESIS AND UNDERLYING CONDITIONS OF DISEASES

### *Autoimmune Mechanisms*

Associations with numerous autoimmune phenomena have raised concern that LIP is itself an autoimmune disease<sup>24</sup>; however, theories on its pathogenesis have mainly focused on the role of viral infections.

### *Viral Infection*

Because LIP occurs in varied clinical settings, including infection and immune system dysfunction, it is thought to represent a nonspecific response to multiple stimuli.<sup>25</sup> In the first published study of LIP after its initial description in 1966, Liebow and Carrington<sup>26</sup> suggested many possibilities for these stimuli, including viral agents, either by their direct action on lungs or by their inducing failure in lung immune surveillance mechanisms. Since then, studies have attempted to delineate the association be-



tween LIP and viral infection, but inconsistencies have precluded the establishment of a well-defined relationship.

**Epstein-Barr Virus:** Epstein-Barr virus (EBV) DNA has been found in the lung tissue specimens of some, but not all,<sup>27</sup> patients with LIP. For example, Barberà et al<sup>28</sup> detected EBV in open-lung biopsy specimens in 9 of 14 patients with LIP using *in situ* hybridization. Using the same method, another study detected EBV DNA in 80% of lung specimens from HIV-positive children with LIP. Some of these patients also had serologic evidence of acute EBV infection.<sup>29</sup> Kaan et al<sup>30</sup> showed concurrently increased levels of EBV latent membrane protein 1, and the human apoptosis-inhibiting proto-oncogene bcl-2 in the lungs of patients with LIP. EBV latent membrane protein 1 up-regulates bcl-2, and high levels of bcl-2, which confer a survival advantage for lymphocytes in other lymphoproliferative disorders, could enhance tissue lymphocyte accumulation and survival in LIP as well. Kramer et al<sup>31</sup> found significantly higher levels of anti-EBV antibodies (indicating primary or reactivated EBV infection) in HIV-positive adults with LIP compared to HIV-positive adults without LIP. Similar findings have also been found in many HIV-positive children with LIP.<sup>22,39</sup>

These data suggest EBV infection plays a role in some cases of LIP, but not all. Even in instances where EBV antigen or antibody is found in the lung, there are likely other adjunctive mechanisms, including a dysregulated host immune system, driving or allowing cellular proliferation.

**HIV:** HIV antigen and antibody have been found in BAL and lung tissue specimens of some HIV-positive patients with LIP.<sup>33,34</sup> Chayt et al<sup>35</sup> reported a significantly increased number of cells expressing human T-lymphotropic virus (HTLV) type III RNA in HIV-positive patients with LIP compared to HIV-positive patients with lung pathology other than LIP. Many of these cells were lymphocytes, but those of the macrophage-monocyte lineage also labeled positively. They concluded that each infected cell housed from 30 to 50 copies of HTLV-III (HIV) RNA.

HIV can induce proliferation of BALT *in vitro*,<sup>36,37</sup> and animal data convincingly display a relationship between HIV and LIP. Transgenically infected mice, expressing entire HIV-1 coding sequences in their CD4+ T lymphocytes and other cells, acquire many characteristic pathologic manifestations of HIV infection, including the lung lesions of LIP.<sup>38</sup>

It appears that a transient lymphocytic alveolitis may develop in every HIV-positive patient group.<sup>39</sup>

Agostini et al<sup>4</sup> identified a model of lung immune response to HIV, which may, in part, explain the progressive evolution of LIP in some of these patients. After infection with HIV, it appears alveolar macrophages recruit CD8+ T cells into the lung from secondary lymphoid tissues.<sup>40</sup> These cells have a number of highly specialized functions, including lysis of certain HIV-infected cells.<sup>41</sup> Coincident with HIV disease progression is a complex series of immune cellular events favoring viral replication.<sup>42</sup> For example, as interactions with antigen presenting cells ensue, intrapulmonary CD8+ T cells, themselves, may become infected with HIV, thus losing their cytotoxic ability.<sup>40</sup> Additionally, certain cytokines released in response to HIV have paradoxical effects of promoting viral replication and down-regulating cytotoxic T lymphocytes.<sup>39</sup> In response, activated alveolar macrophages recruit and activate more immunocompetent cells to combat the enlarging antigen load, thus increasing the density of the cellular infiltrate.

Simultaneous infection with EBV and HIV may amplify the risk of development of LIP. B lymphocytes infected with EBV are very susceptible to HIV infection *in vitro* and could enhance intrapulmonary replication of HIV. This would result in further interstitial lymphocyte proliferation via mechanisms explained above.<sup>43</sup>

Evidence to support the association of LIP with viral infections other than EBV or HIV comes from a Japanese study in which five of six patients with LIP tested seropositive for antibodies to HTLV-1. No patients in the study had antibodies to HIV or EBV.<sup>44</sup>

#### *Underlying Conditions or Diseases*

LIP is often seen in conjunction with systemic diseases, most notably HIV infection (or AIDS) and Sjögren syndrome,<sup>45</sup> although some cases remain idiopathic. Associations with common variable immunodeficiency<sup>46,47</sup> have been reported and LIP can be a late complication of allogeneic bone marrow transplantation, occurring between 200 days and 400 days after transplant.<sup>48,49</sup> There is a case report of a 10-year-old girl with cough and dyspnea, in which the lung biopsy revealed both LIP and pulmonary alveolar microlithiasis.<sup>50</sup> There are also reports of LIP occurring in the setting of Legionella pneumonia,<sup>51</sup> diphenylhydantoin use,<sup>52</sup> and pulmonary alveolar proteinosis.<sup>53</sup>

**Autoimmune Diseases:** One of the most common (25% of LIP cases) associations of LIP is with Sjögren syndrome; 1% of Sjögren patients acquire LIP during the course of their disease.<sup>24,54</sup> As shown in Table 1,

**Table 1—Diseases Associated With LIP**

Diseases
Autoimmune (39%)*
Sjögren syndrome <sup>45</sup>
Systemic lupus erythematosus <sup>55–57</sup>
Rheumatoid arthritis <sup>24</sup>
Juvenile rheumatoid arthritis <sup>58</sup>
Hashimoto thyroiditis <sup>24,26</sup>
Myasthenia gravis <sup>59</sup>
Hemolytic anemia <sup>26</sup>
Pernicious anemia <sup>60</sup>
Autoerythrocyte sensitization syndrome <sup>61</sup>
Chronic active hepatitis <sup>63</sup>
Celiac sprue <sup>64</sup>
Primary biliary cirrhosis <sup>62</sup>
Systemic immunodeficiency states (14%)†
HIV/AIDS <sup>103</sup> with and without DILS
Common variable immunodeficiency† <sup>46,47</sup>
Agammaglobulinemia† <sup>60</sup>
Miscellaneous
Complication of allogeneic bone marrow transplantation <sup>48,49</sup>
Pulmonary alveolar microlithiasis <sup>50</sup>
Infections including <i>Legionella</i> pneumonia, <sup>51</sup> tuberculosis, Mycoplasma, Chlamydia
Diphenylhydantoin use <sup>52</sup>
Pulmonary alveolar proteinosis <sup>53</sup>
Idiopathic

\*Thirty-nine percent of LIP cases are associated with autoimmune diseases; 25% are found in patients with Sjögren syndrome. Between 1% and 2% of HIV-positive adults have LIP. The association of LIP with other diseases mentioned here are far less frequent. Percentages do not add up to 100 because study data are incomplete.

†Compiled data from Yousem et al,<sup>23</sup> Fishback and Koss,<sup>25</sup> and Bakhos et al,<sup>53</sup> which do not include data on HIV.

LIP occurs in the setting of other autoimmune diseases, including systemic lupus erythematosus,<sup>55–57</sup> rheumatoid arthritis, juvenile rheumatoid arthritis,<sup>58</sup> autoimmune thyroiditis,<sup>26</sup> myasthenia gravis,<sup>26,59</sup> hemolytic<sup>26</sup> and pernicious<sup>60</sup> anemia, the autoerythrocyte sensitization syndrome,<sup>61</sup> chronic active hepatitis,<sup>62,63</sup> celiac sprue,<sup>64</sup> and primary biliary cirrhosis.<sup>24,62</sup>

**HIV:** HIV infection represents another common association with LIP. Many believe LIP represents a specific lung reaction to HIV.<sup>35,65,66</sup> Why only some HIV-infected patients acquire hyperplasia of BALT, such as FBB (which has a propensity to occur in similar clinical settings as LIP) or LIP, is unknown. LIP is particularly common in HIV-infected children, wherein 16 to 50% of HIV-infected children acquire it, most often in the second or third year of life.<sup>67,68</sup> In this group, LIP is strongly associated with progression to AIDS, and has been considered an AIDS-defining illness in those < 13 years old since 1987.<sup>69</sup> LIP is listed in clinical category B according to the current HIV classification system for this age group.<sup>70</sup>

In HIV-positive adults, a nonspecific interstitial pneumonitis is much more common than LIP. LIP still occurs, albeit far less frequently than in the HIV-positive pediatric population.<sup>71,72,73</sup> Early reports of adult HIV-positive LIP showed it occurs predominantly in African-Caribbean or African-American population.<sup>34,74,75</sup> The clinical and radiologic findings are less specific than in children, and infectious etiologies must be excluded. A thoracoscopic lung biopsy is often required for this purpose.

**Diffuse Infiltrative Lymphocytosis Syndrome:** A subset of HIV-positive patients have a unique sicca syndrome with increased circulating CD8+ cells, CD8+ T cells infiltrating tissues diffusely, parotid enlargement, and lymphadenopathy, which Itescu et al<sup>76</sup> named diffuse infiltrative lymphocytosis syndrome (DILS). In one study of 523 HIV-positive outpatients, the prevalence of DILS was between 3% and 4% and even higher among African-American patients. Nearly 50% of patients with DILS acquire LIP.<sup>77–79</sup>

Similarities between DILS and Sjögren syndrome include xerostomia, xerophthalmia, lymphocytic infiltration of the salivary glands, and a propensity to acquire LIP. Key discriminating features include the following: the extraglandular manifestations of DILS are caused by CD8+ rather than CD4+ T-lymphocyte infiltrates, the low frequency of autoantibodies in DILS (*ie*, anti-Ro/SS-A and anti-La/SS-B antibodies), the strong association with human leukocyte antigen (HLA)-DR5, and HIV positivity.<sup>76,80</sup>

Having HLA-DR5 confers a relative risk of 16.9 times for DILS in HIV-positive black patients, while this association is lacking in HIV-positive white patients.<sup>76</sup> However, there is an increased frequency of HLA-DRw6 or HLA-DR7 in white patients with DILS. One study showed an increased incidence of DILS in patients who acquire HIV by male-to-male transmission.<sup>77</sup>

Like the lung in HIV-positive LIP, the extrapulmonary lymphocytic infiltration of DILS is thought to be a host immune response; HIV antigen is fueled, genetically determined,<sup>81</sup> and modulated by the major histocompatibility complex (MHC).<sup>82</sup> This is, in part, supported by the finding that some circulating<sup>83</sup> and intrapulmonary<sup>41</sup> CD8+ lymphocytes are cytotoxic to HIV-infected host cells, and are able to directly suppress viral replication in a process utilizing MHC surface markers.<sup>79,84</sup>

The lymphocytic infiltrates of DILS affect different organs including the GI mucosa, liver and portal triads, and kidneys, possibly inducing renal insufficiency and type 4 renal tubular acidosis. Other sites of involvement are the CNS, causing cranial neuropathies, and lymphocytic meningitis.<sup>85,86</sup> Some pa-

tients with DILS and LIP respond to treatment with corticosteroids or other immunosuppressive agents. Although antiretroviral therapy is proven beneficial, it appears that patients with DILS (including those with LIP) have an AIDS-free survival advantage, compared to HIV-positive patients without DILS, independent of whether antiretroviral agents are instituted.<sup>77,80</sup> Two possible explanations are (1) the ability of infiltrating cytotoxic CD8+ cells to lower antigen burden; and (2) the possibility that certain MHC alleles, such as DRB1\*1102, which encodes for DR5, or DRB1\*1301, which encodes for DR6, play roles in a process that suppresses viral replication and delays the emergence of cytopathic HIV strains.<sup>87</sup>

### CLINICAL FEATURES

The majority of patients with LIP are female. The onset of symptoms ranges from 40 to 70 years of age (mean age at diagnosis, 52 to 56 years). There is no race preponderance in children with LIP; however, the majority of HIV-positive adults with LIP are black, while most HIV-negative adults with LIP are white.<sup>24,26</sup> Respiratory symptoms are present in the majority of patients at the time of diagnosis and include progressive dyspnea and dry cough.<sup>26,54,88</sup> Systemic symptoms such as fever, night sweats, and weight loss are less common. The mean time from presentation to diagnosis can exceed 15 months.<sup>54</sup>

Pediatric patients with LIP usually present in their second or third year with lung infiltrates, respiratory distress, and failure to thrive.<sup>15</sup> Some symptoms, like bronchospasm and cough, may be present before any detectable radiographic abnormality.<sup>89</sup>

Lung auscultation often reveals bibasilar crackles.<sup>26</sup> Clubbing is usually absent.<sup>24,26,54</sup> Extrapulmonary lymphatic involvement, including peripheral or mediastinal lymphadenopathy or splenomegaly, is not common in LIP (except in cases of DILS) and suggests alternative diagnostic considerations.<sup>24,26</sup> Pulmonary function studies usually show a restrictive ventilatory defect with a decreased carbon monoxide diffusing capacity and variable degrees of hypoxemia.<sup>24,54</sup>

Approximately 80% of patients with LIP have serum dysproteinemias, most commonly polyclonal hypergammaglobulinemia.<sup>24,26,62</sup> The significance of this finding is not known. In their original case series of 18 patients, Liebow and Carrington<sup>26</sup> reported 12 patients with hypergammaglobulinemia and 5 patients with hypogammaglobulinemia.

### RADIOGRAPHIC FEATURES

#### Chest CT

As with other diffuse interstitial lung diseases, chest high-resolution CT is the radiographic procedure of choice to define the pulmonary opacities in LIP. CT is also able to confirm the absence of lymphadenopathy, as is the case in the majority of patients with LIP. Thickened bronchovascular bundles, nodules of varying sizes, and ground-glass opacities are common<sup>90</sup> (Fig 2). Johkoh et al<sup>91</sup> reported areas of ground-glass attenuation in 22 of 22 patients; the distribution showing bilateral (95%), diffuse (64%), patchy (23%), and peripheral (14%) patterns. Centrilobular nodules were also observed in 100% of cases, subpleural nodules in 86%, patchy bronchovascular bundle thickening in 86%, interlob-

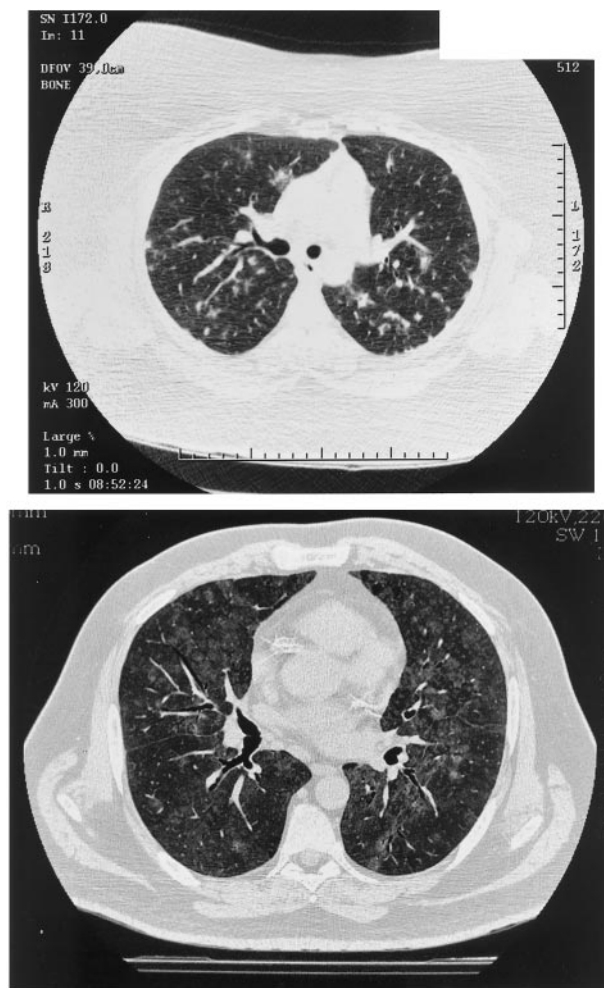


FIGURE 2. High-resolution chest CT scans in two cases of LIP. *Top*: Multiple central and peripheral parenchymal and subpleural nodules of varying size and definition in a 36-year-old, HIV-negative woman. *Bottom*: Bilateral patchy ground-glass opacities and ill-defined centrilobular nodules affecting all lobes in a 41-year-old, HIV-positive man (courtesy of Ann Leung, MD).



ular septal thickening in 82%, and 1- to 30-mm cysts in 68%. In comparing CT findings of patients with LIP to those of patients with lymphoma, Honda et al<sup>92</sup> found cysts in 82% of patients with LIP, but in only 2% of patients with lymphoma. Airspace disease, large nodules, and pleural effusions were rare in their patients with LIP. Other studies have confirmed the high frequency of cysts in LIP.<sup>93,94</sup> Ichikawa et al<sup>95</sup> noted cysts of LIP primarily deep within the lung parenchyma throughout the mid-lung zones, in contrast to the pleural-based, basilar zones in usual interstitial pneumonia. They postulate the cysts in LIP result from the lymphocytic infiltrate compressing bronchioles, causing stenosis or obstruction and subsequent postobstructive bronchiolar ectasia. Diffuse bronchiectasis, with all its classic CT features, is an increasingly reported finding in HIV-positive children with LIP.<sup>96,97</sup>

### Chest Radiography

Although not specific for LIP, the chest radiograph (CXR) is classically described as having bilateral, predominantly lower zone, reticular or reticulonodular opacities (Fig 3). While this pattern may be observed in other entities, such as *Pneumocystis carinii* pneumonia, miliary tuberculosis, or cytomegalovirus pneumonitis, a distinguishing feature of the infiltrates of LIP is their indolence, chronicity, and lack of response to treatment that would be expected to resolve other pulmonary processes.<sup>66</sup> Coarse reticulonodular and more consolidative opacities can occur, but pleural effusions are rare.

Oldham et al<sup>98</sup> reviewed the CXRs of 14 adult and 2 pediatric HIV-positive patients with LIP. They classified the radiographs into three categories based on severity: a type 1 LIP CXR had reticular or finely reticulonodular interstitial opacities with nodules < 3 mm; type 2 CXRs had coarse reticulonodular interstitial opacities with nodules between 3 mm and 5 mm; and type 3 LIP CXRs had findings of either type 1 or 2 plus at least one area of patchy alveolar opacity. A fourth radiographic pattern, focal alveolar consolidation resembling pneumonia, has recently been added to the original three.<sup>66</sup> Although small, their study found a statistically significant ( $p < 0.001$ ) increased mean survival in patients with a type 3 CXR (19 months) compared to a type 1 CXR (7 months). Thus, they equated more severe infiltrates on CXR with a stronger immune system (*ie*, less immunosuppression) and the ability to mount a more vigorous response to HIV. Laboratory data to support these findings (*eg*, increased CD4 counts in those with type 3 CXR compared to type 1 CXR) were not provided, and there were not enough patients with type 2 CXRs to draw conclusions about that group. In pediatric HIV-positive LIP, Prosper and colleagues<sup>99</sup> validated the correlation of CXR infiltrate resolution with increasing severity of immunosuppression and declining CD4 lymphocyte counts. One patient was able to be weaned off oral glucocorticoids, and had clearing of her CXR as her CD4 count decreased from 418 to < 200 cells per microliter. Accordingly, the consensus has been that cases of HIV-positive LIP, in which radiographic

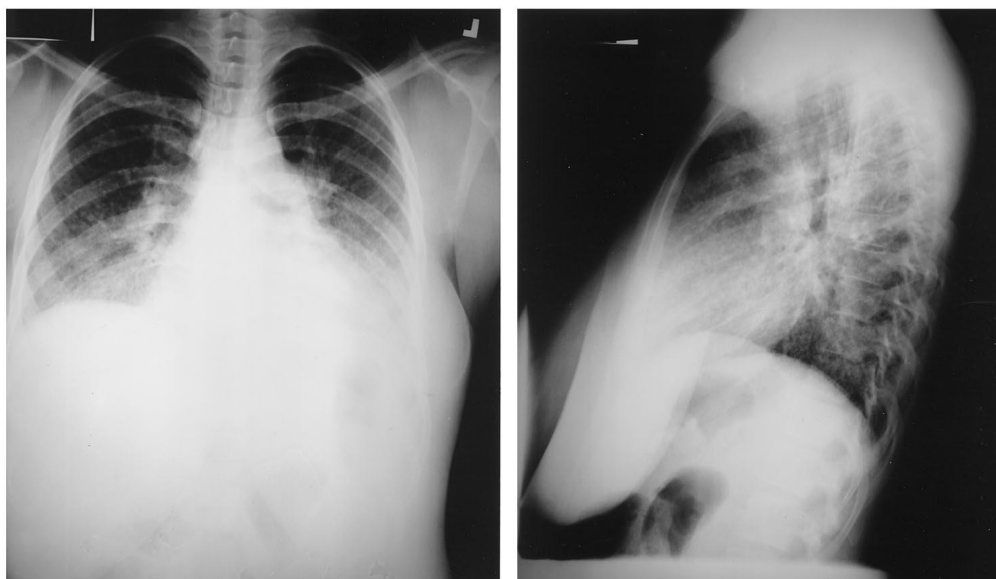


FIGURE 3. CXR in LIP. *Left*: Posteroanterior CXR of a 39-year-old, HIV-negative woman, which demonstrates typical bilateral lower zone coarse reticulonodular opacities (courtesy of Paul Stark, MD). *Right*: Lateral view of the CXR from the same patient.

resolution occurs in the absence of antiretroviral or corticosteroid therapy, should be perceived as a herald of worsening immunosuppression. A more recent retrospective analysis of 20 HIV-positive children with LIP has emphasized that spontaneous clinical and radiographic resolution without immune deterioration also occurs.<sup>100</sup> Of 13 children with complete CXR resolution, CD4 counts remained unchanged from baseline in 11 children. The two patients with significant reductions in CD4 counts corresponding to improvements in their CXR were in clinically stable condition, and their CD4 counts increased over the following year without recurrence of LIP.

### PATHOLOGIC FEATURES

Microscopically, LIP is characterized by diffuse interstitial cellular infiltrates, which expand and widen interlobular and alveolar septae (Fig 4). The infiltrates are generally polymorphous, and are composed of an admixture of small mature lymphocytes, immunoblasts, plasma cells and histiocytes, including epithelioid and giant cell types. In the majority of cases, lymphocytes predominate over plasma cells. Cases with numerous plasma cells are associated with elevated serum gammaglobulin levels.<sup>26</sup> Nonca-

seating granulomas are sometimes observed, but are loosely arranged in contrast to the “hard” granulomas of sarcoidosis.<sup>22</sup> Reactive lymphoid follicles are found along the peribronchiolar regions in the majority of cases often with infiltration of lymphocytes into the bronchiolar epithelium.<sup>62</sup> Interstitial fibrosis and honeycomb change are reported in advanced cases.<sup>54,101</sup> While the predominant changes are centered on the pulmonary interstitium, secondary findings within alveolar airspaces can include collections of proteinaceous fluid, mononuclear inflammatory cells, foamy macrophages, or giant cells (Fig 5).

The interstitial lymphoid cells are mainly T cells and polytypic plasma cells, whereas polyclonal B cells are located in peribronchial germinal centers.<sup>1,10,62,102</sup> The cells reside and also proliferate in these respective areas.<sup>19</sup> This cellular organization, identical to that seen in hyperplastic peripheral lymph nodes, suggests the LIP lung behaves as a giant lymph organ.<sup>19,102</sup> Similar cellular features have also been seen in the salivary glands of patients with Sjögren syndrome.<sup>26</sup>

Reactive lymphoid follicles are seen in both LIP and FBB, and the morphologic distinction is sometimes difficult<sup>62</sup> and often subjective. As mentioned previously, both can be seen in similar clinical settings including connective tissue disorders, drug

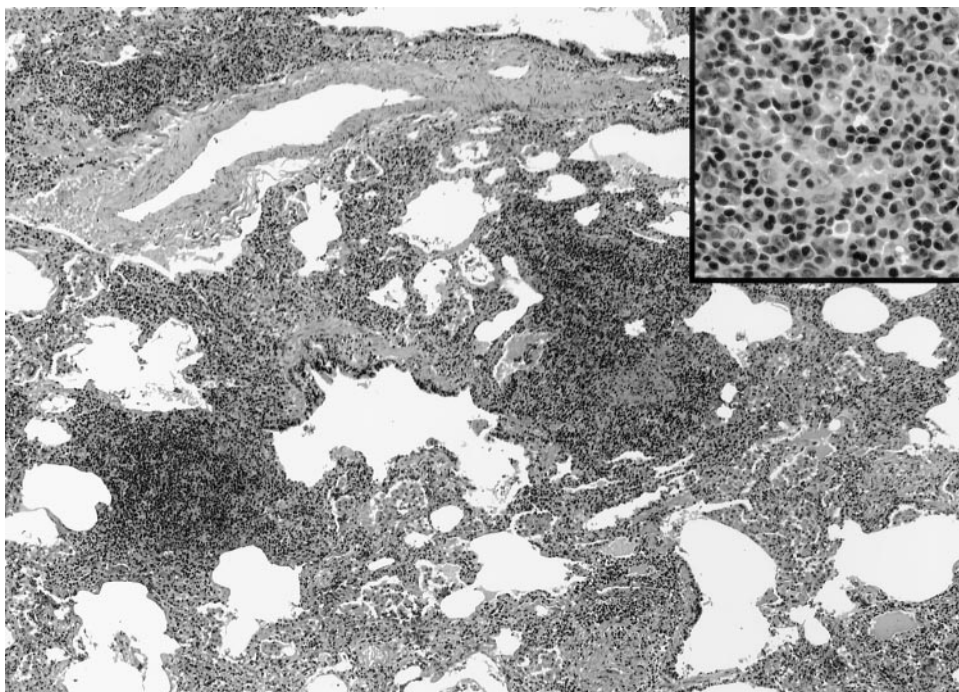


FIGURE 4. Low-power magnification of LIP showing expansion of alveolar interstitium by mononuclear inflammatory cell infiltrates. The alveolar airspaces display variable degrees of distortion and collapse (hematoxylin-eosin, original  $\times 60$ ). The infiltrates (insert) are composed of an admixture of cell types including small lymphocytes, plasma cells, and histiocytes (hematoxylin-eosin, original  $\times 400$ ).



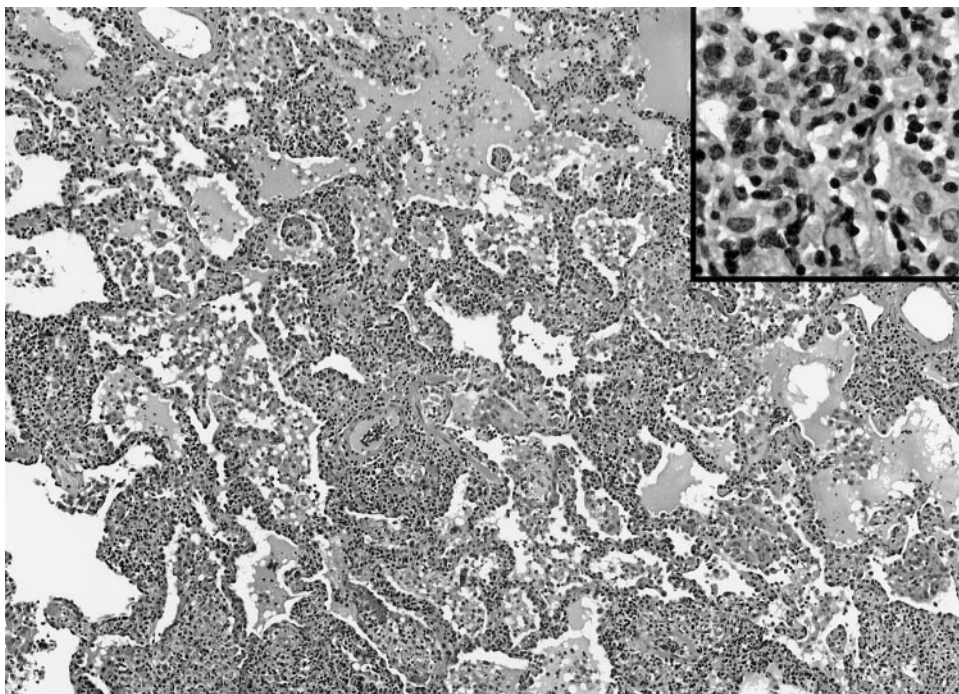


FIGURE 5. LIP arising in an HIV-positive patient with an underlying connective tissue disorder. The airspaces display secondary changes ranging from compression by the interstitial infiltrates to proteinaceous fluid and macrophage collections (hematoxylin-eosin, original  $\times 100$ ). In this case the polyclonal septal infiltrates (insert) contain fewer plasma cells (hematoxylin-eosin, original  $\times 400$ ).

reactions and immunodeficiency states. Like Katzenstein,<sup>22</sup> we recognize infiltrates confined to the peribronchiolar tissues as FBB and require diffuse expansion of alveolar septa for the diagnosis of LIP.

There are subtle differences in the immunophenotypic patterns of LIP in HIV-negative vs HIV-positive patients. In HIV-associated LIP, CD8+ T cells predominate,<sup>81,103</sup> whereas in HIV-negative patients B cells are more numerous (in peribronchiolar areas and lymphoid follicles) and T cells are confined to the alveolar interstitium and areas surrounding lymphoid follicles. Further, bronchiolitis obliterans organizing pneumonia is rarely, if ever, present in cases of LIP,<sup>22,26</sup> but Travis et al<sup>71</sup> showed foci of proliferative obliterative bronchiolitis in one HIV-positive patient with LIP.

The histopathologic differential diagnosis of LIP includes a variety of infectious, inflammatory, and neoplastic processes (Table 2). In immunocompromised patients, histochemical stains (eg, Gomori-methenamine silver) must exclude pneumonitis such as *P carinii*. Viral pneumonia can also mimic LIP, including EBV-associated infections such as infectious mononucleosis or posttransplant lymphoproliferative disorders. Like LIP, the histopathologic findings in hypersensitivity pneumonitis (HP) [or extrinsic allergic alveolitis] include mononuclear bronchiolitis, cellular interstitial pneumonitis, and poorly formed granulomas (Fig 6). In general, HP is patchy in distribution and lacks the intense interstitial infiltrates of LIP. In some cases of HP, the inflammation can be prominent and the distinction

**Table 2—Histopathologic Features That Distinguish LIP, HP, and Small Lymphocytic/Lymphocytoplasmic Lymphoma/Extranodal Marginal Zone Lymphoma (MALToma)\***

Features	LIP	HP	WDL/MALToma
Distribution	Diffuse, interstitial	Patchy, bronchiolocentric	Diffuse, lymphangitic
Alteration of airspace architecture	Compression by interstitial infiltrates	Absent	Compression by nodular infiltrates
Composition of cellular infiltrates	Polymorphous	Polymorphous	Monomorphous
Clonality studies	Polyclonal	Polyclonal	Monoclonal
Reactive lymphoid follicles	Present	Absent	Occasional
Epithelioid histiocytes/granulomas	Present	Present	Occasional in WDL

\*WDL = small lymphocytic/lymphocytoplasmic lymphoma.

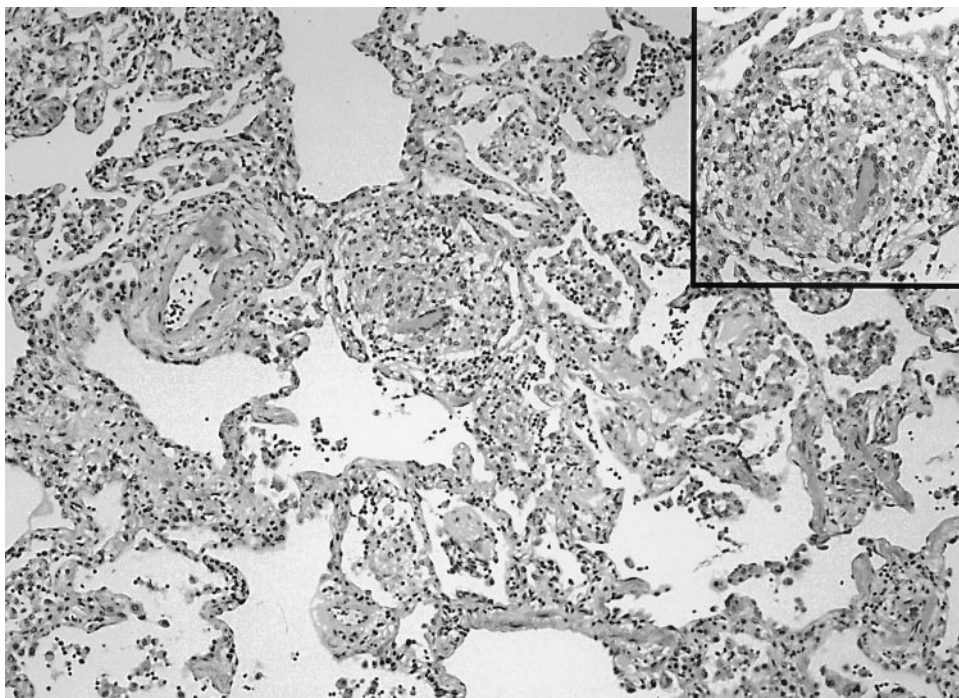


FIGURE 6. The histopathologic features of HP share some features of LIP, but the infiltrates are patchy in distribution and generally less intense, as shown in this low-power view (hematoxylin-eosin, original  $\times 100$ ). The loosely formed granulomas of hypersensitivity pneumonitis (insert) are within the interstitial spaces (hematoxylin-eosin, original  $\times 400$ ).

between these entities may require the clinical exclusion of inhaled antigens and drugs. The cellular variant of nonspecific interstitial pneumonia demonstrates a mild-to-moderate interstitial expansion by lymphocytic or lymphocytoplasmic cells and not the dense infiltrates of LIP. It should be recognized that nonspecific interstitial pneumonia and LIP represent lesions along a morphologic spectrum and that some overlap can exist.

LIP must be distinguished from pulmonary involvement by low-grade malignant lymphoproliferative diseases, such as small lymphocytic lymphoma/chronic lymphocytic leukemia, lymphoplasmacytoid lymphoma, mantle cell lymphoma, and extranodal marginal zone lymphoma of MALT type.<sup>104</sup> Diagnostic features suggesting lymphomatous involvement include a monotonous population of lymphoid cells centered on pulmonary lymphatics in the bronchovascular bundles, subpleural and interlobular septa, pleural infiltration including parietal pleural fibroadipose tissues, the presence of eosinophilic intranuclear inclusions within plasmacytoid cells indicating Ig-secreting cells producing monoclonal proteins (called *Dutcher bodies*) and the formation of parenchymal nodules (Fig 7).<sup>105</sup> Reactive germinal centers may be observed in both LIP and pulmonary low-grade lymphomas. Paraffin section immunohistochemical molecular techniques are cur-

rently available that allow accurate classification of malignant lymphoproliferative disorders of the lung.<sup>106</sup> More than 80% of primary pulmonary lymphomas are of the extranodal marginal zone type (called *MALTomas*). They usually present as single or multiple parenchymal consolidations centered on lymphatics, but can occasionally show a prominent interstitial distribution. Unlike small lymphocytic lymphoma/chronic lymphocytic leukemia that shows mature-appearing small lymphocytes, the composition in MALToma can include centrocyte-like cells, monocytoid cells, and plasmacytoid cells. Demonstration of light chain restriction by immunohistochemistry or flow cytometry is observed in  $> 50\%$  of cases. The application of antibody panels allows discrimination of MALToma from LIP and from the other malignant lymphomas. Extranodal marginal zone lymphoma expresses B-cell-associated antigens CD20+, CD19+, and CD79a+, and is in most cases CD5-, CD10-, CD23-, CD43+/-, cyclin D1-, and BCL2-. This immunophenotypic profile distinguishes them from small lymphocytic lymphoma/chronic lymphocytic leukemia (CD20weak+, CD19+, CD79a+, CD5+, CD23+, CD43+), mantle zone lymphoma (CD5+, CD10-, CD23-, CD43+, cyclin D1+, BCL2+), and small cleaved cell lymphoma (CD20+, CD19+, CD79a+, CD10+, BCL2+).<sup>107</sup>



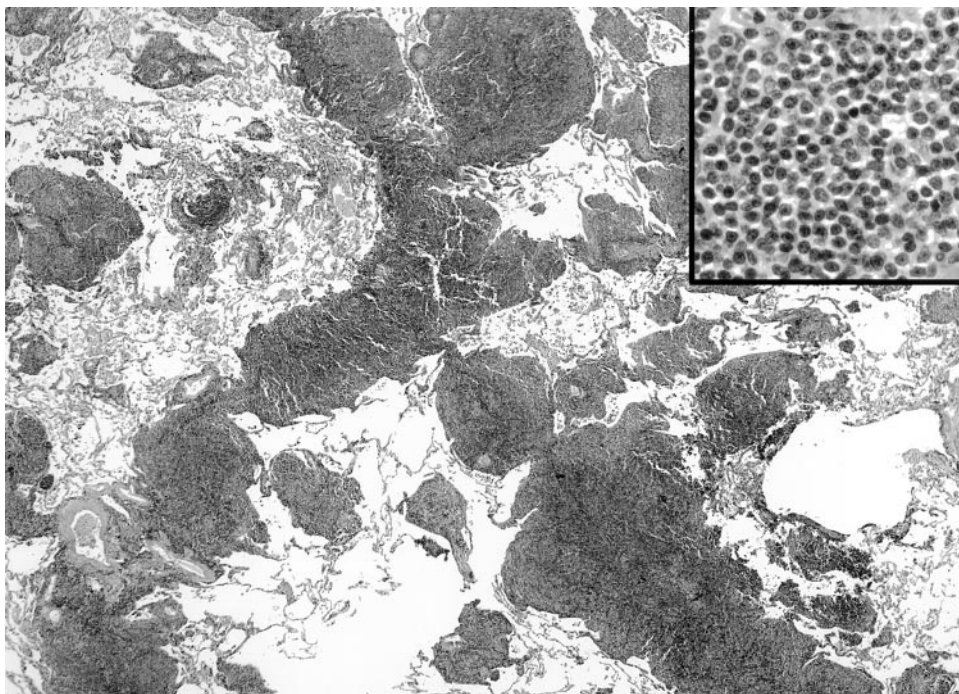


FIGURE 7. Pulmonary involvement by small lymphocytic lymphoma showing the classic nodular collections of neoplastic cells along a lymphatic distribution (hematoxylin-eosin, original  $\times 60$ ). High-power magnification (insert) shows a monotonous population of small lymphocytes (hematoxylin-eosin, original  $\times 400$ ).

#### DIAGNOSIS, TREATMENT, AND PROGNOSIS

Although the lymphocytic infiltration of LIP can sometimes be observed on transbronchial biopsy specimens, the definitive diagnosis requires thorascopic or open-lung biopsy specimens.<sup>15,108</sup> As previously discussed, immunohistochemical studies are required to establish the polyclonal nature of the infiltrate. An exception to this rule occurs in HIV-positive children; their radiographic pattern and symptoms are sufficiently distinctive that the diagnosis of LIP can be made confidently without invasive procedures.<sup>68</sup> In any case, when a histopathologic diagnosis of LIP is made, an investigation for potential associated conditions should be performed.

Controlled treatment trials have not been reported, and current therapeutic regimens are based largely on anecdotal experience. In the majority of published reports, corticosteroids have been the primary therapy, but other immunosuppressive agents, such as cyclophosphamide and chlorambucil, have been used.<sup>24</sup> The results have been variable. Some patients improve without therapy while others progress to advanced interstitial fibrosis despite immunosuppression. Schwarz<sup>109</sup> recommends a regimen similar to one recommended for the treatment of idiopathic bronchiolitis obliterans organizing

pneumonia; prednisone, 0.75 to 1.0 mg/kg/d (based on the patient's ideal weight and not to exceed 100 mg/d), is instituted for 8 to 12 weeks or until stabilization. Once the patient is in clinically stable condition, the dose is slowly tapered to 0.25 mg/kg/d and kept at that dose for another 6 to 12 weeks. Although the data are somewhat dated, approximately 50 to 60% of patients have responded to corticosteroids with symptomatic or radiographic stabilization or improvement.<sup>26</sup> Koss et al<sup>54</sup> noted that 4 of 13 patients treated with corticosteroids had complete clinical resolution after a mean follow-up period of 59 months. Over 82 months, four other patients in that series treated with corticosteroids remained in clinically and radiographically stable condition.

Single and multidrug antiretroviral therapy has resulted in clinical and radiographic resolution of LIP in some HIV-positive patients.<sup>110</sup> Newer approaches have been reported,<sup>111</sup> including the successful treatment of LIP in a 35-year-old HIV-positive man using a three-nucleoside analog regimen. There was a marked decline in viral load, increase in CD4 count, and both radiographic and clinical resolution of pulmonary parenchymal disease.

As in the case with therapy, prognosis is variable



and often unpredictable from clinical, morphologic, and radiographic parameters.<sup>26,54</sup> Stabilization or resolution of disease is reported in some patients, but in others there is progressive decline in pulmonary function and development of honeycomb lung. In general, death occurs in approximately 33 to 50% of patients within 5 years of diagnosis.<sup>26,62</sup> In one published series, 5 of 13 patients treated with corticosteroids died after a mean of only 8.6 months from the time of diagnosis.<sup>24</sup> This may in part be due to the older average age of this group of patients. Among the survivors, two patients had complete radiographic resolution of disease, four patients had mild improvement, and two patients remained clinically and radiographically unchanged at a median follow-up of 44 months. Another series reported similar findings with 5 of 13 patients dying while undergoing treatment with corticosteroids.<sup>54</sup> Of the remaining eight patients in that series, four patients had dramatic improvement and four patients had stabilization of LIP.

Most patients die of infectious complications related to immunosuppression, progressive pulmonary fibrosis, or transformation to malignant lymphoma.<sup>112,113</sup> In the past, LIP had been reported to progress to malignant lymphoma in up to 30% of cases. In retrospect, many of these cases were reclassified by immunohistochemical or molecular techniques as malignant lymphoma from the outset and were not LIP.<sup>104,114</sup> The risk of transformation to malignant lymphoma is not known but is likely infrequent. A more recent and realistic estimate is closer to 5% of patients with LIP acquire malignant, low-grade, B-cell lymphoma.<sup>10,25,54</sup> Reports of survival in children with HIV and LIP have varied. One study showed a significantly decreased mean survival of 33 months compared to HIV-positive children without LIP,<sup>68,115</sup> while other reports indicate a substantially better prognosis for these children compared to HIV-positive children with other AIDS-defining illnesses.<sup>116–118</sup> Mortality in HIV-positive adults is not adversely affected by LIP and, as previously discussed, the subset of patients with LIP and DILS live longer than HIV-positive adults without LIP.<sup>80</sup>

#### CONCLUSION

LIP is an interesting and complex polyclonal, inflammatory, lymphoid proliferation originating from hyperplasia of BALT, in which peribronchiolar and interstitial lymphocytes accumulate in response to various stimuli, including inhaled antigen. Although some cases remain idiopathic, LIP is usually found in association with one of several associated

diseases or conditions. Features of progressive dyspnea and cough in the setting of bilateral reticulonodular CXR infiltrates, or thin-walled cysts on high-resolution CT in a patient with Sjögren syndrome, should raise suspicion for the diagnosis. The pathogenesis of LIP is poorly understood. Some suggest viral infection may play an integral role. There has been little progress in the management of LIP and much about its cause and prognosis remains to be elucidated.

#### REFERENCES

- 1 Koss M. Pulmonary lymphoid disorders. *Semin Diagn Pathol* 1995; 12:158–171
- 2 Pabst R, Gehrke I. Is the bronchus-associated lymphoid tissue (BALT) an integral structure of the lung in normal mammals, including humans? *Am J Respir Cell Mol Biol* 1990; 3:131–135
- 3 Richmond I, Pritchard G, Ashcroft T, et al. Bronchus associated lymphoid tissue (BALT) in human lung: its distribution in smokers and non-smokers. *Thorax* 1993; 48:1130–1134
- 4 Agostini C, Chilosi M, Trentin L, et al. Pulmonary immune cells in health and disease: lymphocytes. *Eur Respir J* 1993; 6:1378–1401
- 5 Picker L. Physiological and molecular mechanisms of lymphocyte homing. *Annu Rev Immunol* 1992; 10:561–591
- 6 Bienenstock J, McDermott M, Clancy R. Respiratory tract defenses: role of mucosal lymphoid tissues. In: Ogra P, Mestecky J, Lamm M, et al, eds. *Mucosal immunology*. San Diego, CA: Academic Press, 1999; 283–292
- 7 Sminia T, van der Brugge-Gamelkoorn G, Jeurissen S. Structure and function of bronchus-associated lymphoid tissue (BALT). *Crit Rev Immunol* 1989; 9:119–150
- 8 Gould S, Isaacson P. Bronchus-associated lymphoid tissue (BALT) in human fetal and infant lung. *J Pathol* 1993; 169:229–234
- 9 Lipscomb M, Bice D, Lyons C, et al. The regulation of pulmonary immunity. *Adv Immunol* 1995; 59:369–455
- 10 Koss M. Pulmonary lymphoproliferative disorders. In: Churg A, Katzenstein A-L, eds. *The lung: current concepts*. Baltimore, MD: Williams and Wilkins, 1993; 145–194
- 11 Bienenstock J, Johnston N, Perey D. Bronchial lymphoid tissue: I. Morphologic characteristics. *Lab Invest* 1973; 28:686–692
- 12 Macklin C. Pulmonary sumps, dust accumulations, alveolar fluid and lymph vessels. *Acta Anat* 1955; 23:1–33
- 13 Isaacson P, Wotherspoon A, Pan L. Follicular colonization in B-cell lymphoma of mucosa-associated lymphoid tissue. *Am J Surg Pathol* 1991; 15:819–828
- 14 Gehrke I, Pabst R. The epithelium overlying rabbit bronchus-associated lymphoid tissue does not express the secretory component of immunoglobulin A. *Cell Tissue Res* 1990; 259:397–399
- 15 Teirstein AS, Rosen MJ. Lymphocytic interstitial pneumonia. *Clin Chest Med* 1988; 9:467–471
- 16 Pabst R. Compartmentalization and kinetics of lymphoid cells in the lung. *Reg Immunol* 1990; 3:62–71
- 17 McDermott MR, Bienenstock J. Evidence for a mucosal immunologic system: I. Migration of B-immunoblasts into intestinal, respiratory and genital tissues. *J Immunol* 1979; 122:1892–1898
- 18 Humphrey J, Sulitzneau B. The use of (14C) amino acids to

- study sites and rates of antibody synthesis in living hyper-immune rabbits. *Biochem J* 1958; 68:146–161
- 19 Kradin R, Mark EJ. Benign lymphoid disorders of the lung, with a theory regarding their development. *Hum Pathol* 1983; 14:857–867
  - 20 Brodie SJ, de la Rosa C, Howe JG, et al. Pediatric AIDS-associated lymphocytic interstitial pneumonia and pulmonary arterio-occlusive disease: role of VCAM-1/VLA-4 adhesion pathway and human herpesviruses. *Am J Pathol* 1999; 154:1453–1464
  - 21 Furfaro S, Berman J. The relation between cell migration and activation in inflammation: beyond adherence. *Am J Respir Cell Mol Biol* 1992; 7:248–250
  - 22 Katzenstein A. Primary lymphoid lung lesions. In: Katzenstein A-LA, ed. *Katzenstein and Askin's surgical pathology of non-neoplastic lung disease*. Philadelphia, PA: W.B. Saunders Company, 1997; 223–246
  - 23 Yousem SA, Colby TV, Carrington C. Follicular bronchitis/bronchiolitis. *Hum Pathol* 1985; 16:700–706
  - 24 Strimlan CV, Rosenow EC, Weiland L, et al. Lymphocytic interstitial pneumonitis: review of 13 cases. *Ann Intern Med* 1978; 88:616–621
  - 25 Fishback N, Koss M. Update on lymphoid interstitial pneumonitis. *Curr Opin Pulm Med* 1996; 2:429–433
  - 26 Liebow A, Carrington C. Diffuse pulmonary lymphoreticular infiltrations associated with dysproteinemia. *Med Clin North Am* 1973; 57:809–843
  - 27 Malamou-Mitsi V, Tsai M, Gal A, et al. Lymphoid interstitial pneumonia not associated with HIV infection: role of Epstein-Barr virus. *Mod Pathol* 1992; 5:487–491
  - 28 Barberà JA, Hayashi S, Hegele RG, et al. Detection of Epstein-Barr virus in lymphocytic interstitial pneumonia by *in situ* hybridization. *Am Rev Respir Dis* 1992; 145:940–946
  - 29 Andiman WA, Eastman R, Martin K, et al. Opportunistic lymphoproliferations associated with Epstein-Barr viral DNA in infants and children with AIDS. *Lancet* 1985; 2:1390–1393
  - 30 Kaan PM, Hegele RG, Hayashi S, et al. Expression of bcl-2 and Epstein-Barr virus LMP1 in lymphocytic interstitial pneumonia. *Thorax* 1997; 52:12–16
  - 31 Kramer MR, Saldana MJ, Ramos M, et al. High titers of Epstein-Barr virus antibodies in adult patients with lymphocytic interstitial pneumonitis associated with AIDS. *Respir Med* 1992; 86:49–52
  - 32 Katz BZ, Berkman AB, Shapiro ED. Serologic evidence of active Epstein-Barr virus-associated lymphoproliferative disorders of children with acquired immunodeficiency syndrome. *J Pediatr* 1992; 120:228–232
  - 33 Resnick L, Pitchenik A, Fisher E, et al. Detection of HIV-III/LAV-specific IgG, and antigen in bronchoalveolar lavage fluid from two patients with lymphocytic interstitial pneumonitis associated with AIDS-related complex. *Am J Med* 1987; 82:553–556
  - 34 Ziza J-M, Brun-Vezinet F, Venet A, et al. Lymphadenopathy-associated virus isolated from bronchoalveolar lavage fluid in AIDS-related complex with lymphoid interstitial pneumonitis [letter]. *N Engl J Med* 1985; 313:183
  - 35 Chayt KJ, Harper ME, Marselle LM, et al. Detection of HTLV-III RNA in lungs of patients with AIDS and pulmonary involvement. *JAMA* 1986; 256:2356–2359
  - 36 Ho D, Pomerantz R, Kaplan J. Pathogenesis of infection with immunodeficiency virus. *N Engl J Med* 1987; 317: 278–286
  - 37 Plata F, Antran B, Martins L. AIDS virus-specific cytotoxic T lymphocytes in lung disorders. *Nature* 1987; 328:348–351
  - 38 Hanna Z, Kay D, Cool M, et al. Transgenic mice expressing human immunodeficiency virus type I in immune cells develop a severe AIDS-like disease. *J Virol* 1998; 72: 121–132
  - 39 White CS, Agostini C, Israel-Biet B, et al. The growth and the control of human immunodeficiency virus in the lung: implications for highly active antiretroviral therapy. *Eur J Clin Invest* 1999; 29:964–972
  - 40 Agostini C, Zambello R, Trentin L, et al. HIV and pulmonary immune responses. *Immunol Today* 1996; 17:359–364
  - 41 Plata F, Antran B, Martins L, et al. AIDS virus-specific cytotoxic T lymphocytes in lung disorders. *Nature* 1987; 328:348–351
  - 42 Mayaud C, Cadranet J. HIV in the lung: guilty or not guilty. *Thorax* 1993; 48:1191–1195
  - 43 Montagnier L, Gruet J, Charmaret S, et al. Adaptation of lymphadenopathy associated virus (LAV) to replication in EBV-transformed B lymphoblastoid cell lines. *Science* 1984; 225:63–66
  - 44 Setoguchi Y, Takahashi S, Nukiwa T, et al. Detection of human T-cell lymphotropic virus type I-related antibodies in patients with lymphocytic interstitial pneumonia. *Am Rev Respir Dis* 1991; 144:1361–1365
  - 45 Deheinzeln D, Capelozzi V, Kairalla R, et al. Interstitial lung disease in primary Sjogren's syndrome. *Am J Respir Crit Care Med* 1996; 154:794–799
  - 46 Popa V. Lymphocytic interstitial pneumonia of common variable immunodeficiency. *Ann Allergy* 1988; 60:203–206
  - 47 Davies C, Juniper M, Gray W, et al. Lymphoid interstitial pneumonitis associated with common variable hypogammaglobulinemia treated with cyclosporine A. *Thorax* 2000; 55:88–90
  - 48 Palmas A, Tefferi A, Myers JL, et al. Late-onset noninfectious pulmonary complications after allogeneic bone marrow transplantation. *Br J Haematol* 1998; 100:680–687
  - 49 Perreault C, Cousineau S, D'Angelo G, et al. Lymphoid interstitial pneumonia after allogeneic bone marrow transplantation: a possible manifestation of chronic graft-vs-host disease. *Cancer* 1985; 55:1–9
  - 50 Ratjen FA, Schoenfeld B, Wiesemann HG. Pulmonary alveolar microlithiasis and lymphocytic interstitial pneumonitis in a ten year old girl. *Eur Respir J* 1992; 5:1283–1285
  - 51 Diccico BS, Anderson G. Lymphocytic interstitial pneumonitis following Legionnaire's pneumonia [letter]. *Chest* 1994; 105:325
  - 52 Chamberlain DW, Hyland RH, Ross DJ. Diphenylhydantoin-induced lymphocytic interstitial pneumonia. *Chest* 1986; 90:458–460
  - 53 Bakhos R, Gattuso P, Arcot C, et al. Pulmonary alveolar proteinosis: an unusual association with *Mycobacterium avium-intracellulare* infection and lymphocytic interstitial pneumonia. *South Med J* 1996; 89:801–802
  - 54 Koss M, Hochholzer L, Langloss J, et al. Lymphoid interstitial pneumonia: clinicopathological and immunopathologic findings in 18 cases. *Pathology* 1987; 19:178–185
  - 55 Pines A, Kaplinsky N, Olchovsky D, et al. Pleuro-pulmonary manifestations of systemic lupus erythematosus: clinical features of its subgroups: prognostic and therapeutic implications. *Chest* 1985; 88:129–135
  - 56 Benisch B, Peison B. The association of lymphocytic interstitial pneumonia and systemic lupus erythematosus. *Mt Sinai J Med* 1979; 46:398–401
  - 57 Yood R, Steigman D, Gill L. Lymphocytic interstitial pneumonitis in a patient with systemic lupus erythematosus. *Lupus* 1995; 4:161–163
  - 58 Uziel Y, Hen B, Cordoba M, et al. Lymphocytic interstitial pneumonitis preceding polyarticular juvenile rheumatoid arthritis. *Clin Exp Rheumatol* 1998; 16:617–619
  - 59 Montes M, Tomasi TJ, Noehren T, et al. Lymphoid inter-

- stitial pneumonia with monoclonal gammopathy. *Am Rev Respir Dis* 1968; 98:277–280
- 60 Levinson A, Hopewell PC, Stites D, et al. Coexistent lymphoid interstitial pneumonia, pernicious anemia, and agammaglobulinemia: comment on autoimmune pathogenesis. *Arch Intern Med* 1976; 136:213–216
  - 61 DeCoteau W, Tourville D, Ambrus J, et al. Lymphocytic interstitial pneumonia and autoerythrocyte sensitization syndrome: a case with deposition of immunoglobulins on the basement membrane. *Arch Intern Med* 1974; 134:519–522
  - 62 Nicholson A, Wotherspoon A, Diss T, et al. Reactive pulmonary lymphoid disorders. *Histopathology* 1995; 26:405–412
  - 63 Helman C, Keeton G, Benatar S. Lymphoid interstitial pneumonia with associated chronic active hepatitis and renal tubular acidosis. *Am Rev Respir Dis* 1977; 115:161–164
  - 64 Neil GA, Lukie BE, Cockcroft DW, et al. Lymphocytic interstitial pneumonia and abdominal lymphoma complicating celiac sprue. *J Clin Gastroenterol* 1986; 8:282–285
  - 65 Marks MJ, Haney PJ, McDermott MP, et al. Thoracic disease in children with AIDS. *Radiographics* 1996; 16:1349–1362
  - 66 Oldham SA, Barron B, Munden RF, et al. The radiology of the thoracic manifestations of AIDS. *Crit Rev Diagn Imaging* 1998; 39:259–338
  - 67 Nesheim SR, Lindsay M, Sawyer MK, et al. A prospective population-based study of HIV perinatal transmission. *AIDS* 1994; 8:1293–1298
  - 68 Rubinstein A, Morecki R, Goldman H. Pulmonary disease in infants and children. *Clin Chest Med* 1988; 9:507–517
  - 69 Centers for Disease Control. Classification system for HIV infection in children under 13 years of age. *MMWR Morb Mortal Wkly Rep* 1987; 36:225–230
  - 70 Centers for Disease Control. 1994 revised classification for human immunodeficiency virus infection in children less than 13 years of age. *MMWR Morb Mortal Wkly Rep* 1994; 43:1–10
  - 71 Travis WD, Fox CH, Devaney KO, et al. Lymphoid pneumonitis in 50 adult patients infected with the human immunodeficiency virus: lymphocytic interstitial pneumonitis vs nonspecific interstitial pneumonitis. *Hum Pathol* 1992; 23:529–541
  - 72 Suffredini AF, Ognibene FP, Lack E, et al. Nonspecific interstitial pneumonitis: a common cause of pulmonary disease in the acquired immunodeficiency syndrome. *Ann Intern Med* 1987; 107:7–13
  - 73 Griffiths MH, Miller RF, Semple SJ. Interstitial pneumonitis in patients infected with the human immunodeficiency virus. *Thorax* 1995; 50:1141–1146
  - 74 Saldana M, Mones JM, Buck B. Lymphoid interstitial pneumonia in Haitian residents of Florida [abstract]. *Chest* 1983; 84:347
  - 75 Solal-Celigny R, Couderc LJ, Herman D, et al. Lymphoid interstitial pneumonitis in acquired immunodeficiency syndrome related complex. *Am Rev Respir Dis* 1985; 131:956–960
  - 76 Itescu S, Brancato L, Winchester R. A sicca syndrome in HIV infection: association with HLA-DR5 and CD8 lymphocytes. *Lancet* 1989; 2:466–468
  - 77 Kazi S, Cohen P, Williams F, et al. The diffuse infiltrative lymphocytosis syndrome: clinical and immunogenetic features in 35 patients. *AIDS* 1996; 10:385–391
  - 78 Williams F, Cohen P, Jumshyd J, et al. Prevalence of the diffuse infiltrative lymphocytosis syndrome among human immunodeficiency virus type 1-positive outpatients. *Arthritis Rheum* 1998; 41:863–868
  - 79 Itescu S, Winchester R. Diffuse infiltrative lymphocytosis syndrome: a disorder occurring in human immunodeficiency virus-1 infection that may present as a sicca syndrome. *Rheum Dis Clin North Am* 1992; 18:683–697
  - 80 Itescu S. Diffuse infiltrative lymphocytosis syndrome in human immunodeficiency virus infection: a Sjogren's-like disease. *Rheum Dis Clin North Am* 1991; 17:99–115
  - 81 Itescu S, Brancato L, Buxbaum J, et al. A diffuse infiltrative CD8 lymphocytosis syndrome in human immunodeficiency virus (HIV) infection: a host immune response associated with HLA-DR5. *Ann Intern Med* 1990; 112:3–10
  - 82 Itescu S, Dalton J, Zhang H, et al. Tissue infiltration in a CD8 lymphocytosis syndrome associated with human immunodeficiency virus-1 infection has the phenotypic appearance of an antigenically driven response. *J Clin Invest* 1993; 91:2216–2225
  - 83 Walker B, Chakrabarti S, Moss B, et al. HIV-specific cytotoxic T lymphocytes in seropositive individuals. *Nature* 1987; 328:345–348
  - 84 Walker C, Moody D, Sites D, et al. CD8+ lymphocytes can control HIV infection *in vitro* by suppressing viral replication. *Science* 1986; 234:1563–1566
  - 85 Itescu S. Adult immunodeficiency and rheumatic disease. *Rheum Dis Clin North Am* 1996; 22:53–73
  - 86 Itescu S. Rheumatic aspects of acquired immunodeficiency syndrome. *Curr Opin Pulm Med* 1996; 1996:346–353
  - 87 Itescu S, Rose S, Dwyer E, et al. Certain HLA-DR5, and -DR6 major histocompatibility complex class II alleles are associated with a CD8 lymphocytic host response to human immunodeficiency virus type 1 characterized by low lymphocyte viral strain heterogeneity and slow disease progression. *Proc Natl Acad Sci U S A* 1994; 91:11472–11476
  - 88 Carrington C, Liebow A. Lymphocytic interstitial pneumonitis [abstract]. *Am J Pathol* 1966; 48:36a
  - 89 Pitt J. Lymphocytic interstitial pneumonia. *Pediatr Clin North Am* 1991; 38:89–95
  - 90 McGuinness G, Scholes J, Jagirdar J, et al. Unusual lymphoproliferative disorders in nine adults with HIV or AIDS: CT and pathologic findings. *Radiology* 1995; 197:59–65
  - 91 Johkoh T, Muller NL, Pickford HA, et al. Lymphocytic interstitial pneumonia: thin-section CT findings in 22 patients. *Radiology* 1999; 212:567–572
  - 92 Honda O, Johkoh T, Ichikado K, et al. Differential diagnosis of lymphocytic interstitial pneumonia and malignant lymphoma on high-resolution CT. *AJR Am J Roentgenol* 1999; 173:71–74
  - 93 Carignan S, Staples CA, Muller NL. Intrathoracic lymphoproliferative disorders in the immunocompromised patient: CT findings. *Radiology* 1995; 197:53–58
  - 94 Berdon WE, Mellins RB, Abramson SJ, et al. Pediatric HIV infection in its second decade: the changing pattern of lung involvement; clinical, plain film, and computed tomographic findings. *Radiol Clin North Am* 1993; 31:453–463
  - 95 Ichikawa Y, Kinoshita M, Koga T, et al. Lung cyst formation in lymphocytic interstitial pneumonia: CT features. *J Comput Assist Tomogr* 1994; 18:745–748
  - 96 Amorosa JK, Miller RW, Laraya-Cuasay L, et al. Bronchiectasis in children with lymphocytic interstitial pneumonia and acquired immune deficiency syndrome: plain film and CT observations. *Pediatr Radiol* 1992; 22:603–606
  - 97 Sheikh S, Madiraju K, Steiner P, et al. Bronchiectasis in pediatric AIDS. *Chest* 1997; 112:1202–1207
  - 98 Oldham SA, Castillo M, Jacobson FL, et al. HIV-associated lymphocytic interstitial pneumonia: radiologic manifestations and pathologic correlation. *Radiology* 1989; 170:83–87
  - 99 Prosper M, Omene JA, Ledlie, et al. Clinical significance of resolution of chest X-ray findings in HIV-infected children with lymphocytic interstitial pneumonitis (LIP). *Pediatr*



- Radiol 1995; 25(suppl 1):S243–S246
- 100 Lynch J, Blickman J, terMeulen D, et al. Radiographic resolution of lymphocytic interstitial pneumonitis (LIP) in children with human immunodeficiency virus (HIV): not a sign of clinical deterioration. *Pediatr Radiol* 2001; 31:299–303
  - 101 Constantopoulos SH, Papadimitriou C, Moutsopoulos HM. Respiratory manifestations in primary Sjogren's syndrome. *Chest* 1985; 88:226–229
  - 102 Kawabuchi B, Tsuchiya S, Nakagawa K, et al. Immunophenotypic and molecular analysis of a case of lymphocytic interstitial pneumonia. *Acta Pathol Jpn* 1993; 43:260–264
  - 103 Morris JC, Rosen MJ, Marchevsky A, et al. Lymphocytic interstitial pneumonia in patients at risk for the acquired immune deficiency syndrome. *Chest* 1987; 91:63–67
  - 104 Herbert A, Walters MT, Cawley MI, et al. Lymphocytic interstitial pneumonia identified as lymphoma of mucosa associated lymphoid tissue. *J Pathol* 1985; 146:129–138
  - 105 Turner R, Colby TV, Doggett R. Well differentiated lymphocytic lymphoma: a study of 47 patients with primary manifestations in the lung. *Cancer* 1984; 54:2088–2096
  - 106 Nicholson A, Wotherspoon A, Diss T, et al. Pulmonary B-cell non-Hodgkin's lymphomas: the value of immunohistochemical and gene analysis in diagnosis. *Histopathology* 1995; 26:395–403
  - 107 Jaffe E, Harris N, Stein H, et al., eds. *Pathology and genetics of tumors of hematopoietic and lymphoid tissues*. Lyon, France: IARC Press, 2001
  - 108 Vath R, Alexander C, Fulmer J. The lymphocytic infiltrative lung diseases. *Clin Chest Med* 1983; 1983:619–634
  - 109 Schwarz M. Lymphoplasmocytic infiltrations of the lung. In: Schwarz M, King TE Jr, eds. *Interstitial lung disease*. Hamilton, Ontario: B.C. Decker, 1998; 685–697
  - 110 Bach MC. Zidovudine for lymphocytic interstitial pneumonia associated with AIDS [letter]. *Lancet* 1987; 2:796
  - 111 Scarborough M, Lishman S, Shaw P, et al. Lymphocytic interstitial pneumonitis in an HIV-infected adult: response to antiretroviral therapy. *Int J STD AIDS* 2000; 11:119–122
  - 112 Banerjee D, Ahmad D. Malignant lymphoma complicating lymphocytic interstitial pneumonia: a monoclonal B-cell neoplasm arising in a polyclonal lymphoproliferative disorder. *Hum Pathol* 1982; 13:780–782
  - 113 Kradin R, Young J, Kradin L, et al. Immunoblastic lymphoma arising in chronic lymphoid hyperplasia of the pulmonary interstitium. *Cancer* 1982; 50:1339–1343
  - 114 Addis BJ, Hyek E, Isaacson P. Primary pulmonary lymphoma: a reappraisal of its histogenesis and its relationship to pseudolymphoma and lymphoid interstitial pneumonia. *Histopathology* 1988; 13:1–17
  - 115 Saldana MJ, Mones JM. Lymphoid interstitial pneumonia in HIV infected individuals. *Prog Surg Pathol* 1992; 12:181–215
  - 116 de Martino M, Tovo PA, Galli L, et al. Prognostic significance of immunologic changes in 675 infants perinatally exposed to human immunodeficiency virus. *J Pediatr* 1991; 119:702–709
  - 117 Tovo PA, de Martino M, Gabiano C, et al. Prognostic factors and survival in children with perinatal HIV-1 infection. *Lancet* 1992; 339:1249–1253
  - 118 Blanche S, Tardieu M, Ouliege AM, et al. Longitudinal study of 94 symptomatic infants with perinatally acquired human immunodeficiency virus infection. *Am J Dis Child* 1990; 144:1210–1215