

Postoperative Use of Bevacizumab as an Antifibrotic Agent in Glaucoma Filtration Surgery in the Rabbit

Farnaz Memarzadeh,^{1,2} Robit Varma,^{1,2,3} Le-Tien Lin,⁴ Jignesh G. Parikh,^{1,2} Laurie Dustin,³ Ana Alcaraz,⁵ and Dean Elliott^{1,2}

PURPOSE. To evaluate the efficacy of bevacizumab as an antifibrotic agent after trabeculectomy in rabbits.

METHODS. Forty-two rabbits underwent trabeculectomy and were randomly assigned to receive a postoperative course of seven subconjunctival injections of bevacizumab (1.25 mg, 25 mg/mL), 5-fluorouracil (5-FU; 5 mg, 50 mg/mL), or balanced salt solution (BSS; 0.1 mL, control). Bleb survival and characteristics were evaluated over a 30-day period. The animals were killed on postoperative day (PD)10, PD20, and PD30. Histology and immunohistochemistry of the surgical eyes was performed to evaluate and grade the amount of scarring and fibrosis in each group.

RESULTS. Bevacizumab significantly improved the outcome of filtration surgery in this model. Bevacizumab prolonged bleb survival compared with the 5-FU and control groups (16.0 ± 1.3 days vs. 6.9 ± 0.6 and 7.4 ± 0.85 days, respectively; $P < 0.001$). Bevacizumab-treated eyes had significantly larger and higher blebs than the control and 5-FU-treated groups ($P < 0.05$). Histologic analysis revealed that eyes treated with bevacizumab had significantly less postoperative scarring at the microscopic level at PD10 and PD20 ($P = 0.009$).

CONCLUSIONS. Postoperative subconjunctival injection of bevacizumab is associated with improved trabeculectomy bleb survival in the rabbit model. Bevacizumab may be a useful agent for improving success and limiting scar tissue formation after trabeculectomy. (*Invest Ophthalmol Vis Sci.* 2009;50:3233–3237) DOI:10.1167/iovs.08-2441

The most common reason for trabeculectomy failure is the development of fibrosis in the conjunctiva and episclera because of progressive fibroblast proliferation and collagen deposition at the site of the filtration bleb.^{1,2} This frequently leads to poor postoperative intraocular pressure control with subsequent progressive optic nerve damage.³ The use of adjunctive antifibrotic agents such as 5-fluorouracil (5-FU) and mitomycin C (MMC) has significantly improved the success

rate of filtration surgery. However, because of their nonspecific mechanisms of action, these agents can cause widespread cell death and apoptosis, resulting in potentially sight-threatening complications such as severe postoperative hypotony, bleb leaks, and endophthalmitis.^{4–7} Thus, alternative antifibrotic agents are needed.

Angiogenesis, which allows for early migration of inflammatory cells and fibroblasts into the wound and the release of key mitogenic cytokines such as fibroblast growth factor, is a critical component of the wound-healing process.^{8,9} Vascular endothelial growth factor (VEGF) is one of the most potent cytokines in wound angiogenesis. Blocking the angiogenic cascade by the use of anti-VEGF proteins may reduce fibroblast migration and proliferation and thus slow the wound-healing response. The inhibitory effect of certain angiogenesis inhibitors on human Tenon fibroblasts has been shown in vitro.¹⁰ Bevacizumab is an antibody against VEGF that has been approved by the US Food and Drug Administration for the treatment of colorectal cancer.¹¹ Several case reports have described the successful, off-label intravitreal use of bevacizumab for treatment of neovascularization associated with proliferative diabetic retinopathy, age-related macular degeneration, and neovascular glaucoma.^{12–14} Few case reports have described the use of intravitreal¹⁵ or subconjunctival¹⁶ bevacizumab injections for improving the success of trabeculectomy filtration surgery.

In this study, we describe the use of postoperative bevacizumab injections (Avastin; Genentech, San Francisco, CA) in a rabbit model of glaucoma filtration surgery. The study was designed to determine whether postoperative subconjunctival injections of bevacizumab can improve bleb survival in comparison with a control group and a group receiving postoperative subconjunctival injections of 5-FU.

MATERIALS AND METHODS

Forty-two New Zealand White rabbits, each weighing 2 to 3 kg, were included in this study. Approval of this protocol was obtained from the University of Southern California Institutional Animal Care and Use Committee, and all animals were treated in accordance with the ARVO Statement for the Use of Animals in Ophthalmic and Vision Research.

Trabeculectomy was performed on the right eye of each rabbit by the same surgeon. General anesthesia was induced by administration of ketamine 50 mg/kg and xylazine 5 mg/kg. Partial-thickness 8–0 silk suture was passed through the superior peripheral cornea, and the eye was infolded. A limbus-based conjunctival flap was fashioned in the superior quadrant, and the sclera was exposed. A rectangular, half-depth 3×3 -mm scleral flap was then prepared. After an approximately 2-mm sclerostomy was made, peripheral iridectomy was performed. The scleral flap was then loosely sutured with two 10-0 nylon sutures. The conjunctiva was closed with a single running 8-0 vicryl suture. Dexamethasone and neomycin ointment (Maxitrol; Maxitrol, Southfield, MI) was instilled at the end of the surgery. No other adjunctive treatment was given at the time of the surgery.

The animals were randomly allocated (14 per group) to receive a postoperative course of seven subconjunctival injections of bevacizumab.

From the ¹Doheny Eye Institute and the Departments of ²Ophthalmology and ³Preventive Medicine, Keck School of Medicine, University of Southern California, Los Angeles, California; ⁴Armed Forces Sung Shan General Hospital, Taipei, Taiwan, Republic of China; and ⁵Anatomic Pathology College of Veterinary Medicine, Western University of Health Sciences, Pomona, California.

Supported by an unrestricted grant from Research to Prevent Blindness. RV is a Research to Prevent Blindness Sybil B. Harrington Scholar.

Submitted for publication June 16, 2008; revised September 2 and November 11, 2008, and January 8, 2009; accepted April 22, 2009.

Disclosure: F. Memarzadeh, None; R. Varma, None; L.-T. Lin, None; J.G. Parikh, None; L. Dustin, None; A. Alcaraz, None; D. Elliott, None

The publication costs of this article were defrayed in part by page charge payment. This article must therefore be marked "advertisement" in accordance with 18 U.S.C. §1734 solely to indicate this fact.

Corresponding author: Rohit Varma, Doheny Eye Institute, Suite 4900, 1450 San Pablo Street, Los Angeles, CA 90033; rvarma@hsc.usc.edu.

zumab (1.25 mg, 25 mg/mL; Avastin; Genentech), 5-FU (5 mg, 50 mg/mL), or balanced salt solution (BSS; 0.1 mL, control). Injections were given on postoperative days (PD) 1, 3, 6, 7, 9, 11, and 14 under topical anesthesia (proparacaine) with a 30-gauge needle. Injections of bevacizumab and BSS were given into the bleb, with the needle entering at the temporal edge of the bleb. Injections of 5-FU were given into the inferior conjunctiva, 180° away from the bleb.

Baseline intraocular pressure (IOP) measurements of the study eyes were performed on the day of the surgery, under topical anesthesia and before the administration of general anesthesia. Measurements were performed with an applanation tonometer (Tonopen XL; Medtronic Solan, Jacksonville, FL). Three readings were taken and averaged. After surgery, all animals were examined by a masked observer daily until postoperative week one and then regularly, at least twice per week until PD30. IOP was measured at all postoperative visits. Bleb length, width, and height were measured with calipers and recorded. The vascularity of the bleb was graded on a scale of 0 to 3, as previously described¹⁷ (0, avascular; 1, normal vascularity; 2, hyperemic; 3, very hyperemic). Slit lamp examination was performed to assess the level of anterior chamber inflammation (0, quiet; 1, cells; 2, fibrin; 3, hypopyon) and depth (2, deep; 1, shallow; 0, flat). Corneal staining was noted to be present or absent.

Histology

On PD10, PD20, and PD30, two animals from each group were killed with a lethal dose of phenobarbital (120 mg/kg). The surgical eye, including the upper eyelid, was removed and fixed in 4% formaldehyde. The operative site was then dissected, dehydrated, and embedded in paraffin. Sequential 5- μ m sections were cut and stained with hematoxylin and eosin for general histologic observation and total cellularity, Masson trichrome stain to assess the level of collagen deposition and fibrosis, Verhoeff stain to assess the density of elastic fiber deposition, α -smooth muscle actin immunocytochemistry to identify the distribution of myofibroblasts, and proliferating cell nuclear antigen (PCNA) immunohistochemistry to assess the level of recent cell division. Staining level was graded by a masked observer based on a histologic grading scale of 0 to 4 (0, <1% of control; 1, 1%–25% of control; 2, 26%–50% of control; 3, 51%–75% of control; 4, 76%–100% of control). The group receiving postoperative injections of BSS at the corresponding time point served as the control.

Statistical Analysis

Primary end points for this analysis included bleb survival, bleb characteristics (height and area), and histologic grading. Bleb failure was defined as the appearance of a flat, vascularized, and scarred bleb. Bleb area and height, anterior chamber depth and activity, conjunctival vascularity, intraocular pressure, and mean score of histologic parameters (per time point) were compared between treatment groups using analysis of variance. For analysis of variance tests with $P < 0.05$, multiple comparison t -tests were performed to test for significance between treatment pairs. Kaplan-Meier survival estimates were obtained for each treatment group. Mean survival times were compared between treatment groups using the log-rank test. The level of significance applied to the statistical analysis was $P < 0.05$.

RESULTS

Of the 42 rabbits in the study, 40 completed the 30-day protocol. One animal in the 5-FU group died suddenly of unknown cause. One animal in the bevacizumab group developed a severe ocular infection in the operative eye on PD7 and was humanely killed.

Bleb Survival and Characteristics

Bevacizumab significantly improved the outcome of filtration surgery in this model. Bevacizumab prolonged bleb survival

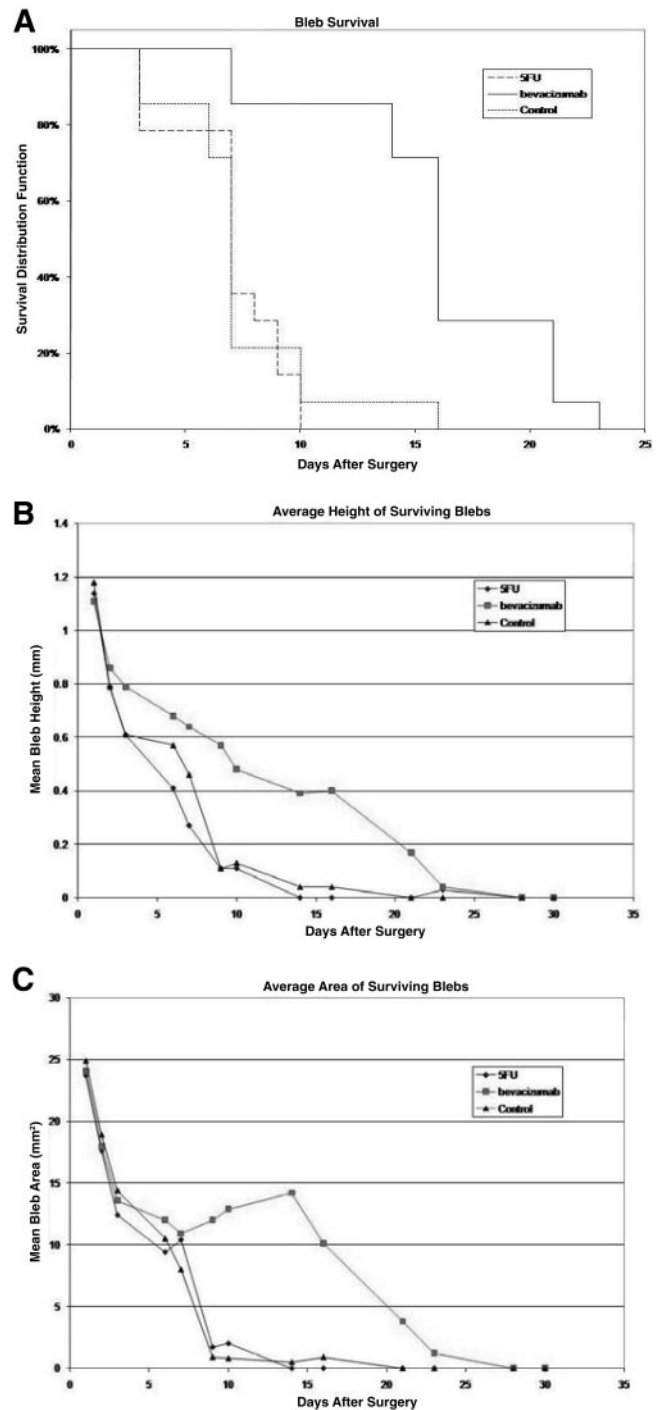


FIGURE 1. Bleb survival (A), height (B), and area (C) of the treatment groups. Bevacizumab treatment significantly prolonged bleb survival and resulted in larger and more elevated blebs compared with 5-FU and control treatment.

compared with the 5-FU and control groups, as shown in the Kaplan-Meier survival curve ($P < 0.001$; Fig. 1A). All blebs in the 5-FU group failed by PD10, and only one bleb in the control group was functioning by PD10. By PD16, all blebs had failed except two in the bevacizumab group. By PD23, all blebs in all groups had failed. The mean number of survival days were 7.4 ± 0.85 , 6.9 ± 0.6 , and 16.0 ± 1.3 for the control, 5-FU, and bevacizumab groups, respectively.

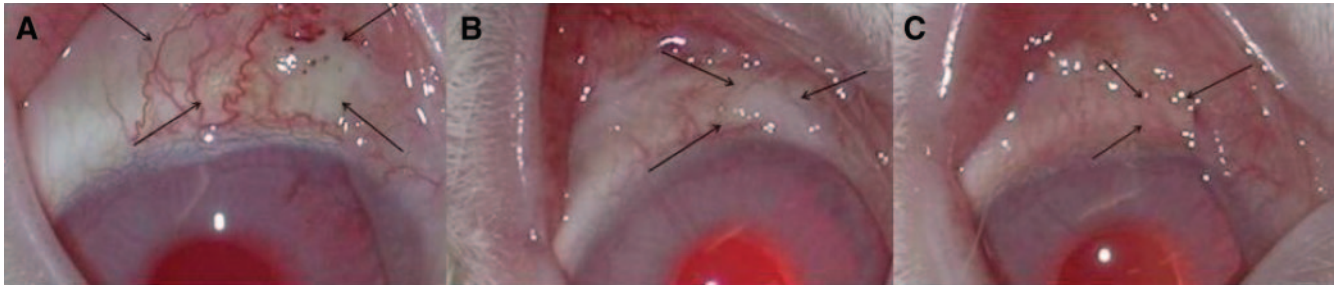


FIGURE 2. Bleb appearance associated with each treatment group at PD10. *Black arrows:* extent of bleb. Treatment with bevacizumab (A) was associated with larger and more elevated blebs compared with the scarred and flat appearance associated with 5-FU (B) and control (C) treatment.

Height and area of the blebs in the surgical eyes were compared among the groups. Bevacizumab-treated eyes had significantly larger and higher blebs than control and 5-FU treated eyes ($P < 0.05$; Figs. 1B, 1C, 2).

Analysis of mean intraocular pressure in the surgical eyes revealed no differences among the treatment groups throughout the study period ($P > 0.05$). Blebs in the bevacizumab group were slightly more avascular than in the control and

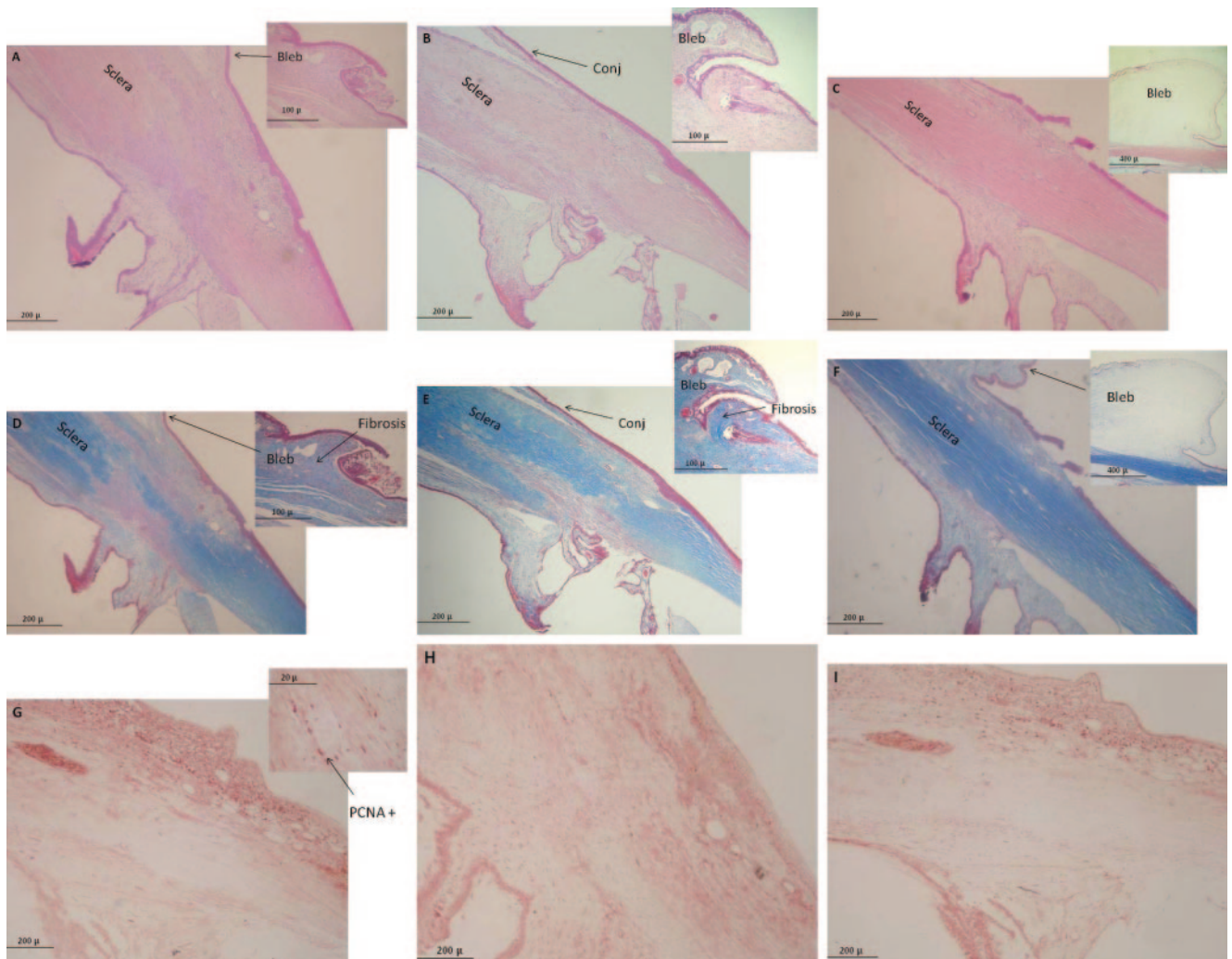


FIGURE 3. Histologic characteristics of the surgical site associated with the control group (A, D, G) and the 5-FU group (B, E, H) in comparison with the bevacizumab group (C, F, I) at PD10. (A–C) Hematoxylin and eosin stain for evaluation of general histologic observation and total cellularity. Compare the large, elevated, loosely architected bleb in the bevacizumab-treated group (C) with the flatter and more densely packed blebs in the control (A) and 5-FU (B) groups. Note the overall reduction in cellular infiltration of the sclera and conjunctiva (conj) in the bevacizumab group compared with the control and 5-FU groups. (D–F) Masson-Trichrome stain to evaluate the level of collagen deposition and fibrosis. Note the increased level of collagen deposition (fibrosis) in the blebs associated with the control (D) and 5-FU (E) groups compared with the (F) bevacizumab-treated group. (G–I) PCNA immunohistochemistry was used to assess the level of recent cell division/mitotic activity in the tissue. PCNA-positive/expressive cells stain red (*arrow*). The number of positively stained cells per four high-powered fields was graded. Bevacizumab-treated eyes (I) demonstrated a reduction in the number of PCNA-expressing cells compared with (G) control and (H) 5-FU eyes.

5-FU groups on PD3 and PD6, but this was not statistically significant ($P = 0.08$). There was no statistically significant difference in the grade of anterior chamber depth or anterior chamber inflammation between the groups. Mild, transient punctate epithelial staining was noted in all groups and was not different among groups.

Histologic Characteristics

Bevacizumab treatment caused significant reduction in the amount of postoperative scarring at the microscopic level at PD10 and PD20. Amount of collagen deposition, density of elastic fiber deposition, fibroblast differentiation into myofibroblasts, amount of tissue cellularity, and degree of mitotic activity/recent cell division in the tissue was reduced significantly in the bevacizumab-treated group (Fig. 3). Overall scarring grade was significantly lower in the bevacizumab group (1.95 ± 0.28) than in the control (3.23 ± 0.67) or 5-FU group (3.17 ± 0.53 ; $P = 0.009$).

DISCUSSION

The success of glaucoma filtration surgery is dependent on the degree of postoperative wound healing and the amount of scar tissue formation. Bleb failure occurs as fibroblasts proliferate and migrate toward the wound, eventually causing scarring and closure of the fistula tract. VEGF is vital molecule in the wound-healing response. Not only is it a powerful inducer of angiogenesis, it is a key growth factor and mediator in the signal transduction cascade leading to fibroblast and inflammatory cell migration and proliferation.^{9,18-20} Thus, blocking the central role of this compound in angiogenesis and wound repair may lead to a reduction in the formation of scar tissue and an overall slowing of the wound healing response. Evidence also suggests that anti-VEGF antibodies at higher concentrations may have a direct inhibitory effect on human Tenon fibroblasts in vitro by causing cell death (Qin Q, et al. *IOVS* 2008;49:ARVO E-Abstract 4541).

The wound-healing response in the rabbit compared with that in humans is known to be more aggressive and exaggerated and to entail routine failure of trabeculectomy surgical sites within few days to weeks.^{21,22} In this model of vigorous wound healing, we have demonstrated that the use of anti-VEGF antibodies can significantly improve the outcome of glaucoma surgery. Postoperative subconjunctival injection of bevacizumab more than doubled the bleb survival time and was associated with larger and more diffuse blebs, both on clinical and histologic inspection (Figs. 2, 3). Bevacizumab-treated eyes demonstrated a significant reduction in tissue cellularity, recent cell division, and collagen deposition on PD10 and PD20 compared with control and 5-FU treated animals.

In this study, there were no significant differences in IOP among the study groups. It is believed that intraocular pressure is not a reliable indicator of filtration in this model, partly because the preoperative IOPs in this model are within the normal range.¹⁷ Thus, in this study, bleb survival rather than IOP was used as the primary outcome measure.

Given the success of surgery in the bevacizumab-treated group and the antiangiogenic properties of bevacizumab, we were surprised to find that there was no difference in vascularity grading between groups. This may partly be explained by the aggressive wound-healing response in the rabbit and the possibility that the success of bevacizumab in this model may be mediated to a greater degree through blockage of the inflammatory signaling cascade regulated by VEGF rather than by its antiangiogenic properties. It is known that thin avascular blebs such as those commonly seen with the use of antifibrotic

agents (e.g., MMC) are associated with greater long-term complications (e.g., late endophthalmitis or chronic hypotony). Thus, the lack of avascularity associated with bevacizumab injections, at least in this model, may be beneficial.

Mean survival times for blebs in the control and 5-FU groups were similar at approximately 7 days. Although this is surprising, others have also found similar results in rabbit models in which bleb survival is not significantly different between control groups and groups receiving postoperative injections of 5-FU.^{17,23} This finding maybe partly be explained by the aggressive healing response in the rabbit or possibly by the distant location—180° away from the surgical site—of the injections. It would have been ideal for all injections in the study to have been performed at the same site. The site of the 5-FU injections in our study, however, was modeled after the Fluorouracil Filtering Surgery Study group and other animal studies looking at the efficacy of 5-FU as postoperative anti-scarring agents and to avoid the possibility of intraocular penetration of the drug.^{17,23,24}

In summary, we have shown that postoperative subconjunctival injection of bevacizumab is associated with improved trabeculectomy bleb survival in the rabbit model. Bevacizumab may be a useful agent for improving success and limiting scar tissue formation after trabeculectomy.

References

- Skuta GL, Parrish RK. Wound healing in glaucoma filtering surgery. *Surv Ophthalmol*. 1987;32:149-170.
- Hitchings RA, Grierson I. Clinicopathological correlation in eyes with failed fistulizing surgery. *Trans Ophthalmol Soc UK*. 1983;103:84-88.
- Migdal C, Gregory W, Hitchings R. Long-term functional outcome after early surgery compared with laser and medicine in open-angle glaucoma. *Ophthalmology*. 1994;101:1651-1656.
- Crowston JG, Akbar AN, Constable PH, et al. Antimetabolite-induced apoptosis in Tenon's capsule fibroblasts. *Invest Ophthalmol Vis Sci*. 1998;39:449-454.
- Yamamoto T, Varani J, Soong HK, Lichter PR. Effects of 5-FU and mitomycin C on cultured rabbit subconjunctival fibroblasts. *Ophthalmology*. 1990;97:1204-1210.
- Seah SK, Prata JA Jr, Minckler DS, et al. Hypotony following trabeculectomy. *J Glaucoma*. 1995;4:73.
- Parrish R, Minckler D. 'Late endophthalmitis': filtering surgery time bomb? *Ophthalmology*. 1996;103:1167-1168.
- Li J, Zhang YP, Kirsner RS. Angiogenesis in wound repair: angiogenic growth factors and the extracellular matrix. *Microsc Res Tech*. 2003;60:107.
- Asahara T, Bauters C, Zheng LP, et al. Synergistic effect of vascular endothelial growth factor and basic fibroblast growth factor on angiogenesis in vivo. *Circulation*. 1995;92(suppl):II365-II371.
- Wong J, Wang N, Miller JW, Schuman JS. Modulation of human fibroblast activity by selected angiogenesis inhibitors. *Exp Eye Res*. 1994;58:439-451.
- Hurwitz H, Fehrenbacher L, Novotny W, et al. Bevacizumab plus irinotecan, fluorouracil and leucovorin for metastatic colorectal cancer. *N Engl J Med*. 2004;350:2335-2342.
- Oshima Y, Sakaguchi H, Gomi F, Tano Y. Regression of iris neovascularization after intravitreal injection of bevacizumab in patients with proliferative diabetic retinopathy. *Am J Ophthalmol*. 2006;142:155-158.
- Avery RL, Pieramici DJ, Rabena MD, Castellarin AA, Nasir MA, Giust MJ. Intravitreal bevacizumab (Avastin) for neovascular age-related macular degeneration. *Ophthalmology*. 2006;113:363-372.
- Davidorf FH, Mouser JG, Derick RJ. Rapid improvement of rubeosis iridis from a single bevacizumab (Avastin) injection. *Retina*. 2006;26:354-356.

15. Jonas JB, Spandau UH, Schlichtenbrede F. Intravitreal bevacizumab for filtering surgery. *Ophthalmic Res.* 2007;39:121-122.
16. Kahook MY, Schuman JS, Noecker RJ. Needle bleb revision of encapsulated filtering bleb with bevacizumab. *Ophthalmic Surg Lasers Imaging.* 2006;37:148-150.
17. Mead AL, Wong TTL, Cordeiro F, Anderson IK, Khaw PT. Evaluation of anti-TGF- β 2 antibody as a new postoperative anti-scarring agent in glaucoma surgery. *Invest Ophthalmol Vis Sci.* 2003;44:3394-3401.
18. Hoeben A, Landuyt B, Highley MS, Wildiers H, Van Oosterom AT, De Bruijn EA. Vascular endothelial growth factor and angiogenesis. *Pharmacol Rev.* 2004;56:549-580.
19. Pollina EA, Legesse-Miller A, Haley EM, Goodpaster T, Randolph-Habecker J, Collier HA. Regulating the angiogenic balance in tissues. *Cell Cycle.* 2008;7:2056-2070.
20. Wilgus TA, Ferreira AM, Oberyszyn TM, Bergdall VK, Dipietro LA. Regulation of scar formation by vascular endothelial growth factor. *Lab Invest.* 2008;88:579-590.
21. Miller MH, Grierson I, Unger WI, Hitchings RA. Wound healing in an animal model of glaucoma fistulizing surgery in the rabbit. *Ophthalmic Surg.* 1989;20:350-357.
22. Gresses MG, Parrish RK II, Folber R. 5-Fluorouracil and glaucoma filtering surgery: an animal model. *Ophthalmology.* 1984;91:378-383.
23. Doyle JW, Sherwood MB, Khaw PT, McGrory S, Fran Smith M. Intraoperative 5-fluorouracil for filtration surgery in the rabbit. *Invest Ophthalmol Vis Sci.* 1993;34:3313-3319.
24. The Fluorouracil Filtering Surgery Study Group. Five-year follow-up of the Fluorouracil Filtering Surgery Study. *Am J Ophthalmol.* 1996;121:349-366.