

Polymyositis Associated with Hepatitis B Virus Cirrhosis and Advanced Hepatocellular Carcinoma

Kessarín Thanapirom, MD, Satimai Aniwan, MD, and Sombat Treeprasertsuk, MD

Department of Medicine, Chulalongkorn University, Bangkok, Thailand

Abstract

Polymyositis (PM) is an inflammatory condition of skeletal muscle and is believed to be a paraneoplastic syndrome associated with various types of cancer. PM associated with chronic hepatitis B virus (HBV)-related hepatocellular carcinoma (HCC) is very rare. We report a case of advanced HCC with chronic HBV cirrhosis that presented with proximal muscle weakness. Further investigation showed elevation of muscle enzymes, myopathic pattern of electromyography (EMG), and evidence of myositis compatible with PM. Lamivudine and 1 mg/kg of oral prednisolone were given. Two sessions of transcatheter arterial chemoembolization (TACE) were performed and sorafenib was started. Muscle enzymes normalized after 6 weeks of treatment. Unfortunately, 5 months after treatment, patient was readmitted and died of severe bacterial pneumonia.

Introduction

Polymyositis (PM) is an idiopathic inflammatory myopathy. It is a systemic disease that affects skeletal muscles and results in proximal muscle weakness. PM is associated with malignancy in 10–15% of patients.^{1–3} The 3 most commonly associated cancers are nasopharyngeal, lung, and breast cancer.⁴ Hepatocellular carcinoma (HCC)-associated PM is quite rare. We report a case of hepatitis B virus (HBV) cirrhosis with advanced HCC presenting with PM.

Case Report

A previously healthy 56-year-old male presented with a 6-week history of fever. Two weeks prior to admission, he developed progressive proximal muscle weakness. Through work-up, he was diagnosed with chronic HBV cirrhosis (Child-Pugh B; MELD 7) with advanced HCC. On physical examination, body temperature was 38°C, blood pressure was 120/75, and pulse rate was 92 bpm. Examination of the limbs showed normal tone without muscle wasting or tenderness. There was bilateral proximal weakness in both upper and lower limbs, with grade 3 of 5 in strength of both flexion and extension based on the Medical Research Council scale (MRC), with normal strength in distal limbs. His neck muscles were also weak. Deep tendon reflexes and sensation were normal. He had hepatomegaly and signs of chronic liver stigmata, but no ascites and no signs of hepatic encephalopathy. His Eastern Cooperative Oncology Group (ECOG) performance status score was 2.

Laboratory revealed albumin 2.2 g/dL, total protein 4.4 g/dL, aspartate aminotransferase (AST) 724 IU/L, alanine aminotransferase (ALT) 236 IU/L, total bilirubin 1.0 mg/dL, alkaline phosphatase 148 U/L, prothrombin time (PT) 14.1 s, international normalized ratio (INR) 1.14, and creatinine 0.8 mg/dL. His creatinine phosphokinase was 17,963 IU/L. Serum electrolytes and thyroid function tests were normal. His viral profiles were positive for HBV with DNA polymerase chain reaction (PCR) of 17,460 IU/mL. Tests for hepatitis C virus and HIV were negative. Alpha-fetoprotein (AFP) was 56,310 ng/mL (normal: <25 ng/mL). Autoantibodies including anti-dsDNA, anti-Jo-1, anti-neutrophilic cytoplasmic antibody, anti-RNP, anti-SSA, and anti-SSB were negative.

ACG Case Rep J 2014;1(3):167–169. doi:10.14309/crj.2014.39. Published online: April 4, 2014.

Correspondence: Sombat Treeprasertsuk, Department of Medicine, Faculty of Medicine, Chulalongkorn University, Rama4 Road, Pathumwan district, Bangkok 10330, Thailand (battan5410@gmail.com).

Copyright: © 2014 Thanapirom et al. This is an open-access article distributed under the terms of the Creative Commons Attribution License, which permits unrestricted use, distribution, and reproduction in any medium, provided the original author and source are credited.

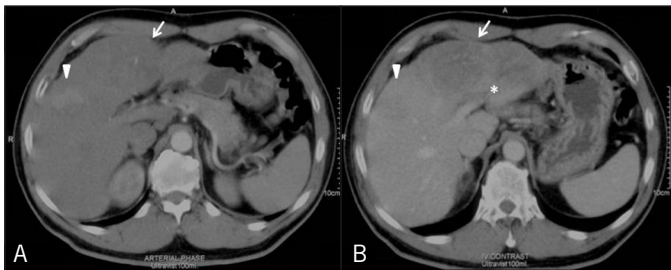


Figure 1. (A) Contrast-enhanced abdominal CT showing liver cirrhosis, an ill-defined, arterial-enhancing heterogeneous isodense to hypodense lesion (arrow), and (B) increased enhancement in the left lobe of the liver on venous phase with central necrosis (arrow) and left main portal vein thrombosis (asterisk).

Abdominal computed tomography (CT) showed liver cirrhosis with an ill-defined 12 x 7-cm, arterial-enhancing, heterogeneous, hypodense lesion in the left lobe of the liver with increased enhancement on venous and delay phase and central necrosis. The CT showed 2 additional arterial-enhancing lesions, size 6 x 7 cm and 3 x 3 cm, with contrast washout in the venous phase at hepatic segments V/VIII and VII and a left main portal vein thrombosis (Figure 1). Liver biopsy of the largest lesion was performed to exclude secondary liver neoplasm. Histology showed poorly differentiated carcinoma positive for glypican 3 (GPC3) and negative for CK7, CK20, and hepatocyte paraffin 1 (Figure 2), which was consistent with the diagnosis of HCC.

Electromyography (EMG) showed low-amplitude, short-duration action potentials with an early recruitment pattern, normal nerve conduction study, and repetitive nerve stimulation. These findings were highly suggestive of a myopathic pattern (Figure 3). Muscle biopsy showed increased endomysial connective tissue and lymphocyte infiltration with necrotic and regenerating myofibers (Figure 4). No vasculitis or perifascicular pattern was seen, and a diagnosis was polymyositis (PM) was confirmed. Prednisolone 1 mg/kg for PM treatment and lamivudine for preventing hepatitis B reactivation were given. Two sessions of transcatheter arterial chemoembolization (TACE) were performed. His creatinine kinase level decreased to normal after 6 weeks of treatment, but his muscle strength did not improve. Unfortunately, 5 months after treatment, he was readmitted with severe bacterial pneumonia and died after 16 days of hospitalization.

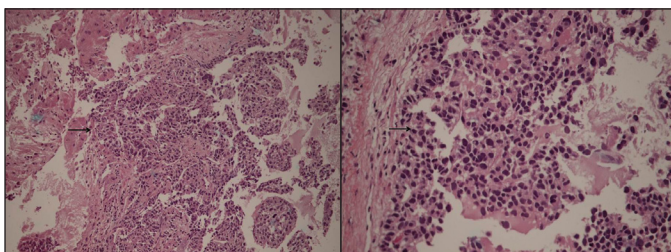


Figure 2. Histological examination of liver mass with haematoxylin and eosin (H&E) stain showing poorly differentiated carcinoma (arrows).

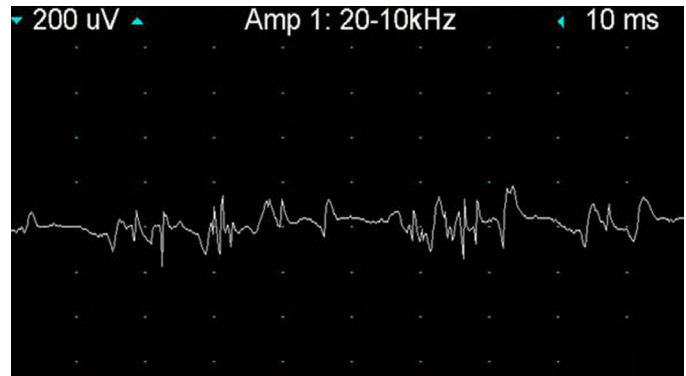


Figure 3. Needle electromyography showing low-amplitude, short-duration action potentials and early recruitment pattern.

Discussion

HCC-associated PM is a rare condition. Only 4 cases of PM associated with HCC have been reported (Table 1).⁵⁻⁸ A previous study showed that large tumor size and a high AFP level were commonly found in HCC patients who had paraneoplastic syndromes.⁹ Our patient had both a large tumor and a very high AFP level. The pathogenesis of PM has not been identified. A possible mechanism is that an autoimmune process triggered by the tumor leads to clonally expanded CD8-positive cytotoxic T-cells that invade muscle fibers and express major histocompatibility complex (MHC) class 1 antigen and release cytokines, causing muscle inflammation.^{10,11} HBV-associated PM has also been reported,¹² so it is possible that HCC, HBV, or both may have caused PM in this patient.

The role of steroids for treating HCC-associated PM is controversial. Physicians should be aware of an increased risk of infection when using high-dose corticosteroids in patients with advanced HCC and cirrhosis. Our patient's ability to maintain daily life was limited by his weakness; therefore, cor-

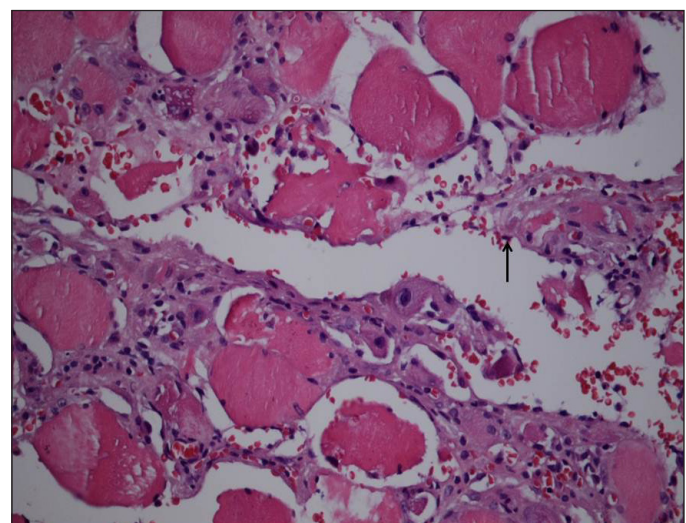


Figure 4. Muscle biopsy showing increased endomysial connective tissue infiltrated by lymphocytes with necrotic and regenerating myofibers.

Table 1. Summary of Baseline Characteristics, Treatment, and Outcome of Patients with HCC-Associated Polymyositis

	Case 1 ⁵	Case 2 ⁶	Case 3 ⁷	Case 4 ⁸
Sex	M	F	M	M
Age, y	72	50	37	55
Largest tumor size, cm	12	4.8	7	6
AFP, ng/mL	Elevated	Elevated	N/A	Normal
PM therapy	Corticosteroid	Corticosteroid	Corticosteroid, methotrexate	Corticosteroid
HCC therapy	Chemoembolization	Surgery	Bed supportive care	Chemotherapy
Outcomes after therapy				
Clinical weakness	Not improved	Improved	Improved	Not improved
Serum CPK	N/A	Decreased	Decreased	N/A
HCC-related death	Yes	Yes	Yes	Yes
Follow-up, mo	2	2	3	2

AFP = alpha-fetoprotein; CPK = creatinine phosphokinase; HCC = hepatocellular carcinoma; N/A = not applicable

ticosteroids were given after discussion with him. As a result of corticosteroid therapy, lamivudine was needed for prevention HBV reactivation. Lamivudine has good efficacy for this indication, particularly when the HBV DNA is low, as in our patient.^{13,14} Most patients with HCC-associated PM have had poor prognosis and treatment outcomes. Despite high-dose corticosteroids and surgery/chemoembolization for HCC management,⁵⁻⁸ few patients had improvement of muscle weakness and all died from HCC-related causes within 6 months after diagnosis.

Disclosures

Author contributions: K. Thanapirom wrote the first draft, collected the data, and conducted the literature research. S. Aniwan conducted the literature research and drafted the article. S. Treeprasertsuk reviewed the final draft and is the article guarantor.

Financial disclosure: No conflicts of interest or sources of funding to report.

Informed consent was obtained for this case report.

Received: January 4, 2014; Accepted: March 18, 2014

References

- Buchbinder R, Forbes A, Hall S, et al. Incidence of malignant disease in biopsy-proven inflammatory myopathy. A population-based cohort study. *Ann Intern Med.* 2001;134(12):1087-95.
- Hill CL, Zhang Y, Sigurgeirsson B, et al. Frequency of specific cancer

- types in dermatomyositis and polymyositis: A population-based study. *Lancet.* 2001;357(9250):96-100.
- Sigurgeirsson B, Lindelöf B, Edhag O, Allander E. Risk of cancer in patients with dermatomyositis or polymyositis. A population-based study. *N Engl J Med.* 1992;326(6):363-7.
- Ungprasert P, Leeaphorn N, Hosiriluck N, et al. Clinical features of inflammatory myopathies and their association with malignancy: A systematic review in Asian population. *ISRN Rheumatol.* 2013;2013:509354.
- Tekaya R, Abdelghni K, Abdelmoula L, et al. Hepatocellular carcinoma with polymyositis as an initial symptom: A case report. *Acta Clin Belg.* 2011;66(1):53-4.
- Kishore D, Khurana V, Raj A, et al. Hepatocellular carcinoma presenting as polymyositis: A paraneoplastic syndrome. *Ann Saudi Med.* 2011;31:533-5.
- Iba-Ba J, Assengone Zeh Y, Bignoumba Ibouili R, et al. Polymyositis and hepatocarcinoma: A case report from Gabon. *Med Trop. (Mars).* 2009;69(6):548.
- Kim MJ, Kim JA, Sung MS, Min JK. Hepatocellular carcinoma, polymyositis, rhabdomyolysis, and acute renal failure. *J Korean Med Sci.* 2004;19(6):891-4.
- Luo JC, Hwang SJ, Wu JC, Li CP, Hsiao LT, Lai CR, Chiang JH, et al. Paraneoplastic syndromes in patients with hepatocellular carcinoma in Taiwan. *Cancer.* 1999;86:799-804.
- Greenberg SA. Proposed immunologic models of the inflammatory myopathies and potential therapeutic implications. *Neurology.* 2007;69(21):2008-19.
- Andrés C, Ponyi A, Constantin T, et al. Dermatomyositis and polymyositis associated with malignancy: A 21-year retrospective study. *J Rheumatol.* 2008;35(3):438-44.
- Wong MH, Sockalingam S, Zain A. Polymyositis associated with hepatitis B: Management with entecavir and prednisolone. *Int J Rheum Dis.* 2011;14(3):e38-41.
- Lomba R, Rowley A, Wesley R, et al. Systematic review: The effect of preventive lamivudine on hepatitis B reactivation during chemotherapy. *Ann Intern Med.* 2008;148:519-28.
- Hsu C, Hsiung CA, Su IJ, et al. A revisit of prophylactic lamivudine for chemotherapy-associated hepatitis B reactivation in non-Hodgkin's lymphoma: A randomized trial. *Hepatology.* 2008;47(3):844-53.

Publish your work in ACG Case Reports Journal

ACG Case Reports Journal is a peer-reviewed, open-access publication that provides GI fellows, private practice clinicians, and other members of the health care team an opportunity to share interesting case reports with their peers and with leaders in the field. Visit <http://acgcasereports.gi.org> for submission guidelines. Submit your manuscript online at <http://mc.manuscriptcentral.com/acgcr>.