DOI: 10.5797/jnet.cr.2017-0107

Case Report

Aneurysmal Coil Embolization Using Gadolinium in a Patient with Allergy to Iodinated Contrast Medium: Case Report

Hiroya Uemura,[1] Rin Shimozato,[1] Noriko Matsunaga,[1] Mototaka Hayashi,[1] Hidesato Takezawa,[2] Yukihiro Hidaka,[3] and Akira Iijima[1]

Objective: We report a patient with allergy to iodinated contrast medium for whom a working angle was prepared based on preoperative CTA data, and coil embolization was performed using gadolinium (Gd) contrast medium at minimum.

Case Presentation: The patient was a 44-year-old female. For detailed examination of an unruptured cerebral aneurysm, contrast-enhanced CT was performed, leading to a diagnosis of an unruptured cerebral aneurysm, measuring 7 mm in maximum diameter, beside the left internal carotid artery. At this point, serious allergic symptoms were observed. Based on the CT data, we prepared a fluoroscopic image of the skull at a working angle on endovascular treatment. Under general anesthesia, body movement was restricted, and angiography with Gd contrast medium was performed by identifying the same angle of fluoroscopy as that on the above fluoroscopic image. Subsequently, coil embolization of the aneurysm was conducted using this image as a road map. Treatment was completed without complications. The volume of Gd contrast medium infused into the artery was 10 mL.

Conclusion: The treatment of an unruptured cerebral aneurysm with a small volume of Gd contrast medium could be performed by adapting image processing from the preoperative CT data to fluoroscopy at the time of treatment.

Keywords ▶ iodinated allergy, gadolinium, cerebral aneurysm, coil embolization

Introduction

Coil embolization of an unruptured cerebral aneurysm using neuroendovascular procedures is a treatment option in which the efficacy was demonstrated to be similar to that of clipping under craniotomy. For patients in whom craniotomy is difficult due to various reasons, it has become a more valuable option.

[1]*Department of Neuroendovascular Treatment, JCHO Tokyo Shinjuku Medical Center, Tokyo, Japan*
[2]*Department of Neurology, Saiseikai Shiga Hospital, Ritto, Shiga, Japan*
[3]*Department of Cardiology, Tomishiro Central Hospital, Tomigusuku, Okinawa, Japan*

Received: September 28, 2017; Accepted: February 12, 2018
Corresponding author: Rin Shimozato. Department of Neuroendovascular Treatment, JCHO Tokyo Shinjuku Medical Center, 5-1 Tukudo-cho, Shinjuku, Tokyo 162-8543, Japan
Email: imnrstz@gmail.com

However, when performing endovascular treatment for patients with severe allergy to iodinated contrast medium, preoperative steroid administration is not effective. In this study, we treated an unruptured cerebral aneurysm by performing newly devised angiography using gadolinium (Gd) instead of iodinated contrast medium, and obtained favorable results. We report the treatment strategy and course.

Case Presentation

Case: A 44-year-old female. She consulted a hospital with vertigo. MRI indicated the presence of an unruptured intracranial aneurysm.

To evaluate the morphology of the aneurysm, contrast-enhanced CT was performed. As contrast medium, 100 mL of iomeprol (Iomeron 350; Eisai Co., Ltd., Tokyo, Japan) was used. Simultaneously, serious symptoms of cutaneous allergy involving the limbs/trunk appeared. CT revealed a heart-shaped, unruptured aneurysm measuring 7 mm in maximum diameter and 3.9 mm in neck diameter, with the intracranial involvement of its superior region, at the anterior clinoid process beside the left internal carotid artery.

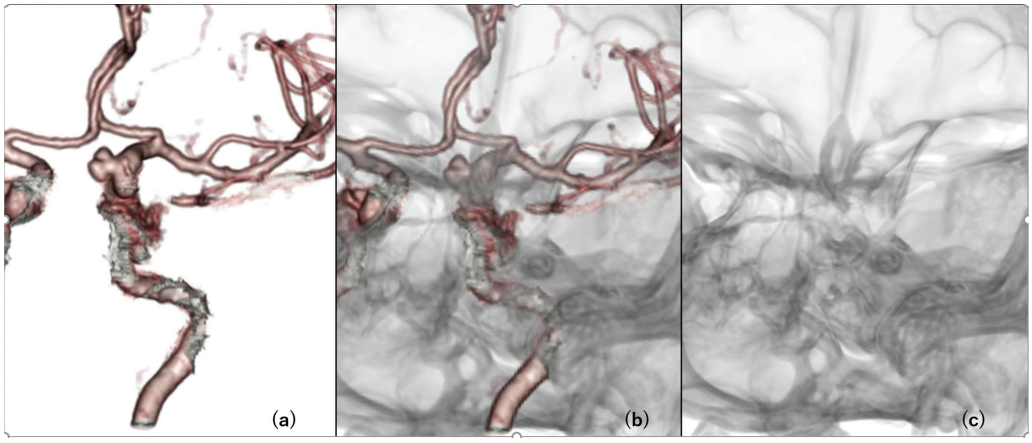

Fig. 1 (**a**) Optimal working angle for coil embolization was identified on 3D CT angiography images. (**b**) Fusion image shows relationship between intracranial artery and skull. (**c**) Skull image was derived after removal of arterial data in same angle with optimal working angle.

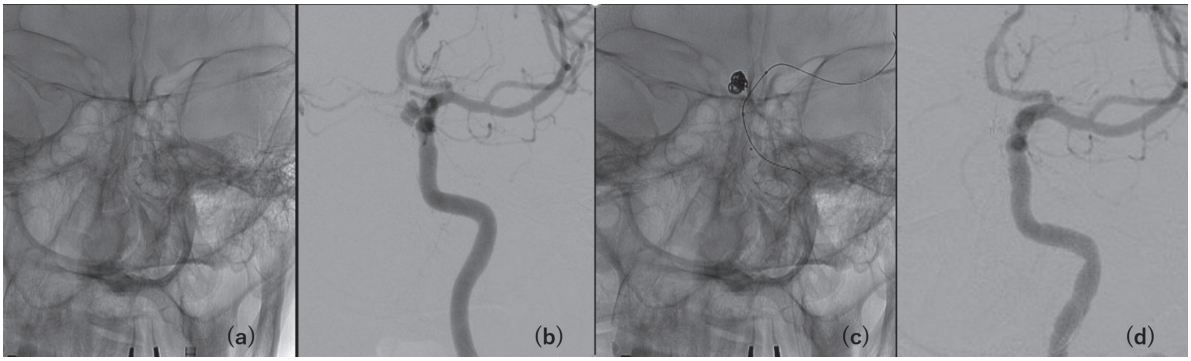

Fig. 2 Procedure of the endovascular treatment. (**a**) Working angle of C-arm was detected according to the prior 3D skull CT image. (**b**) Proper image for coil embolization was made with Gd injection. (**c**) Fluoroscopy shows the aneurysm filled with platinum coils. (**d**) Subtraction image with Gd indicates the disappearance of aneurysm. Note the angle was detected with fluoroscopy according to the 3D-CT image. With remodeling technique, aneurysm structure is clear without roadmap. Gd: gadolinium

The indication of treatment was considered to be necessary. Due to allergy to iodinated contrast medium, clipping under craniotomy was recommended. To obtain a second opinion, she consulted our hospital, and strongly wished to undergo treatment by neuroendovascular surgery. As the original 3D-CT data from the previous hospital were available, coil embolization with Gd was considered to be possible, and this procedure under general anesthesia was selected. The patient didn't have any complication, such as diabetes mellitus or renal dysfunction, other than allergy to iodinated contrast medium. To prepare 3D rearrangement images of contrast-enhanced CT, Ziostation 2 version 2.4.3.0 (Ziosoft, Inc., Tokyo, Japan) was used. Treatment was performed under general anesthesia in the radiologic examination room. As a fluoroscope, a Allura Xper FD20/10 (Philips Healthcare, Amsterdam, Nederland) was used.

The contrast-enhanced CT images obtained were processed with Ziostation 2 to prepare 3D vascular images. After visualizing the bone at an image angle corresponding to a working angle important for endovascular treatment, we prepared 3D fluoroscopic images of the bone alone (**Fig. 1**). Under general anesthesia, cephalic fluoroscopy was performed, and an angiographic image at a working angle necessary for treatment could be obtained by identifying an angle at which the same image as the above fluoroscopic image of the bone can be obtained (**Fig. 2**).

Endovascular treatment

As flare of the anterior chest was appeared on the induction of general anesthesia, betamethasone sodium phosphate (Rinderon; Shionogi & Co., Ltd., Osaka, Japan) was intravenously administered before the start of treatment. After inserting an 8 Fr sheath introducer (Super Sheath; Togo

Medikit Co.,Ltd., Tokyo, Japan) into the right femoral artery, heparin was intravenously injected. An 8 Fr guiding catheter (FUBUKI; Asahi Intecc, Co., Ltd., Aichi, Japan) was guided/inserted into the left internal carotid artery. It was possible to establish the same flat panel incidence angle as that on the 3D bone image that had been prepared, by reconciling the positional relationship between the orbit and upper margin of the petrous bone, as well as bone factors consisting of the periphery of the nasal bone/paranasal sinus. At this angle, angiography was performed, and treatment was started using fluoroscopic-image-fused road mapping (smart mask). As there was no sufficient contrast on fluoroscopic images, a function to prepare a smart mask based on angiographic images was effective.

For coil embolization of aneurysms using iodinated contrast medium, frontal/lateral imaging and 3D rotation are conducted to obtain information on aneurysms, and a working angle to be used for treatment is identified on Work Station prior to angiography. This may increase the volume of contrast medium. The process from femoral artery puncture to internal carotid angiography/smart mask preparation was completed with 5 mL of gadopentetate dimeglumine (Gd contrast medium) (Magnevist; Bayer Yakuhin, Ltd., Osaka, Japan). This contrast medium at 5 mL was diluted with physiological saline to prepare a total volume of 8 mL, and internal carotid angiography was manually performed. After guiding a HyperGlide 4 × 20 mm (Medtronic, Minneapolis, MN, USA) to the aneurysmal neck of the left internal carotid artery using this road map, a steam-shaped, double-angle Excelsior SL-10 preshaped J (Stryker, Kalamazoo, MI, U.S.A.) was guided/inserted into the aneurysm using a Transend EX platinum 0.014/205 cm (Stryker). When a Target 360 Standard 4.0 mm × 10 cm coil (Stryker) was rolled in the aneurysm, its morphology became clear under fluoroscopy. Under a remodeling technique at a standard fluoroscopic mode, two Target Helical Ultra 2.5 mm × 6 cm coils and one Target Helical Nano 1.5 mm × 3 cm coil (total: 4 coils, 25 cm) were inserted. The second session of angiography was conducted using approximately 5 mL of the Gd contrast medium. The results of angiography were reviewed, and embolization was completed (**Fig. 2**).

The volume of the Gd contrast medium infused into the aneurysm on pre-/postoperative internal carotid angiography was 10 mL. The volume used for a HyperGlide 4 × 20 mm (Medtronic) was 7 mL. The total volume was 17 mL.

Treatment was completed without complications. The post-treatment course was favorable. There was no new neurologic deficit, and the patient was discharged. Follow-up MRA has been performed, but there has been no recurrent aneurysm.

Discussion

Many studies have reported endovascular treatment with Gd contrast medium in the field of radiology. Recently, several studies in the field of neurosurgery indicated its efficacy. To our knowledge, studies regarding carotid artery stenting (CAS) for internal carotid artery stenosis[1–3] and a study regarding embolization for arteriovenous malformation (AVM) or dural arteriovenous fistula[4] were published. No study has reported coil embolization of aneurysms with Gd contrast medium.

In Japan, four products are commercially available as Gd contrast medium: gadopentetate dimeglumine (Magnevist), gadoterate meglumine (Magnescope; Terumo Corporation, Tokyo, Japan), gadodiamide hydrate (Omniscan; DAIICHI SANKYO COMPANY, LIMITED, Tokyo, Japan), and gadoteridol (Prohance; Eisai Co., Ltd., Tokyo, Japan). These products consist of ionic and non-ionic products, and differ in osmotic pressure and viscosity. The incidence of adverse reactions to non-ionic Gd contrast medium is lower than that to ionic products. The incidence of adverse reactions to low-osmotic-pressure/low-level-viscosity products is lower. The optimal dose of Gd contrast medium for contrast-enhanced MRI is 0.2 mL/kg, but there is no criterion for the dose of Gd contrast medium for arterial administration. The Food and Drug Administration (FDA) established the upper limit of the dose of Gd contrast medium for intravenous administration as 0.6 mL/kg.[5] A study indicated that the upper limit of the dose of Gd contrast medium to be administered into cerebral blood vessels was 65 mL.[6] In addition, another study performed the intra-arterial administration of Gd contrast medium at 1.7 mL/kg for endovascular embolism treatment in children with AVM, and reported that there were no complications, including renal dysfunction.[4]

Gadopentetate dimeglumine, which we used, is ionic, and its osmotic pressure and viscosity are higher than those of the other three products. However, a study indicated that there was no adverse reaction despite the use of gadopentetate dimeglumine at 60 mL,[2] and another study reported that there was no adverse event related to the use of gadopentetate dimeglumine at 45 mL.[6] Therefore, considering the safety of gadopentetate dimeglumine in clinical practice, we selected this contrast medium in the present case.

For endovascular treatment, we carefully conducted surgical operations, considering gadopentetate dimeglumine at 60 mL as the maximum dose of Gd contrast medium available at the onset of unexpected complications, such as intra-parent-vessel deviation of the coil mass, parent-vessel occlusion, and aneurysmal perforation. Coil embolization was performed while arranging environments so that the procedure can be switched to craniotomy without adhering to catheter management.

In the present case, the total intra-arterial infusion volume of Gd contrast medium was 10 mL; approximately, 0.2 mL/kg is within the permissible range in accordance with previous studies.

In the present case, treatment could be completed at a relatively low dose. This was because the aneurysmal position could be accurately evaluated without administering high-dose contrast medium by preparing fluoroscopic images of the skull at a working angle based on the 3D bone/vascular imaging information obtained in the previous hospital, as described above.

The concentration of Gd contrast medium commercially available in Japan is lower than that of iodinated contrast medium; therefore, contrast enhancement is reduced. According to previous studies, the contrast enhancement capacity of Gd contrast medium is 1/2 to 1/5 of that of iodinated contrast medium.[7] In the present case, a sufficient level of contrast enhancement was not achieved, and the function of preparing a smart mask based on angiographic images was useful. On the other hand, the osmotic pressure/viscosity of Gd contrast medium is lower than those of iodinated contrast medium; therefore, the risk of adverse reactions, including allergic reactions/renal dysfunction, is significantly lower, and most Gd-related symptoms are relatively mild: nausea/vomiting/pruritus.[8,9]

Even in patients in whom endovascular treatment with iodinated contrast medium is difficult due to a history of serious iodine allergy, the use of Gd contrast medium may facilitate standard endovascular treatment.

In the present case, flare of the anterior chest was appeared on anesthesia induction, suggesting hypersensitivity to various drugs used to induce anesthesia. However, there was no allergic symptom during subsequent endovascular treatment with Gd. During the postoperative course, there was no complication related to Gd contrast medium.

Recently, a study indicated the association between the use of Gd contrast medium for contrast-enhanced MRI and nephrogenic systemic fibrosis (NSF), and another study reported that the administration of Gd contrast medium to patients with diabetes mellitus/chronic kidney disease induced acute renal failure or pancreatitis.[10] The use of Gd contrast medium in patients with diabetes mellitus/renal dysfunction should be carefully examined. It is necessary to explain risks related to the use of Gd contrast medium to patients before treatment.

In the present case, the 3D-CT data were available, and it was possible to identify a working angle by simple image processing. Advances in image processing techniques have facilitated the fusion of CT information with MRI information. For patients with a history of serious iodine allergy, it is possible to prepare 3D images of CT bone conditions and parent vessel-aneurysm fusion images by MRA. The use of the procedure similar to that adopted in the present case facilitates coil embolization of unruptured aneurysms in the absence of iodinated contrast medium.

Conclusion

We reported a patient with a history of iodine allergy for whom coil embolization of an unruptured cerebral aneurysm with Gd contrast medium was performed. In some patients, standard endovascular treatment is difficult due to serious iodine allergy. We suggested that, among such patients, coil embolization of cerebral aneurysms may be performed for some patients by adopting Gd contrast medium instead of iodinated contrast medium and modifying standard procedures. In addition, in the present case, treatment could be completed with a relatively low dose of Gd contrast medium by utilizing preoperative CTA data. There are various restrictions or modifications in comparison with treatment with iodinated contrast medium, but, currently, endovascular treatment with Gd contrast medium is a therapeutic strategy to be considered as an option of endovascular treatment for cerebral aneurysms.

Disclosure Statement

There is no conflict of interest regarding this article.

References

1) Matsubara N, Miyachi S, Izumi T: [Carotid angioplasty and stenting using gadolinium in a patient allergic to iodinated contrast medium: case report]. *Curr Pract Neurosurg* 2008; 18: 93–99. (in Japanese)
2) Burry MV, Cohen J, Mericle RA: Use of gadolinium as an intraarterial contrast agent for pediatric neuroendovascular procedures. *J Neurosurg* 2004; 100: 150–155.

3) Omary RA, Frayne R, Unal O, et al: Intraarterial gadolinium-enhanced 2D and 3D MR angiography: a preliminary study. *J Vasc Interv Radiol* 1999; 10: 1315–1321.
4) Nussbaum ES, Casey SO, Sebring LA, et al: Use of gadolinium as an intraarterial contrast agent in digital subtraction angiography of the cervical carotid arteries and intracranial circulation. Technical note. *J Neurosurg* 2000; 92: 881–883.
5) Nagashima H, Sakamoto H, Sano Y, et al: [Fundamental study of DSA images using gadolinium contrast agent]. *Nihon Hoshasen Gijutsu Gakkai Zasshi* 2002; 58: 1369–1376. (in Japanese)
6) Parodi JC, Ferreira LM: Gadolinium-based contrast: an alternative contrast agent for endovascular interventions. *Ann Vasc Surg* 2000; 14: 480–483.
7) Katayama H, Yamaguchi K, Kozuka T, et al: Adverse reactions to ionic and nonionic contrast media. A report from the Japanese committee on the safety of contrast media. *Radiol* 1990; 175: 621–628.
8) Schenker MP, Solomon JA, Roberts DA: Gadolinium arteriography complicated by acute pancreatitis and acute renal failure. *J Vasc Interv Radiol* 2001; 12: 393.
9) Amar AP, Larsen DW, Teitelbaum GP: Percutaneous carotid angioplasty and stenting with the use of gadolinium in lieu of iodinated contrast medium: technical case report and review of the literature. *Nerurosurg* 2001; 49: 1262–1265; discussion 1262–1266.
10) Yaganti V, Alani F, Yaganti S, et al: Use of gadolinium for carotid artery angiography and stenting in patients with renal insufficiency. *J Ren Care* 2009; 35: 211–218.