CASE REPORT JSLS

# Laparoscopic Suture Repair of a Perforated Gastric Ulcer in a Severely Cirrhotic Patient With Portal Hypertension: First Case Report

Paolo Gentileschi, MD, Piero Rossi, MD, Antonio Manzelli, MD, Francesca Lirosi, MD, Francesca Susanna, MD, Vito Maria Stolfi, MD, Claudio Spina, MD, Achille L. Gaspari, MD

## ABSTRACT

**Background:** Open digestive surgery in cirrhotic patients is associated with high morbidity and mortality. Laparoscopy in this setting has the potential to reduce postoperative complications. Laparoscopic treatment of a perforated gastric ulcer in a severely cirrhotic patient with portal hypertension is herein described.

**Methods:** A 75-year-old woman affected by cirrhosis of the liver (Child class C) and chronic gastric ulcer presented with acute abdominal pain. The diagnosis of perforation was made with plain films of the abdomen and computed tomography. Diagnostic laparoscopy showed intense peritonitis due to a perforated ulcer of the anterior gastric wall, 2 cm proximal to the pylorus. Suture closure and placement of an omental patch were performed laparoscopically.

**Results:** Postoperative recovery was complicated by a minor leak of the gastric suture, managed by total parenteral nutrition. Closure of the gastric wound was demonstrated by Gastrografin studies on the 10th postoperative day. The patient was discharged on the 16th postoperative day. At 3-months follow-up, the patient is alive and free of gastric disease.

**Key Words:** Liver Cirrhosis, Perforated peptic ulcer, Laparoscopy.

Department of Surgery, University of "Tor Vergata", Rome, Italy (all authors).

Address reprint requests to: Paolo Gentileschi, MD, Via A. Bevignani, 18, 00162, Rome, Italy. Telephone: 39 06 20902927, Fax: 39 06 20902926, E-mail: gentilp@yahoo.com



## INTRODUCTION

Open digestive surgery in the cirrhotic patient is associated with high mortality and morbidity because of the increased risk of intraoperative bleeding, postoperative hepatic failure, and sepsis with the potential of multiple organ failure.[1] For these reasons, many investigators have historically considered cirrhosis of the liver a contraindication for laparoscopic surgery. Recent studies[2-4] have demonstrated that uncomplicated laparoscopic procedures, such as cholecystectomy, are feasible in the cirrhotic patient and are as safe as conventional open surgery.

No case of perforated gastric ulcer in a cirrhotic patient treated by laparoscopy has been reported in the literature. The case of a 75-year-old woman affected by severe cirrhosis of the liver and perforated gastric ulcer is here presented.

## CASE REPORT

A 75-year-old woman presented with a 4-hour history of diffuse abdominal pain. Her clinical background consisted of hypertension, type II diabetes, gallstones, a chronic gastric ulcer, lower limb edema, and hepatitis C virus (HCV)-related liver cirrhosis with ascites, neurological disorders, gastroesophageal varices, poor nutritional status, serum bilirubin 6.3 mg/dL, serum albumin 2.5 g/100 mL (Child class C). Clinical examination showed a firm board-like abdominal appearance on palpation, with rigidity of the rectus muscles. Rebound tenderness was present in all 4 quadrants and was worse in the epigastric region. Routine laboratory data showed aspartate aminotransferase (AST) 161 U/L, alanine aminotransferase (ALT) 142 U/L, blood urea nitrogen (BUN) 30 mg/dL, serum sodium 124 mEq/L, serum potassium 5.6 mEq/L, white blood cells 22 900 cells per $mm^3$, activated partial thromboplastin time (aPTT) 90.0 seconds, international normalized ratio (INR) 1.43. The plain radiograph of the abdomen demonstrated free intraperitoneal air **(Figure 1)**, and a computed tomography (CT) scan confirmed the presence of free intraperitoneal air and subdiaphragmatic effusion **(Figure 2)**. A laparoscopic approach was planned, and surgery was performed 8 hours after the first symptoms appeared.

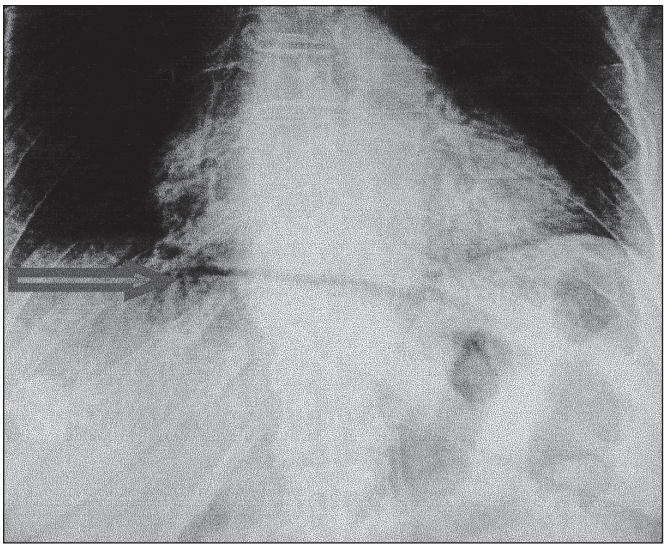

**Figure 1.** Free intraperitoneal air was clearly demonstrated by plain films of the abdomen.

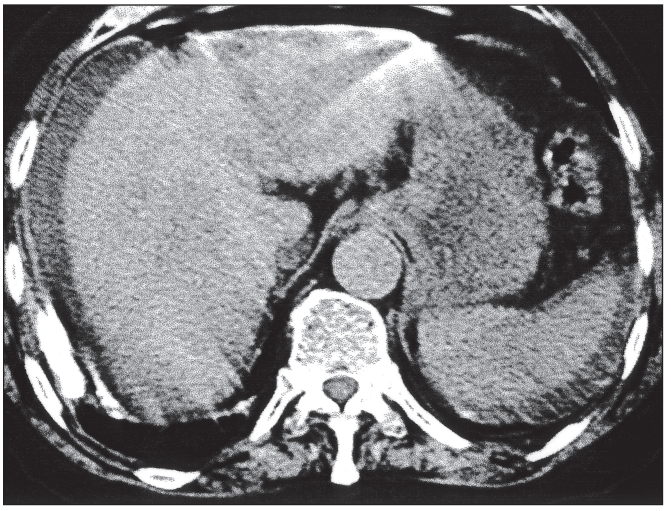

**Figure 2.** CT scan confirmed the presence of free intraperitoneal air, showing subdiaphragmatic effusion.

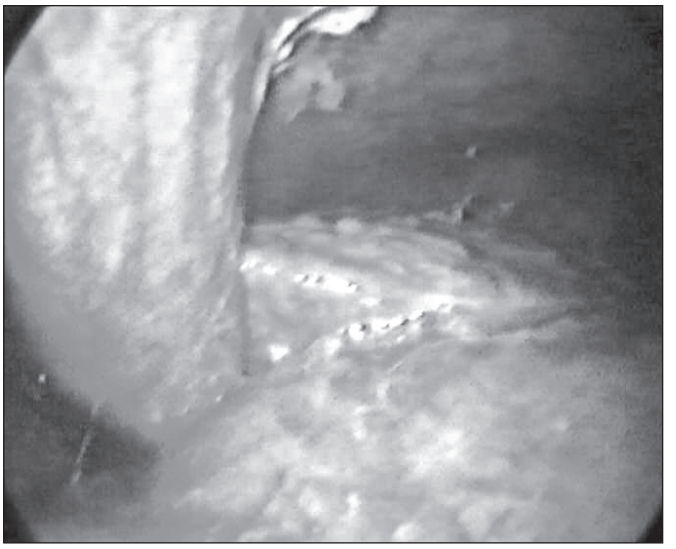

**Figure 3.** A severe form of cirrhosis of the liver was confirmed by laparoscopy.

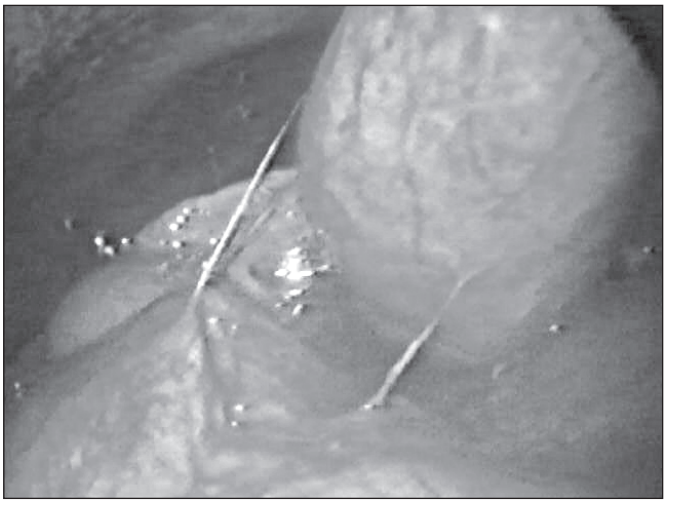

**Figure 4.** Laparoscopy revealed diffuse peritonitis.

The patient was placed on the operating table in a supine position with the surgeon standing between the legs. General anesthesia was administered and the abdomen prepped and draped in the usual sterile fashion. Pneumoperitoneum was obtained with an open umbilical approach. The camera port was inserted and diagnostic laparoscopy was performed. A severe form of cirrhosis of the liver was confirmed **(Figure 3)**, and the entire peritoneal cavity was found to be affected by diffuse peritonitis **(Figure 4)**. Three more ports were inserted under direct vision. Using the suction/irrigation device, the hepatoduodenal ligament was freed of strong adhesions and carefully inspected. A perforation, 1 cm in diameter, was present in the anterior wall of the stomach, 2 cm proximal to the pylorus **(Figure 5)**. The margins of the gastric wound were sharply fenced, and the specimen

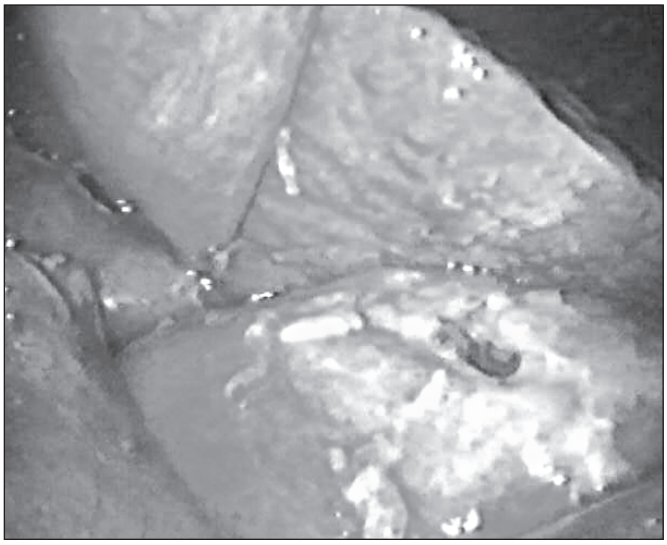

**Figure 5.** A perforation, 1 cm in diameter, was demonstrated in the anterior wall of the stomach, 2 cm proximal to the pylorus.

was sent for histologic examination. An interrupted suture, using Vicryl 2-0, was performed using an intracorporeal knot-tying technique **(Figure 6)**. An omental patch was also sutured to the gastric wall **(Figure 7)**. A methylene blue test through the nasogastric tube showed complete closure with no leakage. The abdomen was extensively irrigated, and 2 Jackson Pratt, drains were left in situ. The total operation time was 110 minutes, and blood loss was slight. No intraoperative complications occurred. Intravenous antibiotics and proton pump inhibitors were started preoperatively and continued for 10 days. Total parenteral nutrition was started and a nasogastric tube was left in place for 3 days. The early postoperative course was uneventful. A Gastrografin, study was performed on the 5th postoperative day that showed a minor leak from the gastric wound **(Figure 8)**, managed by total parenteral nutrition for 5 additional days. Another Gastrografin, study, performed on the 10th postoperative day, showed complete closure of the gastric suture **(Figure 9)**. Drains were removed and peroral nutrition was started. An oral proton pump inhibitor was prescribed after restarting peroral nutrition. The patient was discharged on the 16th postoperative day. A histology study showed a chronic gastric ulcer with no evidence of malignancy. At 3-months follow-up, the patient is alive and free of clinical peptic symptoms.

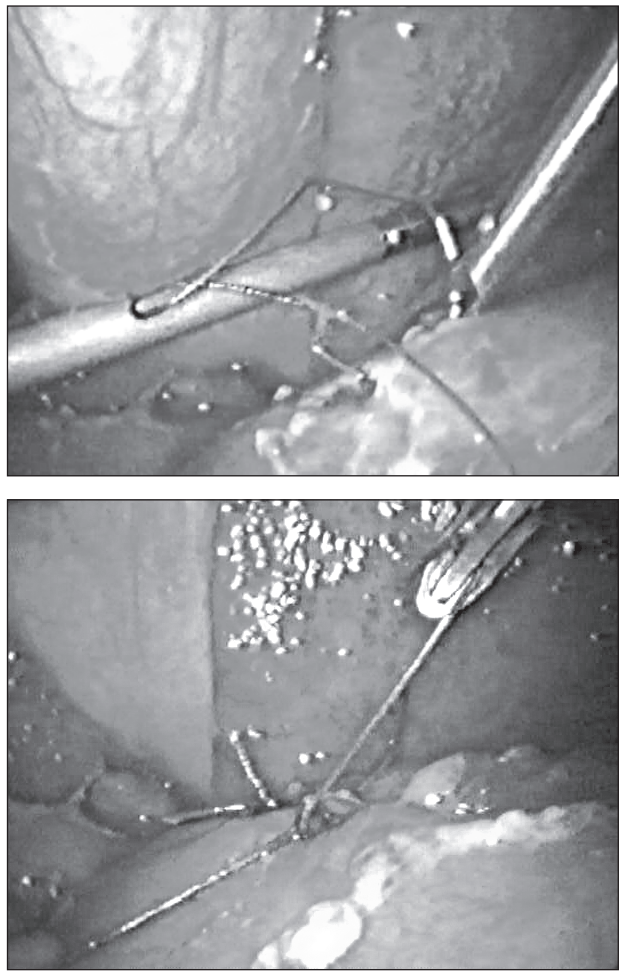

**Figure 6.** Suture closure and intracorporeal knot-tying technique were performed.

## DISCUSSION

Several investigators have reported the high morbidity and mortality of open digestive surgery in the cirrhotic patient.[1,5-7] In these reports, it is documented that the greater the severity of the cirrhosis, the greater is the potential of complications. As for cholecystectomy, Schwartz[1] reported a 27.3% mortality, and Aranha et al[5] reported a mortality of 83% in patients where the prothrombin time (PT) was elevated >2.5 seconds. Garrison et al[6] reported a 63% mortality in cirrhotic patients undergoing abdominal operations with PT elevated >2.5 seconds. Increased risk of intraoperative bleeding, post-

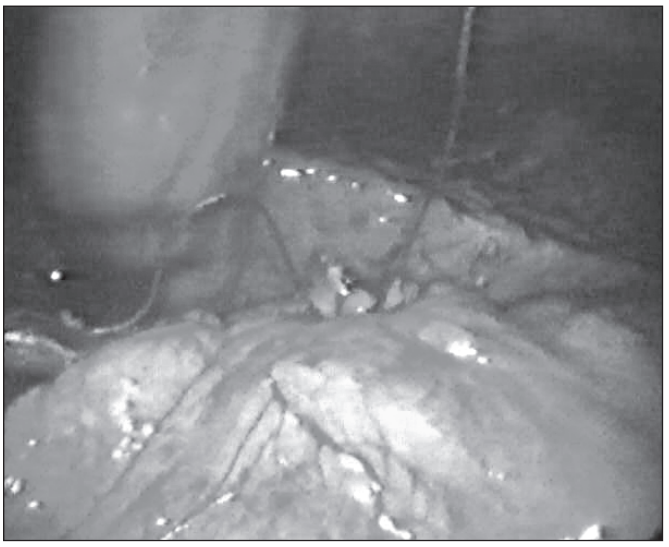

**Figure 7.** An omental patch was also sutured to the gastric wall.

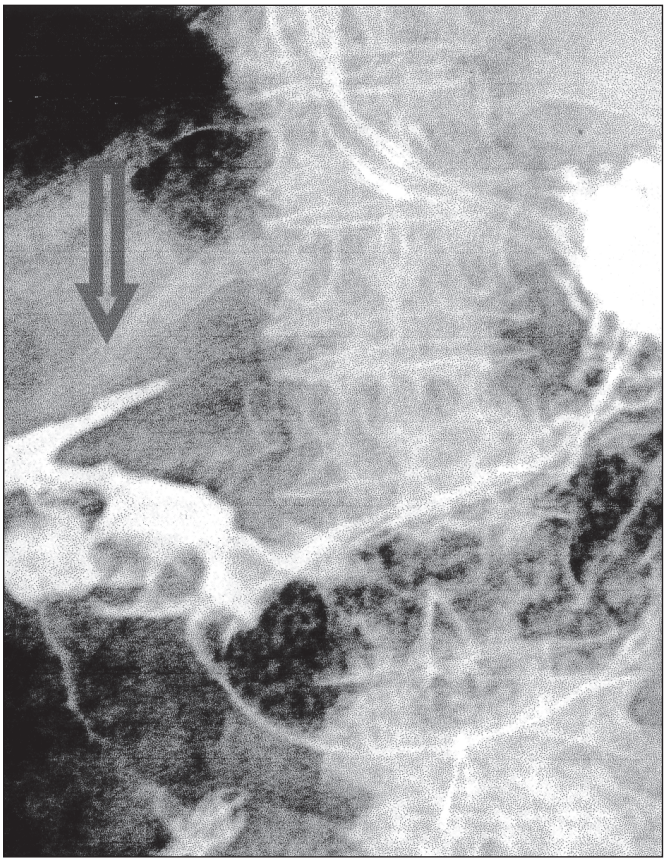

**Figure 8.** A minor leak from the gastric wound was observed with a Gastrografin study.

operative hepatic failure and sepsis with the potential of multiple organ failure are the main reasons for such poor results. Based on these considerations, cirrhosis of the liver has traditionally been considered an absolute contraindication to laparoscopic surgery.

Recently, several authors[2-4,8,9] demonstrated the feasibility and safety of the laparoscopic approach to uncomplicated abdominal operations in cirrhotic patients. Laparoscopic cholecystectomy, for example, has been extensively reported to be safe in patients with cirrhosis.[2-4] Whether the laparoscopic techniques can be extended to complex digestive operations in such high-risk patients is yet to be determined.

A perforated peptic ulcer is a condition for which a laparoscopic approach to repair has attractions. Not only are the location and pathology of the perforation identified, the procedure also allows closure of the perforation and extensive peritoneal lavage without a large abdominal incision. The laparoscopic repair of a perforated duodenal ulcer was first reported by Nathanson[10] in 1990. Since then, laparoscopic techniques for perforated peptic ulcers have rapidly evolved, with the development of both sutured and sutureless repair.[11-13] Laparoscopic suture repair is a widely accepted treatment for perforated peptic ulcers. Several trials[14,15] have described the safety of this technique. Laparoscopic sutureless repair using fibrin glue and a gelatin plug has also been shown to be safe in a randomized trial.[12] For both techniques, therefore, evidence is accumulating on their feasibility and efficacy. Furthermore, a reduction in wound pain and hospital stay has been reported compared with that in the open repair.[16]

Only 1 patient with cirrhosis of the liver and perforated duodenal ulcer treated by laparoscopy has been reported in the literature.[17] The closure was obtained with an omental patch, irrigation, and drainage. Suture closure was not attempted to shorten the operative time in a high-risk patient. In addition, the perforation was small, measuring 5 mm in diameter. In our case, the perforation was in the gastric wall, and was larger. Furthermore, the postoperative leakage rate and reoperation rate after laparoscopic suture repair has been shown to be significantly lower compared with that in laparoscopic sutureless repairs.[18] For these reasons, we decided to perform a suture closure of the perforation that appeared complete at the methylene blue test. Our patient experienced a minor leak on the 5th postoperative day, managed by

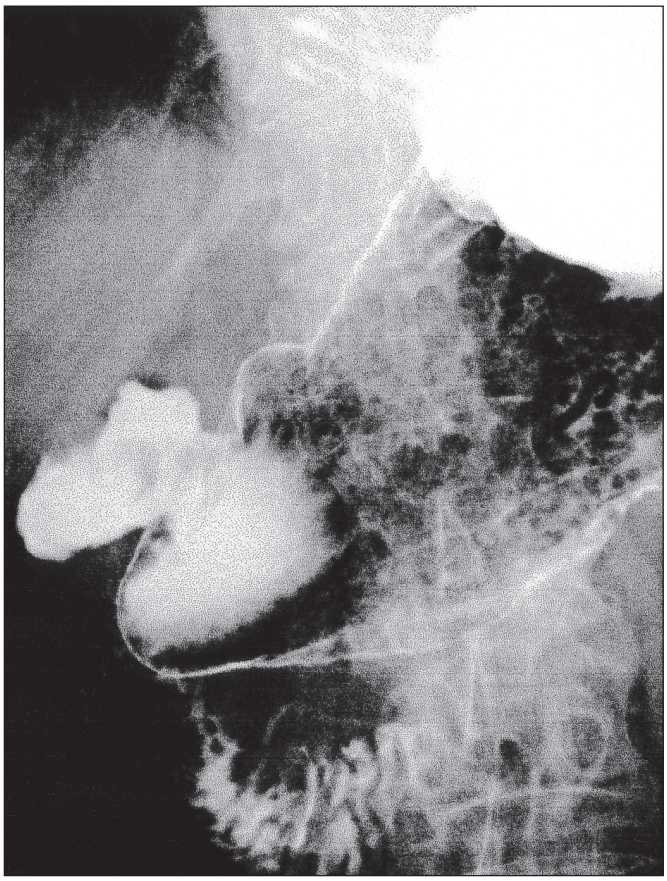

**Figure 9.** Complete closure of the gastric wound at Gastrografin study.

total parenteral nutrition for 5 additional days. Considering the high reported postoperative leakage rate in noncirrhotic patients, ranging from 6% to 16%,[18] we believe that the surgical technique did not influence the chance of leakage from the gastric wound. On the contrary, our patient experienced a painless postoperative course, with no further complications. Several additional advantages of operative laparoscopy in this setting can be identified. The avoidance of a large incision is associated with better management of eventual postoperative ascites and a minor incidence of short- and long-term wound complications. Patients suitable for liver transplantation will benefit from the absence of a subcostal incision and adhesions around the liver. Finally, surgeons are exposed to a minor risk of needle injury and viral infection.

Three prognostic factors (preoperative shock, perforation for more than 24 hours, and associated medical diseases) have been identified in patients with perforated peptic ulcers treated by open surgery.[19] With the development of laparoscopic repair techniques for the treatment of perforated peptic ulcers, the results of many retrospective and prospective trials have been published.[11-14] Nevertheless, the majority of patients in the laparoscopic series had no preoperative shock, long-term perforation, or associated severe conditions. In addition, the numbers are still too small to evaluate the real and evident advantages of minimally invasive surgery in these high-risk patients.

## CONCLUSION

We report a successful laparoscopic suture repair of a patient with perforated gastric ulcer and Child C cirrhosis. We believe that a laparoscopic approach in this setting has the potential to reduce postoperative morbidity and mortality. On the other hand, further experiences are needed.

### References:


1. Schwartz, SI. Biliary tract surgery and cirrhosis. A critical combination. *Surgery.* 1981,90:577-83.

2. Sleeman D, Namias N, Levi D, et al. Laparoscopic cholecystectomy in cirrhotic patients. *J Am Coll Surg.* 1998;187(4):400-403.

3. Gugenheim J, Casaccia M, Mazza D, et al. Laparoscopic cholecystectomy in cirrhotic patients. *HPB Surg.* 1996;10:79-82.

4. Lacy AM, Balaguer C, Andrade E, et al. Laparoscopic cholecystectomy in cirrhotic patients. *Surg Endosc.* 1995;9:407-408.

5. Aranha GV, Sontag SJ, Greenlee HB. Cholecystectomy in cirrhotic patients: a formidable operation. *Am J Surg.* 1982; 143:55-60.

6. Garrison RN, Cryer HM, Howard DA, Polk HC. Clarification risk factors for abdominal operations in patients with hepatic cirrhosis. *Ann Surg.* 1984;199:648-655.

7. Block RS, Allahen RD, Walnut AJ. Cholecystectomy in patients with cirrhosis. A surgical challenge. *Arch Surg.* 1985;120:669-672.

8. Montorsi M, Santambrogio R, Bianchi P, et al. Radiofrequency interstitial thermal ablation of hepatocellular carcinoma in liver cirrhosis. *Surg Endosc.* 2001;15:141-145.

9. Scott DJ, Young WN, Watumull LM, Lindberg G, et al. Accuracy and effectiveness of laparoscopic vs open hepatic radiofrequency ablation. *Surg Endosc.* 2001;15:135-140.

10. Nathanson LK, Easter DW, Cuschieri A. Laparoscopic

repair/peritoneal toilet of perforated duodenal ulcer. *Surg Endosc.* 1990;4:232-233.

11. Tate JJ, Dawson JW, Lau WY, Li AKC. Sutureless laparoscopic treatment of perforated duodenal ulcer. *Br J Surg.* 1993;80:235.

12. Lau WY, Leung KL, Kwong KH, Davey IC, Robertson C, Dawson JJ. A randomized study comparing laparoscopic vs open repair perforated peptic ulcer using suture or sutureless technique. *Ann Surg.* 1996;224:131-138.

13. Druart ML, Van Hee R, Etienne J, Cadiere GB, Gigot JF, Legrand M. Laparoscopic repair of perforated duodenal ulcer. A prospective multicenter clinical trial. *Surg Endosc.* 1997;11:1017-1020.

14. Darzi A, Carey PD, Menzies-Gow N, Monson JR. Preliminary results of laparoscopic repair of perforated duodenal ulcers. *Surg Laparosc Endosc.* 1993;3:161-163.

15. Fung Yee JL, Leung KL, Lai BSP, Siu Man S, Dexter S, Yee Lau W. Predicting morbidity and mortality of patients operated on for perforated peptic ulcers. *Arch Surg.* 2001;136:90-92.

16. Naesgaard JM, Edwin B, Reiertsen O, Trondsen E, Faerden AE, Rosseland AR. Laparoscopic and open operation in patients with perforated peptic ulcer. *Eur J Surg.* 1999;165:209-214.

17. Kabashima A, Maehara Y, Hashizume M, et al. Laparoscopic repair of a perforated duodenal ulcer in two patients. *Jpn J Surg.* 1998;28:633-635.

18. Lee FYJ, Leung KS, Lai PBS, Lau WY. Selection of patients for laparoscopic repair of perforated peptic ulcer. *Br J Surg.* 2001;88:133-136.

19. Boey J, Wong J, Ong GB. A prospective study of operative risk factors in perforated duodenal ulcers. *Ann Surg.* 1982;195:265-269.