A Histometrical Study on the Long Bones of Raccoon Dogs, *Nyctereutes procyonoides* and Badgers, *Meles meles*

Sachinobu HIDAKA, Mitsuharu MATSUMOTO, Seiichiroh OHSAKO, Yasushi TOYOSHIMA and Hayao NISHINAKAGAWA

Department of Veterinary Anatomy, Faculty of Agriculture, Kagoshima University, Kagoshima-shi, Kagoshima 890, Japan

(Received 5 September 1997/Accepted 25 October 1997)

ABSTRACT. To obtain the data required for identification of skeletal remains excavated from archaeological sites, histometrical observations were made in the cross sections of the mid-shaft of humerus, radius, femur and tibia of raccoon dogs (*Nyctereutes procyonoides*) and badgers (*Meles meles*) captured in Kagoshima Prefecture. There were interspecific differences between both animals in the breadth, the depth and the area of medullary cavity at the mid-shaft of the bones. In badgers, all measurements were greater in male than in female bones. The thickness and the area of compact bones in male raccoon dogs were larger than those of female. No differences in histological structure could be detected among the bones, but an interspecific difference was found in the shape of osteons; round and constant-sized osteons consisting of 3 to 5 lamellae in raccoon dogs, while round or elliptic osteons varying in size from 3 to 8 lamellae in badgers. The ratios, the osteon areas per unit compact bone areas, were higher in all the bones of raccoon dogs. The short diameters of osteons and the ratios were greater in males in both animals. In females, the short diameter of osteons was smaller, and the number of osteons was larger. The results revealed interspecific differences between both animals and sexual dimorphism in each species. — KEY WORDS: badger, bone histometry, interspecific difference, raccoon dog, sexual dimorphism.

J. Vet. Med. Sci. 60(3): 323–326, 1998

Recently, a number of skeletal remains of animals including those belonging to the canid and mustelid species were excavated from archaeological sites in Kyushu [13]. Only a few complete skeletons were found, however, and most discoveries were bone fragments. In such cases, it is difficult to identify species with bones similar in size. This is particularly true for bones of the limbs of raccoon dogs and badgers. Because the mid-shaft is less characteristic in form as compared with the proximal and distal extremities of the limb bones, macroscopic identification of raccoon dogs and badgers is extremely difficult.

A large number of histometrical studies were made on the bones of human [2, 3, 6, 17, 18], which described mainly age changes. Human bones, excavated from archaeological sites, were also examined histometrically [4, 8, 14]. On the other hand, histometrical studies on animal bones [1, 5, 7, 10–12, 15, 16] did not include bones of raccoon dogs and badgers.

To obtain the basic data required for identification of animal species excavated from archaeological sites, we attempted morphometrical and histometrical investigations on the whole skeleton of living raccoon dogs and badgers. In the present study, we examined histometrically the long bones of both raccoon dogs and badgers in cross sections of the mid-shaft of humerus, radius, femur and tibia, bones found most frequently in the archaeological sites.

MATERIALS AND METHODS

The right humeri, radii, femora and tibiae of 20 adult raccoon dogs (10 each sex) and 11 adult badgers (5 females and 6 males) captured in Kagoshima Prefecture were used in the present study. The animal with the closed epiphyseal lines of long bones was regarded as adult. Two cross sections (1 mm thick) were obtained from each mid-shaft of the bone. The specimens were dehydrated in a graded ethanol series and embedded in Rigorac, a polyester resin to prepare undecalcified ground sections (30 to 40 μm thick).

After the ground sections were observed with a light microscope, 9 items shown in Table 1 with their abbreviations were measured with an image analyzer (Nikon COSMOZONE Is) in each section. NO, DO and RO were measured at the anterior, posterior, medial and lateral regions (1 mm^2 each) of the section of each bone. These data were compared between species, sexes or kinds of bones using Student's *t*-test.

RESULTS

Morphometrical observations in cross sections: The values obtained in cross sections of the mid-shaft of each

Table 1. List of the measurements and their abbreviations

Breadth of the mid-shaft of the bone (mm)	BS
Depth of the mid-shaft of the bone (mm)	DS
Thickness of the compact bone (mm)	TC
Area of the compact bone (mm^2)	AC
Area of the medullary cavity (mm^2)	AM
AC+AM (mm^2)	TA
Number of osteons	NO
Short diameter of osteon (μm)	DO
Ratio of osteon areas[a)] (%)	RO

a) Total osteon areas at 4 regions/4 mm^2.

Table 2. Mean value and standard deviation of measurements from the mid-shaft of each bone

		Raccoon dog		Badger	
		Male	Female	Male	Female
Humerus	BS	6.56 ± 0.33[b)]	6.48 ± 0.30[c)]	7.66 ± 0.40[a)]	7.05 ± 0.17
	DS	7.99 ± 0.58[b)]	7.70 ± 0.50[c)]	10.40 ± 0.84[a)]	9.59 ± 0.30
	TC	1.26 ± 0.11[a,b)]	1.10 ± 0.11	1.00 ± 0.10[a)]	1.15 ± 0.10
	AC	23.69 ± 2.11[a)]	20.29 ± 1.58[c)]	25.85 ± 3.99	24.96 ± 0.93
	AM	17.11 ± 3.74[b)]	17.74 ± 3.01[c)]	37.25 ± 4.58[a)]	26.55 ± 3.02
	AC/TA	57.48 ± 4.03[a,b)]	53.62 ± 4.60[c)]	40.96 ± 2.89[a)]	48.59 ± 3.31
Radius	BS	4.97 ± 0.33[b)]	4.93 ± 0.26[c)]	4.56 ± 0.48	4.23 ± 0.46
	DS	4.61 ± 0.48[b)]	4.58 ± 0.31[c)]	5.19 ± 0.87	5.06 ± 0.50
	TC	1.17 ± 0.11[a)]	1.09 ± 0.10	1.22 ± 0.09[a)]	1.13 ± 0.11
	AC	12.74 ± 1.29	12.11 ± 0.81	13.39 ± 2.29	11.85 ± 1.09
	AM	3.86 ± 1.59	3.97 ± 0.63	4.66 ± 1.14	4.15 ± 0.27
	AC/TA	77.47 ± 7.26	75.43 ± 3.16	75.04 ± 1.60	74.02 ± 1.56
Femur	BS	7.57 ± 0.64	7.32 ± 0.30[c)]	7.72 ± 0.43	7.60 ± 0.39
	DS	6.70 ± 0.51	6.50 ± 0.26[c)]	7.05 ± 0.46	6.85 ± 0.39
	TC	1.23 ± 0.10[a,b)]	1.09 ± 0.10	1.11 ± 0.11	1.08 ± 0.09
	AC	22.61 ± 3.08[a)]	19.74 ± 1.69[c)]	22.38 ± 2.99	22.35 ± 1.67
	AM	16.35 ± 3.24[b)]	16.91 ± 2.28[c)]	20.23 ± 2.00	19.94 ± 3.82
	AC/TA	58.24 ± 3.21[a,b)]	53.97 ± 4.33	52.43 ± 3.24	53.15 ± 5.47
Tibia	BS	6.40 ± 0.64[b)]	6.07 ± 0.43[c)]	5.88 ± 0.36[a)]	5.49 ± 0.22
	DS	6.33 ± 0.42[a,b)]	6.04 ± 0.37[c)]	7.25 ± 0.73	6.72 ± 0.41
	TC	1.48 ± 0.12[a,b)]	1.36 ± 0.15[c)]	1.34 ± 0.16[a)]	1.22 ± 0.08
	AC	22.79 ± 1.93[a)]	20.07 ± 2.28	21.70 ± 3.77[a)]	18.63 ± 2.19
	AM	7.72 ± 2.04[b)]	8.03 ± 1.50[c)]	11.33 ± 2.12	9.66 ± 1.65
	AC/TA	74.70 ± 5.00[a,b)]	71.47 ± 4.54[c)]	65.96 ± 3.70	65.61 ± 3.94

a) Significant difference between male and female ($p<0.05$).
b) Significant difference between raccoon dogs and badgers in males ($p<0.05$).
c) Significant difference between raccoon dogs and badgers in females ($p<0.05$).

bone are shown in Table 2. In comparisons between the two species, BS was larger in the humerus and femur of badgers, but larger in the radius and tibia of raccoon dogs, while DS was larger in all bones in badgers. They were significantly different ($p<0.05$) with each other except in the case of male femur. Although no consistent tendencies were observed in TC and AC, AM were larger in all the bones of badgers with significant differences ($p<0.05$) from those of raccoon dogs except for the radius.

In raccoon dogs, there were no significant sexual differences in BS and DS, though they tended to be larger in the male bones. TC of males was significantly thicker than that of females ($p<0.05$). AC of males tended to be wider, while AM was wider in females than in males. In badgers, BS, DS, AC and AM were greater in all the male bones. TC was more likely to be thicker in males than in females, but only that of the female humerus was significantly thicker than that of males ($p<0.05$). Among 4 regions of the mid-shaft of the bone, the medial region of the forelimb bones tended to be thicker, but no consistent tendency was observed in any region of the hind limb bones.

Furthermore, AC/TA were higher in all bones in raccoon dogs than in badgers, with higher values in male than female raccoon dogs. In badgers, however, no sexual difference could be observed in AC/TA except for the humerus. In AC/TA of 4 bones, the radius was the highest, followed by the tibia, femur and humerus. Therefore, AM/TA inevitably showed opposite results to those for compact bones.

Histological observations: The histological structures of the humerus, radius, femur and tibia did not differ remarkably in each animal. In raccoon dogs, osteons consisting of 3 to 5 lamellae were nearly round in shape and approximately homogeneous. In badgers, osteons were round or elliptic, and various in size consisting of 3 to 8 lamellae (Fig. 1). The inner circumferential lamellae were composed of several layers and obscurely lamellated in some samples with well-developed trabeculae. Such structures were often seen in bones of relatively young individuals.

Histometrical observations: The values for NO, DO, and RO in each bone are shown in Table 3. In comparisons between the two species, NO values in the humerus and femur were larger, while the values for radius and tibia were smaller in badgers than in raccoon dogs. The values for DO in the humerus and femur were longer, while those for the radius and tibia were shorter in raccoon dogs than in badgers. RO values were higher in all the bones of raccoon dogs. Among 4 regions examined, osteon areas in the medial region of humerus and radius, the posterior region

of femur and the anterior region of tibia were higher in raccoon dogs. On the other hand, osteon areas in badgers were higher in the posterior region of femur and the anterior region of tibia, with no tendency observed for each region in the humerus and radius.

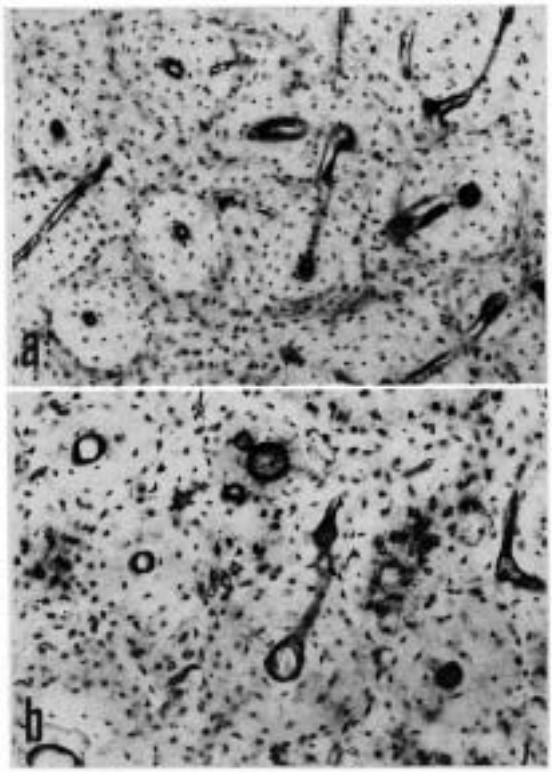

Fig. 1. Cross section of the tibia of male raccoon dog (a) and male badger (b). Osteons are round and constant in size in the raccoon dog (a), and round or elliptic with various size in the badger (b). Medial region. × 250.

Comparing NO between sexes, the values were larger in females of both species; DO and RO exhibited larger values in males of both species, with a significant difference between sexes in DO of raccoon dogs ($p<0.05$).

DISCUSSION

As a series of studies to obtain the basic data required for identification of skeletal remains of raccoon dogs and badgers, the present study was performed to clarify the bone structures in the cross sections of the mid-shaft of humerus, radius, femur and tibia of both living species. Our findings showed some interspecific differences between both species and sexual dimorphism in each species.

The interspecific differences between raccoon dogs and badgers were detected in BS, DS and AM at the mid-shaft of each bone. Especially, it was noted that BS was larger in the humerus and femur of badgers, but larger in the radius and tibia of raccoon dogs, and that DS was larger in all bones of badgers.

Albu *et al*. [1] and Georgia and Albu [7] described that there were certain species characteristics in Haversian canals in the dog, pig, bovine and horse. Jowsey [9] also reported that osteons of human bones and several mammalian species enlarged roughly in proportion to the increase in body size. In the present observation, although the histological characteristics of each bone could not be detected, an interspecific difference was revealed in the shape of osteons. In raccoon dogs, the osteons consisted of 3 to 5 lamellae and were nearly round and approximately homogeneous, while in badgers, they were round or elliptic and varied in size from 3 to 8 lamellae. The present values of osteons obtained in raccoon dogs and badgers were almost equal to

Table 3. Mean value and standard deviation of measurements from the compact bone tissue at the mid-shaft of each bone

		Raccoon dog		Badger	
		Male	Female	Male	Female
Humerus	NO	16.93 ± 2.59	17.31 ± 2.90	17.65 ± 3.84	18.08 ± 3.29
	DO	106.05 ± 6.72[a)]	99.13 ± 4.46	102.95 ± 8.49	97.32 ± 9.54
	RO	35.12 ± 6.55	33.85 ± 3.62[c)]	33.82 ± 4.38	30.37 ± 4.73
Radius	NO	18.53 ± 1.76	19.10 ± 2.48[c)]	16.75 ± 3.26	16.83 ± 2.94
	DO	97.29 ± 8.26[a)]	91.46 ± 5.21[c)]	100.13 ± 8.80	99.31 ± 10.46
	RO	35.59 ± 5.34[a,b)]	29.42 ± 3.23	28.62 ± 2.66	28.43 ± 3.79
Femur	NO	17.05 ± 2.97[a,b)]	18.93 ± 2.34	19.70 ± 3.20	20.63 ± 3.24
	DO	100.25 ± 6.11[a)]	94.21 ± 2.90	96.22 ± 5.77	93.52 ± 8.74
	RO	35.20 ± 3.99	34.38 ± 3.92	33.47 ± 5.05	32.62 ± 5.98
Tibia	NO	21.04 ± 3.51[a)]	24.46 ± 4.09[c)]	19.08 ± 3.44	19.93 ± 3.06
	DO	95.33 ± 8.92[a)]	89.38 ± 4.35[c)]	96.97 ± 7.02	95.56 ± 8.71
	RO	38.34 ± 4.45[b)]	36.61 ± 3.61[c)]	32.59 ± 3.35	30.98 ± 2.98

a) Significant difference between male and female ($p<0.05$).
b) Significant difference between raccoon dogs and badgers in males ($p<0.05$).
c) Significant difference between raccoon dogs and badgers in females ($p<0.05$).

those of rabbits weighing 2 kg [9].

Concerning the sexual dimorphism, TC and AC were thicker or wider in male than in female in raccoon dogs, and BS, DS and AM were larger in male than in female in badgers. Brockstedt [3] described that the osteon diameter was significantly larger in men than in women. The present results also revealed that DO showed larger values in males of both species, with a significant difference between sexes in raccoon dogs.

It is generally agreed that body weights tend to be loaded upon the medial region of the forelimbs to make the medial region of articular facets wider in quadruped animals. TC in the medial region of the forelimb bones tended to be thicker in the present study, which might be related to the load put on forelimbs. Martin *et al.* [11] found that the anterior region of the equine third metacarpal bone had smaller osteons than the other regions. Mason *et al.* [12] reported that osteon population density (osteons/mm^2) of the equine radius was nearly two times as great in the posterior region as in the other three regions. In the present study, we also found the regional variations in osteon areas, which tended to be higher in the medial region of the bones of forelimbs.

Furthermore, AC/TA was higher in the radius than in the humerus, or in the tibia than in the femur. Rajtova *et al.* [15] examined the shape and size of osteons in limb bones of sheep and goats, and described that the increase of mechanical pressure loaded on metapodial bones from the humerus and femur decreased the size and increased the densities of osteons. The present values in the male raccoon dogs agreed well with those of Rajtova *et al.* [15], although in female raccoon dogs only bones of the hindlimb gave similar results. No such tendencies could be detected in badgers.

Histometrical observations on the long bones of limbs revealed that there were interspecific differences between raccoon dogs and badgers and sexual dimorphism in each species. The present findings will provide sufficient data for identification of skeletal remains excavated from archaeological sites.

ACKNOWLEDGMENT. We thank Mr. H. Bono, a member of Kagoshima-ken Hunting Association, for supplying the materials.

REFERENCES

1. Albu, I., Georgia, R. and Georoceanu, M. 1990. The canal system in the diaphysial compacta of the femur in some mammals. *Anat. Anz.* 170: 181–187.
2. Bertelsen, P. K., Clement, J. G. and Thomas, C. D. L. 1995. A morphometric study of the cortex of the human femur from early childhood to advanced old age. *Forensic Sci. Int.* 74: 63–77.
3. Brockstedt, H., Kassem, M., Eriksen, E. F., Mosekilde, L. and Melsen, F. 1993. Age- and sex-related changes in iliac cortical bone mass and remodeling. *Bone* 14: 681–691.
4. Burr, D. B., Ruff, C. B. and Thompson, D. D. 1990. Patterns of skeletal histologic change through time: comparison of an archaic native American population with modern populations. *Anat. Rec.* 226: 307–313.
5. Copping, R. R. 1978. Microscopic age changes in the frontal bone of the domestic rabbit. *J. Morphol.* 155: 123–130.
6. Ericksen, M. F. 1991. Histologic estimation of age at death using the anterior cortex of the femur. *Am. J. Phys. Anthropol.* 84: 171–180.
7. Georgia, R. and Albu, I. 1988. The Haversian canal network in the femoral compact bone in some vertebrates. *Rev. Roum. Morphol. Embryol. Physiol.* 34: 155–160.
8. Iwamoto, S. and Konishi, M. 1993. Estimating the age of death in a group of historically unknown adults. *Okajimas Folia Anat. Jpn.* 70: 105–113.
9. Jowsey, J. 1966. Studies of Haversian systems in man and some animals. *J. Anat.* 100: 857–864.
10. Korkmaz, T., Kaya, M. A. and Bayazit, V. 1996. Relation with the age of the histological variations in the compact layer of the long bones. *Turkish J. Zool.* 20: 71–76.
11. Martin, R. B., Gibson, V. A., Stover, S. M., Gibeling, J. C. and Griffin, L. V. 1996. Osteonal structure in the equine third metacarpus. *Bone* 19: 165–171.
12. Mason, M. W., Skedros, J. G. and Bloebaum, R. D. 1995. Evidence of strain-mode-related cortical adaptation in the diaphysis of the horse radius. *Bone* 17: 229–237.
13. Nishinakagawa, H., Matsumoto, M., Otsuka, J. and Kawaguchi, S. 1994. Mammals from archaeological sites of the Jomon Period in Kagoshima Prefecture. *J. Mamm. Soc. Jpn.* 19: 57–66.
14. Pfeiffer, S. and Zehr, M. K. 1996. A morphological and histological study of the human humerus from Border Cave. *J. Hum. Evol.* 31: 49–59.
15. Rajtova, V., Briancin, J. and Kokardova, M. 1995. Lamellar bone structure in small ruminants. *Folia Vet.* 39: 59–64.
16. Stover, S. M., Pool, R. R., Martin, R. B. and Morgan, J. P. 1992. Histological features of the dorsal cortex of the third metacarpal bone mid-diaphysis during postnatal growth in throughbred horses. *J. Anat.* 181: 455–469.
17. Walker, R. A., Lovejoy, C. O. and Meindl, R. S. 1994. Histomorphological and geometric properties of human femoral cortex in individuals over 50: implications for histomorphological determination of age-at-death. *Am. J. Hum. Biol.* 6: 659–667.
18. Yoshino, M., Imaizumi, K., Miyasaka, S. and Seta, S. 1994. Histological estimation of age at death using microradiographs of humeral compact. *Forensic Sci. Int.* 64: 191–198.