

Evidence for adaptive functional changes in the cerebral cortex with axonal injury from multiple sclerosis

H. Reddy,¹ S. Narayanan,² R. Arnoutelis,² M. Jenkinson,¹ J. Antel,² P. M. Matthews¹ and D. L. Arnold²

¹Centre for Functional Magnetic Resonance Imaging of the Brain, Department of Clinical Neurology, University of Oxford, John Radcliffe Hospital, Oxford, UK and
²Department of Neurology and Neurosurgery, Montreal Neurological Institute, McGill University, Montreal, Canada

Correspondence to: Professor P. M. Matthews, Centre for Functional Magnetic Resonance Imaging of the Brain, John Radcliffe Hospital, Headley Way, Headington, Oxford OX3 9DU, UK
 E-mail: paul@fmrib.ox.ac.uk

Summary

Axonal injury occurs even in the earliest stages of multiple sclerosis. Magnetic resonance spectroscopic imaging (MRSI) measurements of brain *N*-acetylaspartate (NAA), a marker of axonal integrity, show that this axonal injury can occur even in the absence of clinically evident functional impairments. To test whether cortical adaptive responses contribute to the maintenance of normal motor function in patients with multiple sclerosis, we performed MRSI and functional MRI (fMRI) examinations of nine multiple sclerosis patients who had unimpaired hand function. We found that activation of the ipsilateral

sensorimotor cortex with simple hand movements was increased by a mean of fivefold relative to normal controls ($n = 8$) and that the extent of this increase was strongly correlated ($\sigma = -0.93$, $P = 0.001$) with decreases in brain NAA. These results suggest that compensatory cortical adaptive responses may help to account for the limited relationship between conventional MRI measures of lesion burden and clinical measures of disability, and that therapies directed towards promoting cortical reorganization in response to brain injury could enhance recovery from relapses of multiple sclerosis.

Keywords: fMRI; multiple sclerosis; brain; rehabilitation; recovery

Abbreviations: Cr = creatine; fMRI = functional magnetic resonance imaging; LI = lateralization index; MRSI = magnetic resonance spectroscopic imaging; NAA = *N*-acetylaspartate; SMA = supplementary motor cortex; SMC = sensorimotor cortex; TE = echo time; TR = repetition time

Introduction

Multiple mechanisms have been postulated to contribute to maintenance of function after inflammatory brain injury in multiple sclerosis. These include resolution of the acute inflammation, remyelination (Lassmann *et al.*, 1997) and increased expression of sodium channels in chronically demyelinated segments of axons (Waxman and Ritchie, 1993). However, magnetic resonance spectroscopic imaging (MRSI) studies of multiple sclerosis patients have emphasized that considerable axonal injury occurs even within acute plaques (Arnold *et al.*, 1990, 1998). Whereas there can be some degree of reversible axonal injury (De Stefano *et al.*, 1995b), direct pathological studies have confirmed that a substantial amount of the axonal injury and loss in plaques and in the normal appearing white matter appears irreversible

(Ferguson *et al.*, 1997; Trapp *et al.*, 1998). None of the mechanisms of recovery noted above could be expected to contribute to the resolution of functional deficits resulting from such irreversible axonal injury or loss.

A clue to ways in which function may be preserved even when there is substantial axonal injury comes from experimental paradigms that have demonstrated a considerable capacity for cortical adaptation even in the adult brain (Witte, 1998). These cortical 'plastic' changes can involve local synaptic reorganization, reorganization at more distant sites (e.g. in subcortical nuclei projecting onto the cortex) or recruitment of parallel existing pathways. PET and functional MRI (fMRI) studies of patients who have recovered from stroke, or who maintain motor functions despite the

progressive enlargement of brain tumours compressing eloquent areas of cortex, have provided evidence that cortical plasticity may contribute to functional recovery after different forms of brain injury in man (Weiller *et al.*, 1993; Chollet and Weiller, 1994; Cramer *et al.*, 1997; Cao *et al.*, 1998). A longitudinal case study of a patient with a relapse of multiple sclerosis has suggested a dynamic relationship between similar changes in cortical activation with movement and the extent of pathological changes (Reddy *et al.*, 2000). A larger cross-sectional study of multiple sclerosis patients with a wide range of disabilities demonstrated altered patterns of cortical activation for motor tasks, suggesting both that both local and long distance changes occur in proportion to the lesion burden (Lee *et al.*, 2000). Increased ipsilateral motor cortex activation (leading to decreased hemispheric lateralization of motor activation) was associated with an increasing burden of disease. However, this study did not control for performance differences between the subjects. Also, with the exception of the case study (Reddy *et al.*, 2000), neither this nor previous studies of similar phenomena (Weiller *et al.*, 1993; Chollet and Weiller, 1994; Cramer *et al.*, 1997; Cao *et al.*, 1998) directly assessed the neuronal and axonal injury likely to be responsible for driving reorganization, relying instead on less specific measures of the extent of pathological change.

We wished to test the hypothesis that cortical adaptive changes contribute to sustaining motor functions with the progression of axonal injury in multiple sclerosis more directly. We appreciated that it is difficult to interpret the significance of abnormal patterns of activation in functional imaging studies in patients if there are substantial differences in performance between the control and patient groups. Therefore, we chose to study motor cortex activation in a group of patients with relapsing remitting multiple sclerosis who had normal finger tapping ability. In this group, we specifically sought to test whether the hemispheric lateralization of motor cortex activation during finger tapping decreased as the degree of white matter axonal injury increases. Axonal injury was estimated from the extent of decrease in the relative concentration of *N*-acetylaspartate (NAA), which was measured using brain MRSI.

Methods

Patients

Patients were selected from the out-patient population of the Montreal Neurological Institute. Normal controls (eight right-handed) were volunteers recruited from hospital and research staff. Only five of the controls had both fMRI and MRSI studies. All gave informed consent for the protocol, which was approved by the ethics committee of the Montreal Neurological Institute. Finger tapping rates for all of the patients (six right-handed, three left-handed) were equal to or better than performance for the normal controls (4.5 ± 0.6 Hz).

fMRI

The motor task involved simultaneous four-finger flexion-extension of the metacarpal-phalangeal joints of the dominant hand paced by an auditory cue at 75% of the maximum rate (~3 Hz) for each subject. This was alternated with rest (during which time the auditory cue continued). All subjects were visually monitored during the experiment to ensure compliance with the protocol. Data was acquired with a 1.5 T Siemens Magnetom Vision [gradient echo planning, repetition time (TR) = 4 s, echo time (TE) = 47 ms, field of vision = 320×320 , 64×64 matrix, slice thickness 6 mm]. A total of 120 volumes were obtained for each hand in a trial with alternating blocks of rest or movement, during which 20 volumes were acquired for each block. Two trials were performed for movements of each hand. In the analysis, data from the two trials for each hand were concatenated. Image processing and statistical analysis were carried out using a locally (Oxford FMRI Centre) extended version of MEDx 3.0 (Sensor Systems, Inc., Sterling, Va., USA). Motion correction, spatial smoothing (full width half maximum = 5 mm), intensity normalization and temporal filtering were applied. Activation maps were calculated using Student's unpaired *t*-test, and cluster detection (Poline *et al.*, 1997) was performed on all voxels above $Z = 6.0$ to determine clusters significantly activated ($P < 0.01$). The functional image was registered to the structural image and the resulting transform applied to the activation map, which was then overlaid on a high resolution T₁ structural image for neuroanatomical correlation of the activations.

Motor cortex was defined on the structural image using anatomical landmarks. The sensorimotor cortex (SMC) included primary sensorimotor plus premotor cortex from the region within the lateral post-central gyrus anteriorly to the point midway between the central sulcus and the anterior limit of the brain. The supplementary motor area (SMA) was defined as the area medial to this. A lateralization index (LI) was defined as $(C - I) / (C + I)$ where C is the number of significantly activated voxels in the contralateral SMC and I is the number of significantly activated pixels in the ipsilateral SMC.

MRSI and MRI

Conventional proton MRI and MRSI examinations of the brain were performed together using a Philips Gyroscan ACS II at 1.5 T. Anatomical images were acquired using a dual turbo spin-echo sequence (TR = 2075 ms, TE = 30/90 ms, slice thickness = 3 mm) producing proton density weighted and T₂-weighted images. These transverse images were used to select a volume of interest for spectroscopy of ~ $90 \times 90 \times 20$ mm centred on the corpus callosum. Water-suppressed proton spectra were acquired using a 90-180-180 (PRESS) sequence (TR = 2 s, TE = 272 ms, 32×32 phase-encodes and 250 mm field of view). To allow for correction of B₀ inhomogeneity during post-processing, a

Table 1 Clinical data describing patients and individual levels of disability

Patient	T ₂ LV (cm)	EDSS	Dominant hand	Maximum finger tapping rate (Hz)	Disease duration (years)	Type of multiple sclerosis
1	9.4	2	L	6.0	3.4	RR
2	20.5	5	R	3.4	3.3	SP
3	24.9	3	R	4.6	23.2	RR
4	3.2	3.5	R	4.4	11.6	RR
5	13.5	6.5	L	3.1	12.5	SP
6	4.9	3	R	4.8	10.7	RR
7	1.2	2	L	5.6	17.5	RR
8	4.8	2.5	R	3.8	23.0	RR
9	0.4	0	R	7.8	6.8	RR
Median	9.2	3		4.6	11.6	
Range	0.4–29.7	0–6.5		3.1–7.8	3.3–23.2	

Abbreviations: T₂ LV = lesion volume on T₂-weighted MRI scan; NAA/Cr = ratio of *N*-acetylaspartate to creatine in magnetic resonance spectrum from defined volume; EDSS = Extended Disability Status Scale; RR = relapsing–remitting; SP = secondary progressive. The maximum finger tapping rate was measured as described in Methods and is reported for the dominant hand only.

quick MSI without water-suppression was also acquired (TR = 850 ms, TE = 272 ms, 16 × 16 phase-encodes and 250 mm field of view). Post-processing of the raw data was performed as previously described (Fu *et al.*, 1998) with the exception that in the present study the residual water signal was fitted and removed from the water-suppressed data using the Hankel singular-value decomposition procedure. Resonance intensities of NAA and creatine (Cr) were determined and normalized with respect to the intravoxel water signal using in-house software (AVIS; Mr S. Antel, MRS Unit, Montreal Neurological Institute). Values for the NAA/Cr ratio were calculated individually for each voxel and then averaged across the entire acquisition volume for calculation of the average in each subject. Lesions were manually segmented using locally developed software (Display; David Macdonald, Brain Imaging Center, Montreal Neurological Institute).

Statistics

Group differences were determined by two-tailed Wilcoxon signed rank test. The hypothesis that greater axonal injury is associated with increased ipsilateral cortical activation and thus decreased LI was tested with two-tailed Spearman correlations.

Results

The patients had either relapsing–remitting ($n = 7$) or secondary progressive ($n = 2$) multiple sclerosis (Table 1). None had suffered a relapse more recently than 4 months before the study. While disability varied substantially (median Extended Disability Status Scale 3.0; range 0–6.5), all patients were without motor or sensory symptoms in the arms or hands and showed maximum finger tapping rates with the dominant hand that were as fast as (or faster than) those in the normal control group. No mirror movements were noted

during tapping of either the left or right hands in the patient or control groups.

The patients had a mean lesion volume of 10.3 cm³ measured on the T₂-weighted MRI (range, 0.4–24.9 cm³). There was only a trend for a reduction in the mean relative cerebral white matter NAA concentration ($P = 0.08$) measured by MRSI in this mildly affected group of multiple sclerosis patients relative to the normal controls (relative NAA/Cr patient mean, $n = 9$, 2.99 ± 0.32 ; normal controls, $n = 5$, 3.26 ± 0.16 , which is in good agreement with values for our larger group of normal controls, $n = 27$, 3.21 ± 0.21).

With movement of the dominant hand, both the normal controls ($n = 8$, right handed) and patients ($n = 9$, six right-handed, three left-handed) showed significant activations in the SMA and in the contralateral and ipsilateral SMC (Fig. 1). The smaller volumes (see below) of ipsilateral SMC activations for the control subjects were localized somewhat variably in the precentral gyrus and posterior middle frontal gyrus, while the rather greater activation in this region for the patients tended to be centred in the precentral gyrus. fMRI activation images during the hand movement task showed similar mean maximum Z scores (Z_{\max}) in each of the regions studied (for patients and controls together, $n = 17$: contralateral SMC, $Z_{\max} = 12.2 \pm 1.6$; ipsilateral SMC, $Z_{\max} = 6.4 \pm 3.9$; SMA, $Z_{\max} = 8.5 \pm 3.9$).

The relative hemispheric LI of cortical activation during this motor task was lower for the patients as a group than for the controls ($P < 0.02$) (Table 2). There was a strong correlation between the LI and the relative brain NAA for the patients ($\sigma = 0.80$, $P = 0.009$) and for the group as a whole ($\sigma = 0.73$, $P = 0.003$) (Fig. 2A). This correlation arose primarily from increases in ipsilateral motor cortex activation with lower values of brain NAA (for patients alone, $\sigma = -0.93$, $P = 0.001$; for the group as a whole, $\sigma = -0.70$, $P = 0.006$) (Fig. 2B). Both relationships remained significant if only right-handed patients were considered in the total group (correlation of NAA/Cr with LI, $\sigma = 0.65$,

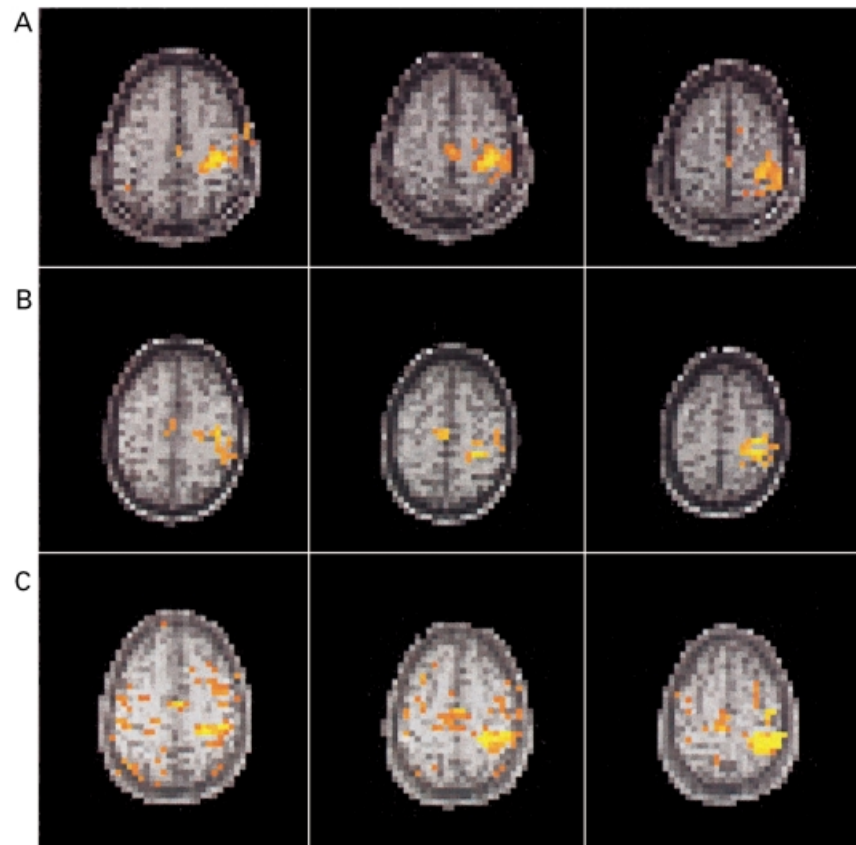


Fig. 1 Representative activation maps registered on single shot echo planar MRIs from a normal control (A), a multiple sclerosis patient with a higher, normal range NAA/creatine concentration ratio in the cerebral white matter and normal range ipsilateral motor cortex activation (B), and a multiple sclerosis patient with a NAA/creatine concentration ratio in cerebral white matter below the normal range showing a relatively larger activation in ipsilateral motor cortex (C). As described previously (Lee *et al.*, 2000), patients may sometimes show relatively increased activation of the supplementary motor/premotor areas as in C, although we did not find this difference significant for the group as a whole.

Table 2 Activations in contra- and ipsilateral SMC and SMA with calculated hemispheric LI and related lesion volume for each patient, and a comparison with normal controls

Patient	NAA/Cr	Numbers of pixels above threshold			Total	LI	Lesion volume (cm ³)
		Contralateral SMC	Ipsilateral SMC	SMA			
1	2.56	98.0	32.0	6.0	136.0	0.51	9.4
2	2.73	213.0	79.0	97.0	389.0	0.46	20.5
3	2.72	94.0	18.0	3.0	115.0	0.68	13.5
4	2.93	53.0	16.0	12.0	81.0	0.54	3.2
5	2.88	80.0	17.0	60.0	157.0	0.65	24.9
6	3.13	64.0	12.0	47.0	123.0	0.68	4.8
7	3.16	34.0	1.0	0.0	35.0	0.94	1.2
8	3.23	99.0	5.0	40.0	144.0	0.90	4.9
9	3.59	55.00	0.0	11.0	66.0	1.00	0.4
Mean ± SD	2.99 ± 0.32	87.8 ± 52.1	20.0 ± 24.3	30.7 ± 31.0	138.4 ± 96.2	0.71* ± 0.20	10.3 ± 9.6
Control (mean ± SD) (n = 8)	3.26 ± 0.16	110.9 ± 10.3	3.8 ± 4.2	23.4 ± 20.4	138.0 ± 29.7	0.94 ± 0.07	

The extent of activation in each region of interest is expressed as the number of pixels above the chosen threshold (see Methods). * $P < 0.02$.

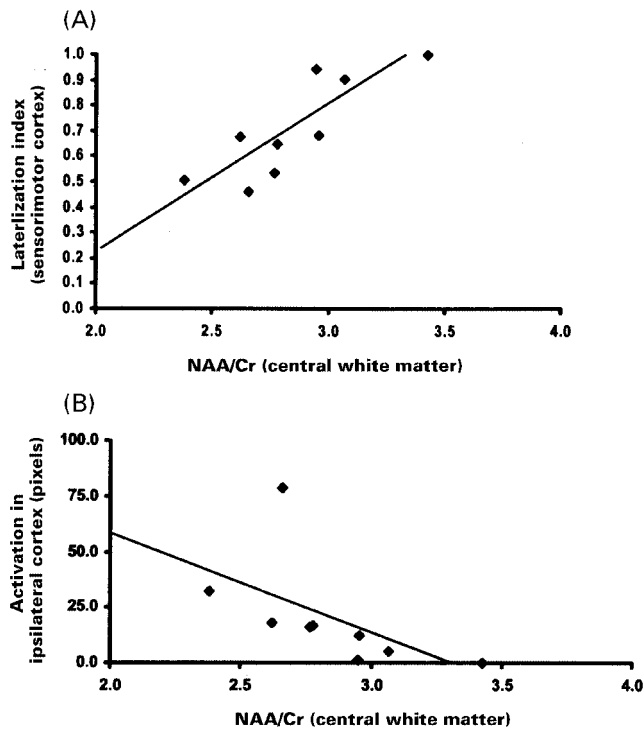


Fig. 2 Strong correlations were found for the patients between brain relative NAA concentration with both the LI for activations associated with the hand movement task ($\sigma = 0.80$, $P = 0.009$) (A) and the absolute number of pixels exceeding threshold in the ipsilateral motor cortex ($\sigma = -0.93$, $P = 0.001$) (B).

$P < 0.03$; correlation of NAA with ipsilateral SMC activation, $\sigma = -0.60$, $P = 0.05$). Considered independently, the control group did not show any significant relationship between relative NAA concentration and either LI ($P = 0.45$) or ipsilateral motor cortex activation ($P = 0.19$). The total numbers of significantly activated pixels ($Z > 6.0$) in the contralateral SMC (or SMA) did not differ between the two groups, but the mean volume of ipsilateral SMC activation was five times greater for the patients than for the normal controls ($P < 0.01$) (Table 2).

The mean localization of activations in the SMC contralateral to the hand moved was not different in patients relative to controls (mean Talairach coordinates for the entire group, $n = 17$, were $x = \pm 33 \pm 6$, $y = -25 \pm 11$, $z = 59 \pm 6$), but the range in the y -axis coordinates for the patients was more than twice as large as for the controls (-13 to -55 for the patients versus -16 to -36 for the normal controls). The increase in range was due to activation that was >2 SD more posterior than the control mean in two patients (2 and 6).

Discussion

Previous studies demonstrated that decreases in white matter NAA/Cr (an index of axonal injury) are correlated strongly with functional impairment or disability in multiple sclerosis (Matthews *et al.*, 1998). Here we found a strong correlation

between decreased NAA/Cr and the lateralization of cortical activation associated with finger tapping in a group of multiple sclerosis patients without any clinically evident functional impairment in the hands. The extent of the decrease in LI was proportional to the pathological reduction of NAA. In an earlier study we showed a similar relationship between T_2 -hyperintense lesion load and similar shifts in lateralization associated with motor activation (Lee *et al.*, 2000). However, T_2 -hyperintense lesion change is a non-specific index of pathology, and relative NAA changes (as used here) are much more directly related to axonal loss, which is currently thought to be a primary mechanism of chronic disability (Matthews *et al.*, 1998). Another important feature of the experimental design for the current work is that the choice of patients with normal fine-finger movements removed performance differences as a confound to interpretation. We therefore interpret the cortical activation changes as evidence for adaptive responses that may act to maintain normal functional capacity after axonal injury associated with the inflammatory lesions of multiple sclerosis. This phenomenon may contribute to limiting the strength of the relationship between disability and measures of multiple sclerosis pathology (e.g. MRI lesion burden) (Filippi *et al.*, 1998).

The major difference in the pattern of cortical motor activation seen in the patient group was a greater activation of ipsilateral SMC with greater degrees of axonal injury (as assessed from decreases in relative NAA measured by MRSI). There was no clinical evidence for 'mirror' movements of the opposite hand to account for this and such movements are uncommon in subjects without paresis. EMG documentation showing that there is no muscle activity in the arm at rest would be desirable in further studies, particularly if the subjects have some degree of weakness. However, the observation of ipsilateral SMC activation itself is perhaps not so surprising, as ipsilateral SMC activity is observed in normal subjects with respect to increasing task complexity or rate (Wexler *et al.*, 1997a). Brains of patients with multiple sclerosis may use similar mechanisms to maintain normal performance levels with increasing injury in the brain. We suggest therefore that these changes represent an 'unmasking' of existing motor pathways in the multiple sclerosis patients rather than novel cortical reorganization occurring in response to axonal injury or other specific factors associated with the disease.

Functional recovery in multiple sclerosis has previously been recognized to occur through a variety of mechanisms including resolution of inflammatory changes, remyelination and reorganization of axonal membrane ion channels. A degree of axonal injury appears to be reversible (De Stefano *et al.*, 1995b), although fixed, irreversible axonal injury also occurs even in acute multiple sclerosis lesions (De Stefano *et al.*, 1995a; Ferguson *et al.*, 1997; Trapp *et al.*, 1998; Evangelou *et al.*, 2000). On the basis of this study we speculate that cortical adaptive changes could also contribute to functional recovery from lesions causing irreversible axonal injury.

One concern in interpretation was that the failure to balance handedness between the control and patient groups might bias results, as left-handed subjects have been reported to have an ~30% lower hemispheric lateralization of motor cortex activation than right-handed subjects for a serial finger opposition task with the dominant hand (Kim *et al.*, 1993). Relative lateralization of activation depends on task complexity, however (Wexler *et al.*, 1997b). In preliminary studies [performed using a 3 T MRI system (Lee *et al.*, 2000), which gives an overall lower apparent lateralization of activation than in the current study because of greater sensitivity to the lower ipsilateral SMC activations], we found only an ~10% difference for this simple hand-tapping task performed by the dominant hand (mean LI = 0.55 ± 0.28 , left dominant, $n = 5$; mean LI = 0.61 ± 0.39 , right dominant, $n = 14$; R. Pineiro, S. Pendlebury, H. Johansen-Berg and P. M. Matthews, unpublished data). This difference could not explain the 44% decrease in LI for Patient 1, for example. Furthermore, as described in Results, a significant correlation (although somewhat weaker than for the group as a whole) is found between decreasing NAA/Cr and LI even if left-handed patients are excluded from the analysis.

We did not observe a significant posterior shift in the localization of contralateral SMC activations as reported in our earlier study of patients with a higher burden of disease and upper limb disability (Lee *et al.*, 2000). This activation localization shift was hypothesized to arise from local cortical reorganization in the patients. In the current study, only the SMC activation centres for Patients 2 and 6 were >2 SD posterior to the normal control mean. The failure to observe a significant shift for the group as a whole may be a consequence of the lack of disease burden sufficient to cause significant disability in fine finger movements for this group. This suggests that if a local posterior shift in the centre of SMC activation is part of adaptive responses to injury, then it may occur only with more severe injury than is necessary to enhance ipsilateral SMC activation.

We believe that measurements of the relative NAA concentrations in the central white matter as performed for this study are relevant to understanding functional changes in the corticospinal tract, even though this region was not selectively sampled. Axonal injury occurs throughout the normal appearing white matter (Narayanan *et al.*, 1997). This injury pattern shows only modest regional variation on average (although it is greatest in the periventricular region) (Narayanan *et al.*, 1997). While it is uncertain whether the decreases in the NAA/Cr are due solely to decreases in NAA, there is no doubt but that (i) the absolute NAA concentration decreases in the white matter of multiple sclerosis patients (Sarchielli *et al.*, 1999); (ii) substantial axonal loss occurs in the white matter, consistent with the decreases in NAA/Cr in patients (Evangelou *et al.*, 2000); and (iii) lower NAA/Cr is associated with greater disability (Fu *et al.*, 1998).

The absolute number of activated voxels is a function of the statistical threshold chosen. Use of $Z > 6.0$ ($P < 0.0003$) gave similar degrees of activation in patients and controls and

suppressed artefactual (e.g. from subject motion) activations during the movement paradigm. In separate studies, we have shown that detection of changes in LI is relatively insensitive to the precise Z threshold chosen, although the precise value of the LI varies as the threshold changes (H. Johansen-Berg, R. Pineiro and P. M. Matthews, unpublished results). In the present case, both patients and controls were highly cooperative and the absolute activations were very similar between the two groups, justifying use of a single threshold level in the comparisons.

It also has been noted that measurement of percentage signal change may provide the most robust measure of activation (Cohen and DuBois, 1999). However, in a separate experiment we compared the relative LI for this hand-tapping protocol measured using the thresholded mean difference image with that from the thresholded Z score image for patients after strokes and for normal controls. We found no meaningful differences between the measures (R. Pineiro and P. M. Matthews, unpublished). Consequently, we have continued to use the thresholded Z score image for measures of the extent (as opposed to the magnitude) of the regional activation.

Overall, our results suggest that the cortical adaptive responses may have an important role in compensating for axonal injury in multiple sclerosis. We therefore propose that loss of adaptive capacity of the cortex with progression of axonal loss in multiple sclerosis could contribute to the development of progressive disease and the accumulation of irreversible clinical deficits. If this is true, then neurotrophic factors or other agents that promote neuronal 'plasticity' could promote improved functional recovery or slow progression of the disease.

Acknowledgements

We wish to thank members of the Oxford FMRIB Center and particularly Dr Steve Smith for his support for image analysis. This work was supported by grants from the Multiple Sclerosis Society of Canada (D.L.A.), the Multiple Sclerosis Society of Great Britain and Northern Ireland (P.M.M.), the Medical Research Councils of Canada (D.L.A.) and the United Kingdom. This work was part of the joint programme in Cortical Reorganization and Plasticity.

References

- Arnold DL, Matthews PM, Francis G, Antel J. Proton magnetic resonance spectroscopy of human brain in vivo in the evaluation of multiple sclerosis: assessment of the load of disease. *Magn Reson Med* 1990; 14: 154–9.
- Arnold DL, Wolinsky JS, Matthews PM, Falini A. The use of magnetic resonance spectroscopy in the evaluation of the natural history of multiple sclerosis. [Review]. *J Neurol Neurosurg Psychiatry* 1998; 64 Suppl 1: S94–101.

- Cao Y, D'Olhaberriague L, Vikingstad EM, Levine SR, Welch KM. Pilot study of functional MRI to assess cerebral activation of motor function after poststroke hemiparesis. *Stroke* 1998; 29: 112–22.
- Chollet F, Weiller C. Imaging recovery of function following brain injury. [Review]. *Curr Opin Neurobiol* 1994; 4: 226–30.
- Cohen MS, DuBois RM. Stability, repeatability, and the expression of signal magnitude in functional magnetic resonance imaging. *J Magn Reson Imaging* 1999; 10: 33–40.
- Cramer SC, Nelles G, Benson RR, Kaplan JD, Parker RA, Kwong KK, et al. A functional MRI study of subjects recovered from hemiparetic stroke. *Stroke* 1997; 28: 2518–27.
- De Stefano N, Matthews PM, Antel JP, Preul M, Francis G, Arnold DL. Chemical pathology of acute demyelinating lesions and its correlation with disability. *Ann Neurol* 1995a; 38: 901–9.
- De Stefano N, Matthews PM, Arnold DL. Reversible decreases in N-acetylaspartate after acute brain injury. *Magn Reson Med* 1995b; 34: 721–7.
- Evangelou N, Konz D, Esiri MM, Smith S, Palace J, Matthews PM. Regional axonal loss in the corpus callosum correlates with cerebral white matter lesion volume and distribution in multiple sclerosis. *Ann Neurol*. In press 2000.
- Ferguson B, Matyszak MK, Esiri MM, Perry VH. Axonal damage in acute multiple sclerosis lesions. *Brain* 1997; 120: 393–9.
- Filippi M, Horsfield MA, Ader HJ, Barkhof F, Bruzzi P, Evans A, et al. Guidelines for using quantitative measures of brain magnetic resonance imaging abnormalities in monitoring the treatment of multiple sclerosis. *Ann Neurol* 1998; 43: 499–506.
- Fu L, Matthews PM, De Stefano N, Worsley KJ, Narayanan S, Francis GS, et al. Imaging axonal damage of normal-appearing white matter in multiple sclerosis. *Brain* 1998; 121: 103–13.
- Kim SG, Ashe J, Hendrich K, Ellermann JM, Merkle H, Ugurbil K, et al. Functional magnetic resonance imaging of motor cortex: hemispheric asymmetry and handedness. *Science* 1993; 261: 615–7.
- Lassmann H, Bruck W, Lucchinetti C, Rodriguez M. Remyelination in multiple sclerosis. [Review]. *Mult Scler* 1997; 3: 133–6.
- Lee M, Reddy H, Johansen-Berg H, Pendlebury ST, Jenkinson M, Smith S, et al. The motor cortex shows adaptive functional changes to brain injury from multiple sclerosis. *Ann Neurol* 2000; 47: 606–13.
- Matthews PM, De Stefano N, Narayanan S, Francis GS, Wolinsky JS, Antel JP, et al. Putting magnetic resonance spectroscopy studies in context: axonal damage and disability in multiple sclerosis. [Review]. *Semin Neurol* 1998; 18: 327–36.
- Narayanan S, Fu L, Pioro E, De Stefano N, Collins DL, Francis GS, et al. Imaging of axonal damage in multiple sclerosis: spatial distribution of magnetic resonance imaging lesions. *Ann Neurol* 1997; 41: 385–91.
- Poline JB, Worsley KJ, Evans AC, Friston KJ. Combining spatial extent and peak intensity to test for activations in functional imaging. *Neuroimage* 1997; 5: 83–96.
- Reddy H, Narayanan S, Matthews PM, Hoge RD, Pike GB, Duquette P, et al. Relating axonal injury to functional recovery in MS. *Neurology* 2000; 54: 236–9.
- Sarchielli P, Presciutti O, Pelliccioli GP, Tarducci R, Gobbi G, Chiarini P, et al. Absolute quantification of brain metabolites by proton magnetic resonance spectroscopy in normal-appearing white matter of multiple sclerosis patients. *Brain* 1999; 122: 513–21.
- Trapp BD, Peterson J, Ransohoff RM, Rudick R, Mork S, Bo L. Axonal transection in the lesions of multiple sclerosis. *N Engl J Med* 1998; 338: 278–85.
- Waxman SG, Ritchie JM. Molecular dissection of the myelinated axon. [Review]. *Ann Neurol* 1993; 33: 121–36.
- Weiller C, Ramsay SC, Wise RJ, Friston KJ, Frackowiak RS. Individual patterns of functional reorganization in the human cerebral cortex after capsular infarction. *Ann Neurol* 1993; 33: 181–9.
- Wexler BE, Fulbright RK, Lacadie CM, Skudlarski P, Kelz MB, Constable RT, et al. An fMRI study of the human cortical motor system response to increasing functional demands. *Magn Reson Imaging* 1997a; 15: 385–96.
- Wexler BE, Fulbright RK, Lacadie CM, Skudlarski P, Kelz MB, Constable RT, et al. An fMRI study of the human cortical motor system response to increasing functional demands. *Magn Reson Imaging* 1997b; 15: 385–96.
- Witte OW. Lesion-induced plasticity as a potential mechanism for recovery and rehabilitative training. [Review]. *Curr Opin Neurol* 1998; 11: 655–62.

Received May 31, 2000. Revised July 18, 2000.

Accepted July 20, 2000