10.5005/jp-journals-10011-1115

CASE REPORT

Odontogenic Myxoma: Report of Two Cases with Review of Literature

[1]Priya Sara Thomas, [2]Subhas Babu G, [1]Chandni Mishra, [1]Anusha RL, [3]Shishir Shetty

[1]Postgraduate Student, Department of Oral Medicine and Radiology, AB Shetty Memorial Institute of Dental Sciences Mangalore, Karnataka, India

[2]Professor and Head, Department of Oral Medicine and Radiology, AB Shetty Memorial Institute of Dental Sciences Mangalore, Karnataka, India

[3]Assistant Professor, Department of Oral Medicine and Radiology, AB Shetty Memorial Institute of Dental Sciences Mangalore, Karnataka, India

Correspondence: Priya Sara Thomas, Postgraduate Student, Department of Oral Medicine and Radiology, AB Shetty Memorial Institute of Dental Sciences, Mangalore, Karnataka-575018, India, e-mail: drpriya222@gmail.com

ABSTRACT

Myxomas of the jaws are believed to arise from odontogenic ectomesenchyme. They bear a close resemblance to the mesenchymal portion of a developing tooth. Myxomas are predominantly found in young adults. Radiographically myxomas appear as unilocular or multilocular radiolucencies. The radiolucent defect can contain thin, wispy trabeculae of residual bone which are often arranged at right angles to each other. Recurrence rates from various studies average approximately 25%.

We report two cases of odontogenic myxoma, occurring in a 27-year-old female patient and 45-year-old male patient with clinical and radiographic findings and a brief review of literature.

Keywords: Multilocular, Odontogenic myxoma, Posterior mandible, Recurrence, Sunray appearance.

INTRODUCTION

Myxomas are a heterogeneous group of tumors which have a common histologic appearance of abundant myxoid ground substance.[1] Oral lesions of myxomatous origin are relatively rare.[2] The WHO classifies odontogenic myxoma under "odontogenic ectomesenchyme with or without included odontogenic epithelium" (1992).[3] It is locally invasive and has a high recurrence rate ranging from 10 to 33% with a reported average of 25%.[4]

CASE REPORTS

Case 1

A 27-year-old female reported with a complaint of swelling in the right lower cheek region for a period of 6 months with a history of a similar swelling in the same site 3 years back. She had undergone removal of the swelling and the lower right posterior teeth 3 years prior to reporting to our department. She eventually underwent two more surgeries since the swelling reportedly recurred every 6 months after removal.

Head and neck examination revealed a diffuse swelling in the right lower posterior jaw measuring approximately 8 × 5 cm. The swelling was tender, firm in consistency with ill-defined borders and fixed to the underlying tissues. Only a right single submandibular lymph node was palpable measuring 1.5 cm in size which was movable and tender. Intraoral examination revealed a well-defined expansive swelling measuring 4 × 3 cm in size involving the right lower alveolus, right floor of the mouth, right buccal mucosa which was tender and soft on palpation at the center of the swelling but firm otherwise (Fig. 1).

A provisional diagnosis of a benign odontogenic tumor was considered. The panoramic radiograph revealed a multilocular radiolucency extending from the distal root of 45 to the ramus as well as involving the entire width of the body (Fig. 2). A mandibular lateral oblique view revealed destruction of the buccal cortical plate with a network of septa arranged at right

Fig. 1: Intraoral view of the lesion

angles to the lower border of the mandible giving a characteristic sunray appearance. The soft tissue margins were observed beyond the peripheral trabeculation and the disrupted cortical margins.

CT revealed an expansile lytic multilocular lesion involving the alveolar bone, body, ramus and angle of the right side of the mandible. The tumor showed relatively homogeneous density with the exception of internal trabeculations (Fig. 3).

Incisional biopsy was then performed and histopathology confirmed the diagnosis of odontogenic myxoma of the right posterior mandible (Fig. 4).

Following which, wide excision of the lesion with segmental resection and reconstruction with stainless steel plate was done. A lip split submandibular incision passing 2 cm below the angle of the right mandible with subplatysmal dissection was given to expose the lesion extraorally. Lesion was excised along with the body and angle of the mandible. Reconstruction plate was adapted and screwed to the condyle and coronoid distally and to the parasymphyseal mandibular region mesially. Patient has been on periodic follow-up for the past 2 years.

Case 2

A 45-year-old male reported to our department with a chief complaint of swelling on the right lower posterior region of the jaw since 10 years. It was insidious in onset and nonprogressive initially but patient complained of rapid growth since one month. Patient had a habit of chewing betel nut, betel leaves, lime and tobacco 10 to 12 times/day for the past 35 years with preferential chewing on the right side and occasional consumption of alcohol since 20 years.

Head and neck examination revealed the presence of a localized swelling on the right side posterior mandibular region measuring approximately 3.5 × 4 cm in size, roughly oval in shape and hard in consistency. Bilateral palpable submandibular and posterior cervical lymph nodes which were soft, nontender, mobile and measuring approximately 1 cm.

Intraoral examination revealed a solitary ill-defined swelling arising from the buccal sulcus area firm to hard in consistency (Fig. 5). Ulceration was noted with relation to 47 buccally. Base of the ulcer was indurated and covered with necrotic slough. Pus discharge was also noticed from the ulcer. Grade III mobility was noticed with respect to 47 and 48.

Based on the clinical findings, a malignant tumor of the right posterior mandibular region was considered. Given the duration of the swelling, differential diagnosis of a benign odontogenic tumor turning into a malignancy was also considered. Lateral oblique view revealed multilocular radiolucency extending from distal to root of 43 to the ramus (Fig. 6). Scalloping between the roots was seen. Mandibular occlusal view revealed destruction of the buccal cortical plate and fine septa arising from the outer cortical plate. Incisional biopsy was then performed.

Histopathology confirmed the diagnosis of odontogenic myxoma (Fig. 7).

Treatment rendered was the wide excision of the lesion with segmental resection and reconstruction with stainless steel plate was done and patient was put on periodic follow-up for 3 years.

DISCUSSION

Myxomas were first described by Virchow in 1871. Myxomas of the jaws were identified by Thoma in 1954.[5] In the head and neck, two forms of myxomas or fibromyxomas are recognized: one is derived from the facial skeleton, the other is derived from the soft tissue. Myxoma of bone exclusive of the jaws and facial skeleton is nearly nonexistent.[6]

The uncertainty that the myxoma is strictly an odontogenic lesion, sustained by its origin in extragnathic locations and

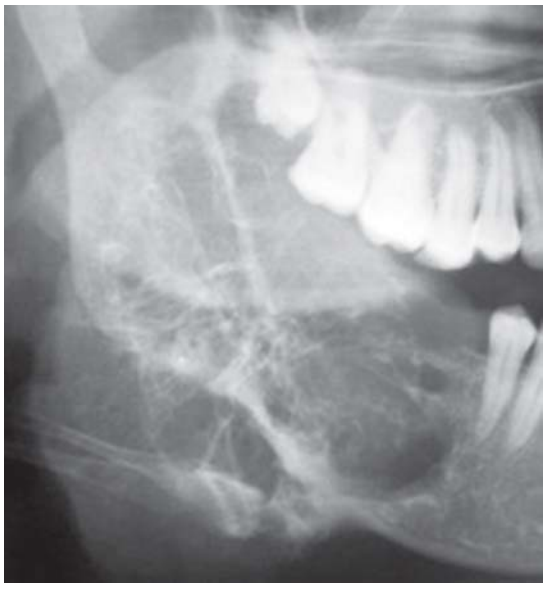

Fig. 2: Panoramic view revealing the multilocular radiolucency

Fig. 3: CT view—expansile lytic multilocular lesion involving the alveolar bone, body, ramus and angle of the right side of the mandible with relatively homogeneous density

nontooth bearing area of the jaws. Although the evidence is mainly circumstantial, support of an odontogenic origin has been postulated by: (1) Its almost exclusive occurrence in the tooth bearing areas of the jaws, (2) its frequent occurrence in the young individuals, (3) its common association with an unerupted tooth or a developmentally absent tooth, (4) its histologic resemblance to dental mesenchyme, especially the dental papilla, and (5) the occasional presence of sparse amounts of odontogenic epithelium.[5,6]

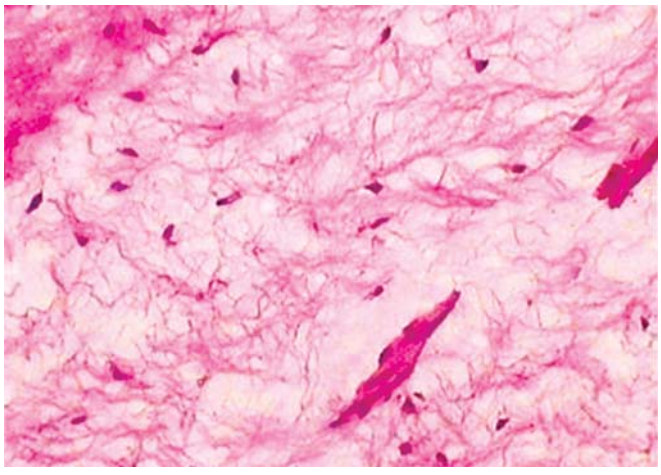

Fig. 4: Histopathology—loosely arranged spindle, rounded and stellate-shaped cells with a lightly eosinophilic cytoplasm in a mucoid rich (myxoid) intercellular matrix

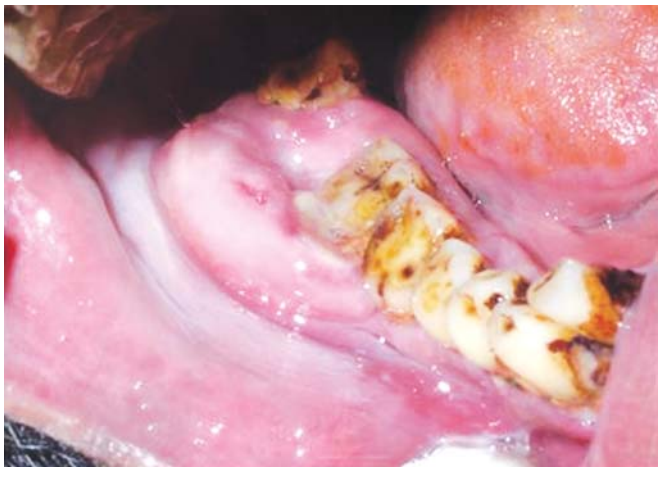

Fig. 5: Intraoral photograph showing swelling

Odontogenic myxoma is the second most common odontogenic lesion with average age ranging from 25 to 30 years. The preference for occurrence in either gender is equivocal in literature.[7]

The mandibular molar and ramus region is more commonly involved than the maxilla. In some instances, clinical growth of the tumor may be rapid as seen in our second case report, this is probably related to the accumulation of myxoid ground substance in the tumor.[3]

On computed tomography (CT) images, the low density area may correspond to the area with the abundant mucoid component. The solid portion of the tumor is reported to be rich in collagen fiber and may correspond to the enhanced area seen on CT images.[8]

Histologically, the myxoma is composed of loosely arranged spindle, rounded and stellate-shaped cells with a lightly eosinophilic cytoplasm in a mucoid rich (myxoid) intercellular matrix. The myxoid matrix is rich in hyaluronic acid and chondroitin sulphate; myxomas pervade bone possibly as a result of the large content of hyaluronic acid.

A number of surgical methods have been advocated, including excision, enucleation and curettage, curettage with and without electrical or chemical cautery, *en bloc* resection and wide resection with and without immediate grafting.[6] According to Chiodo et al, radiotherapy should not be considered as a standard therapy because these tumors are benign, occur in young patients and are easily excised, avoiding the late risk of radiation induced tumors.[9]

Mandibular lesions can be managed primarily using a reconstruction plate followed by an immediate or delayed vascularized fibular free lap, iliac crest graft, costochondral

Fig. 6: Lateral oblique view showing destruction of the buccal cortical plate and fine septa arising from the outer cortical plate

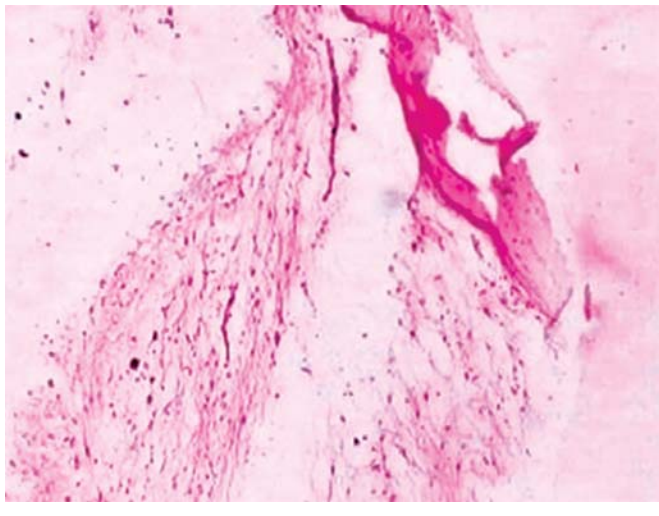

Fig. 7: Histopathology—numerous spindle, rounded and stellate-shaped cells

graft or scapular osteocutaneous free flap.[10] Our case was primarily managed with a stainless steel reconstruction plate.

The overall recurrence rates range from 10 to 33% with a mean rate of 25%. It was suggested by Noffke et al that the invasive nature and high tendency of odontogenic myxoma to recur was more likely to be the result of tumor spillage in the operating field due to the gelatinous consistency and the poorly defined borders which was present in nearly half of all the odontogenic myxomas investigated.[4,6,7]

A minimum follow-up of 5-year is advisable to establish disease free states.[7] Bone and soft tissue reconstruction or osseointegrated implants should be reserved for those patients who remain free of the disease for 3 to 5 years after surgery or until the surgeon is confident that the patient is free of recurrence.[9]

ACKNOWLEDGMENT

AB Shetty Memorial Institute of Dental Sciences, Mangalore, Karnataka, India.

REFERENCES

1. Takahashi H, Fujita S, Okabe H. Immunohistochemical investigation in odontogenic myxoma. J Oral Pathol Med 1991;20:114-19.
2. Bucci E, Lo Muzio L, Mignogna MD, De Rosa G. Odontogenic myxoma: Report of a case with peculiar features. J Oral Maxillofac Surg 1991;49:91-94.
3. Rajendran, Shivapathasundharam. Shafer's Textbook of Oral Pathology: Elsevier 2006;5:413-16.
4. Mehrotra D, Kamboj M. Recurrent odontogenic myxofibroma of the mandible in a 12-year-old: An illustrative case report. J Clin Pediatr Dent 2008;32(4):309-12.
5. Halfpenny W, Verey A, Bardsley V. Myxoma of the mandibular condyle: A case report and review of literature. Oral Surg Oral Med Oral Pathol Oral Radiol Endod 2000;90: 348-53.
6. Brannon RB. Odontogenic tumors. Oral Maxillofacial Surg Clin N Am 2004;16:359-74.
7. Adebayo ET, Ajike SO, Adekeye EO. A review of 328 odontogenic tumors in kaduna, Nigeria. J Oral Maxillofac Surg 2005;63:811-19.
8. Koseki T, Kobayashi K, Hashimoto K, et al. Computed tomography of odontogenic myxoma. Dentomaxillofacial Radiology 2003;32:160-65.
9. Chiodo AA, Strumas N, Gilbert RW, Birt BDB. Management of odontogenic myxoma of the maxilla. Otolaryngol Head Neck Surg 1997;117:S73-76.
10. Leiser Y, Abu-el-naaj I, Peled M. Odontogenic myxoma: A case series and review of the surgical management. Journal of Cranio-maxillofacial Surgery 2009;37:206-09.