

Masticatory muscle activity in children with a skeletal or dentoalveolar open bite

Tatiana dos Santos Ciccone de Faria*, Simone Cecilio Hallak Regalo**, Adilson Thomazinho**, Mathias Vitti** and Cláudia Maria de Felício*

*Department of Otorhinolaryngology, Ophthalmology and Head and Neck Surgery, Faculty of Medicine and

**Dental School of Ribeirão Preto, University of São Paulo, Brazil

SUMMARY The aim of this study was to compare the electromyographic (EMG) characteristics of masticatory muscles in children with either a skeletal or dentoalveolar open bite, compared with a control group (CG).

Forty-five children (31 boys and 14 girls), aged 6–11 years, were included in the study, 15 with a skeletal anterior open bite (SAOB), 15 with a dentoalveolar anterior open bite (DAOB), and 15 with a normal occlusion (CG), defined by clinical evaluation and lateral cephalograms. EMG recordings of the temporal and masseter muscles were performed under maximal voluntary clenching and during chewing. Analysis of variance was used for inter-group analysis, followed by the Tukey *post hoc* test. A Student's *t*-test for paired data was used for intra-group analysis.

There were statistically significant differences among the three groups ($P < 0.05$), with the mean EMG being highest in the CG and lowest in children with a SAOB. The percentage EMG activity during chewing in relation to that during maximal voluntary clenching was more than 100 per cent in the SAOB group. The CG and DAOB groups presented higher EMG activity during clenching compared with chewing ($P < 0.001$), as well as a greater difference between tasks.

In the SAOB group, the neuromuscular system appeared to have a lower capacity to produce EMG activity according to the task, while that in the DAOB group suggests that their functional capacity during growth should also be carefully observed.

Introduction

It has been widely accepted that accurate differentiation between a dentoalveolar and a skeletal open bite is essential in determining an appropriate treatment plan (Burford and Noar, 2003). In a dentoalveolar open bite, the disorder occurs during tooth eruption and alveolar growth. With this type of malocclusion, the skeletal components are relatively normal. In a skeletal open bite, in addition to the dentoalveolar disorders, there is a lack of proportion between the bones of the craniofacial complex (Proffit, 2000). When there is a predominance of vertical growth, i.e. a dolichofacial pattern, open bite patients present problems in prevention, correction, and post-treatment retention (Pepicelli *et al.*, 2005; Remmers *et al.*, 2008).

According to Proffit and Fields (1983), not all adult individuals with a long face present such a pattern before puberty. Therefore, it would be interesting to investigate the masticatory muscle electromyographic (EMG) activity of subjects with a dentoalveolar anterior open bite (DAOB) and skeletal anterior open bite (SAOB) during the growth phase.

The relationship between EMG parameters of the masticatory muscles and vertical craniofacial morphology has been described in children and adults (Ingervall and Thilander, 1974; Ueda *et al.*, 2000; Serrao *et al.*, 2003; Cha *et al.*, 2007). Maximal voluntary contraction was

negatively correlated with anterior face height, mandibular inclination, vertical jaw relationship, and gonial angle (Bakke and Michler, 1991), i.e. the mean EMG amplitude for masticatory muscles of 'long face' subjects was lower than those of subjects with a 'short face' (Serrao *et al.*, 2003).

The evaluation of masticatory muscle activities may be useful in improving orthodontic treatment and in determining a correct retention period after treatment (Kayukawa, 1992), because it has been widely accepted that function of the masticatory muscles is related to craniofacial morphology (Bakke and Michler, 1991; Ueda *et al.*, 2000; Kiliaridis *et al.*, 2003; Serrao *et al.*, 2003; Satiroglu *et al.*, 2005; Kiliaridis, 2006; Charalampidou *et al.*, 2008).

It may also be useful in order to establish treatment goals and procedures to be adopted in orofacial myofunctional therapy, which has proved to be effective in resolving the muscular and functional disorders frequently associated with an anterior open bite (Degan and Puppini-Rontani, 2005; Trawitzki *et al.*, 2006; Felício *et al.*, 2008).

In the present study, the EMG characteristics of children with a SAOB or a DAOB were analysed during static and dynamic tasks, and the data were compared with that obtained of subjects of comparable age, without an open bite.

Subjects and methods

The study was approved by the Human Research Ethics Committee of São Paulo University and the parents of all subjects gave written informed consent.

Subjects

One-hundred consecutive children on the university waiting list for orthodontic treatment were examined. Sixty presented an open bite, 25 a SAOB, and 35 a DAOB. Fifteen children were randomly selected from the SAOB group and 15 from the DAOB group, using the GraphPad Software (www.graphpad.com/quickcalcs; 10 boys and 20 girls: mean age 8.47 years; range 6–11 years). In each group with an open bite, there were eight children with a crossbite.

The control group (CG) comprised 15 matched volunteer children (4 boys and 11 girls: mean age 9.87 years; range 6–11 years) with an Angle Class I occlusion, without an open bite and with normal cephalometric measurements.

The inclusion criteria were: no apparent or reported history of neurological, developmental, or intellectual problems according to parental report and examiner observation; no previous or current tumours or traumas in the head and neck region; and no previous orthodontic treatment or orofacial myofunctional therapy.

The groups were defined by clinical examination and cephalometric measurements, performed by the same orthodontist (AT) for all subjects.

Methods

The vertical relationship between the upper and lower incisors was measured using digital callipers (Mitutoyo; Absolute Coolant Proof IP66, Aurora, Illinois, USA) during the clinical examination. Radiographs were obtained for all subjects according to the Broadbent technique (Broadbent, 1931) in habitual dental occlusion. The radiographs were traced and cephalometric measurements were undertaken. In order to standardize the cephalometric measurements of the bilateral anatomical structures on the two radiographic images, the image closest to the film (in this study, the left side) was used, which more accurately represents the real size of the radiographic structures. Points, lines, and cephalometric planes used for the cephalometric measurements were those defined by Krogman and Sassouni (1957).

From the cephalograms individually traced for each case, the facial skeletal pattern was analysed in the vertical plane using the cephalometric measurements: NS–GoGn angle, the inclination of the mandibular plane with respect to the anterior base to the cranium that expresses the opening degree and anterior vertical height of the mandible; it also determines the vertical growth pattern; NS–Gn angle, vertical and antero-posterior mandibular growth; Facial

axis angle, the direction of mandibular growth that expresses the vertical position of the chin. This angle is determined by intersection of nasion–basion (NBa) line with the pterygoid–gnathion (PtGn) line.

For the differential diagnosis between a DAOB and SAOB, a formula was used based on cephalometric analysis of the angles that express mandibular plane inclination (NS–GoGn), vertical and antero-posterior mandibular growth (NS–Gn), and the facial axis angle: $y = -0.2787 \times x_1 - 0.5422 \times x_2 + 1.2029 \times x_3$, where $x_1 = \text{NS–GoGn}$; $x_2 = \text{NS–Gn}$ and $x_3 = \text{facial axis}$ (Ali-Mere *et al.*, 2005).

The subjects presenting a y value greater than 55.83 degrees were assigned to the DAOB group and those presenting a y value less than or equal to 55.83 were assigned to the SAOB group. The error of the method was 3.5 per cent, i.e. there is a 3.5 in 100 chance that a subject belonging to one group is classified as belonging to the other (Ali-Mere *et al.*, 2005).

Surface differential active electrodes (two, 10 mm long and 2 mm wide, silver-chloride bars, separated by a distance of 10 mm) were used in the study. Electromyography was performed using five channels of the Myosystem-Br1 apparatus (DataHomins Tecnologia Ltda, Uberlândia, Minas Gerais, Brazil), with simultaneous acquisition, common grounding to all channels, input impedance of each channel of 10 G Ω in differential mode, 12 bites of dynamic resolution range, and amplitude band of –10V to +10V. The software Myosystem I, version 3.5 (DataHomins Tecnologia Ltda), was used for signal visualization and processing, allowing, after digitization, the signals to be analogically amplified with a gain of 1000, filtered by a 0.01–1.5 kHz band-pass filter and sampled by a 12-b A/D converter with an acquisition frequency of 2 kHz.

The skin region where the electrodes were placed was cleaned with alcohol. The differential active electrodes were positioned in the ventral region of both masseters and in the anterior portion of the left and right temporalis muscles. The position of the electrodes was determined by palpation and they were fixed with adhesive tape, with the longest extension of the bars perpendicular to the direction of the muscle. A stainless steel circular electrode (3 cm in diameter) was used as a reference electrode (ground electrode), fixed on the skin in the region of the sternum. The localization, orientation, and tests for placing the electrodes was that suggested by the European Recommendations for Surface Electromyography for the non-invasive assessment of muscles (Hermens *et al.*, 1999, 2000). Muscle activity was assessed as the root mean square of the amplitude (micro volt). EMG signals were recorded for further analysis. All examinations were performed by the same author (SCHR).

The EMG recordings were carried out under the following clinical conditions: maximal voluntary clenching (4 seconds) and during usual chewing (20 seconds).

The chewing tests were undertaken using five products with diverse viscoelastic properties, which were obtained directly from the manufacturers to maintain consistency. The

chosen foods were Nutry® cereal bar (Nutrimental SA, São José dos Pinhais, Paraná, Brazil), consistent and fibrous; Trident® gum (Cadbury-Adams, Bauru, São Paulo, Brazil); Mendorato® peanuts (Santa Helena, Ribeirão Preto, São Paulo, Brazil), a hard food; biscuits Bono® (Nestle, São Paulo, Brazil), and BIS® chocolate (Lacta S/A, Curitiba, Paraná, Brazil), being soft and easy to swallow. The diverse properties of the foods promoted different functional stimuli for the masticatory system.

Data were analysed statistically using analysis of variance (ANOVA; 2 groups × 6 tasks × 4 muscles) in order to separately compare the subgroups with and without a crossbite in the DAOB and SAOB groups.

Percentage EMG activity during mastication (PMA) in relation to activity during maximal voluntary clenching was calculated according to the following formula:

$$PMA = \frac{(RTm + LTm + RMm + LMm)}{(RTm_{cv} + LTm_{cv} + RMm_{cv} + LMm_{cv})} \times 100,$$

where RTm, LTm, RMm, LMm correspond to muscle activity during the chewing of a given food and RTm_{cv}, LTm_{cv}, RMm_{cv}, LMm_{cv} to muscle activity during maximal voluntary clenching.

Groups CG, SAOB, and DAOB were analysed by one-way ANOVA, followed by Tukey's *post hoc* test.

A Student's *t*-test for paired data was used for intra-group data analysis regarding EMG activities of the temporal and masseter muscles, during maximal voluntary dental clenching and while chewing gum and natural foods.

All calculations were made using the Statistica software (StatSoft, Inc., Tulsa, Oklahoma, USA), with the level of significance set at 0.05.

Results

ANOVA for EMG activity data showed no significant differences between the subgroups with and without crossbite in the DAOB [$F(1,13) = 0.79, P > 0.05$] or SAOB [$F(1,13) = 0.60, P > 0.05$] groups. ANOVA showed significant differences between tasks [$F(3,39) = 8.13, P < 0.01$] and effects of task and muscle interaction [$F(15,195) = 2.15, P < 0.01$] in the DAOB group. There were also significant differences between muscles in the SAOB group [$F(3,39) = 3.96, P < 0.01$].

ANOVA for EMG activity data showed a significant difference among the groups. *Post hoc* testing demonstrated a significant difference among all three groups ($P < 0.05$). The CG presented significantly higher mean EMG activity than the DAOB and SAOB groups during clenching and in cereal bar, gum, and peanut chewing, and a higher activity than the SAOB group also when chewing a biscuit (Figure 1). There were significant differences between the DAOB and SAOB groups in clenching and biscuit chewing, with higher

mean values for the DAOB group. In contrast, the PMA index was higher in the SAOB group (Table 1).

In intra-group analysis, both the CG and DAOB groups presented higher EMG activity when clenching compared with chewing ($P < 0.001$). During chewing, these groups presented a different EMG activity regarding cereal bar and gum chewing compared with the other foods, and a different activity regarding peanut chewing compared with biscuit or chocolate chewing. The SAOB group showed no significant differences between clenching and chewing. EMG activity regarding cereal bar, gum, and peanut chewing differed from that when chewing biscuits and chocolate (Table 2).

Discussion

There is consensus that in subjects with an anterior open bite, it is necessary to make a differential diagnosis between a dentoalveolar and a skeletal open bite (Proffit, 2000; Burford and Noar, 2003), which require different treatment.

Radiographic cephalometry is an excellent tool for the diagnosis of these abnormalities (Ali-Mere *et al.*, 2005). However, it does not represent the dynamic state of the maxillofacial and intraoral environments (Usui *et al.*, 2007).

The muscles of the maxilla and mandible would seem to be of paramount importance in the aetiology and active treatment of malocclusions and jaw deformities, and also for the stability of such therapies (Pepicelli *et al.*, 2005).

EMG is a useful tool for diagnosis and for the determination of treatment outcomes (Degan and Puppini-Rontani, 2005; Trawitzki *et al.*, 2006; Felício *et al.*, 2008; Tartaglia *et al.*, 2008) and therefore was the method chosen in the present study to determine the activity of the temporal and masseter muscle of subjects with a DAOB or SAOB during the growth phase, with a CG being used as the reference.

Due to the presence of a crossbite among the subjects in the two groups with an open bite, a comparison was first made between the subjects with and without a crossbite. As no significant difference was observed, a crossbite was not considered in further analyses.

In the present study, the CG, in general, showed higher mean EMG values than the DAOB and SAOB groups. During clenching and biscuit chewing, the EMG activity was higher in the DAOB than in the SAOB group. The CG and DAOB groups showed a higher EMG activity when clenching, which differed from the mean values when chewing. In contrast, no difference in EMG activity was observed in the SAOB group between clenching and chewing.

EMG activity has been investigated in subjects with different patterns of craniofacial growth and different types of malocclusion, and significant relationship, have been reported between masticatory muscle activity and cephalometric variables (Ingervall and Thilander, 1974; Ueda *et al.*, 2000; Serrao *et al.*, 2003; Cha *et al.*, 2007), as also found in the present study. Lower occlusal strength has also been previously observed in subjects with a skeletal

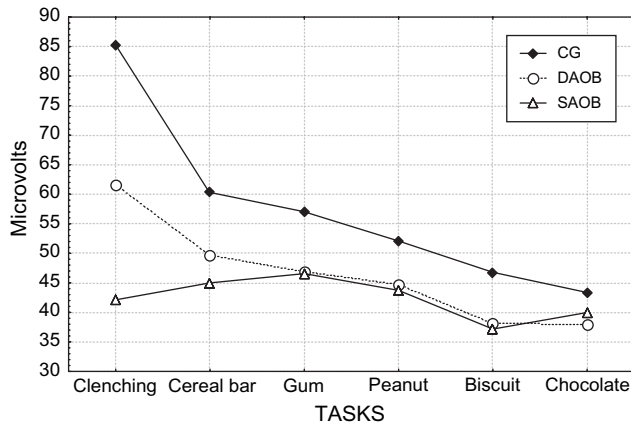


Figure 1 Mean electromyographic activity during clenching and chewing in the control group (CG), dentoalveolar anterior open bite (DAOB), and skeletal anterior open bite (SAOB) groups.

Table 1 Temporal and masseter muscle percentage activity (PMA) during mastication in relation to clenching (mean and standard deviation) in the control group (CG), dentoalveolar anterior open bite (DAOB), and skeletal anterior open bite (SAOB) groups.

	CG (n = 15)	DAOB (n = 15)	SAOB (n = 15)	P
Clenching	85.27 ^a ± 50.38	61.52 ^b ± 28.18	42.13 ^c ± 28.79	0.000
Cereal bar	60.33 ^a ± 29.56	49.60 ^b ± 19.40	44.99 ^b ± 22.50	0.002
Gum	57.07 ^a ± 26.38	46.85 ^b ± 17.19	46.56 ^b ± 25.96	0.020
Peanut	52.09 ± 25.99	44.74 ± 18.50	43.72 ± 18.94	NS
Biscuit	46.78 ^a ± 19.29	38.08 ^a ± 16.72	37.17 ^b ± 20.00	0.040
Chocolate	43.36 ± 27.65	38.04 ± 18.87	39.97 ± 21.27	NS
PAM				
Cereal bar	89.86 ^a ± 57.72	86.80 ^a ± 25.54	139.33 ^b ± 76.61	0.026
Gum	82.42 ^a ± 41.06	81.81 ^a ± 25.82	138.83 ^b ± 75.43	0.005
Peanut	78.20 ^a ± 52.45	78.91 ^a ± 28.10	142.50 ^b ± 89.69	0.009
Biscuit	68.08 ^a ± 43.70	68.98 ^a ± 31.21	110.51 ^b ± 53.24	0.015
Chocolate	62.54 ^a ± 28.03	68.29 ^a ± 26.10	135.25 ^b ± 102.02	0.004

NS: not significant, $P > 0.05$. Means with different superscripts (a, b, or c) differed in the *pos hoc* test.

Table 2 Mean electromyographic activity during clenching and chewing in the control group (CG), dentoalveolar anterior open bite (DAOB), and skeletal anterior open bite (SAOB) groups.

Groups	Clenching	Cereal bar	Gum	Peanut	Biscuit	Chocolate
GC	85.27	60.33 ^{*a}	57.07 ^{*a}	52.09 ^{*b}	46.78 ^{*c}	43.36 ^{*c}
DAOB	61.52	49.60 ^{*a}	46.85 ^{*a}	44.74 ^{*b}	38.08 ^{*c}	38.04 ^{*c}
SAOB	42.13	44.99 ^a	46.56 ^a	43.72 ^a	37.17 ^b	39.98 ^b

Means with *: significant difference between clenching and chewing tasks. Means with different superscripts (a, b or c): significant difference between chewing tasks. Student *t*-test for paired data.

open bite compared with controls in all biting positions (Ellis *et al.*, 1996).

Since in the clenching test the subjects were asked to perform maximum tooth clenching, PMA indices were expected to be always less than 100 per cent, and this occurred in the CG and DAOB groups but not in the SAOB group. The differences in EMG activity in the SAOB group when the subjects chewed the different foods were less frequent, suggesting a lack of adaptation to the demands of the tasks.

The teeth, the masticatory muscles, and the temporomandibular joints are important for the chewing process because together they form the mechanism by which food particles are fragmented (Pereira *et al.*, 2006). Among other factors, the chewing process is adapted to accommodate food texture, i.e. when harder foods are being chewed there is a greater amplitude of EMG activity of masticatory muscles than when softer foods are being chewed (Mioche *et al.*, 1999; Foster *et al.*, 2006).

Variations in EMG activity according to food consistency demonstrate the capacity of the stomatognathic system to adapt to the load and its neuromuscular equilibrium (Piancino *et al.*, 2005). Neurophysiologic evidence of receptor activity and reflex interaction with the basic motor programme of the craniomandibular muscles tends to indicate that the peripheral occlusal control of the elevator muscles is provided by feedback from periodontal pressoreceptors. Occlusal stability keeps the muscles fit and enables the masticatory system to meet its functional demands (Bakke, 1993). There is symmetry between left and right side chewing, with higher EMG activity on the working side than on the non-working side (Ferrario *et al.*, 2004) and relative contraction from muscle to muscle (Belser and Hannan, 1985). Thus, this capacity seems to be reduced in subjects with a SAOB.

The data showed that the DAOB group presented the same tendency as the CG regarding the PMA of the various foods and the comparison of tasks, although EMG activity was always lower, especially during clenching.

Based on the results of the present study, it may be suggested that, just as there is concern about the function of masticatory muscles in subjects with a SAOB, there should also be a similar concern for children with a DAOB during growth since when a long face is manifested during childhood the subjects will rarely grow outside this pattern. However, not all individuals who become adults with a long face present this growth pattern before puberty (Proffit and Fields, 1983).

According to previous research, the functional capacity of masticatory muscles may be considered to be one factor that influences facial morphology (Kiliaridis *et al.*, 2003; Satiroglu *et al.*, 2005; Charalampidou *et al.*, 2008). Increased loading of the jaws associated with masticatory muscle function increases sutural growth and stimulates bone apposition, resulting in greater transverse growth of the maxilla and broader bone bases for the dental arches. Furthermore, an increase in masticatory muscle function is

often associated with an anterior growth rotation pattern and well-developed mandibular angular, coronoid, and condylar processes (Kiliaridis, 2006).

Clinical evaluation of masticatory activity can be useful for the improvement of orthodontic treatment and for the determination of a specific retention period after treatment. In addition, orthodontic treatment should include some type of dynamic myofunctional therapy allied to the correction of static structural abnormalities (Kayukawa, 1992).

Conclusion

On the basis of the current results, it may be concluded that:

1. EMG activity of the masseter and temporal muscles during clenching and chewing was significantly higher in the CG compared with the DAOB and SAOB groups.
2. The DAOB group had a higher mean EMG than the SAOB group during clenching and biscuit chewing.
3. The activity of the masticatory muscles varied according to the demands of the tasks in the CG and DAOB group.
4. The SAOB group did not show differences between clenching and chewing and the percentage EMG activity during chewing was greater than 100 per cent, indicating a reduced capacity of adaptation to the demand of the task.
5. During the growth phase, attention should be paid to the function of masticatory muscles in subjects with a SAOB or DAOB.

Address for correspondence

Cláudia Maria de Felício
 Department of Otorhinolaryngology
 Ophthalmology and Head and Neck Surgery
 Faculty of Medicine of Ribeirão Preto
 University of São Paulo Av. dos Bandeirantes
 3900 14049-900 Ribeirão Preto, SP
 Brazil
 E-mail: cfelicio@fmrp.usp.br

Funding

Coordenação de Aperfeiçoamento de Pessoal de Nível Superior (Process DS 103/00 to S.C.H.R.); Conselho Nacional de Pesquisa (Process N. 301002/2005-3 to C.M.F.).

References

Ali-Mere H C, Thomazinho A, Felício C M 2005 Anterior open bite: a formula for the differential diagnosis. *Pró-Fono* [serial online] 17: 367–374

Bakke M 1993 Mandibular elevator muscles: physiology, action, and effect of dental occlusion. *Scandinavian Journal of Dental Research* 101: 314–331

Bakke M, Michler L 1991 Temporalis and masseter muscle activity in patients with anterior open bite and craniomandibular disorders. *Scandinavian Journal of Dental Research* 99: 219–228

Belser U C, Hannan A G 1985 The influence of altered working-side occlusal guidance on masticatory muscles and related jaw movement. *Journal of Prosthetic Dentistry* 53: 406–413

Broadbent B H 1931 A new X-ray technique and its application to orthodontia. *Angle Orthodontist* 1: 45–66

Burford D, Noar J H 2003 The causes, diagnosis and treatment of anterior open bite. *Dental Update* 30: 235–241

Cha B K, Kim C H, Baek S H 2007 Skeletal sagittal and vertical facial types and electromyographic activity of the masticatory muscle. *Angle Orthodontist* 77: 463–470

Charalampidou M, Kjellberg H, Georgiakaki I, Kiliaridis S 2008 Masseter muscle thickness and mechanical advantage in relation to vertical craniofacial morphology in children. *Acta Odontologica Scandinavica* 66: 23–30

Degan V V, Puppini-Rontani R M 2005 Removal of sucking habits and myofunctional therapy: establishing swallowing and tongue rest position. *Pró-Fono* 17: 375–382

Ellis E, Throckmorton G, Sinn D P 1996 Functional characteristics of patients with anterior open bite before and after surgical correction. *International Journal of Adult Orthodontics and Orthognathic Surgery* 11: 211–223

Felício C M, Melchior M O, Ferreira C L P, Rodrigues da Silva M A M 2008 Otolgic symptoms of temporomandibular disorder and effect of orofacial myofunctional therapy. *Journal of Craniomandibular Practice* 26: 118–125

Ferrario V F, Tartaglia G M, Maglione M, Simion M, Sforza C 2004 Neuromuscular coordination of masticatory muscles in subjects with two types of implant-supported prostheses. *Clinical Oral Implants Research* 15: 219–225

Foster K D, Woda A, Peyron M A 2006 Effect of texture of plastic and elastic model foods on the parameters of mastication. *Journal of Neurophysiology* 95: 3469–3479

Hermens H J, Freriks B, Disselhorst-Klug C, Rau G 2000 Development of recommendations for SEMG sensors and sensor placement procedures. *Journal of Electromyography and Kinesiology* 10: 361–374

Hermens J H *et al.* 1999 European recommendations for surface electromyography—results of the SENIAM project, Roessingh Research and Development. pp.13–58

Ingervall B, Thilander B 1974 Relation between facial morphology and activity of the masticatory muscles. *Journal of Oral Rehabilitation* 1: 131–147

Kayukawa H 1992 Malocclusion and masticatory muscle activity: a comparison of four types of malocclusion. *Journal of Clinical Pediatric Dentistry* 16: 162–177

Kiliaridis S 2006 The importance of masticatory muscle function in dentofacial growth. *Seminars in Orthodontics* 12: 110–119

Kiliaridis S, Georgiakaki I, Katsaros C 2003 Masseter muscle thickness and maxillary dental arch width. *European Journal of Orthodontics* 25: 259–263

Krogman W M, Sassouni V 1957 A syllabus in roentgenographic cephalometry. Library of Congress, Philadelphia

Mioche L, Bourdiol P, Martin J F, Noel Y 1999 Variation in human masseter and temporalis muscle activity related to food texture during free and side-imposed mastication. *Archives of Oral Biology* 44: 1005–1012

Pepicelli A, Woods M, Briggs C 2005 The mandibular muscles and their importance in orthodontics: a contemporary review. *American Journal of Orthodontics and Dentofacial Orthopedics* 128: 774–780

Pereira L J, Duarte Gavião M B, Van Der Bilt A 2006 Influence of oral characteristics and food products on masticatory function. *Acta Odontologica Scandinavica* 64: 193–201

- Piaincio M G *et al.* 2005 Electromyographic evaluation of neuromuscular co-ordination during chewing in a subject with organic occlusion. *Minerva Stomatologica* 54: 379–387
- Proffit W R 2000 Contemporary orthodontics. Mosby, St Louis
- Proffit W R, Fields H W 1983 Occlusal forces in normal and long face children. *Journal of Dental Research* 52: 571–574
- Remmers D, Van't Hullenaar R W G J, Bronkhorst E M, Bergé S J, Katsaros C 2008 Treatment results and long-term stability of anterior open bite malocclusion. *Orthodontics and Craniofacial Research* 11: 32–42
- Satiroglu F, Arun T, Isik F 2005 Comparative data on facial morphology and muscle thickness using ultrasonography. *European Journal of Orthodontics* 27: 562–567
- Serrao G, Sforza C, Dellavia C, Antinori M, Ferrario V F 2003 Relation between vertical facial morphology and jaw muscle activity in healthy young men. *Progress in Orthodontics* 4: 45–51
- Tartaglia G M, Rodrigues da Silva M A M, Bottini S, Sforza C, Ferrario V F 2008 Masticatory muscle activity during maximum voluntary clench in different research diagnostic criteria for temporomandibular disorders (RDC/TMD) groups. *Manual Therapy* 13: 434–440
- Trawitzki L V, Dantas R O, Mello-Filho F V, Marques Jr W 2006 Effect of treatment of dentofacial deformities on the electromyographic activity of masticatory muscles. *Journal of Oral and Maxillofacial Surgery* 35: 170–173
- Ueda H M, Miyamoto K, Saifuddin M, Ishizuka Y, Tanne K 2000 Masticatory muscle activity in children and adults with different facial types. *American Journal of Orthodontics and Dentofacial Orthopedics* 118: 63–68
- Usui T, Uematsu S, Kanegae H, Morimoto T, Kurihara S 2007 Change in maximum occlusal force in association with maxillofacial growth. *Orthodontics and Craniofacial Research* 10: 226–234