

## CASE REPORT

# MR Diagnosis of Steroid Cell Tumor of the Ovary: Value of Chemical Shift Imaging

Keiko SAKAMOTO<sup>1</sup>, Ritsuko FUJIMITSU<sup>1</sup>, Mikiko IDA<sup>1</sup>, Shinji HORIUCHI<sup>2</sup>,  
Yoshihiro HAMADA<sup>3</sup>, and Kengo YOSHIMITSU<sup>1\*</sup>

*Departments of <sup>1</sup>Radiology, <sup>2</sup>Obstetrics and Gynecology, and <sup>3</sup>Pathology,  
Faculty of Medicine, Fukuoka University  
7-45-1, Nanakuma, Jonan-ku, Fukuoka 814-0180, Japan  
(Received August 19, 2009; Accepted October 1, 2009)*

A 53-year-old asymptomatic woman was found to have a pelvic mass at medical examination. Magnetic resonance (MR) imaging revealed a 4-cm solid mass at the right adnexal region, which showed marked hyperintensity on T<sub>2</sub>-weighted imaging and marked enhancement on post-contrast T<sub>1</sub>-weighted imaging. Chemical-shift imaging showed slight but significant signal loss on out-of-phase images, which suggested the presence of intratumoral lipid. The resected specimen exhibited typical features of steroid cell tumor, and Oil Red O stain was positive for cytoplasmic lipid.

**Keywords:** *chemical shift, fat, MR, ovary, steroid cell tumor*

## Introduction

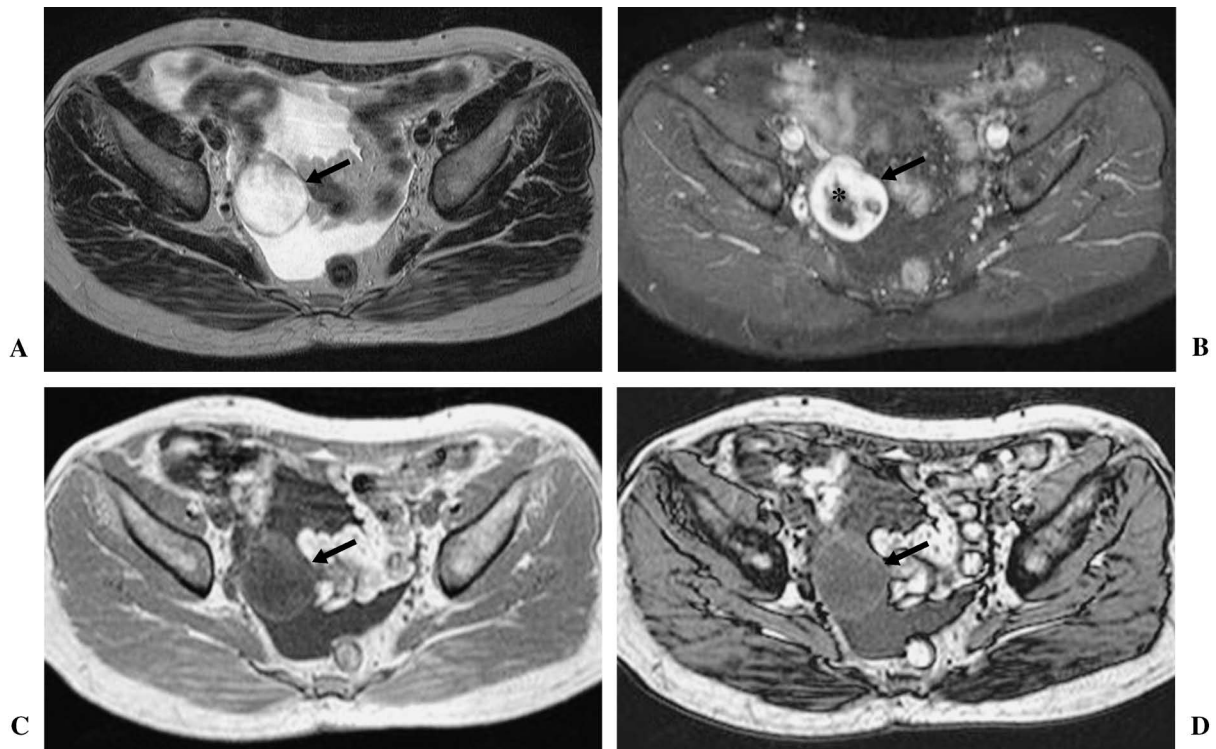
Steroid cell tumor of the ovary is rare, accounting for only 0.1 to 0.2% of all ovarian tumors.<sup>1</sup> Presence of intracytoplasmic fat within the tumor cells is one of its pathological characteristics.<sup>1-5</sup> Theoretically, chemical shift magnetic resonance (MR) imaging (CSI) should demonstrate this cytoplasmic lipid,<sup>2,6-9</sup> but to the best of our knowledge, its use has not been reported. Therefore, we report such a case in whom preoperative CSI successfully demonstrated a small amount of lipid in the steroid cell tumor of the ovary.

## Case Report

A 53 year-old woman who had been asymptomatic was found to have a pelvic mass on the right side of the pelvis on ultrasonography at physical examination. She was referred to our hospital for further work-up of the mass and possible treatment. Laboratory data on admission were mostly unremarkable, and serum estrogen and progesterone levels were within normal limits. Carbohydrate antigen 125 was at the marginal level (37 U/mL, normal range < 35 U/mL), and other tumor markers, including carcinoembryonic antigen and carbo-

hydrate antigen 19-9, were negative. Because the patient presented no sign to suggest hirsutism, serum androgen level was not measured preoperatively. MR imaging was obtained with a 1.0T clinical unit (NT Intera, Philips Medical Systems, Best, The Netherlands). The tumor showed marked homogeneous hyperintensity on fast spin-echo (FSE) T<sub>2</sub>-weighted image (repetition time/echo time/number of echo-train (TR/TE/ET)=4500 ms/100 ms/9) (Fig. 1A) and was strongly enhanced after intravenous administration of 0.1 mmol/kg gadolinium-diethylenetriamine penta-acetic acid (DTPA) (Magnevist, Bayer-Schering, Osaka, Japan) on fat-saturated FSE T<sub>1</sub>-weighted image (TR/TE/ET=400 ms/12 ms/5) (Fig. 1B). On CSI (dual-echo field-echo, TR/TE/flip angle=227.5/3.5 and 6.9/80°), the tumor showed slight but significant signal loss on out-of-phase image (Fig. 1C, D), suggesting the presence of a small amount of fat, although this signal loss was not been recognized as positive at visual inspection at the time of preoperative interpretation. Solid tumor with mucinous or myxomatous stroma was considered, and preoperative differential diagnoses included metastatic adenocarcinoma to the ovary, leiomyoma with myxoid degeneration arising from broad ligament or tube, sclerosing stromal tumor, and other possibilities. Because no significant primary malignancy was found despite extensive preoperative work-up of the whole body, simple right oophorectomy

\*Corresponding author, Phone: +81-92-801-1011, FAX: +81-92-864-6652, E-mail: kengo@fukuoka-u.ac.jp



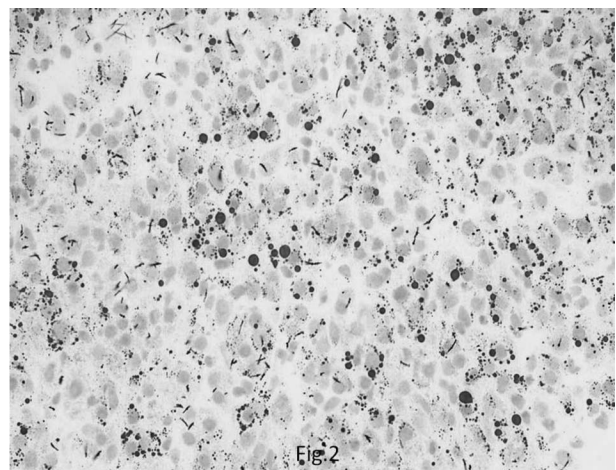
**Fig. 1.**

**A:** Axial T<sub>2</sub>-weighted fast spin-echo image through the mid-pelvis. A 4-cm mass with marked hyperintensity is shown (arrow). Ascitic fluid is also noted at the cul-de-sac. **B:** Axial T<sub>1</sub>-weighted spin-echo image after contrast injection through the mid-pelvis. The tumor is markedly enhanced (arrow). Non-enhancing areas at the central part of the tumor (asterisk) corresponded to intratumoral hemorrhage at pathological correlation. **C:** In-phase image of chemical shift magnetic resonance (MR) imaging corresponding to 1A and 1B. The tumor exhibited intermediate to low signal intensity (arrow). Signal intensity was measured to be 598, avoiding the central hemorrhage by referring to 1B. **D:** Out-of-phase image of chemical shift MR imaging. There is faint to slight signal intensity loss compared to 1C (arrow). Signal intensity was measured to be 538, placing the region of interest exactly at the same site as 1C by copy-and-paste method. Signal loss ratio was calculated to be 10%.

was performed. The resected specimen showed clusters of luteinized cells in edematous stroma, along with some crystal formations, suggesting the diagnosis of steroid cell tumor, particularly, Leydig cell tumor. Periodic-acid Schiff or Alcian blue stain was negative for mucin, and Oil Red O stain was positive for intracellular lipid (Fig. 2), confirming the diagnosis.

## Discussion

Steroid cell tumors are defined as ovarian neoplasms composed entirely of cells resembling typical steroid hormone-secreting cells, i.e., lutein cells, Leydig cells, and adrenal cortical cells. Stromal luteoma, Leydig cell tumor, and steroid cell tumor not otherwise specified (NOS), are included in this group, all of which are very rare.<sup>1-5</sup> Some tumors in the last category are clinically malignant, whereas those in the first 2 categories are benign. In most



**Fig. 2.** Microscopic finding of the tumor with Oil Red O staining (original magnification  $\times 400$ ). Intracellular black dots of various size (originally in red) indicate the presence of cytoplasmic lipid.

cases, these tumors produce androgen and typically present with hirsutism, but estrogen-producing tumors have also been reported.<sup>1-5</sup> In the present case, because no symptoms or signs suggested hyperandrogenic state, serum androgen level was not evaluated; preoperative estrogen and progesterone levels were within normal limits. There is little imaging literature on these tumors, although Leydig cell tumors are reported as hypoattenuating masses on computed tomography (CT). However, none of these showed high signal intensity on T<sub>1</sub>-weighted imaging (T<sub>1</sub>WI).<sup>2-5</sup> Signal intensity on T<sub>2</sub>-weighted imaging (T<sub>2</sub>WI) varies according to the contents of the fibrous stroma. Steroid cell tumors NOS are reported as mixed solid and cystic masses. Reported tumors showed intermediate intensity on T<sub>2</sub>WI and intense enhancement with contrast material.<sup>2-5</sup>

In the present case, marked hyperintensity on T<sub>2</sub>WI may be attributable to the edematous stroma and paucity of fibrous component. The marked enhancement after contrast administration is concordant with the previous report,<sup>2-5</sup> possibly representing abundant blood vessels supplying the tumorous tissues as well as abundant edematous stroma.

The presence of cytoplasmic lipid has been known to be a pathological characteristic of steroid cell tumors.<sup>1-5</sup> On radiological imaging, however, detection of this cytoplasmic lipid has been unsuccessful to the best of our knowledge, although the possibility of its detection with CSI has been suggested.<sup>2</sup> CSI has been utilized in the detection of small amounts of fat throughout the body, typically in diagnosing adrenal adenoma,<sup>6,7</sup> clear cell or papillary renal cell carcinoma,<sup>8,9</sup> and other tumors. Retrospective review of CSI in the present case revealed that signal loss ratio was calculated to be 10% (Fig. 1D),<sup>7-9</sup> with the ratio defined as (SI<sub>in</sub>-SI<sub>out</sub>)/SI<sub>in</sub>, where SI<sub>in</sub> stands for signal intensity at in-phase image and SI<sub>out</sub> for that at out-of-phase image. Although subtle, 10% signal loss ratio is considered sufficient to suggest the presence of fat according to the literature.<sup>7-9</sup> This is the first case reported in which CSI successfully demonstrated cytoplasmic fat in steroid cell tumors. Correct diagnosis of steroid cell tumor might have been suggested if quantitative analysis of CSI was performed preoperatively.

In conclusion, we report a case of a steroid cell tumor (Leydig cell tumor), in which preoperative CSI successfully demonstrated the presence of cytoplasmic lipid. Along with the other characteristic

imaging features, signal loss on out-of-phase of CSI may serve as an important adjunct sign of steroid cell tumor representing intratumoral lipid in this entity.

### Acknowledgements

We thank Professor Shingo Miyamoto, chair of the Department of Gynecology and Obstetrics of the Faculty of Medicine at Fukuoka University, and Professor Kazuki Nabeshima, of the Department of Pathology at Fukuoka University Hospital, for providing clinical or pathological information in this report.

### References

1. Scully RE, Young RH, Clement PB. Steroid cell tumors, In: Tumors of the ovary, maldeveloped gonads, fallopian tube and broad ligament. 3rd ed. Washington, DC: Armed Forces Institute of Pathology, 1998; 227-238.
2. Saida T, Tanaka YO, Minami M. Steroid cell tumor of the ovary, not otherwise specified: CT and MR findings. *AJR Am J Roentgenol* 2007; 188:W393-394.
3. Wang PH, Chao HT, Lee RC, et al. Steroid cell tumors of the ovary: clinical, ultrasonic, and MRI diagnosis—a case report. *Eur J Radiol* 1998; 26:269-273.
4. Tanaka YO, Tsunoda H, Kitagawa Y, Ueno T, Yoshikawa H, Saida Y. Functioning ovarian tumors: direct and indirect findings at MR imaging. *Radiographics* 2004; 24:S147-166.
5. Outwater EK, Wagner BJ, Mannion C, McLarney JK, Kim B. Sex cord-stromal and steroid cell tumors of the ovary. *RadioGraphics* 1998; 18:1523-1546.
6. Mitchell DG, Crovello M, Matteucci T, Petersen RO, Miettinen MM. Benign adrenocortical masses: diagnosis with chemical shift MR imaging. *Radiology* 1992; 185:345-351.
7. Namimoto T, Yamashita Y, Mitsuzaki K, et al. Adrenal masses: quantification of fat content with double-echo chemical shift in-phase and opposed-phase FLASH MR images for differentiation of adrenal adenomas. *Radiology* 2001; 218:642-646.
8. Yoshimitsu K, Honda H, Kuroiwa T, et al. MR detection of cytoplasmic fat in clear cell renal cell carcinoma utilizing chemical shift gradient-echo imaging. *J Magn Reson Imaging* 1999; 9:579-585.
9. Yoshimitsu K, Kakihara D, Irie H, et al. Papillary renal carcinoma: diagnostic approach by chemical shift gradient-echo and echo-planar MR imaging. *J Magn Reson Imaging* 2006; 23:339-344.