usually are not enlarged. Wasting, aneamia, hæmorrhage and biopsy of the lymphnodes are characteristic.

(5) *Leprosy.* Lymphnodes are not universally enlarged are usually limited to the area of skin involvment. Liver and spleen are not commonly enlarged. Diagnosis is clinched by section of a lymphnode as well as lympnode puncture.

Treatment. The treatment usually follows the etiology of the disease. When the etiology was considered to be leprosy the treatment was chaulmogra oil or antileprol, when chronic granulometous condition possibly of tuberculous origin, gold preparation solganol B. etc., were in use. Deep X-ray therapy was used when lymphoadinometosis was thought of. Of course each group of treatment was supported by general treatment as for example Iron, Arsenic, Multi-Vitamins in heavy doses. The treatment with A. C. T. H. or cortisone is quite compatible with the patholigical basis of the disease. The rationalise for this basis of the disease. The rationalise for this treatment of granulomatous disease due to sarcoidosis is the effect on mesenchymal tissue of cortisone or corticotrophin. This effect consists essentially of inhibition of granulomatous tissue before irreversible changes have occussed. Decrease in elevated globulin value during cortisone therapy, lowering of serum globulin and return of albumin—globulin ratio have been noted along with clinical improvement of the case.

The patient under description was treated daily with 500 mg. of Redoxon and 10 mg. of Percotin for 7 days. He developed erythema nodosum, more on the extensor surface of the body. In a few days nodular eruptions subsided and erythroderma spread all over the body simulating acute nephritis. Urine examination did not reveal any casts or R. B. C., though B. P. was slightly raised from 90/75 to 130/95 mm of Hg. (Plate Fig. No. 5). Symptomatic treatment was carried out. He we very ill for three weeks and after that no lymphnodes whether cevical or else-where, could be palpated. The spleen was reduced to 2 fingers below the costal margin and the liver could not be palpated. Two weeks after the recovery, the cervical lymphnodes again began to increase in size, the patient at this dose left the Hospital.

I am thankful to Dr. P. Bhattacharjee, General Surgeon Burdwan for allowing me to report the case.

SELECTED BIBLIOGRAPHY

Baldridge, G. D., Kligman, A. M., and Jones, R. (1951). *Amer. Rev. Tuberc.*, **63**, 672.

Ghose, B. C., and Chakravarti, G. (1953). *Indian J. Pediat.*, **20**, 280.

Hadfield, G. (1950) .. *Recent Advances in Pathology.* J. & A. Churchill Ltd., London.

Lambie, C. G. (1940) .. *Med. J. Australia, i*, 815.

Lovelock, F. J., and Stone, D. J. (1951). *J. Amer. Med. Assoc.*, **147**, 930.

Russell, K. P. (1951). *Amer. Rev. Tuberc.*, **63**, 603.

AN UNUSUAL CASE OF ANEURYSM OF THE SINUS OF VALSALVA DISSECTING INTO THE VENTRICULAR SEPTUM AND THE LEFT AURICIE

By Lt.-Col. K. P. G. MENON, M.R.C.P.

Honorary Physician, Govt. General Hospital

and

SAM G. P. MOSES, B.SC., M.D.

Assistant Physician, Govt. General Hospital, Madras

Aneurysm of the sinus of Valsalva is an uncommon but important variety, and the correct diagnosis is seldom made during life. Osler and NcCrac (1927) refers to aneurysms of this portion of the arch as having definite features. It is not detected in the wards, but is seen only in the post-mortem room, in connection with medico-legal work. It is very often latent, death occurring prior to rupture of aneurysm or before there have been any symptoms. Angina pectoris may be an early feature owing to impaired coronary filling, and aortic insufficiency is a common accompaniment. A very unusual case of such an aneurysm has been presented below and it was diagnosed only at autopsy.

Case Report

Patient S., aged 35 years, was admitted into this hospital on 21-8-1952 with a complaint of

breathlessness and pain in the front of the chest of four months' duration. The patient gave a long history of ailment pertaining to the chest, in addition to progressive loss of weight and appetite, with attacks of haemoptysis: pulmonary tuberculosis has been diagnosed and he had received adequate treatment for the same as early as 1945. Nevertheless he had been getting attacks of breathlessness coming on several times in the day and lasting for about half an hour each time. Later, he developed pain and swelling in the joints and was treated for rheumatoid arthritis with no relief.

On admission, he appeared ill-nourished, anaemic and breathless, with stiff joints and extremities deformed by swellings. There was no clubbing of the fingers. Temperature was normal.

The pulse rate was 62|minute, irregularly irregular and of normal volume and tension. The blood pressure was 130|60 in both upper extremities. Apex impulse was visible and palpable in the 5th intercostal space ½ inch outside midclavicular line. No thrills or pulsations were appreciable over the praecordium. Heart boundaries were slightly outside normal limits. Heart sounds were irregularly irregular, with no pulse deficit. Clinically partial heart block was diagnosed. Except for a faint syslic brunt over the mitral area and faint diastolic murmurs over the aortic and pulmonary areas, without any appreciable conduction, no other abnormalities were detected by auscultatiin.

Examination of other systems revealed nothing abnormal.

Investigations

Urine :

Nil abnormal.

Blood :

R.B.C. 2.95 million|c.m.m., Haemoglobin 10 gm|100 cc, W.B.C. 6800|c.m.m.; Pol. 68%, Lym. 30%, Eos. 2%. Wassermann and Kahn tests, negative. Fasting blood sugar level 125 mg%.

X-ray :

Chest A.P. View : Thick opacity, semicircular in outline adjoining the left cardiac border.

Lateral views: Heart appears pushed forwards and is just substernal, right ventricular enlargement present.

Fluoroscopy: The opaque area is non-pulsatile but moving from side to side with the contractions of the heart.

Kymogram :

A few pulsations were appreciable over the same opaque area.

Electro cardiogram :

22-9-53. Increased P.R. interval showing second degree auricule ventricular block ; a few P waves were unaccompanied by ventricular complexes ; a subsequent graph taken a few days before his death on October 7th confirmed the clinical diagnosis (at the time) of complete heart block.

Diagnosis

Various clinical diagnoses were offered. An aneurysm of the heart was first considered, the absence of pulsation on fluoroscopy being explained by arguing that clotting could have taken place in the aneurysmal sac. A tumor arising from the left auricle—a myxoma—was also considered. An aberrant thyroid was fancied to support the excitable, asthenic aspect of the patient, paroxysmal irregularities of the heart and absence of an enlarged thyroid in the neck ; but reports on the B.M.R. blood cholesterol and glucose tolerance tests were not in favour. Further, the position of the opacity visualised was considered too low for even an aberrant thyroid. A hydatid cyst which had probably calcified, a tumor of the mediastinum and bronchogenic tumors were given due consideration and rejected.

Since routine investigations, offered little help in the making of a diagnosis, a thoracotomy, after a preliminary bronchoscopy, was decided upon, by our surgical colleagues. Meanwhile, the patient was treated on symptomatic lines with sedatives, vitamin powders, iron and a blood transfusion. On 7-10-52, bronchoscopy was done under local spray by the E.N.T. surgeon ; an intrabronchial growth was visualised. The patient's condition, however, deteriorated after bronchoscopy and he expired on the same day.

Chest A.P. View: Thick opacity, semicircular Pathologist reported an aneurysm of the left posterior sinus of Valsalva, burrowing into the ventricular septum, and into the wall of the left auricle. The heart was enlarged, and there was

AN UNUSUAL CASE OF ANEURYSM OF THE SINUS OF VALSALVA DISSECTING INTO THE VENTRICULAR SEPTUM AND THE LEFT AURICLE. (PAGE 657)

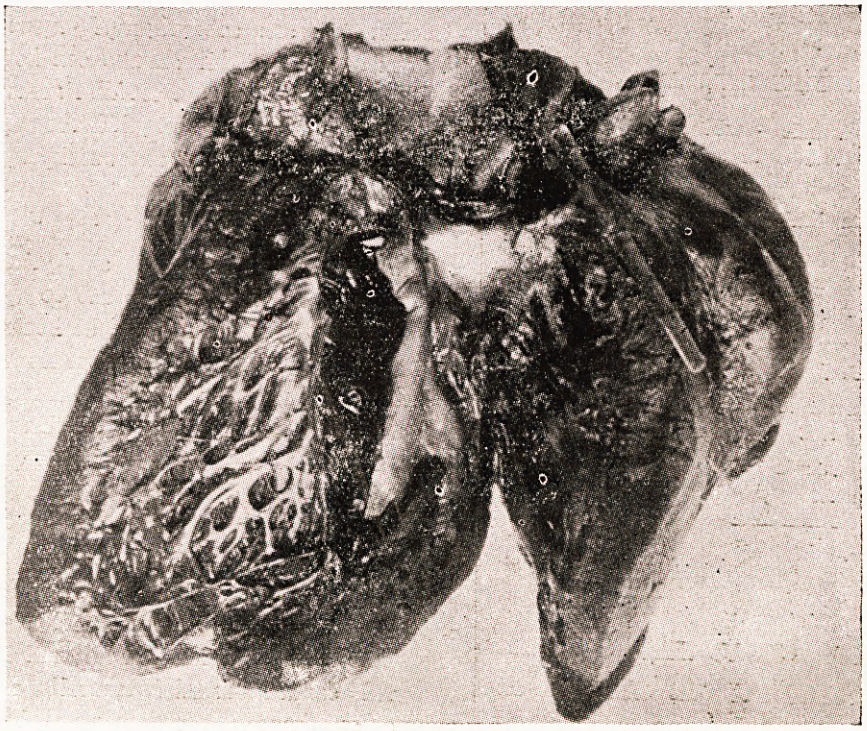

Fig. 1.

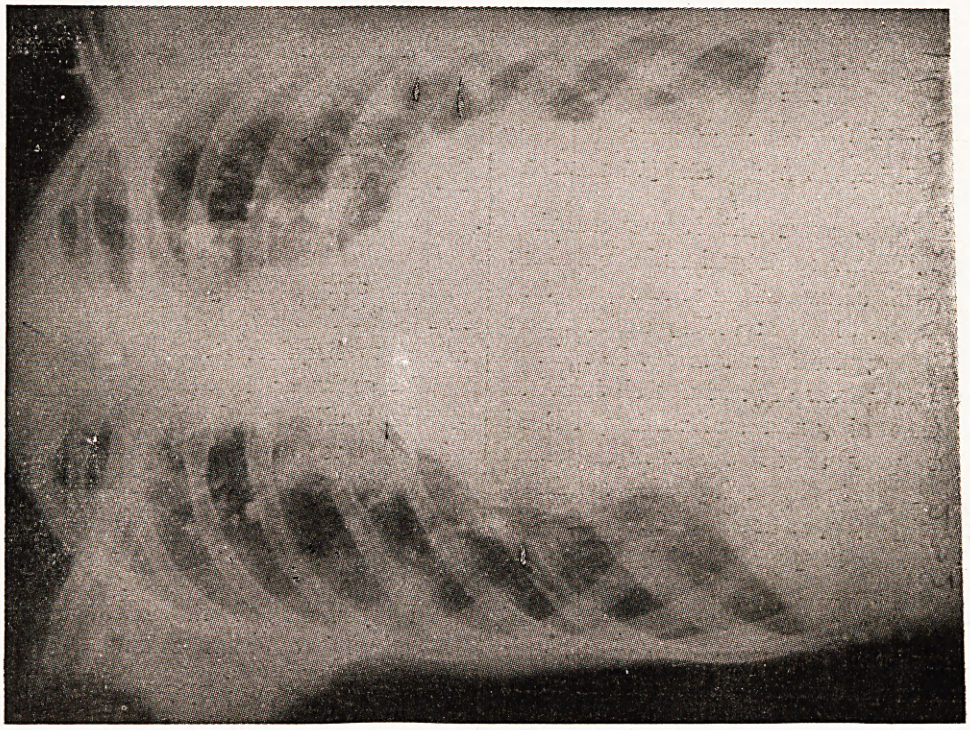

Fig. 2.

a bulge on the left border of the heart in the region of the left auricle, hemispherical, 3″× 3″, with a smooth surface. On cutting into the sac, several bits of blood clots were seen, and the inner wall of the sac was continuous with the wall of the left auricle. The left auricular wall itself was thinned out, and the mitral valve was partly calcified. The left ventricle also was enlarged and hypertrophied. On probing and dissecting further, it was observed that the bulge of the left auricle communicated with the left posterior aortic sinus and continued into an aneurysmal sac within the intraventricular septum. The oarta was wide, and on its inner aspect there were several puckered scars suggestive of syphilitic aortitis. The coronaries were normal.

The aneurysmal sac had arisen from the left posterior aortic sinus and had burrowed simultaneously into the wall of the left auricle (producing the bulge on the left border of the heart) and into the inter ventricular septum, resulting in an aneurysmal sac so large as to give the appearance of a third mid-ventricular chamber in this heart (vide photograph of specimen, Plate XLXXX, Fig. 1).

The relation of symptoms to lesions was perfectly clear. Pain in the chest was obviously due to the aneurysm growing in size. The cardiac dilatation and the calcific spots in the lung fields (Radiograph, Plate XLXXX, Fig. 2) explained the breathlessness. Reflux of blood from the aorta into the aneurysmal sac gave rise to the diastolic murmur in the aortic and pulmonary areas. The partial heart block became complete when the aneurysm dissected into the ventricular septum and destroyed the Bundle of His and its branches.

The histo-pathological examination suggested a syphilitic aetiology although the Wassermann and Kahn tests were repeatedly negative. A previous bacterial endocarditic was slenderly supported by the calcified mitral valves.

Discussion

The ascending aorta, in the region of the semilunar valves presents an onion-shaped dilatation, the bullous aorta, in which are the sinuses of Valsalva. Aneurysm of this part of the aorta has not been frequently met with, although, Osler and McCrac (1927) refers to it as a common and important variety met with particularly in syphilitic subjects, and in comparatively young men (like this case). There may be a pouching of all the three sinuses, but more commonly only one is involved as in our case. The orifice of the coronary artery may be given off from the sac, and the first part of the vessel itself may be dilated. The aortic ring may become involved and the semilunar valve may become incompetent. The aneurysm may perforate one or other auricle from the right posterior sinus, or into the pulmonary artery or the right ventricle from the left posterior aortic sinus or from the anterior ; or the sac may perforate beneath the ring into the left ventricle itself. By far, the most common perforation is into the pericardium. Rupture may also take place into the superior vena cava. Cases have been recorded where the aneurysm seemed to have taken off directly at the aortic ring and involved as much of the ventricle as of the sinus. In a review of 4,000 cases of aneurysms in general, Boyd (1924) points out that rupture most commonly takes place into the pericardium, in the case of aneurysms of Sinus of Valsalva, less commonly into the superior vena cava or the pulmonary artery, and rarely into the chambers of the heart. The first description of rupture into the pulmonary artery was by Wells, ad this syndrome has been reviewed by Nicholson (1943). The dissection of the aneurysm into the ventricular septum to such an extent as to give the appearance of a third ventricular chamber seems to be a feature peculiar to the case referred above.

Aneurysms of the sinus of Valsalva may be very occasionally congenital, when they are usually small finger-like projections, or diverticular arising from the owest part of the sinus. Acquired aneurysms, on the contrary, may be much large and more diffuse dilatation of sinuses as in syphilitic aneurysms, or irregular cavities communicating with the sinuses as in aneurysms complicating aortic valvular endocarditis, or those apparently produced by dissection (Venning 1951). This subject was reviewed by Jones and Langley (1946) who discussed in detail the differences between congenital and acquired aneurysms. This subject has also received independent attention from Raman and Menon (1949). Venning (1951, loc. cit) refers to a series of seven cases of aneurysms of aortic sinus of which three have been seen during life. In one of his cases, he was able to make a correct antemortem diagnosis in a patient in whom a congenital aneurysm of the right coronary sinus of valsalva ruptured into the right atrium.

Venning stresses the importance of radioscopy as an aid in the antemortem diagnosis of aneurysms of the aortic sinuses. He refers to one of his own cases in which a correct antemortem diagnosis of such an aneurysm rupturing into the pulmonary artery was possible, because radioscopy revealed expansile pulsations of the smaller pulomonary arteries. The same was associated with all the signs of a free aortic regurgitation ; some unusual free shunt was naturally assumed and was later confined. This is very interesting, but it is very rare and unusual to make a correct diagnosis during life. In fact, diagnosis by reasoning, antemortem, of such a congenital or acquired aneurysms of the sinus of Valsalva is impossible, unless there is rupture into some portion of the heart, the diagnosis then depending upon the alteration in the haemodynamics. Rupture of these aneurysms, therefore, need not always be immediately fatal.

Usually, at autopsy, there is great difficulty in deciding whether a given aneurysm is congenital or acquired. The difficulty is particularly apparent if there are any associated lesions of syphilis or infective endocarditis. The presence of another congenital lesion is usually evidence enough that an aneurysm is congenital. Calcification has also been reported in association with presumed congenital aneurysms and is recognised as a frequent complication of bicuspid aortic and pulmonary valves (Wauchope, 1928).

In the case described above, congenital causes were not considered because the syphilitic aetiology was evident.

Summary

1. A rare case of aneurysm of the sinus of Valsalva perforating into the wall of the left auricle and into the ventricular septum converting it into a mid-ventricular chamber has been recorded, with partial autopsy findings.

2. The clinical differential diagnosis as observed in this case has been briefly discussed and the clinical and post-mortem findings have been briefly correlated.

3. The literature on the subject has been reviewed.

We are greatly indebted to Dr. D. Gobinda Reddy, Pathologist, for his valuable report and to Dr. C. K. Prasada Rao, Dean of the Hospital for his kind permission to report this case.

REFERENCES

Boyd, L. J. (1924) .. *Amer. J. Med. Sci.*, **168**, 654.

Jones, A. M., and Langley, F. A. (1946). *Brit. Heart J.*, **8**, 191.

Nicholson, R. E. (1943). *Ann. Intern. Med.*, **19**, 286.

Osler, W., and McCrae, T. (1927). *Modern Medicine*, **4**, 859. Henry Kimpton, London.

Raman, Y. K., and Menon, T. B. (1949). *Indian Heart J.*, **1**, 1.

Venning, G. R. (1951). *Amer. Heart J.*, **42**, 57.

Wauchope, G. M. (1928). *Quart. J. Med.*, **21**, 383.

SELECTED BIBLIOGRAPHY

Micks, R. H. (1940) .. *Brit. Heart J.*, **2**, 63.

White, P. D. (1941) .. *Ann. Intern. Med.*, **15**, 589.

DICHROA FEBRIFUGA AND A SYNTHETIC HYDRANGEA ALKALOID IN MALARIA

By R. N. CHAUDHURI
B. N. DUTTA
and
R. N. CHAKRAVARTY

From the Calcutta School of Tropical Medicine

Plants belonging to the genera Dichroa and Hydrangae have been in use for many centuries as herbal remedies for malarial fevers among the indigent population. *Dichora febrifuga,* popularly known as Chang Sang in China has been included in the Book of Herbs which was composed by Emperor Sheng Nung at about 300 B.C. (Work and Work, 1948). This is an evergreen shurb indigenous to India and South Western China. But only very recently serious attempts have been made to determine its active principle. A number of alkaloids have been isolated from Dichroa plant, the principal of which is known as febrifugina. (Henderson *et al,* 1949; Chou *et al,* 1947, 1948; Koepfli *et al,* 1947, 1949; Kuehl *et al,* 1948, Jang *et al,* 1946, 1948). The leaves of the Hydrangea plants were found to contain the same alkaloid, febrifugine, which is present in *Dichroa febrifuga.* Chemical structure of this alkaloid was established by further degradation and synthetic studies to be a quinazolone derivative, 3- -keto- (3-hydroxy 2-piperidyl) propyl-4-quinazolone. Antimala-