

ORIGINAL ARTICLE

# Nogo-A is a Reliable Oligodendroglial Marker in Adult Human and Mouse CNS and in Demyelinated Lesions

Tanja Kuhlmann, MD, Leah Remington, Brigitte Maruschak, Trevor Owens, PhD,  
and Wolfgang Brück, MD

## Abstract

The unambiguous identification of oligodendrocytes in tissue sections, especially in myelinated tracts, is often difficult. Most of the antibodies used to identify oligodendrocytes label the myelin sheath as well. Originally described as an inhibitor of axonal outgrowth, Nogo-A is known to be strongly expressed in mature oligodendrocytes *in vivo*. In the present investigation we analyzed the expression patterns of Nogo-A in adult mouse and human CNS as well as in demyelinating animal models and multiple sclerosis lesions. Nogo-A expression was compared with that of other frequently used oligodendroglial markers such as CC1, CNP, and *in situ* hybridization for proteolipid protein mRNA. Nogo-A strongly and reliably labeled oligodendrocytes in the adult CNS as well as in demyelinating lesions and thus represents a valuable tool for the identification of oligodendrocytes in human and mouse CNS tissue.

**Key Words:** Cuprizone-induced demyelination, Experimental autoimmune-mediated encephalomyelitis, Multiple sclerosis, Nogo-A, Oligodendrocytes.

## INTRODUCTION

The unambiguous identification of oligodendrocytes in tissue sections, especially in myelinated tracts, is often a challenge. Most oligodendrocyte markers used for labeling of oligodendrocytes in human and mouse formalin-fixed and paraffin-embedded tissues recognize oligodendrocytes as well as myelin. The present “gold standard” for the identification of oligodendrocytes is proteolipid protein (PLP) or myelin basic protein (MBP) mRNA *in situ* hybridization (1, 2), a time-consuming and expensive

technique (3). Antibodies such as MBP, myelin oligodendrocyte glycoprotein (MOG) and myelin-associated glycoprotein (MAG) reliably label myelin sheaths, but less frequently the cytoplasm of oligodendrocytes. CNP is a reliable marker of oligodendrocytes in demyelinated lesions (4, 5); however, in myelinated tracts the CNP-positive oligodendrocytes often cannot be distinguished from intensely stained myelinated fibers. The identification of additional immunohistochemical markers that selectively stain the oligodendrocytic cytoplasm but not the myelin sheath is desirable. Therefore, we performed a detailed immunohistochemical study to analyze whether Nogo-A, which is expressed strongly in the oligodendrocyte cell body but only weakly in neurons and some myelin fibers, might be such a marker.

Nogo-A and its splice variants Nogo-B and -C belong to the reticulon family. They have a common carboxy terminus of 188 amino acids and share 172 amino acids at the N terminus. Nogo-A is expressed in oligodendrocytes, in the inner and outer loops of myelin sheaths, and in some neuronal populations such as dorsal root ganglion cells, retinal ganglion cells, and ventral horn neurons in spinal cord (6–8). Nogo-A was originally identified because of its ability to prevent axonal regrowth and sprouting (9–11). Treatment with antibodies recognizing the N-terminal epitope of Nogo-A (IN-1) resulted in improved regenerative fiber outgrowth in rats with spinal cord trauma (9, 12). Nogo-66, the extracellular domain shared by all Nogo splice variants, signals via its receptor, the Nogo receptor, which is localized on axons, some neurons, and astrocytes (13, 14). Nogo-66 binds to the Nogo receptor and its coreceptor p75<sup>NTR</sup>, thus controlling the effects of external stimuli on growth cones (15). However, Nogo-A knockout mice do not show any distinctive morphologic CNS defects or obvious neurologic symptoms, indicating that Nogo-A is not essential for development and maintenance of axons, neurons, or oligodendrocytes during development and in the adult CNS (16–18).

During recent years, it became apparent that Nogo-A and its splice variants might have other functions in addition to controlling axonal regrowth after injury. Nogo-B, for example, is highly expressed in vascular smooth muscle and endothelial cells, where it seems to prevent smooth muscle cell migration (19, 20). Nogo-B was also found in cancer cell lines (21, 22) as well as in interactions with antiapoptotic proteins such as bcl-2 and bcl-xL (23). However, other

From the Department of Neuropathology (TK, BM, WB), University of Göttingen, Göttingen, Germany; the Neuroimmunology Unit (LR), Montreal Neurological Institute, McGill University, Montreal, Quebec, Canada; the Medical Biotechnology Center (TO), University of Southern Denmark, Odense, Denmark; and the Institut für Multiple-Sklerose-Forschung (WB), Bereich Humanmedizin der Georg-August-Universität und Gemeinnützige Hertie-Stiftung, Göttingen, Germany.

Send correspondence and reprint requests to: Tanja Kuhlmann, MD, Department of Neuropathology, University of Göttingen, Robert-Koch-Strasse 40, 37075 Göttingen, Germany; E-mail: tanjakuhlmann@gmx.de  
This work was supported by a research program from the Faculty of Medicine, Georg-August-University Göttingen and the 6th Framework of the European Union, NeuroproMiSe (LSHM-CT-2005-018637).

studies could not demonstrate a change in spontaneous or staurosporine-triggered apoptosis in tumor cell lines over-expressing Nogo-B (22).

In this study, we compare the expression patterns of Nogo-A in adult mouse and human CNS with other frequently used oligodendroglial makers such as PLP mRNA and CC1 (24). We show that Nogo-A reliably labels mature oligodendrocytes in mouse paraffin-embedded CNS tissues. No cross-reaction with other glial cells such as microglial cells, astrocytes, or NG-2-positive cells was observed. Furthermore, Nogo-A also reliably identifies oligodendrocytes in 2 demyelinating animal models, the toxic cuprizone model and experimental autoimmune-mediated encephalomyelitis (EAE). In human myelinated and demyelinated CNS tissues, immunohistochemistry for Nogo-A results in a reliable identification of oligodendrocytes.

## MATERIALS AND METHODS

### Animal Models

#### Experimental Autoimmune Encephalomyelitis

All animal procedures were carried out in accordance with the guidelines set forth by the Canadian Council for Animal Care as approved by the McGill University animal care committee. Female C57BL/6 mice (6–8 weeks old, n = 4) (The Jackson Laboratories, Bar Harbor, ME) were immunized on each side at the base of the tail with a subcutaneous injection of 100 µg of MOG peptide 35–55 (Sheldon Biotechnology Centre, Montreal, QC, Canada) emulsified in complete Freund's adjuvant (Fisher, Montreal, QC, Canada) containing 500 µg of heat-killed *Mycobacterium tuberculosis* (H37RA; Difco, Detroit, MI). Mice received intraperitoneal injections of 300 ng of pertussis toxin (Sigma, Oakville, ON, Canada) in Hanks' buffered saline solution (Invitrogen, Burlington, ON, Canada) on the day of the immunization and also 2 days later. Mice were assessed daily for symptoms and weighed. The grading scheme was as follows: Score 1 (partial floppy tail), Score 2 (floppy tail), Score 3 (floppy tail and slow to right), Score 4 (partial hindlimb paralysis), Score 5 (complete hindlimb paralysis), and Score 6 (moribund or dead).

#### Cuprizone-Induced Demyelination

Male C57BL6/129 mice (7–8 weeks old) were fed with 0.3% cuprizone (Sigma, Seelze, Germany) mixed into powdered food for up to 42 days. Mice were killed at Day 21

(n = 8) or Day 42 (n = 9) after onset of a cuprizone diet, as were untreated control mice (n = 6) of the same age.

### Human Tissue

Four-micrometer-thick paraffin-embedded tissue sections from temporal or occipital lobes of 6 patients who underwent temporal or occipital lobe surgery because of pharmacoresistant seizures (Table 1) as well as 1 multiple sclerosis (MS) lesion were analyzed for the expression of Nogo-A, MBP, MAG, CNP, and/or PLP mRNA.

### Immunohistochemistry

Immunohistochemical staining of human and mouse tissue was performed with an avidin-biotin technique. Brain, spinal cord, spleen, and liver from 4 EAE mice and 5 nonimmunized control mice and the brains of cuprizone-treated mice were embedded in paraffin. Cervical, thoracic, and higher lumbar spinal cord was cut in 8 to 11 3-mm-thick transverse segments before embedding. Frozen sections of either perfusion-fixed (4% paraformaldehyde [PFA]) or fresh-frozen (no perfusion with 4% PFA) CNS tissue sections from control mice were post-treated with 0.1% PFA, acetone, ethanol, ethanol and acetic acid, or methanol, or given no post-treatment.

Paraffin-embedded tissue sections were deparaffinized, and intrinsic peroxidase activity was blocked by incubation with 5% H<sub>2</sub>O<sub>2</sub> in PBS for 20 minutes. Nonspecific antibody binding was inhibited with 10% fetal calf serum in PBS for 25 minutes. The primary antibodies were mouse anti-CC1 (Calbiochem, Darmstadt, Germany), rabbit anti-Nogo A (Chemicon, Hampshire, UK), mouse anti-Nogo-A (11C7) (a generous gift from M. E. Schwab (Brain Research Institute, University of Zurich and Department of Biology, Swiss Federal Institute of Technology, Zurich, Switzerland), anti-2',3'-cyclic nucleotide 3'-phosphodiesterase (anti-CNPase) (Sternberger Monoclonals, Lutherville, MD), anti-myelin basic protein (anti-MBP) (Dako, Glostrup, Denmark), anti-MAG (a generous gift from C. Richter-Landsberg, University of Oldenburg, Oldenburg, Germany), anti-MOG (8-18C5), (a generous gift from C. Linnington, University of Aberdeen, Aberdeen, UK), anti-NG2 (Chemicon), anti-MAC-3 (similar or identical to CD107b (25) (PharMingen, San Diego, CA), and anti-glial fibrillary acidic protein (GFAP) (Dako). For dilution of antibodies and pretreatments, see Table 2.

### In Situ Hybridization

Nonradioactive in situ hybridization (ISH) for PLP mRNA was performed as described in detail previously (1)

**TABLE 1.** Age, Sex, and Clinical Information for Temporal Lobe Surgery Patients

Patient	Age (years)	Sex	Clinical Findings	Neuropathologic Findings
1	30	M	Epilepsy since the age 3	Reactive gliosis in white matter and cortex
2	39	F	Chronic epilepsy	No pathologic changes
3	28	F	Epilepsy with occipital focus	No pathologic changes
4	43	F	Pharmacoresistant epilepsy	No pathologic changes
5	64	M	Pharmacoresistant epilepsy	Focal Ammon's horn sclerosis
6	41	M	Pharmacoresistant epilepsy	Venous angioma

**TABLE 2.** Source, Dilution, and Pretreatment of Antibodies

Antibody	Source	Pretreatment	Dilution
mc mouse anti-CC1	Calbiochem	Microwave, 10 mmol/L Tris/1 mmol/L EDTA, pH 9, 5 × 3 min	1:20
mc mouse anti-CNP	Sternberger Monoclonals	Microwave, 10 mmol/L citrate buffer, pH 6, 5 × 3 min	1:200
pc rabbit anti-GFAP	Dako	No pretreatment	1:1000
mc rat-anti-MAC-3	PharMingen	Microwave, 10 mmol/L citrate buffer, pH 6, 5 × 3 min	1:2000
pc rabbit anti-MAG	Gift from C. Richter-Landsberg	No pretreatment	1:1000
pc rabbit anti-MBP	Dako	No pretreatment	1:2000
mc mouse anti-MOG (8-18C5)	Hybridoma (gift from C. Linnington)	Microwave, 10 mmol/L citrate buffer, pH 6, 5 × 3 min	1:20
mc mouse anti-Nogo-A (11C7)	Gift from M. E. Schwab	Microwave, 10 mmol/L citrate buffer, pH 6, 5 × 3 min	1:15,000 (1:20,000)
pc rabbit anti-Nogo-A	Chemicon	Microwave, 10 mmol/L citrate buffer, pH 6, 5 × 3 min	1:750
pc rabbit anti-NG2	Chemicon	Microwave, 10 mmol/L Tris/1 mmol/L EDTA, pH 9, 5 × 3 min	1:200
mc mouse anti-PLP	Biozol	Microwave, 10 mmol/L citrate buffer, pH 6, 5 × 3 min	1:500

mc, monoclonal; pc, polyclonal.

with an automated immunostainer (Discovery; Ventana Medical Systems, Tucson, AZ). Hybridization was performed using digoxigenin-labeled riboprobes (Roche, Mannheim, Germany) detected by alkaline phosphatase-conjugated anti-digoxigenin Fab fragments (Roche). NBT/BCIP (Roche, Mannheim, Germany) was used as a chromogen. For double staining after ISH, sections were incubated with anti-PLP antibody (Biozol, Eching, Germany) and processed as described above.

### Morphometric Analysis

To determine the numbers of CC1-, Nogo-A-, and PLP mRNA-positive cells in the corpus callosum of healthy mice ( $n = 5$ ) and mice treated with 0.3% cuprizone, the number of labeled cells was counted in 10 high-power fields located in the middle of the corpus callosum on coronal sections at the level of the anterior commissure. To quantify the numbers of labeled cells in the spinal cord of healthy control mice, 1 transversal spinal cord segment of each spinal cord level (cervical, thoracic, and lumbar level) was selected in each mouse, and the number of labeled cells was determined in the dorsal funiculus. Consecutive sections were stained and the same transversal spinal cord segments were analyzed for the different immunohistochemical stainings.

To quantify the demyelinated area in EAE mice, all transverse spinal cord cross-sections were analyzed in each animal ( $n = 4$ ). The demyelinated area was measured in sections stained for Luxol fast blue (LFB)/periodic acid-Schiff (PAS) and expressed as percentage of total white matter. For statistical analysis, the mean per animal was calculated. The number of perivascular infiltrates was counted in all transverse spinal cord cross-sections, and the mean per animal was determined. To quantify the numbers of CC1-, Nogo-A (monoclonal)-, and PLP mRNA-positive cells in EAE lesions, the numbers of

labeled cells within the lesion areas of 2 or 3 transverse spinal cord segments per mouse were counted. In all mice, the same transverse spinal cord segments were analyzed. Consecutive sections were stained with antibodies directed against Nogo-A and CC1 and also were used for ISH with a PLP mRNA probe.

### Statistical Analysis

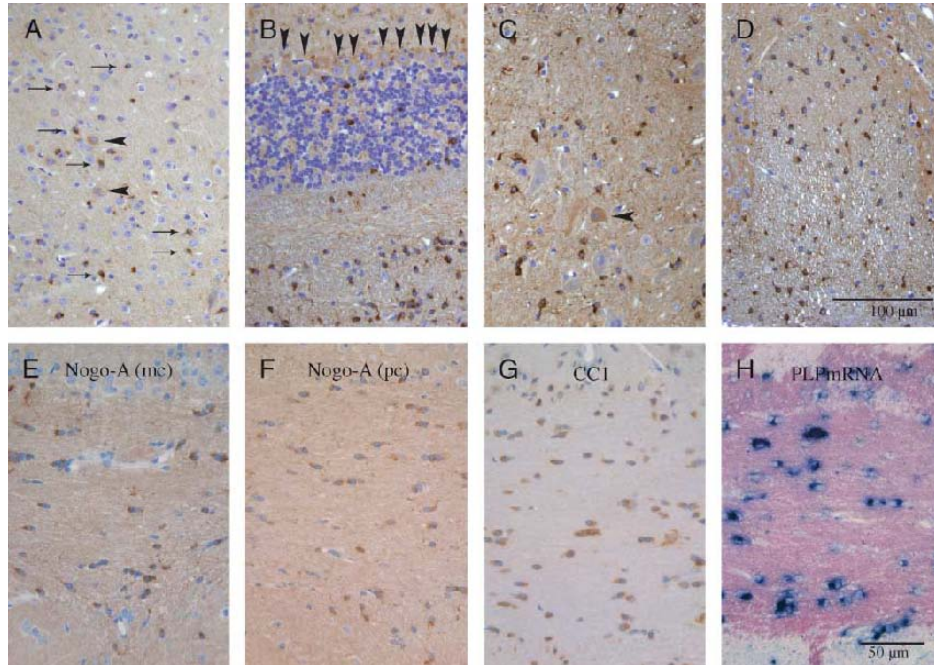
Statistical analysis was performed by using Prism Software (GraphPad) or the InStat statistics program. To analyze the numbers of Nogo-A-, CC1-, and PLP mRNA-positive cells, an unpaired Student *t*-test was used.

## RESULTS

### Expression of Nogo-A in Adult Mouse Central Nervous System

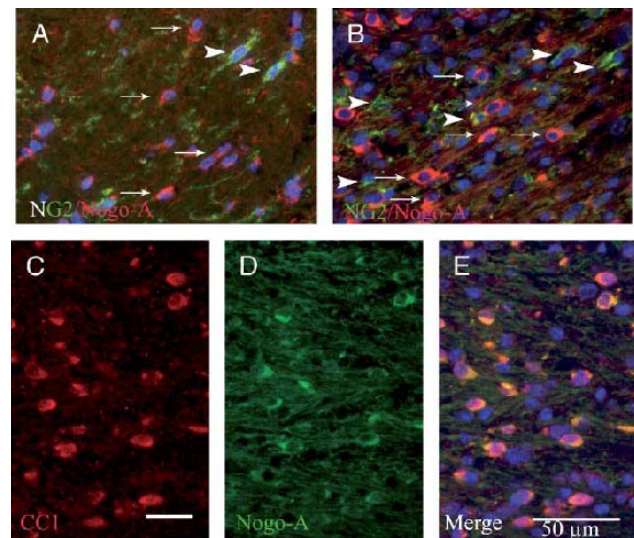
To analyze the specificity and sensitivity of the oligodendrocyte marker Nogo-A, we compared the expression pattern of Nogo-A (Fig. 1A–F) with the expression patterns of CC1 and PLP mRNA (Fig. 1G, H). We investigated 2 different Nogo-A antibodies, the commercially available polyclonal antibody (Chemicon) and the monoclonal antibody 11C7 (26), hereafter termed Nogo-A (pc) and Nogo-A (mc).

Both Nogo-A antibodies intensely stained the somata of oligodendrocytes in the white matter tracts of brain (Fig. 1E, F), cerebellum (Fig. 1B), and spinal cord (Fig. 1D), as well as oligodendrocytes in the cortex (Fig. 1A), basal ganglia, and grey matter of the spinal cord (Fig. 1C). Some oligodendrocytes possessed short Nogo-A-positive processes. Few myelin sheaths were labeled by both Nogo-A antibodies. A subpopulation of neurons, including some neurons in the cortex (Fig. 1A), hippocampus, spinal cord (Fig. 1C), brainstem, or cerebellum (Purkinje cells) (Fig. 1B), were labeled weakly by these 2 markers. The

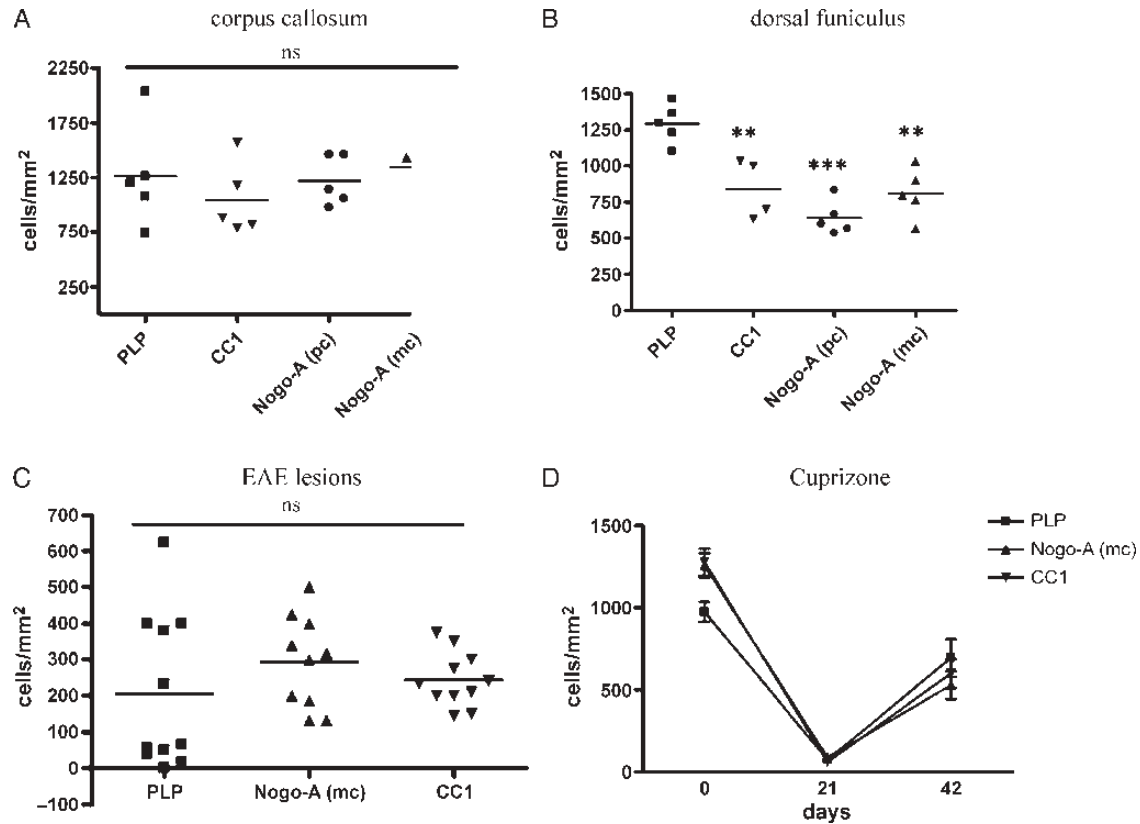


**FIGURE 1.** Expression pattern of Nogo-A in different CNS regions of the mouse and comparison with other oligodendroglial markers. **(A)** In the cortex, oligodendrocytes showed a strong immunohistochemical signal for Nogo-A (monoclonal [mc]) (arrows). Only a few neurons were weakly labeled (arrowhead). **(B)** In cerebellum, anti-Nogo-A (mc) identified numerous oligodendrocytes, and Purkinje cells were weakly labeled (arrowheads). **(C)** In the grey matter of the spinal cord, oligodendrocytes were strongly stained with anti-Nogo-A (mc), but only few  $\alpha$ -motoneurons showed a positive reaction. In the dorsal funiculus **(D)** and the corpus callosum **(E)**, numerous oligodendrocytes were identified by anti-Nogo-A (mc). Similar numbers of oligodendrocytes were detected by immunohistochemistry with anti-Nogo-A (polyclonal) **(F)**, anti-CC1 **(G)**, or proteolipid protein (PLP) mRNA in situ hybridization **(H)**.

strongest neuronal Nogo-A staining was observed in hypoglossal nuclei. The Nogo-A staining intensity of oligodendrocytes was clearly stronger than the Nogo-A signal of most neurons. Staining of frozen tissue sections (either derived from perfusion-fixed or fresh-frozen CNS specimens) revealed a similar staining pattern. Post-treatment with PFA, acetone, or ethanol or no post-treatment resulted in intense labeling of oligodendrocytes. In addition, post-treatment with acetone or 0.1% PFA or no post-treatment revealed stronger labeling of some neuronal subgroups, such as  $\alpha$ -motoneurons (no post-treatment, 0.1% PFA, or acetone) or Purkinje cells (acetone) compared with paraffin-embedded tissue sections. Double immunohistochemistry of Nogo-A with GFAP or NG2 revealed no double labeling of Nogo-A with astrocytes or NG2-positive cells (Fig. 2A). In contrast, all CC1-positive cells were also Nogo-A-positive (Fig. 2C–E). To determine the sensitivity of these different oligodendrocytic markers compared with that of other frequently used oligodendroglial markers such as CC1 or PLP mRNA, the number of oligodendrocytes labeled by these different markers was counted in the corpus callosum as well as in cervical, thoracic, and lumbar dorsal funiculus. Within the corpus callosum, the numbers of labeled oligodendrocytes did not differ significantly among these different oligodendroglial markers (Fig. 3A). In contrast, in the dorsal funiculus some differences were observed among the different markers (Table 3). In all spinal cord regions



**FIGURE 2.** Nogo-A does not colocalize with NG2 but with CC1. By double immunohistochemistry with anti-Nogo-A (monoclonal [mc]) (red, arrows) and anti-NG2 (green, arrowheads) no colocalization of Nogo-A and NG2 was observed either in normal CNS **(A)** or in the corpus callosum of mice treated for 42 days with cuprizone **(B)**. In contrast, all CC1-positive cells (red) were also Nogo-A (mc)-positive (green) **(C–E)**.



**FIGURE 3.** Quantification of oligodendrocytes in different CNS regions and in different demyelinating models by different oligodendroglial markers. In the corpus callosum, similar numbers of oligodendrocytes were identified by proteolipid protein (PLP) mRNA in situ hybridization (ISH) or immunohistochemistry with antibodies directed against CC1 or Nogo-A (A). In the thoracic dorsal funiculus significantly more oligodendrocytes were recognized by PLP mRNA ISH than by CC1 or Nogo-A immunohistochemistry (PLP mRNA ISH: 1,293 ± 62; CC1: 842 ± 102, p = 0.006; Nogo-A (polyclonal): 640 ± 53, p < 0.0001; Nogo-A (11C7): 813 ± 77, p = 0.0013) (B). Similar numbers of oligodendrocytes were labeled by the different oligodendroglial markers in EAE lesions (PLP mRNA: 206 ± 64 cells/mm<sup>2</sup>, CC1: 244 ± 23 cells/mm<sup>2</sup>, Nogo-A (monoclonal): 293 ± 40 cells/mm<sup>2</sup>) (C) and at different time points during the cuprizone diet (D).

analyzed, PLP ISH detected more oligodendrocytes than immunohistochemistry with antibodies directed against Nogo-A or CC1. For most regions this difference was significant (Fig. 3B; Table 3).

### Expression of Nogo-A in Demyelinating Murine Animal Models

To further analyze the specificity and sensitivity of Nogo-A in the diseased CNS, we compared PLP mRNA

expression patterns with Nogo-A and CC1 immunohistochemistry in MOG-EAE and cuprizone-induced demyelination, 2 demyelinating animal models affecting spinal cord or brain, respectively. Because we did not observe any significant differences in the staining patterns between the mono- and polyclonal Nogo-A antibodies, we used the monoclonal Nogo-A antibody 11C7 for the subsequent experiments. PLP mRNA ISH and immunohistochemical stainings were performed on consecutive sections.

### Experimental Autoimmune-Mediated Encephalomyelitis

The first clinical symptoms were observed at Day 14 (n = 2) or Day 16 (n = 2) after immunization with MOG. One mouse had to be killed at Day 19 because of severe clinical symptoms; the other mice had maximal disease scores and were killed at Day 30 after immunization with a disease score of 5 (n = 2) or 1 (n = 1). All 4 mice were analyzed histologically. The extent of demyelination was determined by measuring the area of white matter with loss in LFB-PAS staining. Between 7.2% and 22.5% of the white matter in the different animals showed a lack of LFB

**TABLE 3.** Numbers of PLP mRNA-, CC1-, Nogo-A (pc)- and Nogo-A (mc)-Positive Cells in the Dorsal Funiculus of Different Spinal Cord Levels

	PLP mRNA	CC1	Nogo-A (pc)	Nogo-A (mc)
Cervical	1,007 ± 98	745 ± 62†	733 ± 68†	740 ± 65†
Thoracic	1,293 ± 62	842 ± 102**	640 ± 53***	813 ± 77**
Lumbar	1,245 ± 71	950 ± 65*	656 ± 44**	907 ± 81*

All values are compared with numbers of PLP mRNA-positive cells.  
 PLP, proteolipid protein; pc, polyclonal; mc, monoclonal.  
 \*, p < 0.05; \*\*, p < 0.001; \*\*\*, p < 0.0001; †, not significant.

staining (mean ± standard error of the mean: 13.8 ± 3.3%). The distribution of the Nogo-A staining in brain was similar to that in nonimmunized animals (see above). In the spinal cord, in addition to oligodendrocytes some α-motoneurons were strongly labeled by Nogo-A. Within the lesions, similar numbers of oligodendrocytes were recognized by all oligodendrocytic markers (PLP mRNA: 206 ± 64 cells/mm<sup>2</sup>; CC1: 244 ± 23 cells/mm<sup>2</sup>; and Nogo-A (mc): 293 ± 40 cells/mm<sup>2</sup>), the differences between the different oligodendrocytic markers were not significant (Fig. 3C). To exclude the possibility that Nogo-A also stained astrocytes or macrophages/microglia in autoimmune-induced demyelination, we performed double immunohistochemistry, which demonstrated no colocalization of Nogo-A with macrophages/microglia or astrocytes (Fig. 4A, B).

### Cuprizone Model

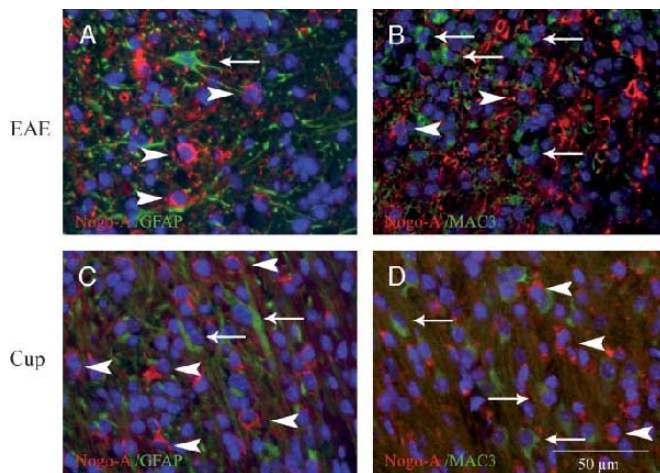
Feeding of 0.3% cuprizone led selectively to the death of mature oligodendrocytes in the brain, especially in the corpus callosum. The loss of oligodendrocytes was accompanied by increased numbers of macrophage/microglial cells and astrocytic gliosis. At Day 42 the medial parts of the corpus callosum were almost completely demyelinated in the majority of mice analyzed. The maximal loss of oligodendrocytes was reached approximately 21 days after onset of a cuprizone diet; after that, we observed that the number of mature oligodendrocytes again increased (Fig. 3D), a finding that has also been reported by others

(27). Similar numbers of oligodendrocytes were labeled by the different oligodendrocyte markers at Day 0 (PLP mRNA: 975 ± 59 cells/mm<sup>2</sup>; Nogo-A (mc): 1,257 ± 75 cells/mm<sup>2</sup>; and CC1: 1,277 ± 84 cells/mm<sup>2</sup>), Day 21 (PLP mRNA: 76 ± 25 cells/mm<sup>2</sup>; Nogo-A (mc): 90 ± 26 cells/mm<sup>2</sup>; and CC1: 62 ± 21 cells/mm<sup>2</sup>), and Day 42 (PLP mRNA: 656 ± 138; Nogo-A (mc): 529 ± 84 cells/mm<sup>2</sup>; and CC1: 600 ± 87 cells/mm<sup>2</sup>) (Fig. 3D). As in EAE lesions, no colocalization of Nogo-A with astrocytes or macrophages/microglial cells (Fig. 4C, D) or NG2-positive cells (Fig. 2B) was found.

### Expression of Nogo-A in Human Central Nervous System

To investigate whether Nogo-A immunohistochemistry sufficiently identifies oligodendrocytes in human paraffin-embedded tissues, we stained white matter and cortex tissue specimens from temporal or occipital lobes of 6 patients who had undergone epilepsy surgery as well as specimens from the lesion of 1 patient with MS. Different myelin markers such as CNP, MAG, MBP, and PLP mRNA were used to compare the results with Nogo-A immunohistochemistry (Fig. 5).

The selected epilepsy cases showed no pathology except for some reactive astrocytes and activated microglia (Table 1). Nogo-A immunohistochemistry detected numerous oligodendrocytes within the white matter (Fig. 5A). No demyelination was seen with CNP, MBP, and MAG staining (Fig. 5B–D). Identification of single oligodendrocytes was not possible in any of these stainings. In 3 of 6 epilepsy cases, strongly labeled oligodendrocytes were found by ISH with a PLP mRNA probe (Fig. 5E). The other 3 cases showed patchy staining patterns as well as tissue areas that were completely negative. The MS lesion was characterized by loss of myelin, perivascular and diffuse T cell infiltration, numerous macrophages, and reactive astrocytes. Some lesion areas showed thin, irregularly formed myelin sheaths indicating remyelination. The monoclonal Nogo-A antibody identified numerous oligodendrocytes within the lesions as well as in the periplaque white matter as shown in Figure 5F. In contrast, only few CNP or PLP mRNA-positive oligodendrocytes were detected within the lesion (Fig. 5G, J), and no MBP- or MAG-positive oligodendrocytes were found (Fig. 5H, I).



**FIGURE 4.** Nogo-A does not colocalize with glial fibrillary acidic protein (GFAP) or MAC3 in demyelinating lesions in animal models. In experimental autoimmune-mediated encephalomyelitis (EAE) lesions, no colocalization of GFAP (green, arrows) and Nogo-A (monoclonal [mc]) (red, arrowheads) was observed (**A**). Double immunohistochemistry with antibodies directed against the macrophage/microglial marker MAC3 (green, arrows) and Nogo-A (mc) (red, arrowheads) revealed that different cell populations were labeled by these 2 markers (**B**). Similar staining patterns were observed in the corpus callosum in mice receiving a cuprizone diet for 42 days. No colocalization was observed with Nogo-A (mc) (red, arrowheads) and the astrocytic marker GFAP (green, arrows) (**C**) or the macrophage marker MAC3 (green, arrows) (**D**).

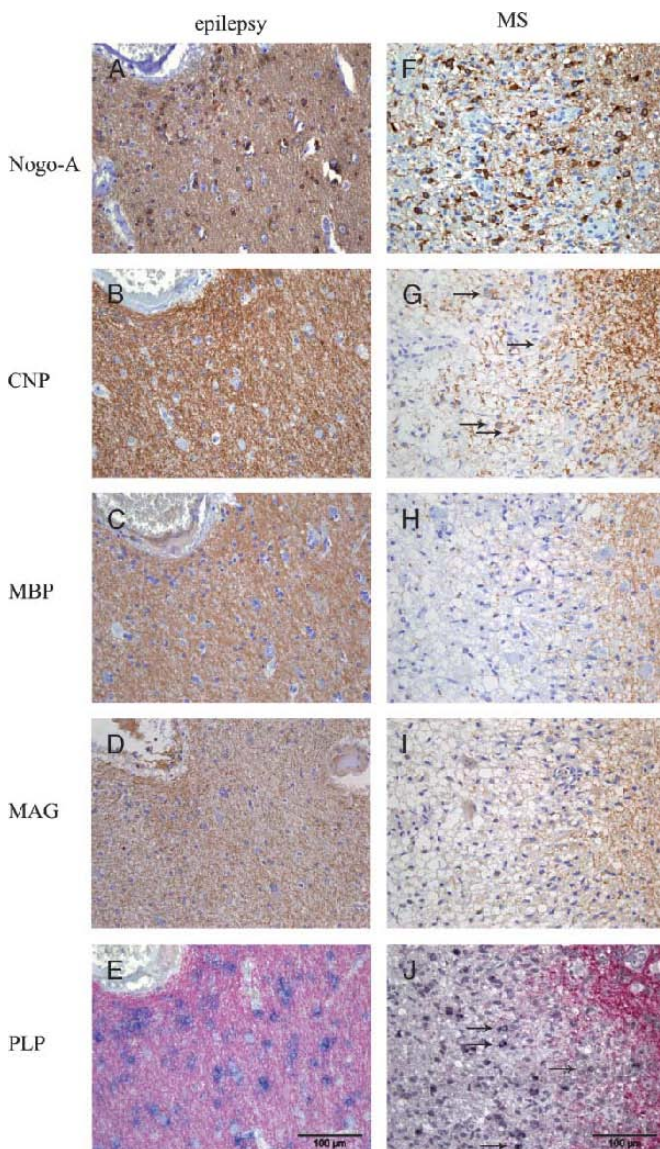
### DISCUSSION

The present study demonstrates that Nogo-A is a reliable marker of oligodendrocytes in paraffin-embedded tissues of mouse and human CNS. Nogo-A is expressed in oligodendrocytes in the white matter tracts of brain, cerebellum, and spinal cord as well as in oligodendrocytes within the cortex, basal ganglia, and grey matter of spinal cord. Furthermore, Nogo-A reliably labels oligodendrocytes in different demyelinating animal models and in human demyelinating diseases such as multiple sclerosis. Because of its strong staining of the oligodendroglial cytoplasm but only weak staining of myelin sheaths, Nogo-A represents a valuable tool for the identification of human and mouse oligodendrocytes in paraffin-embedded tissues.

Nogo-A expression has been described in the CNS and, at lower levels, in testis and heart in adult rats (7). Within the CNS of adult rats Nogo-A was reported to be strongly expressed in the cytoplasm of oligodendrocytes, a subpopulation of neurons, and the myelin in fresh-frozen tissue sections (7). In paraffin-embedded tissue sections, we observed the strongest Nogo-A expression within the cytoplasm of oligodendrocytes and only weak or no labeling in the majority of neurons. By using fresh-frozen or perfusion-fixed frozen CNS tissue sections post-treated with either 0.1% PFA and acetone or receiving no post-treatment, we detected also a stronger Nogo-A signal in some subpopulations of neurons similar to the results described by Huber et al (7). However, neither in paraffin-embedded sections nor in frozen sections did we find intense labeling of the myelin sheaths. Instead, we saw a strong labeling of some oligodendroglial processes, especially in remyelinating MS lesions as well as a light and diffuse staining of the

myelinated tracts. This difference might be explained by the different antibodies used in these 2 studies. Although we observed similar numbers of Nogo-A, CC1, and PLP mRNA-positive oligodendrocytes in the corpus callosum of nondiseased mice, significantly fewer Nogo-A or CC1-positive oligodendrocytes were found in the dorsal funiculus in spinal cord. This difference is most likely not due to methodologic problems. The stainings were performed on consecutive sections, and care was taken to always analyze the same tissue areas. In addition, this difference in the numbers of CC1, Nogo-A, and PLP mRNA-positive cells was obvious in different regions in the cervical, thoracic, and lumbar spinal cord. These results indicate that PLP mRNA ISH is more sensitive for the detection of oligodendrocytes in spinal cord than immunohistochemistry for Nogo-A or CC1.

Only limited data are available on the expression of Nogo-A in demyelinating animal models such as EAE or cuprizone-induced demyelination. Immunization with Nogo-66, the extracellular domain shared by Nogo-A, -B and -C, induced neurologic symptoms and histologic characteristics similar to those seen in EAE (28). Mice vaccinated with Nogo-A (623–640) or treated with a neutralizing antibody against Nogo and immunized with MOG peptide showed improved clinical symptoms, reduced numbers of inflammatory infiltrates, and less tissue damage (29). In the present study we have shown that Nogo-A is expressed in a pattern in mice immunized with MOG peptide similar to that in nonimmunized animals. Oligodendrocytes in apparently unaffected white matter as well as in inflammatory lesions showed a strong Nogo-A signal. Neurons in the brain of EAE mice presented with the same staining patterns as that in nonimmunized mice. In addition, some  $\alpha$ -motoneurons in the spinal cord of EAE mice displayed more intense Nogo-A



**FIGURE 5.** Nogo-A reliably labels Nogo-A-positive oligodendrocytes in human CNS tissues and multiple sclerosis (MS) lesions. **(A–E)** Images were taken from the same temporal lobe biopsy of a patient who underwent epilepsy surgery. **(A)** Numerous oligodendrocytes were easily identified by immunohistochemistry with anti-Nogo-A antibody (mc). **(B–D)** The myelinated fibers showed no sign of demyelination as demonstrated by immunohistochemistry for 2,3-cyclic nucleotide 3-phosphodiesterase (CNPase), myelin basic protein (MBP), and myelin-associated glycoprotein (MAG). Note that oligodendrocytes were not labeled more intensely than myelin sheaths (immunohistochemistry for CNPase, MBP, and MAG, brown). **(E)** Proteolipid protein (PLP) mRNA in situ hybridization (ISH) identified some of the oligodendrocytes, but the staining signal was diffuse (PLP mRNA ISH [black] combined with PLP immunohistochemistry [red]). **(F–J)** Images were taken from the same MS lesion. **(F)** Numerous oligodendrocytes in the lesion and the periplaque white matter were labeled by anti-Nogo-A (monoclonal) (brown). **(G)** Only single CNPase-positive oligodendrocytes were identified (brown, arrows). **(H, I)** Immunohistochemistry with antibodies against MBP and MAG led to an intensive staining of the periplaque white matter, but no oligodendrocytes could be identified. **(J)** ISH with a PLP mRNA probe detected only single oligodendrocytes (black, arrows).

staining compared with nonimmunized animals. The significance of this observation is not clear, but it may be speculated that the upregulation of Nogo-A in  $\alpha$ -motoneurons is a reaction to inflammatory changes and axonal damage in EAE lesions. In EAE lesions, similar numbers of cells were labeled by the different oligodendroglial markers. However, slightly fewer oligodendrocytes were identified by PLP mRNA ISH compared with Nogo-A (mc)-positive cells. This finding is in contrast to the higher numbers of PLP mRNA-positive cells observed in the spinal cord of untreated control mice. These results may indicate that mRNA levels of myelin proteins react more sensitively to autoimmune-induced demyelination than the proteins, as has been observed in early stages of cuprizone-induced demyelination (30).

Feeding of cuprizone for 4 to 5 weeks leads to oligodendroglial cell death and extensive demyelination in the corpus callosum, with the lowest numbers of mature oligodendrocytes at about Day 28 (27). By 6 weeks, approximately 50% of axons are remyelinated despite ongoing cuprizone diet. This remyelination is accompanied by increasing numbers of oligodendroglial precursors as well as mature oligodendrocytes (27). We identified similar numbers of oligodendrocytes with the 3 oligodendroglial markers at all time points. As expected and in line with the earlier studies mentioned above (27, 30), the lowest numbers of oligodendrocytes were observed at Day 21. Similar numbers of Nogo-A, CC1, and PLP mRNA-positive oligodendrocytes were found at Day 42, suggesting that there is no major temporal difference in the re-expression of these myelin genes during remyelination. This finding is in agreement with earlier studies demonstrating similar time courses for different myelin genes during remyelination in the cuprizone model (30, 31). Together, these results demonstrate that Nogo-A is a specific and reliable oligodendroglial marker in the de- and remyelinating phase of the cuprizone model.

In human paraffin-embedded tissues, the identification of oligodendrocytes, especially in myelinated tracts, is challenging. The most frequently used immunohistochemical markers, such as CNP or MOG, also stain the myelin sheath, often making unambiguous identification of oligodendrocytes difficult. Markers that reliably label the oligodendrocytic cytoplasm but not the myelin in mouse tissues, such as CC1, do not cross-react with human antigens. ISH for PLP or MBP mRNA is an expensive and time-consuming procedure and requires RNase-free handling of samples that is not feasible in routine neuropathology work. To analyze whether Nogo-A represents a suitable oligodendroglial marker for human biopsy tissues, we compared the staining patterns of different myelin/oligodendrocyte markers such as MBP, MAG, CNP, and PLP mRNA ISH with Nogo-A immunohistochemistry in CNS tissues from patients who underwent epilepsy surgery and in 1 MS lesion. As described in previous studies, immunohistochemistry with Nogo-A resulted in intense labeling of the oligodendroglial cytoplasm and some oligodendroglial processes, whereas the myelin showed only a weak staining signal (6). These results are partly in contrast to those of Satoh et al (32), who

reported a strong Nogo-A signal of oligodendrocytes in MS lesions, but a weak labeling of only a subpopulation of oligodendrocytes in normal appearing white matter. In our study, immunohistochemistry for Nogo-A identified the majority of oligodendrocytes in normal appearing as well as demyelinated CNS tissue. Furthermore, Nogo-A immunohistochemistry proved to be more robust and reliable than PLP mRNA ISH or any other immunohistochemical marker in the identification of oligodendrocytes in human biopsies.

In conclusion, Nogo-A is a valuable tool for identifying oligodendrocytes in adult human and mouse CNS as well as in demyelinated lesions.

## ACKNOWLEDGMENTS

*We are grateful to Dr. M. E. Schwab (Brain Research Institute, University of Zurich and Department of Biology, Swiss Federal Institute of Technology Zurich, Switzerland) for kindly providing the Nogo-A antibody 11C7. The authors thank Lyne Bourbonniere (Montreal Neurological Institute, McGill University) for help with the EAE experiments and excellent technical support.*

## REFERENCES

- Breitschopf H, Suchanek G, Gould RM, Colman DR, Lassmann H. In situ hybridization with digoxigenin-labeled probes: Sensitive and reliable detection method applied to myelinating rat brain. *Acta Neuropathol* 1992;84:581–87
- Woodruff RH, Franklin RJM. The expression of myelin basic protein exon 1 and exon 2 containing transcripts during myelination of the rat spinal cord: An in situ hybridization study. *J Neurocytol* 1998;27:683–93
- Weidenheim KM, Bodhireddy SR, Rashbaum WK, Lyman WD. Temporal and spatial expression of major myelin proteins in the human fetal spinal cord during the second trimester. *J Neuropathol Exp Neurol* 1996;55:734–45
- Stadelmann C, Ludwin S, Tabira T, et al. Tissue preconditioning may explain concentric lesions in Balo's type of multiple sclerosis. *Brain* 2005;128:979–87
- Lucchinetti C, Brück W, Parisi J, et al. Heterogeneity of multiple sclerosis lesions: Implications for the pathogenesis of demyelination. *Ann Neurol* 2000;47:707–17
- Buss A, Sellhaus B, Wolmsley J, et al. Expression pattern of Nogo-A protein in the human nervous system. *Acta Neuropathol* 2005;110:113–19
- Huber AB, Weinmall O, Brösamle C, Oertle T, Schwab ME. Pattern of Nogo mRNA and protein expression in the developing and adult rat and after CNS lesions. *J Neurosci* 2002;22:3553–67
- Wang X, Chun S-J, Treloar H, et al. Localization of Nogo-A and Nogo-66 receptor proteins at sites of axon-myelin and synaptic contact. *J Neurosci* 2002;22:5505–15
- Chen M, Huber AB, van der Haar M, et al. Nogo-A is a myelin-associated neurite outgrowth inhibitor and an antigen for monoclonal antibody IN-1. *Nature* 2000;403:434–39
- GrandPre T, Nakamura F, Vartanian T, Strittmatter SM. Identification of the Nogo inhibitor of axon regeneration as a reticulon protein. *Nature* 2000;403:439–44
- Prinjha R, Moore S, Vinson M, et al. Inhibitor of neurite outgrowth in humans. *Nature* 2000;403:383–84
- Bregman B, Kunkel-Bagden E, Schnell L, et al. Recovery from spinal cord injury mediated by antibodies to neurite growth inhibitors. *Nature* 1995;378:498–501
- Fournier A, GrandPre T, Strittmatter SM. Identification of a receptor mediating Nogo-66 inhibition of axonal regeneration. *Nature* 2001;409:341–46
- Hunt D, Mason M, Campbell G, Coffin R, Anderson P. Nogo receptor



- mRNA expression in intact and regenerating neurons. *Mol Cell Neurosci* 2002;20:537–52
15. Dechant G, Barde Y. The neurotrophin receptor p75(NTR): Novel functions and implications for disease of the nervous system. *Nat Neurosci* 2002;5:1131–36
  16. Kim J, Li S, GrandPre T, Strittmater S. Axon regeneration in young adult mice lacking Nogo-A/B. *Neuron* 2003;38:153–56
  17. Simonen M, Pedersen V, Weinmann O, et al. Systemic depletion of the myelin-associated outgrowth inhibitor Nogo-A improves regenerative and plastic responses after spinal cord injury. *Neuron* 2003;38:201–11
  18. Zheng B, Ho C, Li S, et al. Lack of enhanced spinal regeneration in Nogo-deficient mice. *Neuron* 2003;38:153–56
  19. Acevedo L, Yu L, Erdjument-Bromage H, et al. A new role for Nogo as a regulator of vascular remodeling. *Nat Med* 2004;10:382–83
  20. Miao R, Gao Y, Harrison K, et al. Identification of a receptor necessary for Nogo-B stimulated chemotaxis and morphogenesis of endothelial cells. *Proc Natl Acad Sci U S A* 2006;103:10997–1002
  21. Li Q, Qi B, Oka K, et al. Link of a new type of apoptosis-inducing gene ASY/Nogo-B to human cancer. *Oncogene* 2001;20:3929–36
  22. Oertle T, Merkler D, Schwab ME. Do cancer cells die because of Nogo-B? *Oncogene* 2003;22:1390–99
  23. Tagami S, Eguchi Y, Kinoshita M, Takeda M, Tsujimoto Y. A novel protein, RTN-XS, interacts with both Bcl-XL and Bcl-2 on endoplasmic reticulum and reduces their anti-apoptotic activity. *Oncogene* 2000;19:5736–46
  24. Bhat R, Axt K, Fosnaugh J, et al. Expression of the APC tumor suppressor protein in oligodendroglia. *Glia* 1996;17:169–74
  25. Chen J, Murphy M, Willingham M, Pastan I, August J. Identification of two lysosomal membrane glycoproteins. *J Cell Biol* 1985;101:85–95
  26. Oertle T, van der Haar ME, Brandtlow C, et al. Nogo-A inhibits neurite outgrowth and cell spreading with three discrete regions. *J Neurosci* 2003;23:5393–406
  27. Matsushima GK, Morell P. The neurotoxicant, cuprizone, as a model to study demyelination and remyelination in the central nervous system. *Brain Pathol* 2001;11:107–16
  28. Fontoura P, Ho P, De Voss J, et al. Immunity to the extracellular domain of Nogo-A modulates experimental autoimmune encephalomyelitis. *J Immunol* 2004;173:6981–92
  29. Karnezis T, Mandemakers W, McQualter JL, et al. The neurite outgrowth inhibitor Nogo A is involved in autoimmune-mediated demyelination. *Nat Neurosci* 2004;7:736–44
  30. Morell P, Barrett CV, Mason JL, et al. Gene expression in brain during cuprizone-induced demyelination and remyelination. *Mol Cell Neurosci* 1998;12:220–27
  31. Jurevics H, Largent C, Hostettler J, et al. Alterations in metabolism and gene expression in brain regions during cuprizone-induced demyelination and remyelination. *J Neurochem* 2002;82:126–36
  32. Satoh J-I, Onue H, Arima K, Yamamura T. Nogo-A and Nogo receptor expression in demyelinating lesions of multiple sclerosis. *J Neuropathol Exp Neurol* 2005;64:129–38