

# Primary omental pregnancy

Recep Yildizhan, MD, Mertihan Kurdoglu, MD, Ali Kulusari, MD, Remzi Erten, MD.

## ABSTRACT

يعتبر الحمل التربي حالة نادرة من الحمل المنتبذ ويمكن رؤيته أولياً أو ثانوياً في الحمل الأنبوبي. حضرت امرأة تبلغ من العمر 25 عاماً إلى المستشفى وهي تعاني من تمدد في البطن مصحوب بالآلام وأنيماً بدون نزيف مهبلية. بعد التشخيص المؤقت للحمل المنتبذ المتمزق أجريت لها عملية شق البطن. عند العملية الاستكشافية تبين أن الأنبوبين والمبيضين سليمين. ولكن تبين وجود حمل تربي كحالة تدمي الصفاق. أجريت لها عملية قطع الشراب الجزئي. على الرغم من كون معظم الحالات ثانوية، إلا إننا نقدم هنا حالة إضافية للحمل التربي الأولي في أسبوعه الثاني عشر حسب تصنيف ستاديفورد. أكدت نتائج فحص الأنسجة تشخيصنا بدليل تشكل أوعية جديدة للنسيج الداعم. يجب دائماً على الحمل التربي الأولي أن يؤخذ بعين الاعتبار كشرح محتمل لتدمي الصفاق الشديد للحمل المنتبذ الذي يصاحبه ألم في البطن والملحقات سليمة عند الاستكشاف الجراحي.

Omental pregnancy is a rare form of ectopic pregnancy, and can be seen primarily or secondary to a tubal pregnancy. A 25-year-old woman presented with abdominal distention with pain and anemia without vaginal bleeding. After a provisional diagnosis of ruptured ectopic pregnancy, laparotomy was performed. On surgical exploration, the bilateral tubes and ovaries were intact, however, an omental pregnancy was detected as the cause of hemoperitoneum. Partial omentectomy was performed. Although most cases are secondary, presented here is an additional case of primary omental pregnancy at 12 weeks according to Studdiford's criteria. Histological evidence of neovascularization into the supporting tissue confirmed our diagnosis. A primary omental pregnancy should always be considered as a possible explanation for severe hemoperitoneum in ectopic pregnancies presenting with acute abdomen, and with intact adnexes on surgical exploration.

*Saudi Med J 2008; Vol. 29 (4): 606-609*

*From the Departments of Obstetrics and Gynecology (Yildizhan, Kurdoglu, Kulusari) and Pathology (Erten), Yuzuncu Yil University, Van, Turkey.*

*Received 16th November 2007. Accepted 23rd February 2008.*

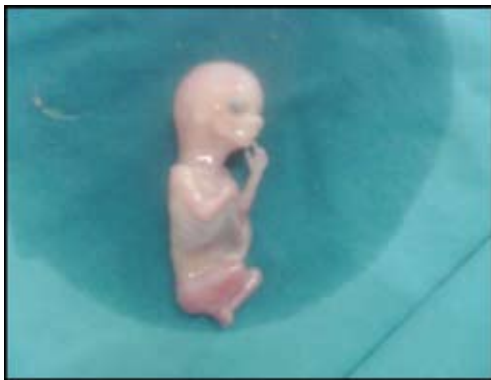*Address correspondence and reprint request to: Dr. Recep Yildizhan, Assistant Professor, Department of Obstetrics and Gynecology, Yuzuncu Yil University, Van, Turkey. Tel. +90 (432) 2150471. Fax. +90 (216) 3634018. E-mail: recepyildizhan@yahoo.com*

Abdominal pregnancy, with a diagnosis of one per 10000 births, is an extremely rare, and serious form of extrauterine gestation. In approximately 1.4% of all ectopic pregnancies, the peritoneal cavity can be the primary or secondary implantation site without any tubal, ovarian, or intraligamentous invasion. Omental implantation in abdominal pregnancy is also very uncommon, and is associated with increased maternal mortality rates, due to the difficulty in diagnosis caused by highly variable clinical presentations. Most of these are secondary, primary omental pregnancies account for only 9 of the cases in the English literature.<sup>1-9</sup> This paper presents an additional case of primary omental pregnancy, and reviews all similar cases in the literature.

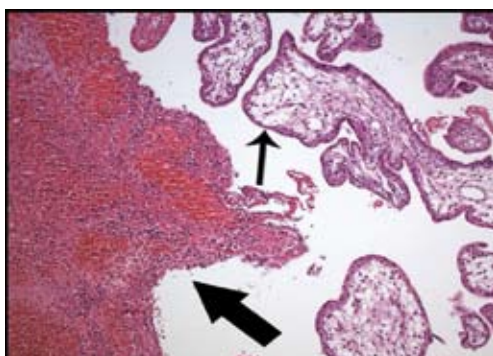
**Case Report.** A 25-year-old gravida 2, para 1 woman presented with a 3-week history of abdominal distention together with steadily increasing abdominal and back pain, weakness, lack of appetite, and restlessness without vaginal bleeding. Her first baby had been born by spontaneous vaginal delivery, and she had not used any contraceptive method afterwards. She denied a history of pelvic inflammatory disease, sexually transmitted disease, surgical operations, or allergies. Her menses were irregular, and she did not know when her last menstrual period had been. Her blood pressure was 80/50 mmHg, and pulse was 110 beats/minute. An abdominal examination revealed rigidity, and peritoneal irritation signs. Her hematocrit was 18.7%, and hemoglobin value was 6.1 g/dl. Her urinary pregnancy test was positive. A transabdominal ultrasound examination revealed a large amount of free peritoneal fluid without any intrauterine sac, or adnexial mass. With a preoperative diagnosis of acute abdomen due to ruptured ectopic pregnancy, laparotomy was performed, and it revealed approximately 3000 ml of hemoperitoneum. After aspiration of the blood, both fallopian tubes and the left ovary were found to be normal in appearance. The uterus was slightly enlarged, and soft. The right ovary was normal except for an intact 4 cm corpus luteum cyst. On exploration, the omentum was found to be adherent to the placenta of a fetus in the uterovesical fold, and active bleeding from

this site was observed. The appearance was consistent with omental pregnancy, and partial omentectomy was performed by the excision of 15x9 cm of omental tissue. A cyst was excised from the right ovary. The pelvis was irrigated with 2000 ml of saline, and exploration of the upper abdomen, the rest of the omentum, the appendix, and bowel surfaces did not show any further pathology. The operation ended with uterine curettage. The patient was transfused during, and after surgery with 6 units of whole blood.

The fetus was approximately 12 weeks old according to its development (Figure 1). Histological evidence of neovascularization into the supporting tissue confirmed our diagnosis of primary omental pregnancy (Figure 2). The right ovarian cyst excised was a hemorrhagic corpus luteum cyst. The uterine curettage yielded a decidual endometrial reaction. The patient was discharged on postoperative day 4 without any complication. The patient's consent was obtained for publication of this case report.



**Figure 1** - The fetus of the omental pregnancy. The photograph was taken immediately after the removal of the fetus from the uterovesical fold by detaching it from the placenta. The fetus development is consistent with 12 weeks of gestation.



**Figure 2** - Omental pregnancy. Extensive villus formation (thin arrow), and trophoblastic proliferation into the omental tissues including newly formed blood vessels, and acute inflammation (thick arrow) are seen.

**Discussion.** Although omental pregnancies are mostly secondary, presented here is an additional case of primary omental pregnancy at 12 weeks according to Studdiford's criteria.<sup>10</sup> In this criteria, the diagnosis of primary omental pregnancy is based on the following anatomic conditions, 1) normal tubes and ovaries 2) absence of an utero placental fistula, and 3) attachment exclusively to a peritoneal surface early enough in gestation to eliminate the likelihood of secondary implantation. In our case, both fallopian tubes and the left ovary were normal. Although the right ovary contained a corpus luteum cyst, it was intact, and histology confirmed our diagnosis. Berghella et al<sup>11</sup> proposed that the presence of a ruptured corpus luteum in a patient, suggests that the original site of implantation might have been the ovary since all ovarian pregnancies seem to implant adjacent to the corpus luteum. It is also possible that the villi become implanted on the omentum, leaving the site of origin of the pregnancy apparently normal. However, Berghella et al<sup>11</sup> recommended that, in order to support a diagnosis of primary ectopic pregnancy, histological evidence of neovascularization, or growth of trophoblast into the supporting tissue must be shown. In our pathological sections, neovascularization together with extensive villus formation and trophoblastic proliferation into the omental tissues was observed (Figure 2). With regard to the second criterion, we did not observe any utero placental fistula in our case. Since abdominal pregnancy at less than 20 weeks of gestation is considered early,<sup>12</sup> our case can be regarded as early, and so we eliminated the likelihood of secondary implantation.

The recent use of progesterone-only pills and intrauterine devices with a history of surgery, pelvic inflammatory disease, sexually transmitted disease, and allergy can be regarded as risk factors for ectopic pregnancy. Our patient had not been using any contraception, and did not give a history of the other risk factors. The clinical presentation of an abdominal pregnancy can differ compared to that of a tubal pregnancy. Although there may be great variability in symptoms, severe lower abdominal pain is one of the most consistent findings.<sup>5</sup> As seen in our patient, there may be neither delay of menstruation nor spotting in these patients.

Transvaginal ultrasound is superior to transabdominal ultrasound in the evaluation of ectopic pregnancy since it allows a better view of the adnexa and uterine cavity. However, since our emergency department has no transvaginal sonography facilities, and is far from our obstetrics and gynecology department, which do have them, we directed this hemodynamically unstable patient immediately to the operation room, upon diagnosis of suspected ruptured ectopic pregnancy. That may be the reason why we could not detect the corpus luteum preoperatively. As a management protocol in our

department, we perform uterine curettage in all patients with ectopic pregnancy gently at the end of the operation, not only for the differential diagnosis of ectopic pregnancy, and to help in reducing present, or possible postoperative vaginal bleeding. However, it may be considered an inappropriate procedure in a hemodynamically unstable condition with the operative diagnosis of omental pregnancy, and no preoperative suspicion of intrauterine pregnancy, like in our patient, since it may cause complications. Although exploratory laparotomy is considered the gold standard in the management of both early and late abdominal pregnancies, some recent reports recommend laparoscopy in early cases when the patient is hemodynamically stable.<sup>5,12</sup> In our case, since the patient was hemodynamically unstable, we chose laparotomy. However, in such a case with a virgin abdomen, and a background of a provisional diagnosis

of ectopic pregnancy, laparoscopy could also have been considered. Some surgeons indicate that they could perform uncomplicated laparoscopic surgery in patients in shock due to ruptured tubal pregnancy with the advantages of a better operative view, ease of aspiration of hemoperitoneum, and patient recovery. If we had attempted a laparoscopic approach first, due to technical issues (night-time) we would have been unable to set up the laparoscopy.

Ten cases of primary omental pregnancies (including this report) reported in the English literature before January 2008 are reviewed in Table 1. The patients were between ages 16 and 35. Lower abdominal pain accompanied by signs of hemorrhagic shock comprises most of the symptomatology. While 5 of the 10 cases were managed by laparoscopy only, laparotomy was performed in 4 cases. In only one case, both laparoscopy, and laparotomy were

**Table 1** – Reported cases of primary omental pregnancy.

Case	Age (years)	Parity	Symptoms	Weeks of gestation	Surgery	Positive findings on exploration	Pathology
Weeks et al, <sup>7</sup> 1997	34	0	Left iliac fossa pain	6	Laparoscopy	A 2-cm hemorrhagic mass adherent to the omentum adjacent to the left ovary	A blood clot containing scanty chorionic villi and syncytiotrophoblast cells
Chung et al, <sup>2</sup> 2002	16	0	Lower abdominal pain	8	Laparoscopy	A mass with blood clots on the omentum, 1.5 cm gestational sac	Hemorrhagic change and villi on resected omental tissue
Chang et al, <sup>1</sup> 2003	28	1	Abdominal pain, sweat, syncope	5	Laparoscopy	A bleeding site on the omentum	Trophoblastic invasion, hemorrhagic corpus luteum on the left ovary
Ozdemir et al, <sup>6</sup> 2003	21	0	Abdominal pain, nausea, and vomiting,	12	Laparotomy	Gestational sac within the great omentum, placenta implanted on the omentum	Adipose tissue containing blood clots and villi
Wong et al, <sup>8</sup> 2004	29	2	Colicky epigastric pain	No delay	Laparoscopy + Laparotomy	Bluish mass embedded in the omentum, blood clot; left ovarian cyst	Chorionic villi and placental site reaction between blood clot and omental fat
Onan et al, <sup>5</sup> 2005	28	1	Bilateral severe abdominal pain	No delay	Laparotomy	Palpable nodular lesion on the omentum	Extensive villus formation, dense trophoblastic invasion, vascular structure
Khalil et al, <sup>4</sup> 2006	31	1	Lower abdominal pain	7	Laparoscopy	Bleeding corpus luteum at right ovary, a swelling in omentum and blood clot	Omental tissue containing blood clot, chorionic villi and trophoblastic tissue
Karaer et al, <sup>3</sup> 2007	35	1	Dizziness and abdominal pain	No delay	Laparotomy	Bleeding mass on the gastrocolic ligament, a gestational sac with the embryo	Arias-Stella reaction on endometrial curettage
Hornemann et al, <sup>9</sup> 2007	25	2	Colicky abdominal pain	No delay	Laparoscopy	Blood clot on the omentum majus, corpus luteum in the right ovary	Hemorrhage and resorption, $\beta$ -hCG-positive multinucleated syncytiotrophoblasts
This case	25	1	Abdominal and back pain, distention, weakness, restlessness	12	Laparotomy	Omentum was adherent to the placenta of a fetus in uterovesical fold, corpus luteum of right ovary	Extensive villus formation and trophoblastic proliferation into the omental tissues

$\beta$ -hCG - beta-human chorionic gonadotropin

used, as needed. On surgical exploration, a hemorrhagic mass adherent to the omentum, and a blood clot was the most consistent finding. Some of the cases also included a corpus luteum in one of the ovaries. Histopathological examinations of surgical specimens usually showed trophoblastic invasion, and villus formation on omental tissue.

In conclusion, a primary omental pregnancy should always be considered as a possible explanation of severe hemoperitoneum in ectopic pregnancies presenting with acute abdomen, and with intact adnexa on surgical exploration.

**Acknowledgment.** *We would like to thank Dr. Ertan Adali for his contributions in the preparation of the manuscript, and Russell Fraser for the corrections in English.*

## References

1. Chang CK, Leu FJ, Teng SW. Primary omental pregnancy treated by laparoscopic surgery. *Int J Gynaecol Obstet* 2003; 80: 325-326.
2. Chung MT, Lin YS, Wu MP, Huang KF. Laparoscopic surgery for omental pregnancy. *J Am Assoc Gynecol Laparosc* 2002; 9: 84-86.
3. Karaer O, Ilkgul O, Oruc S. Primary omental pregnancy on the gastrocolic ligament. *South Med J* 2007; 100: 403-404.
4. Khalil A, Aslam N, Haider H, Creighton SM. Laparoscopic management of a case of unexpected omental pregnancy. *J Obstet Gynaecol* 2006; 26: 475-476.
5. Onan MA, Turp AB, Saltik A, Akyurek N, Taskiran C, Himmetoglu O. Primary omental pregnancy: case report. *Hum Reprod* 2005; 20: 807-809.
6. Ozdemir I, Demirci F, Yucel O, Alper M. Primary omental pregnancy presenting with hemorrhagic shock. A case report. *Gynecol Obstet Invest* 2003; 55: 116-118.
7. Weeks AD, Aagaard J, Bromham D. Laparoscopic management of an abdominal pregnancy. *Gynaecol Endosc* 1997; 6: 249-250.
8. Wong WC, Wong BP, Kun KY, Ng TK, Kwok SY, Lee CK. Primary omental ectopic pregnancy. *J Obstet Gynaecol Res* 2004; 30: 226-229.
9. Hornemann A, Holl-Ulrich K, Finas D, Altgassen C, Diedrich K, Hornung D. Laparoscopic management of early primary omental pregnancy. *Fertil Steril* 2007 Aug 2. Epub ahead of print.
10. Studdiford WE. Primary peritoneal pregnancy. *Am J Obstet Gynecol* 1942; 44: 487-491.
11. Berghella V, Wolf SC. Does primary omental pregnancy exist? *Gynecol Obstet Invest* 1996; 42: 133-136.
12. Gaither K. Abdominal pregnancy-an obstetrical enigma. *South Med J* 2007; 100: 347-348.

## Illustrations, Figures, Photographs

Four copies of all figures or photographs should be included with the submitted manuscript. Figures submitted electronically should be in JPEG or TIFF format with a 300 dpi minimum resolution and in grayscale or CMYK (not RGB). Printed submissions should be on high-contrast glossy paper, and must be unmounted and untrimmed, with a preferred size between 4 x 5 inches and 5 x 7 inches (10 x 13 cm and 13 x 18 cm). The figure number, name of first author and an arrow indicating "top" should be typed on a gummed label and affixed to the back of each illustration. If arrows are used these should appear in a different color to the background color. Titles and detailed explanations belong in the legends, which should be submitted on a separate sheet, and not on the illustrations themselves. Written informed consent for publication must accompany any photograph in which the subject can be identified. Written copyright permission, from the publishers, must accompany any illustration that has been previously published. Photographs will be accepted at the discretion of the Editorial Board.