

Case Report

An unusual cause of peritonitis in peritoneal dialysis patients: *Pantoea agglomerans*

Rumeyza Kazancioglu¹, Banu Buyukaydin², Meryem Iraz³, Murat Alay¹, Reha Erkoç¹

¹ Department of Nephrology, Faculty of Medicine, Bezmialem Vakif University, Istanbul, Turkey

² Department of Internal Medicine, Faculty of Medicine, Bezmialem Vakif University, Istanbul, Turkey

³ Department of Microbiology, Faculty of Medicine, Bezmialem Vakif University, Istanbul, Turkey

Abstract

Peritonitis is a serious infection and early diagnosis and treatment is mandatory. A variety of microorganisms are identified in these cases and during recent years a new one was included, *Pantoea agglomerans*. In this case report, a female patient on continuous ambulatory peritoneal dialysis therapy with a peritonitis episode caused by this organism is described. The source of infection was thought to be due to contact of catheter with non-sterile surfaces. In microbiologic culture, this organism was identified and the patient successfully treated with a three week course of gentamicin therapy. The number of reported cases with this organism has increased in last years and various infection localizations and clinical progress patterns have been identified. In peritoneal dialysis patients presenting with peritonitis, this organism must be kept in mind.

Key words: *pantoea agglomerans*; peritoneal dialysis; peritonitis.

J Infect Dev Ctries 2014; 8(7):919-922. doi:10.3855/jidc.3785

(Received 11 May 2013 – Accepted 10 November 2013)

Copyright © 2014 Kazancioglu *et al.* This is an open-access article distributed under the Creative Commons Attribution License, which permits unrestricted use, distribution, and reproduction in any medium, provided the original work is properly cited.

Introduction

Peritonitis is a common and serious complication in patients on peritoneal dialysis (PD) [1]. Gram-positive and aerobic gram-negative bacteria are commonly isolated from peritoneal fluid in this group of patients. One of these gram-negative organisms is *Pantoea agglomerans*. The earliest reports regarding this organism were published in 1972 and it was formerly named *Enterobacter agglomerans* and *Erwinia herbicola* [2]. It belongs to the family *Enterobacteriaceae* and is responsible for infection diseases ranging from plant-thorn arthritis, osteoitis, osteomyelitis and traumatic wound infections to bacteremia. Until now a number of clinical cases caused by this organism have been described.

In this report we present a patient on continuous ambulatory peritoneal dialysis (CAPD) infected with *P. agglomerans* and we reviewed the literature for infections caused by this organism, including peritonitis.

Case Report

A 63 years old female patient receiving CAPD for a year presented with abdominal, inguinal pain and cloudy peritoneal fluid. Two days prior to presentation

she had completed two weeks intraperitoneal vancomycin and ceftazidime treatment for a peritonitis attack which was assumed to have developed after a non-sterile surface contact of the PD catheter. Her past medical history consisted of hypertension. Four exchanges of two liters per day were her PD prescription. She was a house wife and had not traveled recently. On physical examination, her temperature was 37°C and blood pressure was 150/100 mmHg. There was minimal pretibial edema, mild generalized abdominal tenderness with no rebound and normal bowel sounds. Catheter exit-site was clean and without erythema. In laboratory studies, white blood cell count (WBC) was $5.88 \times 10^3/\mu\text{L}$. The haemoglobin level was 10.8 g/dl and the platelet count was $168 \times 10^3/\mu\text{L}$. C-reactive protein was 0.1 mg/dl. The serum blood urea nitrogen and creatinine were detected as 36 mg/dl and 4.3 mg/dl respectively. Dialysate WBC count was 810/ μL . For microbiologic evaluation, 10 ml dialysate was inoculated in a BACTEC Plus Aerobic/F and Plus Anaerobic/F broth (Becton Dickinson Franklin Lakes, USA) and incubated at 37°C in a BACTEC 9120 (Becton Dickinson, Franklin Lakes, USA) automatised blood culture system. Meanwhile, intraperitoneal (IP) 1 gr

cefazolin sodium and 80 mg gentamicin per day were started. Bacterial growth developed in aerobic bottle after 24 hours of incubation. Inoculation was applied on solid culture from positive bottles. In gram staining of dialysate from positive bottles, gram negative bacilli were detected (Figure 1.) On blood and chocolate agar plates, the colonies displayed yellow pigmentation (Figures 2 and 3). The isolate was identified as *P. agglomerans* by Vitek-2 automatized system (bioMerieux, Marcy l'Etoile, France). Identification was confirmed by conventional microbiological methods (Citrate-, urease-, TSI Alk/A hydrogen sulfide -, indole-, voges-proskauer+, motility+, yellow pigment+, oxidase-, catalase+). It was sensitive to ampicillin, gentamicin, amikacin, ciprofloxacin, trimethoprim-sulfamethoxazole, piperacillin, ceftazidime and tigecycline. The initially administered 1 gr cefazolin sodium was stopped and 80 mg gentamicin per day IP was continued for 21 days. In clinical follow-up, patients' complaints completely resolved and dialysate WBC count decreased to normal levels within a few days. The patient is currently still on CAPD with no complaint.

Discussion

In this report, we present a patient with PD. In this group of patients, peritonitis is a serious complication and one of the major reasons for drop-out from PD. Treatment of infections is very important and this requires proper microbiological evaluation. One of the microorganisms with increased incidence over the last years is *P. agglomerans*. Various sources of infection and transmission patterns have been identified. In this study, we considered that a simple contact of the PD catheter with a non-sterile surface was responsible for transmission. For PD patients, compliance with sterilization procedures is very important for preventing contamination with this organism along with other pathogens. Presentation of infection is generally the same as that with other pathogens, as in our case. Microbiological evaluation is essential for identification. The course of the infection shows variability but response to treatment is satisfactory. In our case, the isolate was highly susceptible to antibiotics and gentamicin treatment was sufficient to resolve the episode.

This organism is found especially in plants, fruits, vegetables and also human and animal feces [2]. Its transmission is generally associated with plant thorn injuries, intravenous anaesthetic catheters, contaminated parenteral nutrition and subgingival sites with periodontal diseases [3,4].

Figure 1. Gram staining of dialysate

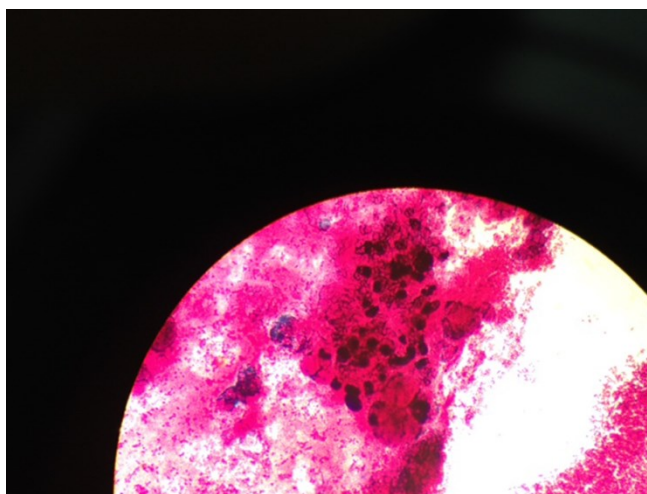


Figure 2. Yellow pigmentation in blood agar

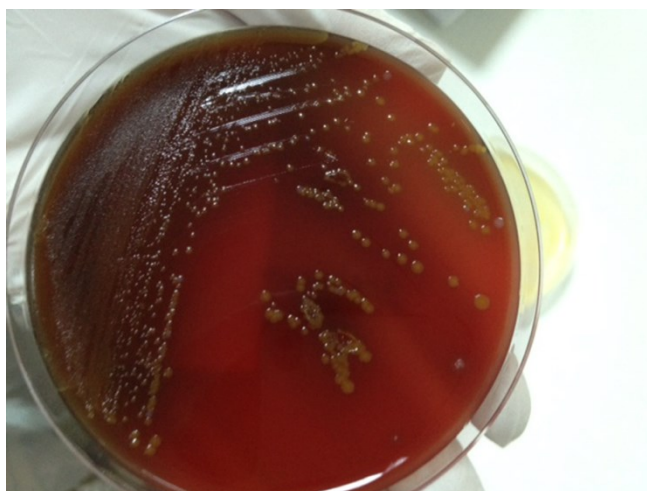
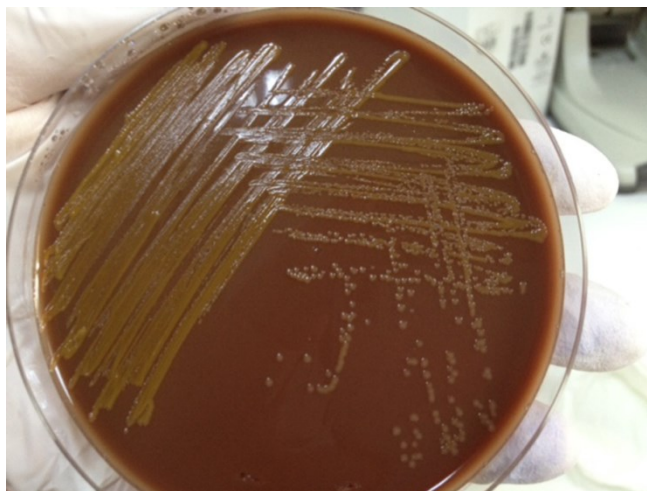


Figure 3. Yellow pigmentation in chocolate agar



Clinical reflections are listed from osteoitis, osteomyelitis, arthritis to systemic infections and severe septicemia. Peritonitis is a rare presentation of this organism. For diagnosis, microbiological specimens obtained from proper localizations according to patients' complaints and presentation are generally sufficient. The symptoms of *P. agglomerans*-associated peritonitis are not different from those with other pathogens, including fever, nausea, vomiting and abdominal pain. *P. agglomerans* is commonly considered an environmental pathogen, but it can cause symptomatic peritonitis with a fatal outcome. Therefore, microbiological evaluation and antibiotic susceptibility tests should be required for every peritonitis episode as suggested by International Society for Peritoneal Dialysis (ISPD) guidelines [5]. *P. agglomerans* peritonitis shows good response to antibiotics such as ciprofloxacin and aminoglycoside. Also in our case, the isolate was highly susceptible to antibiotics, and gentamycin was sufficient to resolve the episode.

In the literature, infections with *P. agglomerans* have generally been presented as case reports. We detected an increase the number of reports with this organism in recent years. In 2007, Cruz *et al.* reported 53 pediatric cases with isolates from varied sites including blood culture, abscesses, joints, urinary tract, and peritoneum [6]. In immunosuppressed patients, presentation with sepsis was also reported [7]. In 2010, a rare presentation of *P. agglomerans* - endophthalmitis - was observed and a good response with systemic and local antibiotics was reported [8]. Another case report, authored by Kurşun *et al.* described a ventilator-associated pneumonia in a male patient with chronic renal failure in intensive care unit [9]. In 2012, Boszczowski *et al.* identified a nosocomial outbreak with *P. agglomerans* in patients treated with hemodialysis and plasmapheresis. In that study, a possible environmental contamination was considered and continuous education for good quality hand hygiene and rigorous observation of environmental transmission were advised [10]. In another study, high association between bacteremia and gastroesophageal reflux disease was identified [11].

Among PD patients, peritonitis attacks with this organism have increased in recent years. The mode of infection and pathogenesis of this disease in this patients' group remained unclear. There is no proven better diagnostic technique for more easily identification. The incubation period is uncertain and inappropriate growth media and identification methods could be the reason for negative results. Different

contamination patterns were identified like rose-thorn injury and teething on a catheter in these reports also [12-14]. However, some patients proposed etiologies were unknown [14,15]. Our patient did not report any injury or skin trauma but complained of a previous contact of the catheter on nonsterile surfaces. We think this contamination was responsible for bacterial infection.

In peritonitis attacks of PD patients, this microorganism must be kept in mind. Response to treatment is favorable and early treatment modification according to antibiogram is essential. In PD patients, peritoneal function tests may be affected after this infection. Ultrafiltration failure has been observed in some cases and peritoneal calcification and thickening were considered as possible pathologies [16].

Conclusion

Peritonitis is a serious complication of PD treatment. *P. agglomerans* is one of the causative organisms with rising incidence in recent years and must be kept in mind. Although early diagnosis and therapy provides satisfactory outcomes, studies regarding transmission patterns are still required.

Acknowledgements

We would like to thank the peritoneal dialysis medical assistant team in the Nephrology Clinic.

References

1. Troidle L, Gorban-Brennan N, Kliger A, Finkelstein FO (2003) Continuous peritoneal dialysis-associated peritonitis: a review and current concepts. *Semin Dial* 16: 428-437.
2. Bottone E, Schneierson SS (1972) *Erwinia* species: an emerging human pathogen. *Am J Clin Pathol* 57: 400-405.
3. Kratz A, Greenberg D, Barki Y, Cohen E, Lifshitz M (2003) *Pantoea agglomerans* as a cause of septic arthritis after palm tree thorn injury; case report and literature review. *Arch Dis Child* 88: 542-544.
4. Kahveci A, Asicioglu E, Tigen E, Ari E, Arıkan H, Odabasi Z, Ozener C (2011) Unusual causes of peritonitis in a peritoneal dialysis patient: *Alcaligenes faecalis* and *Pantoea agglomerans*. *Ann Clin Microbiol Antimicrob* 10: 12.
5. Li PK, Szeto CC, Piraino B, Bernardini J, Figueiredo AE, Gupta A, Johnson DW, Kuijper EJ, Lye WC, Salzer W, Schaefer F, Struijk DG (2010) Peritoneal dialysis-related infections recommendations 2010 update. *Perit Dial Int* 30: 393-423.
6. Cruz AT, Cazacu AC, Allen CH (2007) *Pantoea agglomerans*, a plant pathogen causing human disease. *J Clin Microbiol* 45: 1989-1992.
7. Liberto MC, Matera G, Puccio R, Lo Russo T, Colosimo E, Focà E (2009) Six cases of sepsis caused by *Pantoea agglomerans* in a teaching hospital. *The New Microbiol* 32: 119-123.

8. Lee NE, Chung IY, Park JM (2010) A case of *Pantoea* endophthalmitis. *Korean J Ophthalmol* 24: 318-321.
9. Kurşun O, Unal N, Cesur S, Altın N, Canbakan B, Argun C, Koldaş K, Sencan I (2012) A case of ventilator-associated pneumonia due to *Pantoea agglomerans*. *Mikrobiyol Bul* 46: 295-298.
10. Boszczowski I, Nóbrega de Almeida Júnior J, Peixoto de Miranda EJ, Pinheiro Freire M, Guimarães T, Chaves CE, Cais DP, Strabelli TM, Risek CF, Soares RE, Rossi F, Costa SF, Levin AS (2012) Nosocomial outbreak of *Pantoea agglomerans* bacteraemia associated with contaminated anticoagulant citrate dextrose solution: new name, old bug? *Journal of Hospital Infection* 80: 255–258.
11. Cheng A, Liu CY, Tsai HY, Hsu MS, Yang CJ, Huang YT, Liao CH, Hsueh PR (2013) Bacteremia caused by *Pantoea agglomerans* at a medical center in Taiwan 2000-2010 *J Microbiol Immunol Infect* 46: 187-194.
12. Lau KK, Ault BH, Jones DP (2005) Polymicrobial peritonitis including *Pantoea agglomerans* from teething on a catheter. *South Med J* 98: 580-581.
13. Lim PS, Chen SL, Tsai CY, Pai MA (2006) *Pantoea* peritonitis in a patient receiving chronic ambulatory peritoneal dialysis. *Nephrology* 11: 97-99.
14. Habhab W, Blake PG (2008) *Pantoea* peritonitis: not just a “thorny” problem. *Perit Dial Int* 28: 430.
15. Moreiras-Plaza M, Blanco-García R, Romero-Jung P, Feijóo-Piñero D, Fernandez-Fernandez C, Ammari I (2009) *Pantoea agglomerans*: the gardener’s peritonitis? *Clin Nephrol* 72: 159-161.
16. Borràs M, Roig J, Garcia M, Fernández E (2009) Adverse effects of *pantoea* peritonitis on peritoneal transport. *Perit Dial Int* 29: 234–235.

Corresponding author

Dr. Banu Buyukaydin
Bezmialem Vakif University, Faculty of Medicine, Department of Internal Medicine,
Adnan Menderes Street, 34093 Fatih / Istanbul, Turkey
Phone: +902124531710
Fax: +902126217580
E-mail: bbuyukaydin@hotmail.com

Conflict of interests: No conflict of interests is declared.