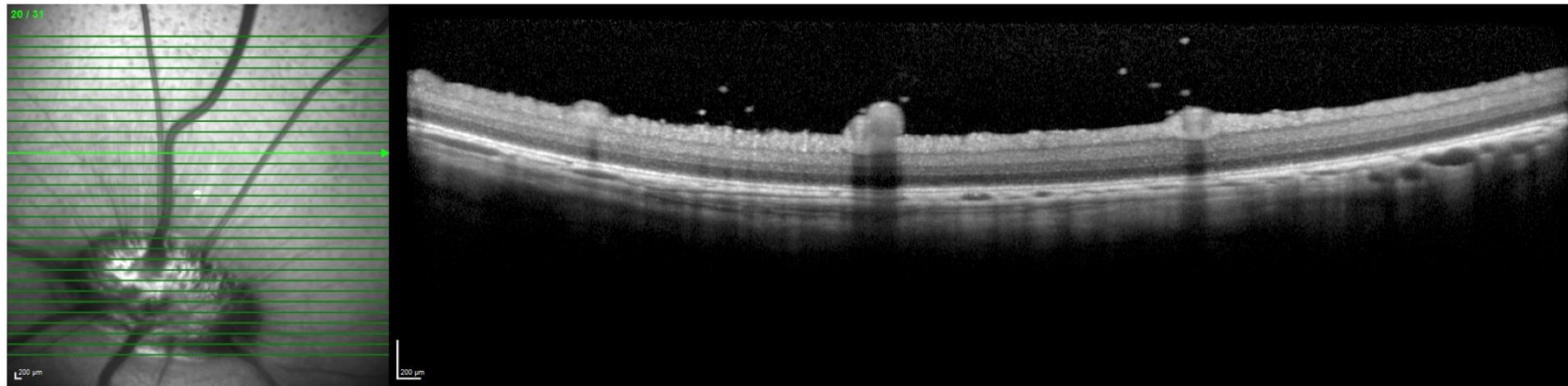


Supplemental Figure 1



Representative OCT image illustrating the presence of Hyper-reflective spots (HRS) in the vitreous