

Rib Lodged in the Airway

Norihiko Matsumura¹, Hideaki Takenaka², Sumito Cho² and Kazuo Yamamoto³

Key words: rib, intrabronchial foreign body, CT scan

(DOI: 10.2169/internalmedicine.45.1648)

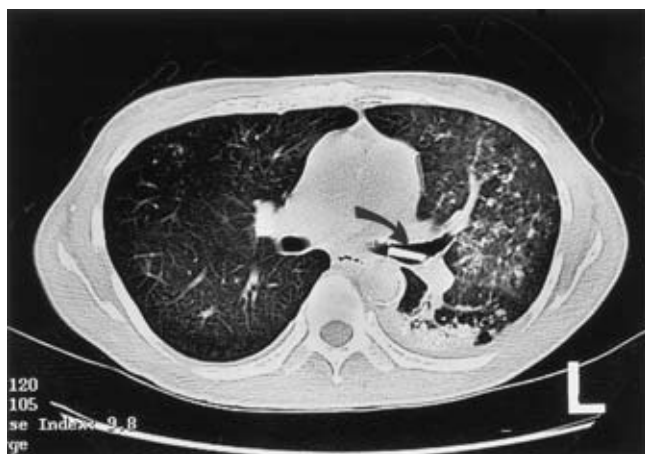


Figure 1. CT scan showing a stick-like structure with increased density, 2 cm in length, in the left main bronchus (arrow). Note the infiltrate of the left lower lobe and scattered patchy opacities over the left lung field.

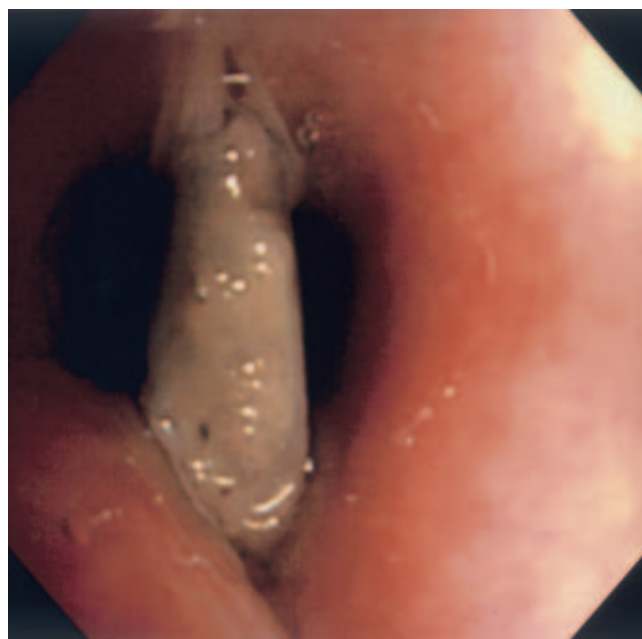

Figure 2. Fiberoptic bronchoscopy showing a foreign body covered with mucus in the left main bronchus.

A 55-year-old woman on maintenance hemodialysis presented with a recurrent cough, hemoptysis and productive purulent sputum. She had undergone a tracheoplasty with her own rib for stenosis of the trachea six years earlier. A chest radiograph showed infiltrative shadows in the left lung field. A computed tomographic (CT) scan of the chest showed a stick-like structure in the left main bronchus, and consolidation of the left lower lobe (Fig. 1). Fiberoptic bronchoscopy disclosed a foreign body covered with mucus

in the left main bronchus (Fig. 2). Simultaneous removal of the bronchoscope and the object, firmly grasped with foreign body forceps, was attempted. The object was successfully retrieved. It was identified as a piece of rib. Taking the disappearance of the rib at the latest CT film into consideration, the rib must have migrated into the airway or dropped because of thinning of the mucosa of the trachea. Although the precise process is not known, the fragility of the trachea as scaffolding might result in lodgment of a foreign body.

© 2006 The Japanese Society of Internal Medicine
<http://www.naika.or.jp/imindex.html>

¹ Department of Nephrology, Saiseikai Suita Hospital, Suita, ² Respiratory Medicine, Saiseikai Suita Hospital, Suita and ³ Cardiology, Saiseikai Suita Hospital, Suita

Received for publication November 10, 2005; Accepted for publication February 3, 2006

Correspondence to Norihiko Matsumura, Department of Nephrology, Saiseikai Suita Hospital, 1-2 Kawazono-cho, Suita, Osaka 564-0013