

MORPHOMETRIC STUDY OF NUTRIENT FORAMEN IN THE LONG BONES OF LOWER LIMB

Kalyanasundaram Mohan ¹, Backiaraj Devaraj ², Shalini Ramanathan ^{*3}, Manoranjitham Rethinasamy ⁴,

¹ Professor, Department of Anatomy, Thanjavur Medical College, Thanjavur, Tamilnadu, India.

² Assistant Professor, Department of Orthopaedics, Dhanalakshmi Srinivasan Medical College and Hospital, Siruvachur, Perambalur, Tamilnadu, India.

^{*3} Assistant Professor, Department of Anatomy, Dhanalakshmi Srinivasan Medical College and Hospital, Siruvachur, Perambalur, Tamilnadu, India.

⁴ Professor and Head, Department of Anatomy, Dhanalakshmi Srinivasan Medical College and Hospital, Siruvachur, Perambalur, Tamilnadu, India.

ABSTRACT

Background: The nutrient foramen allows the passage of the neurovascular bundle to and from the diaphysis of the long bones. The nutrient foramen has a specific position in each long bone. The nutrient artery is the main source of blood supply to the actively growing long bone in children.

Materials and Methods: This study was conducted in 450 long bones of the lower limb (150- femur, 150- tibia, 150- fibula). The number, size, location and direction of the diaphyseal nutrient foramen in each of the long bones was noted. The foraminal index was also calculated using the Hughes formula.

Results: In femur single nutrient foramen was present in 64% of the bones, double nutrient foramina in 30% of the bones and triple nutrient foramina in 6% of the bones. The most common location of the nutrient foramina in femur was in between the 2 lips of linea aspera, which was noted in 40.84% of the bones and in 88% of the bones the nutrient foramen was located in the middle third of the shaft of femur. In tibia, single nutrient foramen was found in 98% of the bones and double nutrient foramina were found in 2% of the bones. The most common location of the nutrient foramen in tibia was on the posterior surface midway between the interosseous border and soleal line, which was noted in 47.05% of the bones and in 58% of the bones, the nutrient foramen was located in the middle third of the shaft of tibia. In fibula, single nutrient foramen was found in 98.66% of the bones and double nutrient foramina were found in 1.33% of the bones. The most common location of the nutrient foramen in fibula was on the posterior surface on the medial crest, which was noted in 41.44% of the bones and in 90% of the bones the nutrient foramen was on the middle third of the shaft of fibula.

Conclusion: The precise knowledge of the nutrient foramen of the long bones of lower limb will help Orthopaedicians and Plastic surgeons during surgeries of the lower limb.

KEY WORDS: Nutrient Foramen, Nutrient Artery, Foraminal Index, Dominant Nutrient Foramen, Secondary Nutrient Foramen.

Address for Correspondence: Dr. Shalini Ramanathan, Assistant Professor, Department of Anatomy, Dhanalakshmi Srinivasan Medical College and Hospital, Siruvachur, Perambalur, Tamilnadu, India. **E-Mail:** liniram80@yahoo.com

Access this Article online

Quick Response code



DOI: 10.16965/ijar.2017.225

Web site: International Journal of Anatomy and Research
ISSN 2321-4287
www.ijmhr.org/ijar.htm

Received: 20 Apr 2017
Peer Review: 20 Apr 2017
Revised: None

Accepted: 23 May 2017
Published (O): 30 Jun 2017
Published (P): 30 Jun 2017

INTRODUCTION

The nutrient foramen is a cavity allowing the passage of a nutrient artery and a peripheral nerve into the diaphysis of a long bone [1]. The nutrient artery is the principal source of blood supply to long bones, especially during periods of active bone growth and also in embryonic stages [2]. Trueta J, [3] has reported that 70 – 80% of intraosseous blood supply to long bones in children is supplied by nutrient arteries and when there is a compromise of this blood supply, ischemia of medullary bone occurs and there is less vascularization of metaphysis and growth plate. The nutrient foramen is generally directed away from the growing end of the bone [4].

The nutrient foramen is located in a specific position in each bone [5]. In femur, the nutrient foramen is directed upwards and most commonly located on the Linea Aspera. The main nutrient artery is derived from the 2nd perforating artery. If there are 2 nutrient arteries, they may arise from the 1st and 3rd perforators [4].

In tibia, the nutrient foramen usually lies near the soleal line and is directed downwards. The main nutrient artery is a branch of posterior tibial artery, but sometimes it may also arise at the popliteal bifurcation, or as a branch from anterior tibial artery [4].

In fibula, the nutrient foramen is located slightly proximal to the midpoint of the posterior surface and is directed downwards. The nutrient artery to fibula is a branch of fibular artery [4]. Knowledge of the anatomy of nutrient foramen of fibula is very important while raising osteofasciocutaneous free flaps of fibula [5]. The vascularized fibular bone grafts are used for stabilization of lost mandible, spine and also tibia. Fibular grafts are also used for reconstructive surgeries after excision of bone tumours and other bony defects [6].

The precise knowledge of nutrient foramina is needed during treatment of bone fractures [7], bone grafting surgeries and also for the interpretation of height of an individual from a fragment of bone in medicolegal cases [8]. Hence, the present study was conducted to observe the number, size, location and direction of nutrient foramen in the long bones of lower limb.

MATERIALS AND METHODS

The present study was conducted on 450 long bones of lower limb (150- femur, 150- tibia and 150- fibula) of unknown age and sex. The bones were obtained from the Department of Anatomy, Dhanalakshmi Srinivasan Medical College and Hospital, Perambalur, Tamilnadu. The bones which were complete and fully ossified were included for the study. Incomplete bones and those with pathological changes were not included in the study. Only the diaphyseal nutrient foramen was observed for the study.

The number of nutrient foramina in each bone was noted. The size of the nutrient foramen was measured using a hypodermic needle. Nutrient foramina which did not allow the passage of a size 24 gauge needle were considered as secondary nutrient foramina. Nutrient foramina which allowed the passage of size 24 gauge needle were considered as dominant nutrient foramina [9]. The direction of the nutrient foramen was assessed by passing a hypodermic needle into the nutrient foramen.

The location of the nutrient foramen in each long bone was noted in relation to the nearby anatomical structures.

The distance of the dominant nutrient foramen (DNF) from the highest point of the proximal part of the long bones was measured with a vernier calipers. The total length (TL) of the bone was measured using an osteometric board. The location of the nutrient foramen in the upper, middle or lower third of the bone was determined using Hughes formula for foraminal index (FI). $FI = DNF / TL \times 100$.

The nutrient foramen was localised to the proximal, middle and distal third of the shaft of the bone based on the foraminal index as follows:

FI less than 33.33 – the nutrient foramen was in the proximal third of the bone

FI from 33.33 to 66.66 – the nutrient foramen was in the middle third of the bone

FI greater than 66.66 – the nutrient foramen was in the distal third of the bone.

All the observations were carefully tabulated and statistically analysed using Microsoft excel worksheet.

RESULTS

Number of nutrient foramina observed: In femur, single nutrient foramen was observed in 64% of the bones, double nutrient foramina (Figure 1) was observed in 30% of the bones and triple nutrient foramina (Figure 2) was observed in 6% of the bones (Table 1).

In tibia, single nutrient foramen was observed in 98% of the bones and double nutrient foramina (Figure 3) were observed in 2% of the bones (Table 1).

In fibula, single nutrient foramen was observed in 98.66 % of the bones and double nutrient foramina (Figure 4) were observed in 1.33% of the bones (Table 1).

Table 1: Number of nutrient foramina observed in the long bones of lower limb.

Bone	Single nutrient foramen	Double nutrient foramina	Triple nutrient foramina
Femur	96	45	9
Tibia	147	3	-
Fibula	148	2	-

Fig. 1: Femur showing the presence of two nutrient foramina.




Fig. 3: Tibia showing the presence of two nutrient foramina.

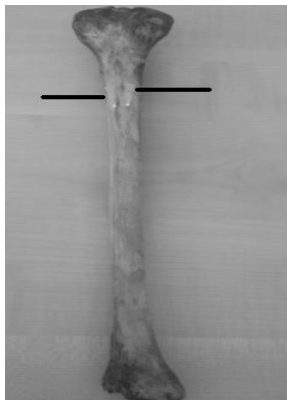

Fig. 2: Femur showing the presence of three nutrient foramina.





Fig. 4: Fibula showing the presence of two nutrient foramina.



Nutrient foramina in femur: All the nutrient foramina observed in femur were directed upwards. 88.26% of the nutrient foramina allowed the passage of 24 gauge needle and were considered as dominant nutrient foramina. 11.73% of the nutrient foramina were observed to be secondary nutrient foramina (Table 2). The nutrient foramina were most commonly located between the 2 lips of linea aspera (Table 2).

Table 2: Position and number of dominant nutrient foramina and secondary nutrient foramina observed in femur.

Position in femur	Number of nutrient foramina	Percentage of nutrient foramina	Number of dominant nutrient	Number of secondary nutrient
Between 2 lips of linea aspera	87	40.84%	75	12
Medial lip of linea aspera	60	28.16%	54	6
Lateral lip of linea aspera	18	8.45%	15	3
Posteromedial surface	45	21.12%	41	4
Posterolateral surface	2	0.93%	2	-
Medial to spiral line	1	0.46%	1	-

The average total length of femur was found to be 42.19 ± 3.46 cm. The average distance of the dominant nutrient foramen from the highest point on the proximal part of the bone was 17.11 ± 5.42 cm. The average foraminal index was 40.55 ± 8.32 . 88% of the nutrient foramina were observed in the middle third of the shaft of femur (Table 3).

Table 3: Location of nutrient foramina based on foraminal index.

Location of nutrient foramen on the shaft of femur	Number of bones	Percentage
Proximal third	18	12%
Middle third	132	88%
Distal third	-	-

Table 4: Position and number of dominant nutrient foramina and secondary nutrient foramina observed in Tibia.

Position in Tibia	Number of nutrient foramina	Percentage of nutrient foramina	Number of dominant nutrient	Number of secondary nutrient
Posterior surface- midway between interosseous border and soleal line	72	47.05%	60	12
Posterior surface- closer to interosseous border	60	39.21%	48	12
Posterior surface- closer to soleal line	21	13.72%	18	3

Nutrient foramina in Tibia: All the nutrient foramina observed in tibia were directed downwards. 82.35% of the nutrient foramina observed

were dominant nutrient foramina and 17.64% of the nutrient foramina were secondary nutrient foramina (Table 4). The most common location of the nutrient foramen was posterior surface of tibia- midway between interosseous border and soleal line (Table 4).

The average total length of tibia was found to be 36.58 ± 2.38 cm. The average distance of the dominant nutrient foramen from the highest point on the proximal part of the bone was 12.70 ± 3.64 cm. The average foraminal index was 34.74 ± 4.08 . 58% of the nutrient foramina were observed in the middle third of the shaft of tibia (Table 5).

Table 5: Location of nutrient foramina on tibia based on foraminal index.

Location of nutrient foramina on the shaft of tibia	Number of bones	Percentage
Proximal third	63	42%
Middle third	87	58%
Distal third	-	-

Nutrient foramina on fibula: All the nutrient foramina observed in fibula were directed downwards. 82.89% of the nutrient foramina observed were dominant nutrient foramina and 17.10% of the nutrient foramina were secondary nutrient foramina (Table 6). The most common location of the nutrient foramina was on the medial crest on the posterior surface of fibula (Table 6).

Table 6: Position and number of dominant nutrient foramina and secondary nutrient foramina observed in Fibula.

Position in fibula	Number of nutrient foramina	Percentage of nutrient foramina	Number of dominant nutrient	Number of secondary nutrient foramina
Posterior surface on medial crest	63	41.44%	57	6
Posterior surface- midway between medial crest and interosseous border	40	26.31%	31	9
Lateral surface	49	32.23%	38	11

Table 7: Location of nutrient foramina on fibula based on foraminal index.

Location of nutrient foramen on the shaft of fibula	Number of bones	Percentage
Proximal third	15	10%
Middle third	135	90%
Distal third	-	-

The average total length of fibula was found to be 35.36 ± 3.26 cm. The average distance of the dominant nutrient foramen from the highest point on the proximal part of the bone was

14.12 ± 3.75 cm. The average foraminal index was 39.93 ± 7.32 . 90% of the nutrient foramina were observed in the middle third of the shaft of fibula (Table 7).

DISCUSSION

Femur: In the present study 64% of the femur bones showed a single nutrient foramen. Kizilkanat et al. [10] in his study on Turkish population & Longia et al, [8] in his study on Indian population have reported that single nutrient foramen in femur is commonly present.

Mysorekar VR [11], has reported a 50% incidence of occurrence of double nutrient foramina in Indian population. Forriol Campos et al. [12] has reported 60% occurrence of double nutrient foramina in Spanish population. Sendemir and Cimen [13] in Turkish population have recorded 46% occurrence of double nutrient foramina. In the present study, it was 30% (Table 1).

Mysorekar VR [11], has also reported the occurrence of triple nutrient foramina in femur. Mazengeny et al. [14] has reported the occurrence of 6 nutrient foramina on a single femur. Ambekar SA et al. [9] has reported the occurrence of 5 nutrient foramina in 2 femur bones and triple nutrient foramina were observed in 26.9% of the femur bones in their study.

The mean length of femur was 42.19cm which is less compared to other population. The mean femur length of black South African population was 44.34cm and white South African population was 44.96cm [14]. Sendemir and Cimen [13], have reported a mean length of 44.3cm in Turkish population, Kizilkanat et al. [10] have reported the length to be 42.6cm in Turkish population and Kirschner et al. [15] have reported a mean femoral length of 40.8cm in Germans. Abledu JK et al. [16] have reported the length of femur to be 44.97 ± 2.34 cm. Ambekar SA et al. [9] has reported the mean femoral length to be 40.79cm.

Mazengeny et al. [14] has reported that the majority of the nutrient foramina were found between the 2 lips of linea aspera. In the studies by Lutken P [17], 71.1% of the nutrient foramina were on the linea aspera. Patel SM et al. [18] have reported that the nutrient foramina were most commonly located on the postero-medial surface of femur.

Mazenganya et al. [14] has reported that the majority of the nutrient foramina were on the middle third of shaft of femur. Mysorekar et al. [11], Longia et al. [8], Kirschner et al. [15], and Kizilkanat et al. [10] have also reported that the nutrient foramina were most commonly located on the middle third of femur. Patel SM et al. [18] has reported the occurrence of 25% secondary nutrient foramina in femur.

The nutrient foramina are directed away from the fast growing ends of the bone. In the lower limb the nutrient foramina are directed away from the knees [11]. Hence the nutrient foramina is directed upwards in femur.

Tibia: Patel SM et al. [18] have reported that there was only a single nutrient foramen in tibia. Gupta RK and Kumari GA [19], have reported the occurrence of 2 nutrient foramina in 2 tibiae. Kizilkanat et al. [10] have reported 2% occurrence of double nutrient foramina. Mazenganya et al. [14] have reported 1.7% occurrence of double nutrient foramina in white Africans and 0.6% occurrence in black Africans. Mazenganya et al. [14] have reported the mean tibial length to be 38.44cm in black South Africans and 37.12 in white South Africans. Nagel A [20], has reported the tibial length to be 34.8cm in Americans. Kizilkanat et al. [10] in Turkish population have reported the length to be 35.8cm. Length of tibia in the present study is similar to Ambekar SA et al. [9] who have reported it to be 36.19cm. In the present study the length of tibia is 36.58cm. Patel SM et al. [18] from India have reported that the most common location of nutrient foramina was on the posterior surface closer to the interosseous border.

Mazenganya et al. [14] have reported the nutrient foramina to be located in posterior surface in 75.6% of black South Africans and 77.8% in white South Africans. Mysorekar et al. [11] has reported 74% occurrence of nutrient foramina in the posterior surface. Sendemir and Cimen [13], have reported 90% occurrence of nutrient foramina in the posterior surface. In present study, all the nutrient foramina were on the posterior surface and commonly located midway between the interosseous border and soleal line. Gupta RK and Kumari GA [19], have reported that there was no secondary nutrient foramina in tibia. Patel SM et al. [18] has reported occur-

ce of 62.5% of secondary nutrient foramina. Patel SM et al. [18] have reported that the nutrient foramina were most commonly located in the upper third of the tibia. Gupta RK and Kumari GA [19], have reported the nutrient foramina to be commonly located in middle third of tibia. Ambekar SA et al. [9] have reported that the nutrient foramina were commonly placed on the proximal third of tibia. Kizilkanat et al. [10] have reported that the nutrient foramina were commonly present in middle third of tibia.

The nutrient foramina is generally directed downwards in tibia [11]. Mazenganya et al. [14] have reported that 0.6% tibial nutrient foramina in black South Africans and 1.7% tibial nutrient foramina in white South Africans to be directed upwards.

Fibula: Ambekar SA et al. [9] has reported the presence of one nutrient foramen in 63.5% of fibulae, two nutrient foramina in 7.7% of fibulae and three nutrient foramina in 1.9% of fibulae. Patel SM et al. [18] has reported the occurrence of single nutrient foramen in 80% of fibulae and triple nutrient foramina in 1.3% of fibulae in black South Africans. Double nutrient foramina were found in 8.9% of fibulae of white South Africans. Occurrence of only a single nutrient foramen was reported by Kizilkanat et al. [10], Longia et al. [8], and Forriol Campor et al. [12].

Ambekar SA et al. [9] has reported the total length of fibula to be 35.35 cm. Kizilkanat et al. [10] has reported the length to be 34.02cm in Turkish population. Mazenganya et al. [14] has reported the length to be 36.76cm in black South Africans and 36.07cm in white South Africans.

Patel SM et al. [18] has reported the most common location for nutrient foramina in fibula to be on the posterior surface and on the medial crest. Mazenganya et al. [14] has reported the most common location to be on the posterior surface of fibula, followed by medial surface and then lateral surface of fibula. Nutrient foramen was most commonly located on the medial surface of fibula in the study by Forriol Campos et al. [12], and Sendemir and Cimen [13].

Mysorekar VR et al. [11] has reported the common location to be on the medial crest.

Ambekar SA et al. [9] has reported the nutrient

foramina to be located in the middle third of the fibula. Patel SM et al. [18] has reported the nutrient foramina to be in the middle third in 93.8% of fibulae and in 4.1% of fibulae the nutrient foramina were in the in the distal third. Mysorekar VR et al. [11] have reported the nutrient foramina to be directed downwards in fibula. It was directed downwards in all the nutrient foramina observed in fibula.

The nutrient artery should be preserved during tumour resection and fracture surgeries [21]. Accidental ligation of nutrient artery will decrease the blood supply to bones and may lead to malunion and non-union. Nutrient foramen appears linear in radiographs which can mimic a fracture.

The nutrient foramen is also considered as a potential area of weakness in some patients [22]. Longitudinal stress fractures associated with nutrient foramen are commonly seen in Tibia and have been reported to occur less frequently in femur, fibula and patella [7]. Fibula is commonly used for bone grafting. Hence location of nutrient foramen will help during bone transplantation surgeries.

CONCLUSION

The precise knowledge of the location, direction, number and size of the nutrient foramina of long bones of lower limb will help the orthopaedicians during fracture repair surgeries, tumour resection and also during bone grafting surgeries. The nutrient artery is essential to maintain the growth of osteophytes, hence the nutrient foramina should be preserved during tumour resection surgeries on the bones.

Conflicts of Interests: None

REFERENCES

- [1]. Pereira GM, Lopes PTC, Santos AMPV, Silvera FHS. Nutrient foramen in the upper and lower limb long bones: Morphometric study in bones of southern Brazilian adults. *Int J Morphol.* 2011;29:514-520.
- [2]. Lewis OJ. The blood supply of developing bones with special reference to the metaphysis. *J Bone Joint Surg.* 1953;35B(3):462-466.
- [3]. Trueta J. Blood supply and the rate of healing of the tibial fractures. *ClinOrthopRelat Res.* 1974;105:11-26.
- [4]. Sharma M, Prashar R, Sharma T, Wadhwa A, Kaur J. Morphological variations of nutrient foramina in lower limb long bones. *Int J Med and Dent Sci.* 2015;4(2):802- 808.
- [5]. Payton CG. The position of the nutrient foramen and direction of the nutrient canal in the long bones of the madder- fed pig. *J Anat.* 1934;68:500-510.
- [6]. Ebraheim NA, Elgafy H, Xu R. Bone – graft harvesting from iliac and fibular donor sites: Techniques and complications. *J Amer Acad Orthop Surg.* 2001;9:210-218.
- [7]. Craig JG, Widman D, Van Holsbeek M. Longitudinal stress fracture: patterns of edema and the importance of the nutrient foramen. *Skeletal Radiol.* 2003;32:22-27.
- [8]. Longia GS, Ajmani ML, Saxena SK, Thomas RJ. Study of diaphyseal nutrient foramina in human long bones. *Acta Anat (Basel).* 1980;107(4):399-406.
- [9]. Ambekar SA, Sukre SB. Diaphyseal nutrient foramen of lower limb long bones: Variations and importance. *Int J Anat Res.* 2016;4(3):2684-2688.
- [10]. Kizilkanat E, Boyan N, Ozashin ET, Soames R, Oguz O. Location, number and clinical significance of nutrient foramina in human long bones. *Ann Anat.* 2007;189(1):87- 95.
- [11]. Mysorekar VR. Diaphyseal nutrient foramina in human long bones. *J Anat.* 1967;101:813-822.
- [12]. Forriol Campos F, Gomez Pellico L, Gianonatti alias M, Fernandez –Valencia R. A study of the nutrient foramina in human long bones. *Surg Radiol Anat.* 1987;9:251-255.
- [13]. Sendermir E, Cimen A. Nutrient foramina in the shafts of lower limb bones: Situation and number. *Surg Radiol Anat.* 1991;13:105-108.
- [14]. Mazengenya P, Faremore MD. Morphometric studies of the nutrient foramen in lower limb long bones of adult black and white South Africans. *Eur J Anat.* 2015;19(2):155-163.
- [15]. Krischner MH, Menck J, Hennerbichler A, Gaber O, Hofmann GO. Importance of arterial blood supply to the femur and tibia for transplantation of vascularised femoral diaphyses and knee joints. *World JSurg.* 1998;22:845-852.
- [16]. Abledu JK, Offei EB, Osabutey CK. Reconstruction of femoral length from fragmentary femora. *Anat Cell Biol.* 2016;49:206-209.
- [17]. Lutken P. Investigation into the position of the nutrient foramina and the direction of the vessel canals in the shafts of humerus and femur in men. *Acta Anat.* 1950;9:57.
- [18]. Patel SM, Vora RK, Jotania BH. A study of Diaphyseal nutrient foramina in Human lower limb long bones. *Natl J Integr Res Med* 2015;6(3):14-18.
- [19]. Gupta RK, Kumari GA. A study of Diaphyseal nutrient foramina in Human Tibia. *National Journal of Medical Research.* 2014;4(4):310-313.
- [20]. Nagel A. The clinical significance of the nutrient artery. *Orthop Rev.* 1993;22:557-561.
- [21]. Udhaya K, Devi KV, Sridhar J. Analysis of nutrient foramen of Tibia-South Indian Population Study. *Int J Cur Res Rev* 2013;5(8):91-98.
- [22]. Saad J, Zrig A, Marrakchi F, Harbi F, Alghamdi S. Longitudinal stress fracture: Patterns of Edema and the importance of the nutrient foramen in MRI Evaluation. *European Society of radiology.* 2015;1-17.

How to cite this article: Kalyanasundaram Mohan, Backiaraj Devaraj, Shalini Ramanathan, Manoranjitham Rethinasamy, MORPHOMETRIC STUDY OF NUTRIENT FORAMEN IN THE LONG BONES OF LOWER LIMB. *Int J Anat Res* 2017;5(2.3):3943-3948. DOI: 10.16965/ijar.2017.225