

REVIEW

Thyroid papillary microcarcinoma: a descriptive and meta-analysis study

Elio Roti, Ettore C degli Uberti¹, Marta Bondanelli¹ and Lewis E Braverman²

Institute of Endocrinology, University of Milan, 20133 Milan, Italy, ¹Section of Endocrinology, Department of Biochemical Sciences and Advanced Therapies, University of Ferrara, 44100 Ferrara, Italy and ²Section of Endocrinology, Diabetes, and Nutrition, Boston Medical Center, Boston University School of Medicine, Boston, Massachusetts 02118, USA

(Correspondence should be addressed to E Roti; Email: elio.roti@unimi.it)

Abstract

The authors review anatomical, clinical characteristics and prevalence of thyroid microcarcinoma. Diagnostic procedures and risk factors of aggressiveness at diagnosis and during follow-up are also covered. The possible clinical, pathologic and therapeutic risk factors are analyzed by meta-analysis study. Treatment procedures by different authors and guidelines suggested by societies are reported.

European Journal of Endocrinology 159 659–673

Introduction

Thyroid microcarcinoma has been defined as thyroid cancer ≤ 10 mm in diameter, usually papillary (papillary thyroid microcarcinoma, PTMC) (1). In the past, the term occult thyroid carcinoma was used to define cancers with local metastases without a definite presurgical diagnosis and those detected at histologic examination. The diameter of these apparently unidentified thyroid cancers was set ≤ 15 mm (2). A recent study did not separate cancers with a diameter ≤ 10 mm from those with ≤ 15 mm, all defined as small papillary thyroid carcinomas (3).

However, in the present review, we will analyze some clinical and histological characteristics of PTMC (Table 1), mentioning some aspects of small thyroid carcinomas, when appropriate, for a more comprehensive evaluation. The uncertainty of the literature concerning the possible risk factors at diagnosis for recurrent disease as well as the treatment to adopt in patients with PTMC has led us to conduct the present review, including a meta-analysis of the clinical, pathologic, and therapeutic characteristics of PTMC related to cancer recurrence.

Selection of relevant studies for review

We have searched the key words 'thyroid microcarcinoma' and 'papillary microcarcinoma' on the electronic database Medline with a temporal limit, 1966–March, 2008. Through PubMed, 243 and 207 articles related to the former and latter keywords respectively have been retrieved. The former group of articles included, as well, all the articles related to the latter item 'papillary

microcarcinoma' except four articles. These four articles were not included in the present review: two articles were not related to thyroid pathology and two did not describe the characteristics of PTMC. Thus, 243 abstracts were read by two authors (ER, MB). These authors agreed to discard from the present analysis 22 articles of medullary carcinoma, 23 only dealing with histological aspects, 23 with immunochemistry, 7 related to surgical technique only, 21 editorials/reviews, 53 case reports/letters, 15 discussing cancer in general, and 3 because the abstracts were not reported or insufficient for evaluation. Articles from the same group of authors updating their series of PTMC were reported once or pooled, as appropriate. To describe the general characteristics of PTMC, 76 articles were examined.

For analyzing the risk factors for recurrence, we further restricted the selection to articles in English and Italian, each article containing a number of cases > 35 and reporting data on PTMC recurrence and possible risk factors for tumor recurrence, such as age, sex, discover modality, tumor size and extension, lymph node involvement at diagnosis, distant metastases at diagnosis, type of surgery, and ablative ¹³¹I-iodine therapy. Thus, in total, 17 articles met the inclusion/exclusion criteria for the meta-analysis study.

Data pooling and statistics

The primary analysis consisted in evaluating an effect size for each of the studies by calculating the odds ratio (OR) for dichotomous events. The effect sizes of all trials were tested for heterogeneity using the Q statistics, which were an adaptation of the χ^2 goodness-of-fit test. The OR was the ratio across different groups for the odds

Table 1 Some clinical and pathologic characteristics of papillary thyroid microcarcinoma (PTMC).

		Reference nos
Size	≤10 mm	(1)
Mean size (range)	4.1–8	(4–26)
Papillary type (range)	65–99%	(5, 9, 10, 15, 17, 18, 24, 30–32)
Age (years; range)	41.9–55	(4–6, 8–12, 15–26, 30, 34, 38–55)
Sex F/M ratio	4.8/1	(4–6, 8, 10, 12, 15–19, 21, 25, 30–32, 34, 38–42, 44–47, 49, 50, 52–57)
Autopsy prevalence	> 35.6%	(29)
Clinical prevalence	> 95.3% of all cancers	(23)
Incidental prevalence	> 100% of all PTMC	(7)

Range values refer to the results of different studies.

that the event would occur. A 95% confidence interval (CI) was constructed around the effect size to establish its significance. If the 95% CI of an OR included 1, the two groups were not considered statistically different. Statistical analysis was performed using the Comprehensive Meta-analysis software (v. 2.0, Biostat, Englewood, NJ, USA). A *P* value less than 0.05 was considered statistically significant.

Size

The diameter of PTMC is more than 5 mm in 35.2–79% of the cases, with a median size in each study ranging from 4.1 to 8 mm in diameter (4–26). In some patients, cancers as small as 1 mm in diameter have been diagnosed (4, 5, 9, 27).

An autopsy study on survivors of the atomic bomb in Hiroshima and Nagasaki, revealed that among 2035 thyroid glands examined, 141 harbored a papillary cancer <1.0 mm in diameter (28). In Finland, an autopsy study found that the size of occult papillary carcinoma was <1.0 mm in diameter in 77% of the cases (29). Another autopsy study of thyroid glands collected in different geographical areas of the world reported that thyroid microcarcinomas 1–3 mm in diameter were more prevalent than those 3–9 and 10–15 mm in diameter, 50.4, 27.3 and 3.6% respectively, suggesting an arrest of the growth of PTMC (30).

Histology

Thyroid microcarcinoma is most often papillary, 65–99% of the cases (5, 9, 10, 15, 17, 18, 24, 30–32). The follicular variant of papillary thyroid cancer has been observed in 9.7 (30), 13.1 (9) and 31% (15) of the cases and follicular cancer has been found in 0.3–23.6% of the cases (5, 9, 10, 17, 18, 24, 30–34). This latter finding is in agreement with the observation that 11% of follicular cancers are ≤10 mm in diameter (35). The more virulent oncocytic and tall cell variants of PTMC have been observed, with a prevalence of 0.8% of the cases (9). The sclerosing variant has been found in 5–11.7% of thyroid carcinomas with a diameter ≤10 mm (9, 24) and in only 1.1% of cancers with a diameter of 11–20 mm (36).

The decreased prevalence of the sclerosing variant with the larger tumors might indicate, as suggested by Fukunaga & Yatani (37), that the sclerosing is a defensive mechanism preventing tumor growth. Also, a recent study (3) confirmed that the sclerosing variant is more frequent in cancers ≤10 mm in diameter than those with a diameter of 1.1–1.5 mm (*P* < 0.015). However, in patients with smaller cancers, the prevalence of distant metastases was increased compared with those of larger cancers.

Age at the time of the diagnosis PTMC

The mean age at diagnosis of patients with thyroid microcarcinoma has been reported by different studies to be 41.9–55 years (4–6, 8–12, 15–26, 30, 31, 34, 38–53) with a range of 4–85 years (4–6, 8, 11, 12, 15, 17–20, 24, 30, 31, 34, 38, 39, 42, 44–46, 48, 51, 53). The age range of larger thyroid cancers ≤15 mm in diameter at diagnosis did not change, 13–79 years with a median value of 41.9 years (3). Two studies reported that 25.9 and 52.8% of cases of thyroid microcarcinoma occurred in patients older than 45 years (54, 55). Autopsy studies demonstrated that thyroid microcarcinomas occurred at the same rate in each decade in adults (29, 37, 56, 57). In only one study, patients with thyroid microcarcinoma with metastases had a mean age higher than those without metastases, 54 ± 16.9 and 37.7 ± 12.3 years respectively (58).

Sex

Combining the results of different studies, among 6653 patients with thyroid microcarcinoma, 5516 (82.9%) were women and 1137 (17%) were men with a ratio of 4.85/1 (4–6, 8, 10, 12, 15–19, 21, 25, 30–32, 34, 38–42, 44–47, 49, 50, 52–55). Similarly, in patients with small thyroid carcinomas, ≤15 mm in diameter, 85% were women and 15% were men (3). This striking sex difference was not observed in autopsy studies. Among 198 cases of microcarcinoma, 109 (55%) were men and 89 (45%) were women (29, 37, 56, 59). In a single study describing 141 cases of thyroid microcarcinoma <10 mm in diameter, 82 (58%) were men and 59 (42%) were women (28). It is likely that the

higher prevalence of thyroid microcarcinoma in living women may be due to their higher prevalence of thyroid disease and, therefore, greater access to diagnostic procedures resulting in increased identification of PTMC.

Familial prevalence of PTMC

PTMC has been reported in members of the same family. Lupoli *et al.* (60) reported seven familial cases out of 119 patients with PTMC. Pellegriti *et al.* (3) observed 18 familial cases among 299 small papillary thyroid cancers (size ≤ 15 mm in diameter); of these, 10 were true microcarcinomas. Roti *et al.* (12) reported 13 familial cases in their series of 243 PTMC patients. Thus, familial cases of PTMC have an overall prevalence of 4.5%. Similarly, 5–10% of all thyroid carcinoma are familial (61). Familial cases of PTMC have occasionally been reported (62, 63). One study reported that familial PTMC are more aggressive than the nonhereditary types (60). However, this finding was not confirmed by others (3, 12) likely due to the fact that familial papillary thyroid carcinoma (PTC) consists of different syndromes with heterogeneous genetic susceptibility to thyroid cancer (61).

Molecular events in PTMC

Papillary carcinomas frequently harbor activating mutations of genes coding for proteins that signal along the MAP kinase pathway.

It has been reported that RET/PTC rearrangement is present not only in large papillary thyroid cancers but also in micropapillary thyroid carcinoma in up to 52% of the cases (64–66), but this finding does not seem to be a sign of cancer aggressiveness (67). In contrast, RET/PTC3-positive papillary thyroid carcinoma has a more aggressive behavior (68). BRAF mutations may occur in papillary thyroid carcinoma and have also been reported in PTMC (65, 69–71). Furthermore, it has recently been reported that BRAF mutations enhance the capacity of BRAF mutated cells to proliferate and transform (72). It has also been suggested that lymph node metastases of papillary cancer are accompanied by a new BRAF mutation, different from that observed in the matched primary thyroid cancer, confirming the progression model of cancer where metastatic foci have a new mutational event (73). These results suggesting that PTMC harboring an activating mutation of the gene for BRAF might have a more aggressive behavior have not been confirmed by another study in Korean patients (74).

Prevalence

Autopsy prevalence

The autopsy prevalence of thyroid microcarcinoma is largely ranging between 0.01% in USA (37) and 35.6% in

Finland (29), the highest value reported in the literature. This striking difference may be due to genetic and environmental factors and to the methods employed in the histologic examination of the thyroid gland.

An elevated prevalence of thyroid microcarcinoma has consistently been observed in the Japanese population, 13.7–28.4% (37, 75–78). This may be related to radiation exposure during the bombing of Hiroshima and Nagasaki, but is probably due to ethnicity since Japanese residing in Hawaii, not exposed to bomb radiation, have a similar prevalence of thyroid microcarcinoma, 24% (37, 79). In 4620 autopsy cases, PTMC was observed in 9.9% when only a suspected lesion was examined and in 15.5% of 1262 autopsy cases when the entire gland was examined (13, 29, 37, 59, 75, 76, 80–85). Therefore, the prevalence of occult thyroid microcarcinoma increases with the extent of the examination of the thyroid, in particular with the thinness of the anatomical slices of the thyroid specimens (29).

Iodine intake has been suggested as a possible factor affecting the prevalence of thyroid cancer (86). In a single ethnic group, it has been observed that the autopsy prevalence of PTMC was not affected by iodine intake (80).

Clinical prevalence

The prevalence of thyroid nodules is variable in different populations and within the same population. In the USA, the prevalence of nodules detected by ultrasound examination (US) varies between 13 and 67% (86). US diagnosed nodules with a diameter of 0.5–1.0 cm have been found in 10% of the population of Germany (87). Tan *et al.* (88) reported that 48% of patients with a palpable nodule had more than one nodule detected by US examination and, in these patients, 72% of the nodules had a diameter of ≤ 1 cm. Similar results have been reported by others (89, 90). Obviously, the increased accuracy in the clinical and laboratory evaluation since the introduction of US-guided fine needle aspiration biopsy (FNAB) of patients with suspected thyroid diseases has led to a dramatic increase in the incidence of thyroid cancer. Recently, it has been reported that the prevalence of PTMC is 1.24% in 8203 patients who underwent FNAB (21). In France, during the last two decades, the prevalence of PTMC among all thyroid cancers increased from 18.4 (1983–1987) to 43.1% (1998–2001) (91). The Geneva Cancer Registry showed an increase in PTMC/all papillary thyroid cancers from 17 to 24% in 1970–1974 and 1995–1998 respectively (92). In the USA, the incidence of PTMC has consistently increased over the course of years; in 1968, PTMC had an incidence of 1.5 per 100 000, whereas in 2002 it was ~ 3.5 per 100 000 subjects, accounting for 49% of all thyroid cancers (93). Similarly, in Tasmania, the prevalence of PTMC among all thyroid cancers almost doubled during 1992–1998 in comparison with 1978–1984 (94). In Hong Kong, the

proportion of PTMC among all differentiated thyroid cancers was 5.1% before 1980, 16.1% during 1981–1990, and 21.7% during 1991–2000 (95). In Table 2, we report the prevalence of PTMC in patients with different thyroid diseases (6, 10–12, 15–17, 20, 23, 31, 38, 43, 45, 46, 49, 50, 52, 54, 55, 96–118). As shown, PTMC accounts for approximately a quarter of thyroid malignant diseases. Furthermore, it has been reported that 14.2% of 551 patients operated upon for thyroid papillary carcinoma had a cancer ≤ 5 mm (119, 122).

Thus, the increased prevalence of PTMC at surgery reflects the prevalence of occult thyroid carcinoma in autopsy series.

Incidental prevalence

PTMC is often diagnosed during thyroidectomy for benign thyroid and parathyroid diseases. The results of different studies of 5035 patients with PTMC, demonstrated that 71% were incidentally discovered at surgery for other thyroid disorders (4–7, 11–15, 18, 23–27, 32, 43, 44, 46, 49, 96–99, 102, 103, 112–116, 118, 119–125). The prevalence of incidental cases of PTMC is very variable ranging in large series between 4.6 (23) and 100% (7). Even in the same institution, the prevalence of incidental PTMC varied at different periods of time from 10.9 to 55.4% (9, 55, 123, 126). Recent studies reported a prevalence of incidental PTMC ranging from 3.1% in 385 (121) to 21% in 386 patients (99) operated upon for benign diseases of the thyroid. In multinodular goiter/nodules, PTMC has been observed in 2–15.2% of the cases (96, 125). In patients operated upon for nodules measuring > 1 and > 4 cm in diameter, the presence of PTMC occurred in 3.1 and 15.2% of the cases respectively (120, 125). The different results in the prevalence of incidental PTMC are likely due to the variable use and expertise in the use of US and US-guided FNAB.

Diagnosis of PTMC

The use of US examination of the thyroid gland has greatly increased the number of small benign and malignant nodules diagnosed before surgery. Some US nodule characteristics appear suspicious for malignancy. Microcalcifications within malignant nodules

have been observed in many studies (76, 127–130) and were present in 7.1–59% of patients with PTMC (76, 127–131). Irregular margins of the nodules have been observed in 21.5–77% of PTMC (11, 127, 130, 133). A taller-than wider dimension and antero-posterior diameter larger than the transverse diameter of non-palpable thyroid nodules have also been suggested as a diagnostic feature for the presence of malignancy (76, 101). An increase in the size of small thyroid nodules at US follow-up was not a reliable marker in the differential diagnosis between malignant and benign nodules (132). In one study, US examination of the thyroid led to a correct preoperative diagnosis in 20 out of 36 PTMC patients (110).

US-guided FNAB is a very accurate diagnostic procedure in evaluating patients with thyroid nodules ≤ 10 mm in diameter. Under US guidance, sufficient cytological material has been obtained from nodules as small as 2 mm in diameter (53). Inadequate cytologic samples obtained by US-guided FNAB in nonpalpable nodules was $\sim 18.5\%$ of all cases (127, 133, 134) and 22.5 and 33% in nodules ≤ 10 mm (127, 130, 135, 138). To our knowledge, no systematic studies have been conducted to evaluate the diagnostic precision of FNAB in nodules with a diameter ≤ 10 mm. PTMC was detected in 12 (9.2%) out of 131 nodules that are 8–10 mm in diameter (127) and in 24 (13.5%) out of 178 nodules that are 2–10 mm in diameter (135). US-guided FNAB is performed in patients with small nodules with variable frequency, primarily due to the decision of the physician and to patient preference. The American Thyroid Association (ATA) (136) and the American Association of Clinical Endocrinologists (AACE) (137) suggested that nodules ≤ 10 mm should be examined by US-guided FNAB only in the presence of suspicious features at US examination, a history of neck irradiation and a positive family history of thyroid cancer. The guidelines of the Society of Radiologists in Ultrasound (138) recommended that only nodules with a diameter of at least 10 mm with microcalcifications should undergo FNAB.

It has been reported that the presence of malignancy was not different between nodules with a diameter of 8–10 and 11–15 mm (127) and that the risk of malignancy was not significantly increased by the presence of more than one nodule (127). This finding

Table 2 Prevalence of papillary thyroid microcarcinoma (PTMC) among malignant and benign thyroid diseases in different studies.

	PTMC (%)	Reference nos
Papillary thyroid cancer (10 981)	28.8	(10, 11, 15, 16, 20, 23, 31, 38, 50, 54, 55, 99–105)
Differentiated thyroid cancer (4776)	24.8	(52, 105–111)
All thyroid cancer (10 628)	22.9	(13, 17, 43, 45, 50, 99, 100, 112–114)
Nodular goiter/nodule (2157)	7.7	(13, 26, 43, 99, 118, 120)
Graves'/hyperthyroidism (1789)	4.1	(105, 115, 117)
All thyroidectomy (10 422)	3.8	(46, 49, 101, 116, 119)

The prevalence of PTMC has been calculated as the mean of the percentage values in different studies (Reference nos). In parenthesis are reported the sum of cases of the different thyroid conditions in the studies indicating the prevalence of PTMC.

is similar to that observed in patients with larger nodules (138).

Thyroid scans should not be used in the diagnostic work up of PTMC, since it does not have sufficient sensitivity and specificity in detecting small cancers (<1.5 cm) (139). PET imaging with [18F] fluorodeoxyglucose failed to detect extrathyroid invasion in patients with PTMC (140).

Clinical and pathologic characteristics of PTMC at diagnosis

The clinical and pathologic characteristics of PTMC at the time of diagnosis are variable in different studies. Bilateral and multiple foci have been observed in 2.9 (125) to 48% (26) and 7.1 (14) to 56.8% (104) respectively. The prevalence of extracapsular invasion and lymph node metastasis at diagnosis ranged between 2 (4) and 62.1% (112) and 0 (113) and 64% (8) respectively. In one study, it was reported that lymph node metastases were present in 40.5% of patients with microcarcinoma, even though the patients were diagnosed as node negative before surgery (141).

Distant metastases at diagnosis have rarely been observed in patients with PTMC, occurring in only 35 cases (0.37%) of 9313 patients described in different studies published between 1966 and 2008 (3–8, 10–12, 13–18, 20, 21, 23–27, 30, 31, 34, 38–40, 42, 45–52, 58, 98, 103, 109, 112–114, 116, 121, 123–125, 141–143). In one study, multifocality, extrathyroidal extension, and lymph node metastasis at diagnosis were similarly prevalent in patients with PTMC and in those with larger papillary thyroid carcinomas (21). In three studies (5, 12, 130), the clinical and histologic characteristics of incidental and nonincidental PTMC were compared. It was observed that the prevalence of multifocality/bilaterality, extracapsular invasion, and lymph node metastases at diagnosis were more frequent in patients with nonincidental PTMC. Furthermore, distant metastases at diagnosis were observed in only 9 cases out of 283 nonincidental and in 3 out of 241 incidental PTMC (5, 12).

Risk factors for the presence of lymph node metastases at diagnosis

Some studies have identified risk factors for the presence of lymph node metastases at diagnosis. Nonincidental PTMC appears to have a higher risk for lymph node metastases at diagnosis (12, 131). Lymph node metastases were more frequent in patients with larger PTMC, >5 (8, 144) and >8 mm (12). Lymph node metastases and extrathyroid extension were observed in only 4.4 and 25.7%, respectively, of patients with PTMC ≤5 mm in diameter (42). The follicular variant of PTMC and extracapsular invasion were associated with a higher prevalence of lymph node metastases (12).

The presence of Hashimoto's thyroiditis appeared to be protective for the presence of lymph node metastases at diagnosis (12). Recently, it has been reported that the absence of epidermal growth factor receptor expression was positively correlated with the presence of lymph node metastases (23). Some studies evaluated whether the expression of cyclin D1 and galectin-3 in PTMC could be a marker of lymph node metastases (145–147). Overexpression of cyclin D1 was present in PTMC with lymph node metastases. However, similar results were observed in patients without lymph node metastases (148). Similarly, the expression of galectin in PTMC was not significantly correlated with the presence of lymph node metastases (148, 149).

Risk factors for the presence of distant metastases at diagnosis

Distant metastases at diagnosis are a rare event. Therefore, only few studies have statistically analyzed possible risk factors. Distant metastases at diagnosis correlated positively with the diameter of PTMC ($P \leq 0.05$) (12), advancing age ($P \leq 0.01$), lymph node metastasis at diagnosis ($P < 0.01$), and follicular variant of PTMC ($P < 0.008$) (58). In one study, it was observed that all patients with distant metastases had lymph node invasion at diagnosis (5).

Treatment of PTMC

Surgical procedures

Surgical procedures in patients with PTMC were extremely different among the studies. Total/near total thyroidectomy was carried out in 100% of the cases in 17 (11, 12, 14, 15, 18, 24, 26, 27, 39, 46, 49, 52, 97, 104, 106, 117, 150) out of 44 studies that reported the type of surgery (4–6, 8, 11, 12, 14–18, 20, 23–27, 30–32, 34, 38–40, 42, 45, 46, 48–50, 58, 97, 98, 104–106, 114, 117, 121, 123, 124, 143, 148, 150). Combining the results of different studies that clearly reported the extent of surgery in 9259 patients with PTMC, total/near total thyroidectomy was performed in the 72%, subtotal thyroidectomy in the 11% and lobectomy in the 17% of the cases (4–6, 8, 11, 12, 14–18, 20, 23–27, 30–32, 34, 38–40, 42, 45, 46, 48–50, 58, 97, 98, 104–106, 114, 117, 121, 123, 124, 143, 148, 150). In these studies, therapeutic lymph node excision was carried out in an extremely variable proportion of patients, ranging from 0 to 46.9% of the cases, with a mean value of 9.8%, whereas prophylactic lymph node excision was performed in 11 studies (4–8, 17, 30, 34, 39, 48, 148) with a mean value of 55.7% of the patients. The presence of metastases in the excised nodes was found in 1104 (58%) out of 1895 cases (3, 5, 7, 8, 12, 22, 30, 41, 42, 56).

Table 3 Characteristics of the studies included in the meta-analysis on possible risk factors for recurrence of thyroid papillary microcarcinoma.

Authors	No of patients (M/F)	Age (yr)	Period of study (yr)	Mean follow-up (yr or mo; range)	Lymph node metastases at diagnosis (no)	Distant metastases at diagnosis (no)	Locoregional recurrence (no)	Distant recurrence (no)	Total recurrence (no)
Besic <i>et al.</i> 2008 (152)	228 (39/189)	14–85	1975–2006	84 mo (1–385)	56	0	6	1	7
Baudin <i>et al.</i> 1998 (5)	273 (69/204)	6–65	1962–1995	7.3 yr (0.6–33.7)	121	3	11	1	11
Sugitani <i>et al.</i> 1998 (51)	190		1976–1996	8 yr (2–21)	34	0	11	4	
Roti <i>et al.</i> 2006 (12)	243 (46/197)	16–85	1993–2002	4.4 yr (2.4–10.6)	32	4	4	0	4
Pelizzo <i>et al.</i> 2006 (55)	403 (66/337)		1990–2004	8.5 yr (9 mo–14 yr)	47	1	6	1 (+)	24 ^a
Lo <i>et al.</i> 2006 (20)	185 (37/148)	11–84	1964–2003	8.2 yr (0.1–38)	43	3	NR	NR	13 (+ 4 died of disease)
Küçük <i>et al.</i> 2007 (22)	120 (15/105)	17–67	1997–2005	45 mo (16–86)	7	0	2	0	2
Ito <i>et al.</i> 2004 (48)	590 (38/552)	18–83	1993–2003	(0–140 mo)	67	NR	10	NR	
Ito <i>et al.</i> 2003 (41)	626 (39/587)	16–83	1993–2003	48.7 mo (0–120)	300	0	16	0	16
Rodríguez <i>et al.</i> 1997 (31)	36 (6/30)	4–65	1970–1990	7 yr	6 ?	0	3	0	3
Appetecchia <i>et al.</i> 2002 (40)	120 (24/96)	23–77	NR	8 yr (5–15)	26	0	2	0	2
Chow <i>et al.</i> 2003 (42)	203 (27/176)	7.7–77.2	1960–1999	8.4 yr	50	4	12	4	
Wada <i>et al.</i> 2003 (8)	259 (29/230)	17–72	1988–1998	61.6 mo (13–144)	93	0	7	0	7
Gülben <i>et al.</i> 2008 (151)	81 (15/66)	16–61	1990–2003	7 yr (28–192)	10	0	1	0	1
Schönberger <i>et al.</i> 2007 (25)	67 (19/48)	22–88	1993–2003	55.5 mo (14–169)	10	2	1	2 ^b	1
Yamashita <i>et al.</i> 1999 ^c (7)	1743 (186/1557)		1970–1994	11.2	202	0	35	5	31
Monacelli <i>et al.</i> 2006 ^c (18)	74 (16/58)	24–73	2001–2004		6	0	4	0	4

6 ?, six patients presented with enlarged cervical lymph node without a palpable lesion, histology of these lymph node has not been specified. NR, not reported; mo, months; yr, years.

^aLiving with disease: 24 patients with increased serum thyroglobulin levels; during follow-up, six of these patients experienced locoregional macroscopic recurrent disease. Moreover, one patient (+) was deceased due to metastatic thyroid cancer.

^bThese patients had distant metastases also at diagnosis.

^cThese studies also included some follicular and/or medullary thyroid microcarcinomas.

¹³¹I treatment following thyroidectomy

¹³¹I treatment following surgical treatment was done in some studies (4, 5, 12, 16, 20, 25, 22, 26, 39, 40, 45, 50, 97, 98, 106, 123, 124, 142, 143) with a variable proportion of patients, 10.3 (4) to 100% (22, 106). In total, 1594 (17%) out of 9379 patients were treated with ¹³¹I.

L-T₄ (L-thyroxine) treatment following thyroidectomy

Many studies on PTMC failed to mention whether L-T₄ was given after surgery. However, it seems likely that L-T₄ therapy was administered in patients with extensive thyroidectomy. In some studies (3, 8, 12, 21, 32, 38, 39, 55, 142), suppressive doses of L-T₄ were recommended in patients operated upon for PTMC, but in one study it was discontinued within several years (30). L-T₄ suppressive therapy was prescribed in 95.8% of patients who underwent prophylactic lymph node excision, 87.2% of patients who had therapeutic lymph node excision and 47.1% of those who did not have lymph node excision (8). Another study reported that either suppressive or substitutive L-T₄ therapy was recommended for an unknown period of time and later substitutive therapy only (42). Finally, substitutive L-T₄ therapy was the treatment of choice in some patients with PTMC (26, 27, 42).

Follow-up

Recurrence

One study has provided information on the natural course of PTMC (41). In this study, it was observed that in 162 patients with PTMC who did not undergo surgical excision, cancer size increased in 27.5%, decreased in 12.1%, and remained stable in 60.3%,

and lymph-node metastases were diagnosed in 5.5% of the cases over 5 years of follow-up (41).

Local/lymph node recurrent disease has been observed with variable prevalence, with values ranging between 0.3 and 37% (97, 104). Combining the results of different studies, local/lymph node recurrence has been observed in 231 (2.4%) out of 9379 patients (4–6, 8, 11, 12, 14–18, 20, 22, 23–27, 30–32, 34, 38–40, 42, 45, 46, 48–50, 58, 97, 98, 104–106, 114, 117, 121, 123, 124, 143, 148, 150). In these studies, distant metastases were clearly reported in 26 cases (4, 16, 20, 30, 34, 42, 48, 51, 58, 105) corresponding to 0.27% of 9379 cases (4–6, 8, 11, 12, 14–18, 20, 22, 23–27, 30–32, 34, 38–40, 42, 45, 46, 48–50, 58, 97, 98, 104–106, 114, 117, 121, 123, 124, 143, 148, 150).

Mortality

Cancer-related death has rarely been reported in patients with PTMC, 32 (0.34%) of 9379 patients (4–6, 8, 11, 12, 14–18, 20, 22, 23–27, 30–32, 34, 38–40, 42, 45, 46, 48–50, 58, 97, 98, 104–106, 114, 117, 121, 123, 124, 143, 148, 150).

Risk factors for recurrence and mortality

In the present study, possible risk factors at diagnosis for recurrent disease have been studied by meta-analysis. Table 3 reports the studies utilized for the analysis; the studies by Gülben *et al.* (151) and Besic *et al.* (152) were not included since we had direct access to the full text after the calculations of our study were completed.

Recurrence was not statistically related to gender. In contrast, younger age (<45 years) was significantly ($P < 0.04$) associated with cancer recurrence (Fig. 1). Also, clinically overt cancer was significantly related ($P < 0.001$) to recurrence (Fig. 2). Among the pathologic characteristics of PTMC, cancer size was not associated with recurrence. In contrast, cancer multifocality (Fig. 3) and lymph node involvement at diagnosis

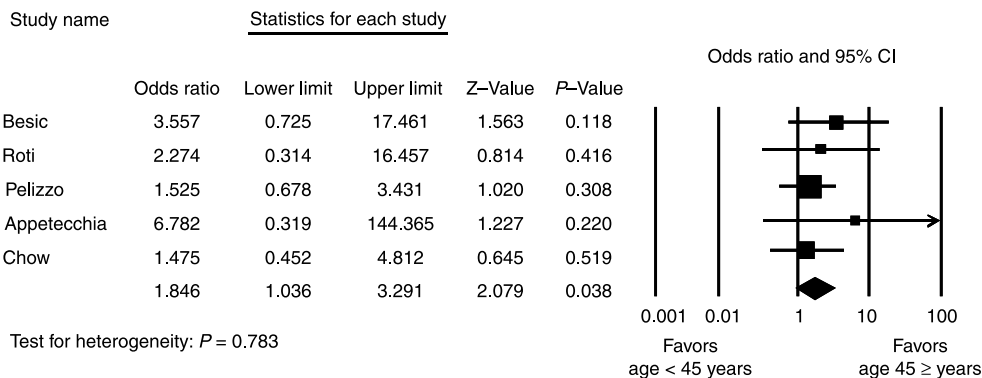


Figure 1 Pooled data for the association of tumor recurrence and age. OR in patients aged <45 years was 1.846 (95% CI 1.036–3.291; $P = 0.038$). There was no statistical heterogeneity ($P = 0.783$). Tumor recurrence was significantly associated to younger age (<45 years).

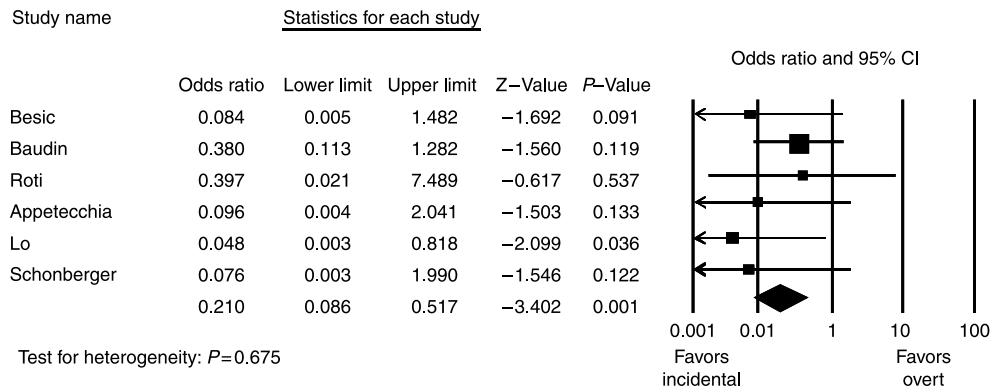


Figure 2 Pooled data for the association of tumor recurrence and modality of diagnosis. OR in incidentally discovered tumors was 0.210 (95% CI 0.086–0.517; $P=0.001$). There was no statistical heterogeneity ($P=0.675$). Tumor recurrence was significantly higher in patients with overt tumors.

(Fig. 4) were highly significantly ($P<0.000$) associated with recurrence. The presence of extrathyroid extension was not related to cancer progression. The presence of distant metastases at diagnosis suggests a higher cancer recurrence rate; however, in this analysis, some patients had only persistent disease rather than new metastases (Fig. 5). Among the therapeutic option for treatment of PTMC, we found that patients who had total/near total thyroidectomy, as well those with lymph node excision had a lower cancer recurrence rate, but these values were not statistically significant because of the heterogeneity of the data. Again, ^{131}I treatment was not associated with progression of the disease.

Analyzing different studies (4, 30, 34, 42, 55, 153), a total of 14 patients with PTMC died, of whom 11 had extensive thyroidectomy and the other 3 had partial thyroidectomy.

Guidelines for the treatment of PTMC

Specific recommendations for the treatment of patients with PTMC have been published by some Scientific Societies. The ATA (136) recommends that total/near total thyroidectomy should be performed in patients with thyroid cancer of > 1.5 cm in diameter. In patients with small, low-risk, isolated, intrathyroidal papillary carcinomas in the absence of cervical nodal metastases, thyroid lobectomy may be sufficient treatment. The presence of positive contralateral thyroid nodules or regional or distant metastases, if the patient has a history of radiation therapy to the head and neck or a first-degree member with differentiated thyroid cancer or older than 45 years of age, near-total or total thyroidectomy is the treatment of choice for PTMC. The European Thyroid Association (ETA) (154) and the British Thyroid

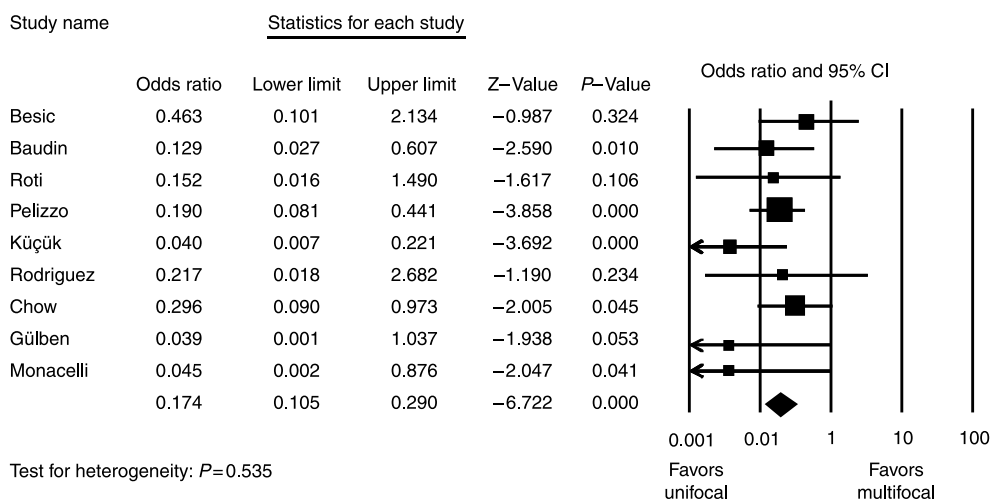


Figure 3 Pooled data for the association of tumor recurrence and tumor focality at diagnosis. OR in patients with unifocal tumor was 0.174 (95% CI 0.105–0.290; $P=0.000$). There was no statistical heterogeneity ($P=0.535$). Positive association was found between tumor recurrence and multifocal tumors at diagnosis.

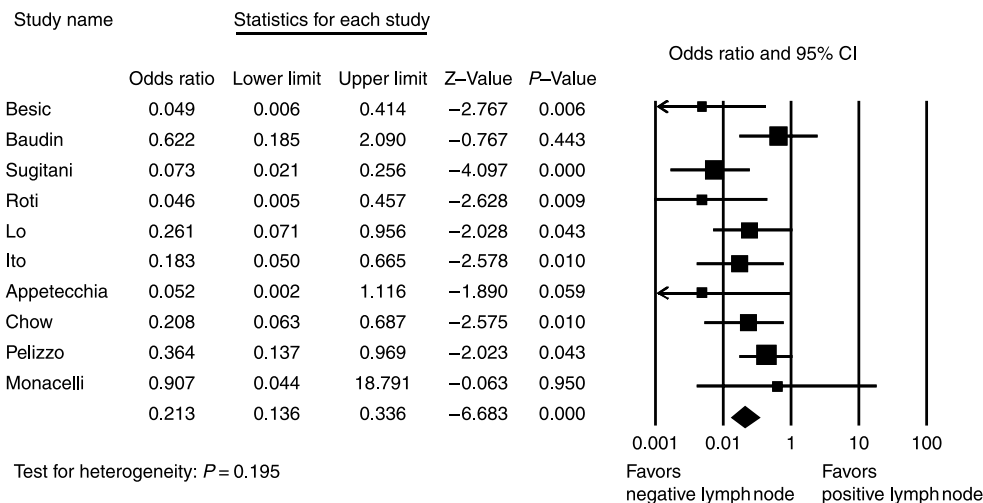


Figure 4 Pooled data for the association of tumor recurrence and positive lymph node at diagnosis. OR in patients with no lymph node involvement at diagnosis was 0.213 (95% CI 0.136–0.336; $P=0.000$). There was no statistical heterogeneity ($P=0.195$). Positive association was found between tumor recurrence and lymph node involvement at diagnosis.

Association (BTA) (155) recommend partial thyroidectomy and lobectomy respectively, in the presence of PTMC NOM0 without a history of neck irradiation. The AACE (137) suggests that lobectomy plus isthmectomy is the surgical procedure of choice in cases of PTMC without evidence of lymph node involvement.

¹³¹I treatment, according to the ATA guidelines (136), is indicated in patients with PTMC (any N, M1) younger than 45 years (stage II disease) and in patients older than 45 years, N1a,Mo (stage III) and N1b, Mo (stage IVa) and any N,M1 (stage IVc), according to the TNM 6th edition classification for differentiated thyroid carcinoma (156). The ETA recommendations (154) state that patients with unifocal microcarcinoma (≤ 1 cm) with no extension beyond the thyroid capsule and without lymph node metastases will not benefit from postoperative ¹³¹I treatment. Also, in patients with documented persistent disease or at high risk of persistent or recurrent post-operative disease, ¹³¹I treatment reduces the recurrence rate and possibly prolongs survival (154). The BTA (155)

recommends ¹³¹I treatment in patients with a tumor size > 1 cm in diameter.

Suppressive or substitutive L-T₄ treatment in patients with PTMC has not been clearly stated by the different Societies. The ATA (136) recommends that low-risk patients, a category that includes the majority of PTMC, be treated with L-T₄ to reach serum thyroid stimulating hormone (TSH) concentrations = 0.1 mU/l in the early follow-up period; for maintenance treatment, the goal is to have serum TSH values 0.1–0.5 mU/l and in the long-term follow-up of patients free of disease and low-risk at diagnosis, a serum TSH concentration of 0.3–2.0 mU/l is recommended. In contrast, the BTA recommends TSH-suppressive doses of L-T₄ for patients with PTMC < 1 cm in diameter and negative nodes treated by a lobectomy (155). These recommendations seem acceptable for the large majority of patients with PTMC. A recent Belgian survey conducted among the members of the Belgian Thyroid Club (157) found that in the case of nodules 0.9 cm in diameter, suspicious of PTC by FNA

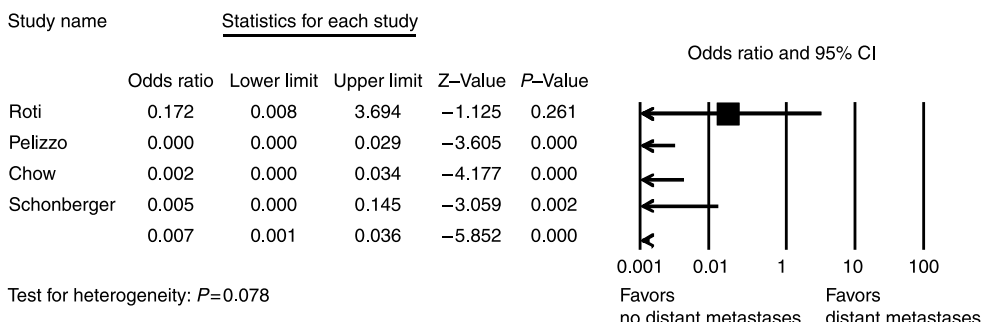


Figure 5 Pooled data for the association of tumor recurrence and distant metastases at diagnosis. OR in patients with distant metastases at diagnosis was 0.007 (95% CI 0.001–0.036; $P<0.0000$). There was no statistical heterogeneity ($P=0.078$). Positive association was found between tumor recurrence and presence of distant metastases at diagnosis. Please note that some patients had persistent rather than recurrent disease.

without lymph node enlargement, 41% of the respondents favored a total thyroidectomy and 37% a total thyroidectomy with lymph node dissection; only 17% favored lobectomy. This study indicates that the large majority of Belgian endocrinologists did not follow the American, European, or BTA recommendations (136, 154, 155). Similarly, Mazzaferri (158) recently recommended total or near total thyroidectomy for preoperatively diagnosed low-risk PTMC.

Recently, Jonklaas *et al.* (159) reported no impact, positive or negative, of total/near total thyroidectomy, radioactive iodine treatment and L-T₄ suppressive therapy in patients with stage I differentiated thyroid carcinoma. The large majority of patients with PTMC are stage I. However, the same study showed that the above-mentioned specific therapies were beneficial in stage III patients. We have recently observed (36) that 17% of patients with PTMC were classified as stage III, according to the TNM 6th edition classification (105). Similarly, Cappelli *et al.* (21) reported that 15.7% of PTMC were stage III cancers. At present, it is not possible to discriminate patients with aggressive PTMC from those with an indolent clinical course. Future prospective studies carried out according to the recommendations of the above-mentioned Societies might determine the adequate treatment for patients with PTMC. After the completion of this manuscript, Pacini's group published a review on the same topic (160). However, we have added to the description of clinical and pathologic characteristics of PTMC a meta-analysis study of the risk factors for recurrence.

In conclusion, PTMC is diagnosed with increased frequency, mainly due to the widespread use of ultrasound-guided FNAB, and an increased percentage of all thyroid cancers are PTMC.

The diagnosis and treatment reported in the different studies are, in general, increased in contrast to the guidelines suggested by some Scientific Societies; in some studies, a more aggressive treatment than that recommended has been adopted. In the present study, a meta-analysis showed some clinical and pathologic characteristics associated with increased aggressiveness. Probably, a more aggressive treatment should be reserved to PTMC showing these characteristics. Despite the increased prevalence of PTMC, thyroid cancer-related mortality did not change over the years (93). This finding suggests that PTMC has, in general, a benign clinical course; therefore, increasingly sophisticated diagnostic procedures and aggressive treatment procedures appear unnecessary. However, the scientific perception and the patient perception of the problem are different.

Declaration of interest

The authors declare that there is no conflict of interest that would prejudice the impartiality of this scientific work.

Funding

Grant support: This work was supported by grants from the Italian Ministry of University and Scientific and Technological Research (MIUR 2005060839-004), Fondazione Cassa di Risparmio di Ferrara, and Associazione Ferrarese dell'Iperensione Arteriosa to the University of Ferrara. It was also supported by NIH grant 5K23DK4611.

References

- Lloyd R, De Lellis R, Heitz P & Eng C. *World Health Organization Classification of Tumours: Pathology and Genetics of Tumours of the Endocrine Organs* Lyon, France: IARC Press International Agency for Research on Cancer, 2004.
- Woolner LB, Lemmon ML, Beahrs OH, Black BM & Keating FR. Occult papillary carcinoma of the thyroid gland: a study of 140 cases observed in 30 year period. *Journal of Clinical Endocrinology and Metabolism* 1960 **20** 89–105.
- Pellegriti G, Scollo C, Lumera G, Regalbutto C, Vigneri R & Belli A. Clinical behavior and outcome of papillary thyroid cancers smaller than 1.5 cm in diameter: study of 299 cases. *Journal of Clinical Endocrinology and Metabolism* 2004 **89** 3713–3720.
- Hay ID, Grant CS, van Heerden JA, Goellner JR, Ebersold JR & Bergstralh EJ. Papillary thyroid microcarcinoma: a study of 535 cases observed in a 50-year period. *Surgery* 1992 **112** 1139–1146.
- Baudin E, Travagli JP, Ropers J, Mancusi F, Bruno-Bossio G, Caillou B, Cailleux AF, Lombroso JD, Parmentier C & Schlumberger M. Microcarcinoma of the thyroid gland: the Gustave Roussy Institute experience. *Cancer* 1998 **83** 553–559.
- Sugino K, Ito K Jr, Ozaki O, Mimura T, Iwasaki H & Ito K. Papillary microcarcinoma of the thyroid. *Journal of Endocrinological Investigation* 1998 **21** 445–448.
- Yamashita H, Noguchi S, Murakami N, Toda M, Uchino S, Watanabe S & Kawamoto H. Extracapsular invasion of lymph node metastasis. A good indicator of disease recurrence and poor prognosis in patients with thyroid microcarcinoma. *Cancer* 1999 **86** 842–849.
- Wada N, Duh QY, Sugino K, Iwasaki H, Kameyama K, Mimura T, Ito K, Takami H & Takanashi Y. Lymph node metastasis from 259 papillary thyroid microcarcinomas: frequency, pattern of occurrence, and optimal strategy for neck dissection. *Annals of Surgery* 2003 **237** 399–407.
- Pelizzo MR, Boschini IM, Toniato A, Pagetta C, Piotta A, Bernante P, Casara D, Pennelli G & Rubello D. Natural history, diagnosis, treatment and outcome of papillary thyroid microcarcinoma (PTMC): a mono-institutional 12-year experience. *Nuclear Medicine Communications* 2004 **25** 547–552.
- Fardella C, Jiménez M, González H, León A, Goñi I, Cruz F, Solar A, Torres J, Mosso L, González G, Rodríguez JA, Campusano C, López JM & Arteaga E. Pathological characteristics of thyroid microcarcinoma. A review of 402 biopsies. *Revista Médica de Chile* 2005 **133** 1305–1310 (Spanish).
- Barbaro D, Simi U, Meucci G, Lapi P, Orsini P & Pasquini C. Thyroid papillary cancers: microcarcinoma and carcinoma, incidental cancers and non-incidental cancers – are they different diseases? *Clinical Endocrinology* 2005 **63** 577–581.
- Roti E, Rossi R, Trasforini G, Bertelli E, Ambrosio MR, Busutti L, Pearce EN, Braverman LE & degli Uberti EC. Clinical and histological characteristics of papillary thyroid microcarcinoma: results of a retrospective study in 243 patients. *Journal of Clinical Endocrinology and Metabolism* 2006 **91** 2171–2178.
- de Matos PS, Ferreira AP & Ward LS. Prevalence of papillary microcarcinoma of the thyroid in Brazilian autopsy and surgical series. *Endocrine Pathology* 2006 **17** 165–173.

- 14 Sacco R, Aversa S, Innaro N, Carpino A, Bolognini S & Amorosi A. Thyroid microcarcinoma and multinodular struma. Personal experience and considerations regarding surgical therapy. *Chirurgia Italiana* 2006 **58** 69–75 (Italian).
- 15 Antonaci A, Anello A, Aucello A, Consorti F, Della Rocca C, Giovannone G & Scardella L. Microcarcinoma and incidental carcinoma of the thyroid in a clinical series: clinical behaviour and surgical management. *La Clinica Terapeutica* 2006 **157** 225–229.
- 16 Cheema Y, Olson S, Elson D & Chen H. What is the biology and optimal treatment for papillary microcarcinoma of the thyroid? *Journal of Surgical Research* 2006 **134** 160–162.
- 17 Lee J, Rhee Y, Lee S, Ahn CW, Cha BS, Kim KR, Lee HC, Kim SI, Park CS & Lim SK. Frequent, aggressive behaviors of thyroid microcarcinomas in Korean patients. *Endocrinology Journal* 2006 **53** 627–632.
- 18 Monacelli M, Sperlongano P, D'Ajello M, Calzolari F, Piatto A, Lucchini R, Misso C, Parmeggiani D, Pisaniello D, Sordelli I, Sperlongano R & Avenia N. Thyroid microcarcinoma: our experience. *Il Giornale di Chirurgia* 2006 **27** 158–160 (Italian).
- 19 Torlontano M, Crocetti U, Augello G, D'Aloiso L, Bonfitto N, Varraso A, Dicembrino F, Modoni S, Frusciante V, Di Giorgio A, Bruno R, Filetti S & Trischitta V. Comparative evaluation of recombinant human thyrotropin-stimulated thyroglobulin levels, ¹³¹I whole-body scintigraphy, and neck ultrasonography in the follow-up of patients with papillary thyroid microcarcinoma who have not undergone radioiodine therapy. *Journal of Clinical Endocrinology and Metabolism* 2006 **91** 60–63.
- 20 Lo CY, Chan WF, Lang BH, Lam KY & Wan KY. Papillary microcarcinoma: is there any difference between clinically overt and occult tumors? *World Journal of Surgery* 2006 **30** 759–766.
- 21 Cappelli C, Castellano M, Braga M, Gandossi E, Pirola I, De Martino E, Agosti B & Agabiti Rosei E. Aggressiveness and outcome of papillary thyroid carcinoma (PTC) versus microcarcinoma (PMC): a mono-institutional experience. *Journal of Surgical Oncology* 2007 **95** 555–560.
- 22 Küçük NO, Tari P, Tokmak E & Aras G. Treatment for microcarcinoma of the thyroid – clinical experience. *Clinical Nuclear Medicine* 2007 **32** 279–281.
- 23 Lim DJ, Baek KH, Lee YS, Park WC, Kim MK, Kang MI, Jeon HM, Lee JM, Yun-Cha B, Lee KW, Son HY & Kang SK. Clinical, histopathological, and molecular characteristics of papillary thyroid microcarcinoma. *Thyroid* 2007 **17** 883–888.
- 24 Pisello F, Geraci G, Sciumè C, Li Volsi F & Modica G. Total thyroidectomy of choice in papillary microcarcinoma. *Il Giornale di Chirurgia* 2007 **28** 13–19 (Italian).
- 25 Schönberger J, Marienhagen J, Agha A, Rozeboom S, Bachmeier E, Schlitt H & Eilles C. Papillary microcarcinoma and papillary cancer of the thyroid $\leq 1\text{ cm}$: modified definition of the WHO and the therapeutic dilemma. *Nuklearmedizin* 2007 **46** 115–120.
- 26 Sakorafas GH, Stafyla V, Kolettis T, Tolumis G, Kassaras G & Peros G. Microscopic papillary thyroid cancer as an incidental finding in patients treated surgically for presumably benign thyroid disease. *Journal of Postgraduate Medicine* 2007 **53** 23–26.
- 27 Carlini M, Giovannini C, Castaldi F, Mercadante E, Dell'Avanzato R, Zazza S, Nania A, Santeusano G, Passeri M & Di Perna P. High risk for microcarcinoma in thyroid benign diseases. Incidence in a one year period of total thyroidectomies. *Journal of Experimental and Clinical Cancer Research* 2005 **24** 231–236.
- 28 Sampson RJ, Key CR, Buncher CR & Iijima S. Smallest forms of papillary carcinoma of the thyroid. A study of 141 microcarcinomas less than 0.1 cm in greatest dimension. *Archives of Pathology* 1971 **91** 334–339.
- 29 Harach HR, Franssila KO & Wasenius VM. Occult papillary carcinoma of the thyroid. A 'normal' finding in Finland. A systematic autopsy study. *Cancer* 1985 **56** 531–538.
- 30 Noguchi S, Yamashita H, Murakami N, Nakayama I, Masakatsu T & Kawamoto H. Small carcinomas of the thyroid. A long-term follow-up of 867 patients. *Archives of Surgery* 1996 **131** 187–191.
- 31 Rodriguez JM, Moreno A, Parrilla P, Sola J, Soria T, Tebar FJ & Aranda F. Papillary thyroid microcarcinoma: clinical study and prognosis. *European Journal of Surgery* 1997 **163** 255–259.
- 32 Ruggieri M, Genderini M, Gargiulo P, Del Grammastro A, Mascaro A, Luongo B & Paolini A. Surgical treatment of differentiated microcarcinomas of the thyroid. *European Review for Medical and Pharmacological Sciences* 2001 **5** 85–89.
- 33 Simpson WJ, McKinney SE, Carruthers JS, Gospodarowicz MK, Sutcliffe SB & Panzarella T. Papillary follicular thyroid cancer: prognostic factors in 1578 patients. *American Journal of Medicine* 1987 **83** 479–488.
- 34 Sugitani I & Fujimoto Y. Symptomatic versus asymptomatic papillary thyroid microcarcinoma: a retrospective analysis of surgical outcome and prognostic factors. *Endocrine Journal* 1999 **46** 209–216.
- 35 Emerick GT, Duh QY, Siperstein AE, Burrow GN & Clark OH. Diagnosis, treatment, and outcome of follicular thyroid carcinoma. *Cancer* 1993 **72** 3287–3291.
- 36 Rossi R, Roti E, Trasforini G, Bertelli F, Cavazzini L, Zatelli MC, Pearce EN, Braverman LE & degli Uberti EC. Histological and clinical differences in thyroid cancers $\leq 10\text{ mm}$ and $11\text{--}20\text{ mm}$ in diameter: results of a retrospective study of 426 patients. *Thyroid* 2008 **18** 309–315.
- 37 Fukunaga FH & Yatani R. Geographic pathology of occult thyroid carcinomas. *Cancer* 1975 **36** 1095–1099.
- 38 Tournaire J, Bernard MH, Bizollon-Roblin MH, Bertholon-Grégoire M & Berger-Dutrieux N. Le micro-carcinome papillaire du corps thyroïde. 179 cas observés depuis 1973. *Presse Médicale* 1998 **27** 1467–1469.
- 39 Falvo I, D'Ercole C, Sorrenti S, D'Andrea V, Catania A, Berni A, Grilli P & De Antoni E. Papillary microcarcinoma of the thyroid gland: analysis of prognostic factors including histological subtype. *European Journal of Surgery* 2002 **168** (Suppl 588) 28–32.
- 40 Appetecchia M, Scarcello G, Pucci E & Procaccini A. Outcome after treatment of papillary thyroid microcarcinoma. *Journal of Experimental & Clinical Cancer Research* 2002 **21** 159–164.
- 41 Ito Y, Uruno T, Nakano K, Takamura Y, Miya A, Kobayashi K, Yokozawa T, Matsuzuka F, Kuma S & Miyauchi A. An observation trial without surgical treatment in patients with papillary microcarcinoma of the thyroid. *Thyroid* 2003 **13** 381–387.
- 42 Chow SM, Law SCK, Chan JKC, Au SK, Yau S & Lau WH. Papillary microcarcinoma of the thyroid – prognostic significance of lymph node metastasis and multifocality. *Cancer* 2003 **98** 31–40.
- 43 Barroeta JE, Wang H, Shiina N, Gupta PK, Livolsi VA & Baloch ZW. Is fine-needle aspiration (FNA) of multiple thyroid nodules justified? *Endocrine Pathology* 2006 **17** 61–65.
- 44 Biscolla RP, Ugolini C, Sculli M, Bottici V, Castagna MG, Romei C, Cosci B, Molinaro E, Faviana P, Basolo F, Miccoli P, Pacini F, Pinchera A & Elisei R. Medullary and papillary tumors are frequently associated in the same thyroid gland without evidence of reciprocal influence in their biologic behavior. *Thyroid* 2004 **14** 946–952.
- 45 Bonnin C, Trojani M, Corcuff JB & Bonichon F. Outcome of 111 thyroid papillary carcinomas. Retrospective study from 1953 to 1994. Experience of Bergonié Institute. *Annales d'Endocrinologie* 1997 **58** 318–325 (Review. French).
- 46 Farina GP, Baccoli A, Pisano M, Pani C, Di Ninni S, Marcello A & Cagetti M. Papillary microcarcinoma of the thyroid. Clinical implications and therapeutic strategy. *Il Giornale di Chirurgia* 2003 **24** 11–17 (Italian).
- 47 Ito Y, Higashiyama T, Takamura Y, Miya A, Kobayashi K, Matsuzuka F, Kuma K & Miyauchi A. Prognosis of patients with benign thyroid diseases accompanied by incidental papillary carcinoma undetectable on preoperative imaging tests. *World Journal of Surgery* 2007 **31** 1672–1676.
- 48 Ito Y, Tomoda C, Uruno T, Takamura Y, Miya A, Kobayashi K, Matsuzuka F, Kuma K & Miyauchi A. Preoperative ultrasonographic examination for lymph node metastasis: usefulness when designing lymph node dissection for papillary microcarcinoma of the thyroid. *World Journal of Surgery* 2004 **28** 498–501.

- 49 Jacquot-Laperrière S, Timoshenko AP, Dumollard JM, Peoc'h M, Estour B, Martin C & Prades JM. Papillary thyroid microcarcinoma: incidence and prognostic factors. *European Archives of Oto-Rhino-Laryngology* 2007 **264** 935–939.
- 50 Lin JD, Chen ST, Chao TC, Hsueh C & Weng HF. Diagnosis and therapeutic strategy for papillary thyroid microcarcinoma. *Archives of Surgery* 2005 **140** 940–945.
- 51 Sugitani I, Yanagisawa A, Shimizu A, Kato M & Fujimoto Y. Clinicopathologic and immunohistochemical studies of papillary thyroid microcarcinoma presenting with cervical lymphadenopathy. *World Journal of Surgery* 1998 **22** 731–737.
- 52 Wang J, Qiu X, Zhou L, Deng X, Zhang C & Zhou C. Differentiated microcarcinoma of the thyroid gland in 45 cases. *Lin Chuang Er Bi Yan Hou Ke Za Zhi* 2001 **15** 542–543 (Chinese).
- 53 Yang GC, LiVolsi VA & Baloch ZW. Thyroid microcarcinoma: fine-needle aspiration diagnosis and histologic follow-up. *International Journal of Surgical Pathology* 2002 **10** 133–139.
- 54 Miccoli P, Minuto MN, Ugolini C, Panicucci E, Massi M, Berti P & Basolo F. Papillary thyroid cancer: pathological parameters as prognostic factors in different classes of age. *Archives of Otolaryngology – Head and Neck Surgery* 2008 **138** 200–203.
- 55 Pelizzo MR, Boschin LM, Toniato A, Piotto A, Bernante P, Pagetta C, Rampin L & Rubello D. Papillary thyroid microcarcinoma (PTMC): prognostic factors, management and outcome in 403 patients. *European Journal of Surgical Oncology* 2006 **32** 1144–1148.
- 56 Nishiyama RH, Ludwig GK & Thompson NW. The prevalence of small papillary thyroid carcinomas in 100 consecutive necropsies in an American population. In *Radiation-Associated Thyroid Carcinoma*, pp 123–135. Eds LJ De Groot, LA Frohman, EL Kaplan & S Refetoff. New York: Grune & Stratton, 1977.
- 57 Sampson RJ. Comment on Dr. Edis's presentation on natural history of occult thyroid carcinoma. In *Radiation-Associated Thyroid Carcinoma*, pp 171–181. Eds LJ De Groot, LA Frohman, EL Kaplan & S Refetoff. New York: Grune & Stratton, 1977.
- 58 Lin KD, Lin JD, Huang J, Huang HS, Jeng LB & Chao TC. Clinical presentations and predictive variables of thyroid microcarcinoma with distant metastasis. *International Surgery* 1997 **82** 378–381.
- 59 Neuhold N, Kaiser H & Kaserer K. Latent carcinoma of the thyroid in Austria: a systematic autopsy study. *Endocrine Pathology* 2001 **12** 23–31.
- 60 Lupoli G, Vitale G, Caraglia M, Fittipaldi MR, Abbruzzese A, Tagliaferri P & Bianco AR. Familial papillary thyroid microcarcinoma: a new clinical entity. *Lancet* 1999 **353** 637–639.
- 61 Eng C. Familial papillary thyroid cancer: many syndromes, too many genes? *Journal of Clinical Endocrinology and Metabolism* 2000 **85** 1755–1757.
- 62 Ríos A, Rodríguez JM, Illana J, Torregrosa NM & Parrilla P. Familial papillary carcinoma of the thyroid: report of three families. *European Journal of Surgery* 2001 **167** 339–343.
- 63 Fernández-Real JM & Ricart W. Familial papillary thyroid microcarcinoma. *Lancet* 1999 **353** 1973–1974.
- 64 Viglietto G, Chiappetta G, Martínez-Tello FJ, Fukunaga FH, Tallini G, Rigoupoulou D, Visconti R, Mastro A, Santoro M & Fusco A. RET/PTC oncogene activation is an early event in thyroid carcinogenesis. *Oncogene* 1995 **11** 1207–1210.
- 65 Adeniran AJ, Zhu Z, Gandhi M, Steward DL, Fidler JP, Giordano TJ, Biddinger PW & Nikiforov YE. Correlation between genetic alterations and microscopic features, clinical manifestations, and prognostic characteristics of thyroid papillary carcinomas. *American Journal of Surgical Pathology* 2006 **30** 216–222.
- 66 Corvi R, Martínez-Alfaro M, Harach HR, Zini M, Papotti M & Romeo G. Frequent RET rearrangements in thyroid papillary microcarcinoma detected by interphase fluorescence *in situ* hybridization. *Laboratory Investigation; A Journal of Technical Methods and Pathology* 2001 **81** 1639–1645.
- 67 Tallini G, Santoro M, Helie M, Carlomagno F, Salvatore G, Chiappetta G, Carcangiu ML & Fusco A. RET/PTC oncogene activation defines a subset of papillary thyroid carcinomas lacking evidence of progression to poorly or undifferentiated tumor phenotypes. *Clinical Cancer Research* 1998 **4** 287–294.
- 68 Sugg SL, Zheng L, Rosen IB, Freeman JL, Ezzat S & Asa SL. RET/PTC1, 2 and 3 oncogene rearrangements in human thyroid carcinomas: implications for metastatic potential? *Journal of Clinical Endocrinology and Metabolism* 1996 **81** 3360–3365.
- 69 Namba H, Nakashima M, Hayashi T, Hayashida N, Maeda S, Rogounovitch TI, Ohtsuru A, Saenko VA, Kanematsu T & Yamashita S. Clinical implication of hot spot BRAF mutation, V599E, in papillary thyroid cancers. *Journal of Clinical Endocrinology and Metabolism* 2003 **88** 4393–4397.
- 70 Nikiforova MN, Kimura ET, Gandhi M, Biddinger PW, Knauf JA, Basolo F, Zhu Z, Giannini R, Salvatore G, Fusco A, Santoro M, Fagin JA & Nikiforov YE. BRAF mutations in thyroid tumors are restricted to papillary carcinomas and anaplastic or poorly differentiated carcinomas. *Journal of Clinical Endocrinology and Metabolism* 2003 **88** 5399–5404.
- 71 Puxeddu E, Moretti S, Elisei R, Romei C, Pascucci R, Martinelli M, Marino C, Avenia N, Rossi ED, Fadda G, Cavaliere A, Ribacchi R, Falorni A, Pontecorvi A, Pacini F, Pinchera A & Santeusano F. BRAF(V599E) mutation is the leading genetic event in adult sporadic papillary thyroid carcinomas. *Journal of Clinical Endocrinology and Metabolism* 2004 **89** 2414–2420.
- 72 Liu D, Liu Z, Condouris S & Xing M. BRAF V600E maintains proliferation, transformation, and tumorigenicity of BRAF-mutant papillary thyroid cancer cells. *Journal of Clinical Endocrinology and Metabolism* 2007 **92** 2264–2271.
- 73 Oler G, Ebina KN, Mchaluart P, Rimura ET & Cerutti J. Investigation of BRAF mutation in a series of papillary thyroid carcinoma and matched lymph node metastasis reveals a new mutation in metastasis. *Clinical Endocrinology* 2005 **62** 509–511.
- 74 Kim EK, Park CS, Chung WY, Oh KK, Kim DI, Lee JT & Yoo HS. New sonographic criteria for recommending fine-needle aspiration biopsy of nonpalpable solid nodules of the thyroid. *American Journal of Roentgenology* 2002 **178** 687–691.
- 75 Sampson RJ, Woolner LB, Bahn RC & Kurland LT. Occult thyroid carcinoma in Olmsted County, Minnesota: prevalence at autopsy compared with that in Hiroshima and Nagasaki, Japan. *Cancer* 1974 **34** 2072–2076.
- 76 Yamamoto Y, Maeda T, Izumi K & Otsuka H. Occult papillary carcinoma of the thyroid. *Cancer* 1990 **65** 1173–1179.
- 77 Briere I & Dickson LG. Clinically unsuspected thyroid disease. *American Family Physician/GP* 1964 **30** 94–98.
- 78 Yagawa K, Takahashi S & Murata T. Clinicopathological study of latent thyroid carcinoma. In *Proceedings of the Japanese Cancer Association, the 25th Annual Meeting*, 106 (abstract). December, 1966.
- 79 Fukunaga FH & Lockett IJ. Thyroid carcinoma in Japanese in Hawaii. *Archives of Pathology* 1971 **92** 6–13.
- 80 Kovacs GL, Gonda G, Vadasz G, Ludmany E, Uhrin K, Gorombey Z, Kovacs L, Hubina E, Bodo M, Goth MI & Szabolcs I. Epidemiology of thyroid microcarcinoma found in autopsy series conducted in areas of different iodine intake. *Thyroid* 2005 **15** 152–157.
- 81 Balazs GY & Krasznai G. Occult pajzsmirigyрак post mortem vizsgalata [in Hungarian]. *Orvosi Hetilap* 1974 **115** 2856–2860.
- 82 Sobrinho-Simoes MA, Sambade MC & Goncalves V. Latent thyroid carcinoma at autopsy. *Cancer* 1979 **43** 1702–1706.
- 83 Bondeson L & Ljungberg O. Occult thyroid carcinoma at autopsy in Malmö, Sweden. *Cancer* 1981 **47** 319–323.
- 84 Lang W, Borrusch H & Bauer L. Evaluation of 1020 sequential autopsies. *American Journal of Clinical Pathology* 1988 **90** 72–76.
- 85 Ottino A, Pianzola HM & Castelletto RH. Occult papillary thyroid carcinoma at autopsy in La Plata, Argentina. *Cancer* 1989 **64** 547–551.
- 86 Tan GH & Gharib H. Thyroid incidentalomas: management approaches to nonpalpable nodules discovered incidentally on thyroid imaging. *Annals of Internal Medicine* 1997 **126** 226–231.
- 87 Reiners C, Wegscheider K, Schicha H, Theissen P, Vaupel R, Wrbitzky R & Schumm-Draeger PM. Prevalence of thyroid

- disorders in the working population of Germany: ultrasonography screening in 96,278 unselected employees. *Thyroid* 2004 **14** 926–932.
- 88 Tan GH, Gharib H & Reading CC. Solitary thyroid nodule. Comparison between palpation and ultrasonography. *Archives of Internal Medicine* 1995 **155** 2418–2423.
- 89 Brander A, Viikinkoski P, Tuuhea J, Voutilainen L & Kivisaari L. Clinical versus ultrasound examination of the thyroid gland in common clinical practice. *Journal of Clinical Ultrasound* 1992 **20** 37–42.
- 90 Walker J, Findlay D, Amar SS, Small PG, Wastie ML & Pegg CA. A prospective study of thyroid ultrasound scan in the clinically solitary thyroid nodule. *British Journal of Radiology* 1985 **58** 617–619.
- 91 Leenhardt L, Grosclaude P & Chérié-Challine L. Thyroid Cancer Committee. Increased incidence of thyroid carcinoma in France: a true epidemic or thyroid nodule management effects? Report from the French thyroid cancer committee *Thyroid* 2004 **14** 1056–1106.
- 92 Verkooijen HM, Fioretta G, Pache JC, Franceschi S, Raymond L, Schubert H & Bouchardy C. Diagnostic changes as a reason for the increase in papillary thyroid cancer incidence in Geneva, Switzerland. *Cancer Causes and Control* 2003 **14** 13–17.
- 93 Davies L & Welch HG. Increasing incidence of thyroid cancer in the United States, 1973–2002. *Journal of the American Medical Association* 2006 **295** 2164–2167.
- 94 Burgess JR, Dwyer T, McArdle K, Tucker P & Shugg D. The changing incidence and spectrum of thyroid carcinoma in Tasmania (1978–1998) during a transition from iodine sufficiency to iodine deficiency. *Journal of Clinical Endocrinology and Metabolism* 2000 **85** 1513–1517.
- 95 Chow SM, Law SC, Au SK, Mang O, Yau S, Yuen KT & Lau WH. Changes in clinical presentation, management and outcome in 1348 patients with differentiated thyroid carcinoma: experience in a single institute in Hong Kong, 1960–2000. *Clinical Oncology* 2003 **15** 329–336.
- 96 Abdumughni YA, Al-Hureibi MA, Al-Hureibi KA, Ghafoor MA, Al-Wadan AH & Al-Hureibi YA. Thyroid cancer in Yemen. *Saudi Medical Journal* 2004 **25** 55–59.
- 97 Ardito G, Revelli L, Lucci C, Giacinto O & Praquin B. Papillary microcarcinoma [correction of carcinoma] of the thyroid: clinical experience and prognosis factors. *Annali Italiani di Chirurgia* 2001 **72** 261–265 (Italian. Erratum in: *Annali Italiani di Chirurgia* 2001 **72**: 390).
- 98 Garrel R, Cartier C, Marvaso V, Corpelet D, Makeieff M, Crampette L & Guerrier B. Our experience with papillary microcarcinoma of the thyroid. *Revue de Laryngologie – Otologie – Rhinologie* 2002 **123** 239–242 (French).
- 99 Deveci MS, Deveci G, LiVolsi VA, Gupta PK & Baloch ZW. Concordance between thyroid nodule sizes measured by ultrasound and gross pathology examination: effect on patient management. *Diagnostic Cytopathology* 2007 **35** 579–583.
- 100 Lam AK, Lo CY & Lam KS. Papillary carcinoma of thyroid: a 30-yr clinicopathological review of the histological variants. *Endocrine Pathology* 2005 **16** 323–330 (Review).
- 101 Cappelli C, Pirola I, Cumetti D, Micheletti L, Tironi A, Gandossi E, Martino E, Cherubini L, Agosti B, Castellano M, Mattanza C & Agabiti Rosei E. Is the anteroposterior and transverse diameter ratio of nonpalpable thyroid nodules a sonographic criteria for recommending fine-needle aspiration cytology? *Clinical Endocrinology* 2005 **63** 689–693.
- 102 Gemsenjäger E & Schweizer I. Small thyroid carcinomas: biological characteristics, diagnosis and therapy. *Schweizerische Medizinische Wochenschrift* 1999 **129** 681–690.
- 103 Leprat F, Trouette H, Cochet C, Saumthally B, Masson B, de Mascarel A & Latapie JL. Papillary microcarcinoma of the thyroid. *Annales d'Endocrinologie* 1994 **54** 343–346 (French).
- 104 Melliere D, Hindie E, Becquemini JP, Desgranges P, Allaire E & Geachan E. Differentiated thyroid carcinoma – how to improve the long-term results? Twenty-five-year outcomes of 850 patients *Bulletin de l'Académie Nationale de Médecine* 2006 **190** 89–106 (discussion 106–109, French).
- 105 Orsenigo E, Beretta E, Fiacco E, Scaltrinia F, Veronesi P, Invernizzi L, Gini P, Fiorina P & Di Carlo V. Management of papillary microcarcinoma of the thyroid gland. *European Journal of Surgical Oncology* 2004 **30** 1104–1106.
- 106 Jukkola A, Bloigu R, Ebeling T, Salmela P & Blanco G. Prognostic factors in differentiated thyroid carcinomas and their implications for current staging classifications. *Endocrine-Related Cancer* 2004 **11** 571–579.
- 107 Passler C, Scheuba C, Prager G, Kaczirek K, Kaserer K, Zettinig G & Niederle B. Prognostic factors of papillary and follicular thyroid cancer: differences in an iodine replete endemic goiter region. *Endocrine-Related Cancer* 2004 **11** 131–139.
- 108 Eustatia-Rutten CF, Corssmit EP, Biermasz NR, Pereira AM, Romijn JA & Smit JW. Survival and death causes in differentiated thyroid carcinoma. *Journal of Clinical Endocrinology and Metabolism* 2006 **91** 313–319.
- 109 Piraino P, Sepúlveda A, Lillo R, Pineda P & Liberman C. Thyroid cancer. Report of 85 cases. *Revista Médica de Chile* 2000 **128** 405–410 (Spanish).
- 110 Yokozawa T. Evaluation of the clinical usefulness of ultrasonography in making a preoperative diagnosis of thyroid carcinoma. *Nippon Geka Gakkai Zasshi* 1988 **89** 582–594 (Japanese).
- 111 Hundahl SA, Cady B, Cunningham MP, Mazzaferri E, McKee RF, Rosai J, Shah JP, Fremgen AM, Stewart AK & Hölzer S. Initial results from a prospective cohort study of 5583 cases of thyroid carcinoma treated in the United States during 1996. US and German Thyroid Cancer Study Group. An American College of Surgeons Commission on Cancer Patient Care Evaluation study. *Cancer* 2000 **89** 202–217.
- 112 Chigot JP, Ménégau F, Keopadabsy K, Hoang C, Aurengo A, Leenhardt L & Turpin G. Thyroid cancer in patients with hyperthyroidism. *Presse Médicale* 2000 **29** 1969–1972 (French).
- 113 Dietlein M, Luyken WA, Schicha H & Larena-Avellaneda A. Incidental multifocal papillary microcarcinomas of the thyroid: is subtotal thyroidectomy combined with radioiodine ablation enough? *Nuclear Medicine Communications* 2005 **26** 3–8.
- 114 Kasuga Y, Sugeno A, Kobayashi S, Masuda H & Iida F. The outcome of patients with thyroid carcinoma and Graves' disease. *Surgery Today* 1993 **23** 9–12.
- 115 Klofanda J, Krška Z & Trca S. Total thyroidectomy in malignant goiter, significance and problems. *Rozhledy v Chirurgii* 2002 **81** 5–7 (Czech).
- 116 Lokey JS, Palmer RM & Macfie JA. Unexpected findings during thyroid surgery in a regional community hospital: a 5-year experience of 738 consecutive cases. *American Surgeon* 2005 **71** 911–913 (discussion 913–915).
- 117 Costanzo M, Caruso LA, Messina DC, Cavallaro A, Palumbo A, Marziani A & Cannizzaro MA. Thyroid microcarcinoma in benign thyroid diseases. *Annali Italiani di Chirurgia* 2005 **76** 119–121 (discussion 121–122, Italian).
- 118 Stulak JM, Grant CS, Farley DR, Thompson GB, van Heerden JA, Hay ID, Reading CC & Charboneau JW. Value of preoperative ultrasonography in the surgical management of initial and reoperative papillary thyroid cancer. *Archives of Surgery* 2006 **141** 489–496.
- 119 Yassa L, Cibas ES, Benson CB, Frates MC, Doubilet PM, Gawande AA, Moore FD, Kim BW, Marqusee E, Larsen PR & Alexander EK. Long-term assessment of a multidisciplinary approach to thyroid nodule diagnostic evaluation. *Cancer* 2007 **111** 508–516.
- 120 Ríos A, Rodríguez JM, Canteras M, Galindo PJ, Balsalobre MD & Parrilla P. Risk factors for malignancy in multinodular goitres. *European Journal of Surgical Oncology* 2004 **30** 58–62.
- 121 Russo F, Barone Adesi TL, Arturi A, Stolli VM, Spina C, Savio A, De Majo A, Uccioli L & Gentileschi P. Clinico-pathological study of microcarcinoma of the thyroid. *Minerva Chirurgica* 1997 **52** 891–900 (Italian).

- 122 Ortiz S, Rodriguez JM, Torregrosa N, Balsalobre M, Rios A & Parrilla P. Relation between clinical presentation and prognosis of patients with papillary thyroid microcarcinoma (article in Spanish). *Medicina Clinica* 2003 **120** 773–774.
- 123 Pelizzo MR, Merante Boschini I, Toniato A, Piotto A, Bernante P, Pagetta C, Casal Ide E, Mazzarotto R, Casara D & Rubello D. Papillary thyroid microcarcinoma. Long-term outcome in 587 cases compared with published data. *Minerva Chirurgica* 2007 **62** 315–325.
- 124 Giles Y, Boztepe H, Terzioğlu T & Tezelman S. The advantage of total thyroidectomy to avoid reoperation for incidental thyroid cancer in multinodular goiter. *Archives of Surgery* 2004 **139** 179–182.
- 125 McCoy KL, Jabbour N, Ogilvie JB, Ohori NP, Carty SE & Yim JH. The incidence of cancer and rate of false-negative cytology in thyroid nodules greater than or equal to 4 cm in size. *Surgery* 2007 **142** 837–844.
- 126 Pelizzo MR, Piotto A, Rubello D, Casara D, Fassina A & Busnardo B. High prevalence of occult papillary thyroid carcinoma in a surgical series for benign thyroid disease. *Tumori* 2000 **76** 255–257.
- 127 Papini E, Guglielmi R, Bianchini A, Crescenzi A, Taccogna S, Nardi F, Panunzi C, Rinaldi R, Toscano V & Pacella CM. Risk of malignancy in nonpalpable thyroid nodules: predictive value of ultrasound and color – Doppler features. *Journal of Clinical Endocrinology and Metabolism* 2002 **87** 1941–1946.
- 128 Khoo ML, Asa SL, Witterick IJ & Freeman JL. Thyroid calcification and its association with thyroid carcinoma. *Head and Neck* 2002 **24** 651–655.
- 129 Peccin S, de Castro JA, Furlanetto TW, Furtado AP, Brasil BA & Czepielewski MA. Ultrasonography: is it useful in the diagnosis of cancer in thyroid nodules? *Journal of Endocrinological Investigation* 2002 **25** 39–43.
- 130 Chan BK, Desser TS, McDougall IR, Weigel RJ & Jeffrey RB Jr. Common and uncommon sonographic features of papillary thyroid carcinoma. *Journal of Ultrasound in Medicine* 2003 **22** 1083–1090.
- 131 Ito Y, Kobayashi K, Tomoda C, Uruno T, Takamura Y, Miya A, Matsuzuka F, Kuma K & Miyauchi A. Ill-defined edge on ultrasonographic examination can be a marker of aggressive characteristic of papillary thyroid microcarcinoma. *World Journal of Surgery* 2005 **29** 1007–1011.
- 132 Asanuma K, Kobayashi S, Shingu K, Hama Y, Yokoama S, Fujimori M & Amano J. The rate of tumour growth does not distinguish between malignant and benign thyroid nodules. *European Journal of Surgery* 2001 **167** 102–105.
- 133 Leenhardt L, Hejblum G, Franc B, Fediaevsky LD, Delbot T, Le Guillouez D, Menegaux F, Guillausseau C, Hoang C, Turpin G & Aurengo A. Indications and limits of ultrasound-guided cytology in the management of nonpalpable thyroid nodules. *Journal of Clinical Endocrinology and Metabolism* 1999 **84** 24–28.
- 134 Hagag P, Strauss S & Weiss M. Role of ultrasound-guided fine-needle aspiration biopsy in evaluation of nonpalpable thyroid nodules. *Thyroid* 1998 **8** 989–995.
- 135 Nam-Goong IL, Kim HY, Gong G, Lee HK, Hong SJ, Kim WB & Shong YK. Ultrasonographically-guided fine needle aspirations of thyroid incidentaloma: correlation with pathologic findings. *Clinical Endocrinology* 2004 **60** 21–28.
- 136 Cooper DS, Doherty GM, Haugen BR, Kloos RT, StLee SL, Mandel SJ, Mazzaferri EL, McIver B, Sherman SI & Tuttle RM. The American Thyroid Association Guidelines Taskforce. Management guidelines for patients with thyroid nodules and differentiated thyroid cancer. *Thyroid* 2006 **16** 109–141.
- 137 AACE/AME Task Force on Thyroid Nodules. American Association of Clinical Endocrinologists and Associazione Medici Endocrinologi medical guidelines for clinical practice for the diagnosis and management of thyroid nodules. *Endocrine Practice* 2006 **12** 63–102.
- 138 Frates MC, Benson CB, Charboneau JW, Cibas ES, Clark OH, Coleman BG, Cronan JJ, Doubilet PM, Evans DB, Goellner JR, Hay ID, Hertzberg BS, Intenzo CM, Jeffrey RB, Langer JE, Larsen PR, Mandel SJ, Middleton WD, Reading CC, Sherman SI & Tessler FN. Society of Radiologists in Ultrasound. Management of thyroid nodules detected at US: Society of Radiologists in Ultrasound consensus conference statement. *Radiology* 2005 **237** 794–800.
- 139 Kang HW, No JH, Chung JH, Min YK, Lee MS, Lee MK, Yang JH & Kim KW. Prevalence, clinical and ultrasonographic characteristics of thyroid incident-talomas. *Thyroid* 2004 **14** 29–33.
- 140 Jeong HS, Chung M, Baek CH, Ko YH, Choi JY & Son YI. Can [18F] fluorodeoxyglucose standardized uptake values of PET imaging predict pathologic extrathyroid invasion of thyroid papillary microcarcinomas? *Laryngoscope* 2006 **116** 2133–2137.
- 141 Ito Y, Higashiyama T, Takamura Y, Miya A, Kobayashi K, Matsuzuka F, Kuma K & Miyauchi A. Risk factors for recurrence to the lymph node in papillary thyroid carcinoma patients without preoperatively detectable lateral node metastasis: validity of prophylactic modified radical neck dissection. *World Journal of Surgery* 2007 **31** 2085–2091.
- 142 Oueslati Z, Aloui M, Gritli S, Touati S, el-May A, Gamoudi A, Ben Slimene F & Ladgham A. Thyroid papillary microcarcinoma. Salah Azaiz Institute experience. *Revue de Laryngologie – Otologie – Rhinologie* 2002 **123** 39–42 (French).
- 143 Rosário PW, Fagundes TA & Purisch S. Treatment of papillary microcarcinoma of the thyroid. *Arquivos Brasileiros de Endocrinologia e Metabologia* 2004 **48** 855–860 (Portuguese).
- 144 Machens A, Holzhausen HJ & Dralle H. The prognostic value of primary tumor size in papillary and follicular thyroid carcinoma. *Cancer* 2005 **103** 2269–2273.
- 145 Lantsov D, Meirmanov S, Nakashima M, Kondo H, Saenko V, Naruke Y, Namba H, Ito M, Abrosimov A, Lushnikov E, Sekine I & Yamashita SH. Cyclin D1 overexpression in thyroid papillary microcarcinoma: its association with tumour size and aberrant beta-catenin expression. *Histopathology* 2005 **47** 248–256.
- 146 Khoo ML, Ezzat S, Freeman JL & Asa SL. Cyclin D1 protein expression predicts metastatic behavior in thyroid papillary microcarcinomas but is not associated with gene amplification. *Journal of Clinical Endocrinology and Metabolism* 2002 **87** 1810–1813.
- 147 Ito Y, Uruno T, Takamura Y, Miya A, Kobayashi K, Matsuzuka F, Kuma K & Miyauchi A. Papillary microcarcinomas of the thyroid with preoperatively detectable lymph node metastasis show significantly higher aggressive characteristics on immunohistochemical examination. *Oncology* 2005 **68** 87–96.
- 148 Londero SC, Godballe C, Krogdahl A, Bastholt L, Specht L, Sørensen CH, Pedersen HB, Pedersen U & Christiansen P. Papillary microcarcinoma of the thyroid gland: is the immunohistochemical expression of cyclin D1 or galectin-3 in primary tumour an indicator of metastatic disease? *Acta Oncologica* 2007 **28** 1–7.
- 149 Cvejic D, Savin S, Petrovic I, Paunovic I, Tatic S, Krgovic K & Havelca M. Galectin-3 expression in papillary microcarcinoma of the thyroid. *Histopathology* 2005 **47** 209–214.
- 150 Cotellesse R, Dell’Osa A, Francomano F, Cieri M & Innocenti P. Thyroid microcarcinoma: our experience. *Tumori* 2005 **4** S155–S156 (Italian).
- 151 Gülben K, Berberoğlu U, Celen O & Mersin HH. Incidental papillary microcarcinoma of the thyroid-factors affecting lymph node metastasis. *Langenbeck’s Archives of Surgery* 2008 **393** 25–29.
- 152 Besic N, Pilko G, Petric R, Hocevar M & Zgajnar J. Papillary thyroid microcarcinoma: prognostic factors and treatment. *Journal of Surgical Oncology* 2008 **97** 221–225.
- 153 Rouxel A, Hejblum G, Bernier MO, Boelle PY, Menegaux F, Mansour G, Hoang C, Aurengo A & Leenhardt L. Prognostic factors associated with the survival of patients developing loco-regional recurrences of differentiated thyroid carcinomas. *Journal of Clinical Endocrinology and Metabolism* 2004 **89** 5362–5368.
- 154 Pacini F, Schlumberger M, Dralle H, Elisei R, Smit JWA, Wiersinga W & the European Thyroid Cancer Taskforce.

- European consensus for the management of patients with differentiated thyroid carcinoma of the follicular epithelium. *European Journal of Endocrinology* 2006 **154** 787–803.
- 155 British Thyroid Association and Royal College of Physicians. Guidelines for the management of thyroid cancer in adults. www.british-thyroid-association.org, 2002.
- 156 Shah JP, Kian K, Forastiere A, Garden A, Hoffman HT, Jack Lee J, Lydiatt W, Medina JE, Mukherji S, Oliva ME, O'Sullivan B, Paulino A, Singh B, Weber R & Weymuller E. American Joint Committee on Cancer. In *Cancer Staging Manual*, edn 6, pp 77–87. New York: Springer-Verlag, 2002.
- 157 Van den Bruel A, Moreno-Reyes R, Bex M, Daumerie C & Glinoe D. Is the management of thyroid nodules and differentiated thyroid cancer in accordance with recent consensus guidelines? – results of a national survey *Clinical Endocrinology* 2008 **68** 599–604.
- 158 Mazzaferri EL. Management of low-risk differentiated thyroid cancer. *Endocrine Practice* 2007 **5** 498–512.
- 159 Jonklaas J, Sarlis NJ, Litofsky D, Ain KB, Thomas Bigos T, Brierley JD, Cooper DS, Haugen BR, Ladenson PW, Magner J, Robbins J, Ross DS, Skarulis M, Maxon HR & Sherman SI. Outcomes of patients with differentiated thyroid carcinoma following initial therapy. *Thyroid* 2006 **16** 1229–1242.
- 160 Pazaitou-Panayiotou K, Capezzone M & Pacini F. Clinical features and therapeutic implication of papillary thyroid microcarcinoma. *Thyroid* 2007 **17** 1085–1092.

Received 27 July 2008

Accepted 5 August 2008