

 **Case Report** 

Two Cases of Micro-Arteriovenous Fistula in the Lower Extremity with Misdiagnosis of Refractory Cellulitis

Miyako Tanaka, MD,¹ Fukashi Serizawa, MD, PhD,² Yohei Nagaoka, MD,¹ Takuya Jimbo, MD, PhD,¹ Kazuki Kawashima, MD,¹ Takeshi Asakura, MD, PhD,¹ Hiroshi Otomo, MD, PhD,¹ and Kenichi Yokota, MD, PhD¹

We report our experience of two cases of refractory cellulitis caused by peripheral micro-arteriovenous fistulas (AVFs) in the lower extremity. The micro-AVFs were so small that they could not be located accurately; further, the patients' symptoms differed markedly from those previously reported for AVF. AVF is known to cause ischemic symptoms. In contrast, micro-AVF causes congestive symptoms and remains undetected in the majority of patients. Identification of this pathology is crucial to enable effective treatment by the ligation of the incompetent perforator vein that increases venous hypertension, leading to congestive symptoms.

Keywords: arteriovenous fistula, lower extremity, cellulitis

Introduction

Cellulitis is a common disease defined as cutaneous inflammation due to infection. It is different from cutaneous inflammation associated with pus collection that requires drainage. According to the 2014 practice guidelines of the Infectious Disease Society of America for skin and soft tissue infections, the main treatment for cellulitis involves the administration of antibiotics. Predisposing conditions,

such as edema, obesity, eczema, venous insufficiency, and toe web abnormalities, also require treatment during the acute stage of cellulitis. Refractory cellulitis can result from chronic edema in a lower limb, with the differential diagnosis including lymphedema, varices, venous thrombosis, heart failure, and age-related conditions. Arteriovenous fistula (AVF) also causes edema in the foot; however, little information is available about this manifestation. In addition, AVF can cause cellulitis-like symptoms, such as cutaneous redness, warmth, tenderness, and hemi-edema, for which antibiotic treatment is ineffective.

We report our experience with two cases of refractory cellulitis caused by micro-AVF. These cases emphasize the importance of micro-AVF as a predisposing disease and as a differential diagnosis in cases of cellulitis. In these micro-AVF cases, surgical ligation of incompetent perforator veins is effective in reducing the symptoms. To our knowledge, this is the first study to report this therapy. We have used the term "arteriovenous fistula" in this manuscript according to the 2014 International Society for the Study of Vascular Anomalies classification of vascular anomalies.

Case Reports


Case 1

An 84-year-old woman presented to our Emergency Department with consciousness disturbance. Her past medical history included hypertension, fibrillation, obesity, and dementia. We detected high body temperature and edema in the right lower limb with local petechial rash and tenderness. Blood cultures were negative, and laboratory findings revealed a strong inflammatory reaction. She was admitted with a diagnosis of sepsis due to cellulitis. Antibiotic agents were administered immediately; however, the high body temperature persisted, and the redness on her right leg worsened. We suspected abscess formation and diseases-causing limb edema (e.g., deep-vein thrombosis) as the reasons for the lack of improvement and performed dynamic computed tomography (CT)

¹Department of Surgery, Kesenuma City Hospital, Kesenuma, Miyagi, Japan

²Department of Vascular Surgery, Kesenuma City Hospital, Kesenuma, Miyagi, Japan

Received: November 21, 2017; Accepted: January 4, 2018
Corresponding author: Fukashi Serizawa, MD, PhD. Department of Vascular Surgery, Kesenuma City Hospital, 8-2 Akaiwasuginosawa, Kesenuma, Miyagi 988-0181, Japan
Tel: +81-226-22-7100, Fax: +81-226-22-3121
E-mail: f-serizawa@med.tohoku.ac.jp

 ©2018 The Editorial Committee of Annals of Vascular Diseases. This article is distributed under the terms of the Creative Commons Attribution License, which permits use, distribution, and reproduction in any medium, provided the credit of the original work, a link to the license, and indication of any change are properly given, and the original work is not used for commercial purposes. Remixed or transformed contributions must be distributed under the same license as the original.

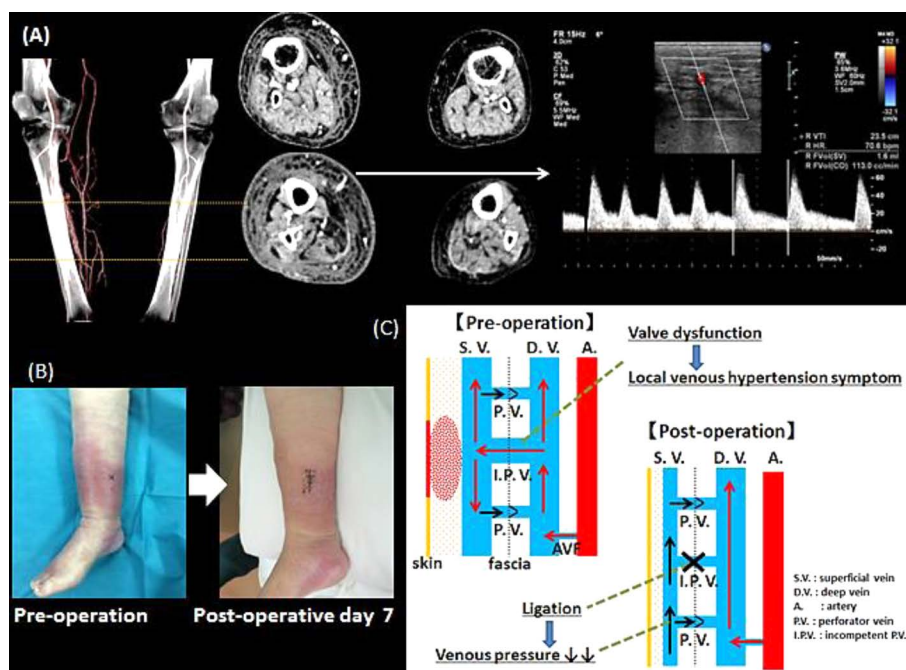


Fig. 1 Case 1 (A) Dynamic computed tomography (CT) scan showing early contrast filling of veins and subcutaneous edema. The incompetent venous perforator (arrow) showed an arterialized waveform on ultrasonography. (B) Preoperative and postoperative views of the right lower extremity. Redness and edema disappeared on postoperative day 7. (C) The schema of the pathology and treatment course of AVF.

that revealed AVFs but no nidus, abscess formation, or other cause of limb edema (Fig. 1A). We concluded that the AVFs caused high venous pressure, resulting in refractory cellulitis. Compression therapy was performed using elastic bandages. Some improvement in the patient's fever and edema as well as in the inflammatory reaction (as determined by laboratory findings) was observed; however, the local redness did not disappear. Color-flow Doppler ultrasonography showed an arterialized waveform in a perforator vein that had an increased diameter, peak systolic velocity (PSV), and flow volume in the area of redness (Figs. 1A and 1B; Table 1). This dilated vein was receiving arterial flow from the AVF, causing local high venous pressure leading to stasis dermatitis on the right lower limb. An incompetent perforator vein with an improperly functioning one-way valve was identified. We ligated the incompetent perforator vein under local anesthesia. Postoperative examination revealed reduced diameter, PSV, and flow volume of a superficial vein peripheral to the ligated perforator vein and disappearance of the local redness (Fig. 1B). During 14 months of follow-up, the patient remained asymptomatic.

Case 2

An 83-year-old man with redness and edema in the left lower limb presented to our Dermatology Department and was diagnosed with cellulitis. Antibiotic administra-

tion failed to show any improvement, and the patient was referred to the Department of Vascular Surgery. His past medical history included psoriasis, ringworm in the extremities, thrombocytosis, and heart failure. Physical examination revealed obvious swelling of the left limb with local heat and pigmentation on the ankle. The patient did not have high body temperature or elevated inflammatory response. Color-flow Doppler ultrasonography revealed arterialized waveforms in dilated superficial veins, with increased PSV and high-velocity turbulent flow, especially in the pigmented area (Table 1). CT showed early contrast filling in the dilated superficial veins during the arterial phase, with no nidus in either limb (Figs. 2A and 2B). The left limb showed greater contrast filling of the veins in the arterial phase. No deep venous thrombosis or evidence of varices was observed. The refractory edema in the left limb was diagnosed as stasis dermatitis secondary to multiple AVFs. Compression therapy using elastic stockings did not reduce the symptoms. Erosive lesions and a large amount of effusion were present on the patients' left lower limb (Fig. 2C). We planned ligation of the incompetent perforator veins that were draining the arterial blood flow via the AVFs and increasing the superficial venous pressure, causing the edema. We first determined the locations of all perforators in the left limb using CT and then examined the function of the perforator valves using ultrasonography. Thirteen incompetent perforator

Table 1 Ultrasonographic characteristics of the incompetent venous perforators

Case 1			
No.	Diameter	Fvol (cc/min)	PSV (cm/s)
1	3.03	108	59.7
Case 2: left limb			
No.	Diameter	Fvol (cc/min)	PSV (cm/s)
1	1.95	37.4	139
2	2.34	30.1	80
3	2.63	28.6	39
4	2.63	21.5	50
5	2.39	35.8	49
6	2.6	135.9	99
7	2.49	121.6	78
8	2.3	28.6	28
9	2.39	42.9	76
10	2.33	28.6	71
11	2.54	64.4	72
12	2.67	85.8	53
13	3.01	178.8	122
Case 2: right limb			
No.	Diameter	Fvol (cc/min)	PSV (cm/s)
1	3.09	81.2	73
2	2.47	59	68
3	3.34	184.5	91
4	2.27	44.3	56
5	1.88	14.8	22
6	1.85	36.9	46
7	2.13	44.3	80
8	2.21	118.1	120

Fvol: flow volume; PSV: peak systolic velocity

veins associated with 10–15 mm wounds were ligated under local anesthesia. The patient's symptoms improved postoperatively (Fig. 2C). His right limb showed the same symptoms as his left limb. Examination revealed the same disease course, and ligation of eight perforator veins led to improvement in his condition. Seven months following this, follow-up CT revealed lesser contrast effects and a reduced size of the superficial veins. Echocardiography showed no right heart overload, and chronic heart failure was not exacerbated. No recurrence was observed during 15 months of follow-up.

Discussion

In cases of peripheral micro-AVFs in the lower extremity reported here, the micro-AVFs were so small that they could not be located accurately, and the symptoms dif-

fered markedly from those reported previously for AVF. AVF is known to cause ischemic symptoms. Micro-AVF causes congestive symptoms and remains undetected in most patients. In micro-AVF cases, therapy aimed at reducing pressure, such as the use of elastic bandages or stockings, is necessary, and the ligation of a superficial perforator vein is effective, as shown in this report. Recognition of this pathology is important because congestive symptoms in the lower extremities are frequently observed in daily practice and may cause refractory symptoms.

AVF, defined as an abnormal connection between the arterial and venous systems, can be congenital or acquired and may be located anywhere in the body. AVF can be distinguished from arteriovenous malformation on the basis of the presence of a nidus.¹⁾ AVF is characterized by direct connection between one or more arteries and veins, resulting in the high-pressure transfer of arterial blood into the venous system, increasing the venous pressure. This increased pressure causes several ischemic and congestive symptoms, depending on the location. AVF in the lower extremities can occur congenitally, such as in Kippel–Tre-naunay syndrome and congenital malformation, or may be an acquired condition. Although some groups have reported on acquired AVFs in the lower extremities, most cases exhibited ischemic symptoms resulting from iatrogenic injury, such as arterial puncture during coronary angiography or the insertion of a dialysis catheter.^{2,3)} Traumatic injury, such as blunt or penetrating trauma, can also cause AVF.^{4–6)} It can be detected in patients with increased resistance at the precapillary level because of frostbite, scleroderma, or emboli.⁶⁾ Chronic atheromatous arterial disease may be related to AVF incidence.^{6,7)} Long-term steroid use or other causes of increased vascular fragility, such as vasculitis, dialysis, and older age, are possible risk factors of AVF.⁶⁾ However, the patients described here had unremarkable past histories and congestive, rather than ischemic, symptoms. In our cases, AVFs could have formed owing to minor bruising during daily life, although no related details were revealed. The lack of previous reports indicates that spontaneous AVF in the lower extremities is extremely rare in routine clinical practice.⁵⁾ However, we believe that such cases are largely unrecognized, rather than being rare, according to our ongoing study.

The reported symptoms of AVF in the lower extremities include claudication, resting pain, refractory ulcers, foot gangrene, pulsing veins, and edema that are caused by arterial stealing phenomena and venous hypertension.⁶⁾ Generally, the major patient complaints are ischemic symptoms in the limb. Straton and Tisnado⁶⁾ reported five cases of AVF in the lower extremities, wherein all the patients presented with ischemic symptoms. We are unaware of any previous report wherein the patients' chief complaints were related to venous hypertension, although

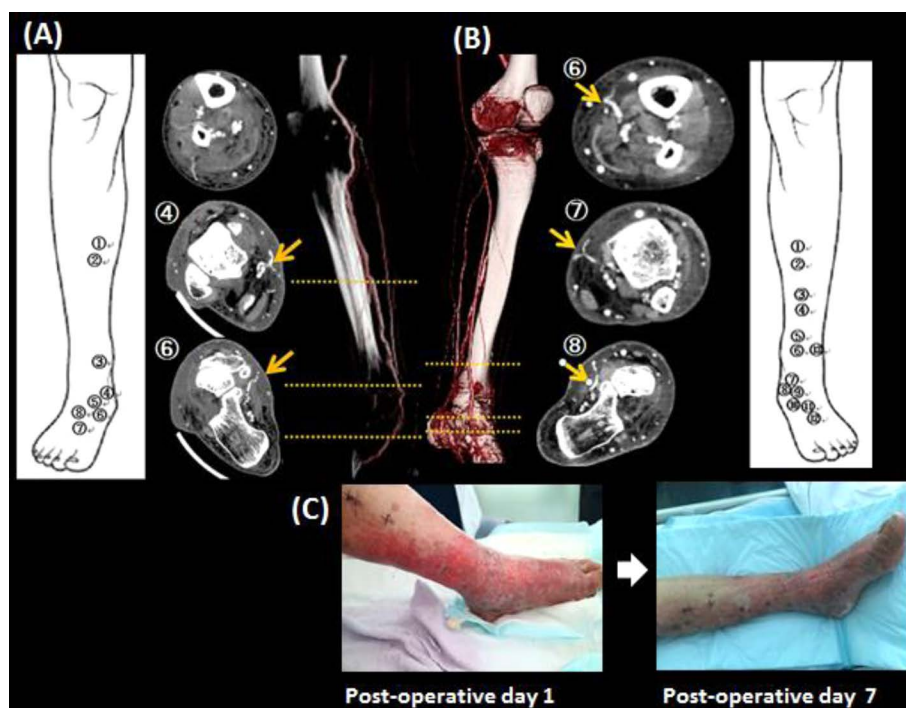


Fig. 2 Case 2 (A) and (B) Dynamic CT scan showing incompetent venous perforators, numbered on the schemas as part of the surgical preparation. (C) Preoperative and postoperative views of the limb. Lesion erosion and effusion had disappeared on post-operative day 7.

some reports have described symptoms related to arterial stealing phenomena caused by AVF. These phenomena implicate a different mechanism of AVF in the lower extremities, as in our patients.

Our patients had no previous medical history of iatrogenic injury, traumatic injury, or any other disease or factor known to lead to AVF development. They were initially diagnosed with lower-limb cellulitis causing unilateral lower-limb edema and redness. No ischemic symptoms were observed in our patients. These differences from past reports may be due to the location of the AVFs; more peripheral AVFs may contribute to higher superficial venous pressure relative to the arterial blood flow to the lower extremities. CT revealed early contrast filling in the dilated superficial veins from the dorsum pedis during the arterial phase, indicating the presence of one or more micro-AVFs in the peripheral foot. Classification of such peripheral micro-AVF cases into a new category, rather than as AVF causing ischemic symptoms as in past reports, may be appropriate because their therapeutic strategies are different.

Symptomatic AVFs must be repaired because spontaneous closure is rare.⁵⁾ Isolation or closure of the arteriovenous connection is the treatment goal. Recently used treatments have generally involved endovascular embolization, useful for complex AVFs with many feeding and draining vessels.¹⁾ Surgical ligation is the main treat-

ment for simple AVFs in superficial lesions, such as those arising after coronary angiography with a single connection between an afferent artery and vein. Selection of the appropriate treatment requires the identification of the anatomical location and the number of connecting vessels. However, accurate determination of the peripheral micro-AVF location is often impossible, as in our cases, making curative treatment of AVF extremely challenging. Micro-AVF presents with many symptoms related to perforator incompetence, and its severity differs, depending on the number of incompetent perforator vessels and the amount of superficial venous blood flow. Symptoms were more prevalent and severe in our second patient than in our first patient. Compression therapy to reduce the overall venous pressure is usually performed first. However, the focal high venous pressure cannot be reduced using only elastic bandages in the presence of substantial blood drainage through the AVF into the local superficial veins via the incompetent perforator veins. Ligation of these perforator veins effectively decreases the superficial venous pressure and reduces venous hypertension symptoms caused by micro-AVF, although it is ineffective for ischemic symptoms because it does not treat AVF directly. Ligation of the perforator veins alone is predicted to increase the pressure on the valves of the remaining normal perforators, leading to valve dysfunction and subsequent recurrence.⁵⁾ In

our case, the postoperative use of elastic stockings may have effectively reduced the superficial venous pressure, preventing recurrence.

Color-flow Doppler ultrasonography is useful for detecting AVF and incompetent perforators. Arterialized waveforms in dilated superficial veins on ultrasonograms indicate AVFs, and red coloration of the venous perforators indicates valve dysfunction and the possible need for ligation. The ligation was performed easily. First, we induced local anesthesia just above the incompetent perforator veins, searched for the perforators, and ligated them. We used Doppler ultrasonography to check for an arterial pulse sound to identify the competent perforators. We did not perform angiography following the diagnosis of peripheral micro-AVF using CT in our patients because neither of these imaging modalities can be used for the determination of micro-AVF location and the angiography resolution is poor. In addition, three-dimensional CT angiography enables simultaneous evaluation of the contralateral leg. Thus, CT is adequate for diagnosing micro-AVF, and angiography is unnecessary. The complete ligation of all perforator veins is the most important treatment aspect because the remaining perforator veins may cause more severe symptoms when they receive higher flows. CT is also useful for accurately marking the surgical locations. We first check the locations of all perforator veins on CT and then evaluate whether these veins have normal valve function. This approach can prevent the overlooking of incompetent perforators that require ligation.

AVFs in the lower extremities are generally easily diagnosed, based on the presence of ischemic symptoms because we perform CT for all patients with ischemic limbs. However, our ability to recognize the underlying symptoms of micro-AVFs related to venous hypertension, such as hemi-lower limb redness, swelling, and pain, remains insufficient. We now routinely perform ultrasonography for patients with lower-limb redness, swelling, and pain and are realizing that peripheral micro-AVF is not very rare. We suggest the inclusion of micro-AVF in the differential diagnosis of lower-limb edema. The definitive treatment for micro-AVFs is difficult because they are too small to be detected. The ligation of incompetent venous perforators effectively improves symptoms related to venous hypertension, and it can be performed in cases where compression therapy is ineffective or insufficient. Long-term follow-up is necessary because this treatment

is symptomatic, and thus far, long-term outcomes have not been examined sufficiently.

Conclusion

The pathology of micro-AVFs is markedly different from that of AVFs presented in past reports. The comprehension of micro-AVFs is important because they may cause refractory congestive symptoms, such as cellulitis and edema in the lower extremity, that are generally observed in routine clinical practice.

Disclosure Statement

The authors have no conflict of interest.

Author Contributions

Study conception: MT, FS

Data collection: MT, FS

Analysis: MT, FS, YN, KK, TA, HO, KY

Writing: MT, FS

Critical review and revisions: all authors

Final approval of the article: all authors

Accountability for all aspects of the work: all authors

References

- 1) Patel R, Nicholson AA. Arteriovenous fistulas: etiology and treatment. *Endovasc Today* 2012; 7: 45-51.
- 2) Altin RS, Flicker S, Naidech HJ. Pseudoaneurysm and arteriovenous fistula after femoral artery catheterization: association with low femoral punctures. *AJR Am J Roentgenol* 1989; 152: 629-31.
- 3) Mylankal KJ, Johnson B, Ettles DF. Iatrogenic arteriovenous fistula as a cause for leg ulcers: a case report. *Ann Vasc Dis* 2011; 4: 139-42.
- 4) Yilmaz AT, Arslan M, Demirkilic U, et al. Missed arterial injuries in military patients. *Am J Surg* 1997; 173: 110-4.
- 5) Davidovic L, Lotina S, Vojnovic B, et al. Post-traumatic AV fistulas and pseudoaneurysms. *J Cardiovasc Surg (Torino)* 1997; 38: 645-51.
- 6) Straton CS, Tisnado J. Spontaneous arteriovenous fistulas of the lower extremities: angiographic demonstration in five patients with peripheral vascular disease. *Cardiovasc Intervent Radiol* 2000; 23: 318-21.
- 7) Vallance R, Quin RO, Forrest H. Arterio-venous shunting complicating occlusive atherosclerotic peripheral vascular disease. *Clin Radiol* 1986; 37: 389-93.