



HISTOLOGICAL EFFECTS OF RAUWOLFIA VOMITORIA EXTRACT ON CARBON TETRACHLORIDE INDUCED HEPATOTOXICITY IN ADULT WISTAR RATS

Ezejindu D.N.¹, Okafor I. A.¹, & Anibeze C.I.P.²

¹Department of Anatomy, College of Health Sciences, Nnamdi Azikiwe University, Nnewi Campus. Anambra state, Nigeria.

²Department of Anatomy, College of Health Sciences, Abia State University, Uturu. Abia state, Nigeria.

³Department of Anatomy, College of Health Science, Imo State University Owerri, Imo state, Nigeria.

Abstract

More than 900 drugs, toxins and herbs have been reported to cause liver injury and drugs account for 20–40% of all instances of fulminant liver failure. In the absence of reliable liver protection drugs in modern medicine, a large number of medicinal preparations are recommended for the treatment of liver disorders and quite often claimed to offer significant relief. *Rauwolfia vomitoria* is a medical herb which has been used over the years for the treatment of hypertension, snakebite and nervous disorders. This study was carried out to determine the effects of *Rauwolfia vomitoria* on rats. Twenty four wistar rats weighing between 100–175g were used. The rats were divided into four groups A, B, C and D. Group A animals served as the control and received 0.35ml of distilled water. The experimental groups B, C and D received different doses of drugs as follows: group B received 0.55ml of extract of *Rauwolfia vomitoria*, group C received 0.41ml of CCl₄ and group D received 0.41ml of CCl₄ + 0.8ml of extract of *Rauwolfia vomitoria*. The drugs were administered using intubation method. Twenty four hours after the last administration, the animals were anaesthetized under chloroform vapour and were dissected. Liver tissues were removed, weighed and trimmed down to a size of 3mm×3mm and fixed in zenkers fluid for four hours for histological studies. The final body weight of group C treated with CCl₄ were significantly higher ($p < 0.001$) than the control and group B and D. The values for groups B and D were similar to that of the control group. Histological results showed distortions of liver architecture in group C and non distortions of liver architecture in group B and D compared to the control. The results revealed that the extract has hepatoprotective effects on drug induced hepatotoxicity of liver tissues.

Keywords: *Rauwolfia vomitoria*, Liver, Hepatotoxicity, Wistar rats.

1. Introduction

During the latter part of last century, the practice of herbalism became mainstream throughout the world. Herbs have been shown to have significant useful medicinal effects, either in their natural state or as the source of pharmaceuticals^[9]. One of the plants of medicinal value from the humid tropics is *Rauwolfia vomitoria*. It is traditionally used in treatment of variety of ailment such as snakebites, fever and nervous disorders.

From 1931, Indian doctors researched on possible utilization of *Rauwolfia vomitoria* in neuro-psychiatry. The extract from this plant was first extracted by Swiss chemists in 1952 and becomes the first natural neuroleptic. Today, this plant is still the source of a lot of drugs used in psychiatry^[5]. In traditional medicine, the roots and leaves of *Rauwolfia vomitoria* are brewed as tea and used in humans for treatment of hypertension, insanity, snakebite and cholera^[12].

A bioactive carboline alkaloid, alstonine, present in the root and leaf of *Rauwolfia vomitoria* have anti-cancer activity^[6,10] while the antipyretic effect of the leaf extract has also been demonstrated^[3]. Folk medicinal uses of the roots are extensive, particularly for their emetic, purgative, dysenteric, abortive and insecticidal properties^[11].

Liver is the key organ regulating homeostasis in the body. It is involved with almost all the biochemical pathways related to growth, fight against disease, nutrient supply, energy production and reproduction. Because of its unique metabolism and relationship to the gastrointestinal tract, the liver is an important target for toxicity produced by drugs, xenobiotics and oxidative stress.^[7] More than 900 drugs, toxins and herbs have been reported to cause liver injury and drugs account for 20–40% of all instances of fulminant liver failure. In the absence of reliable liver protection drugs in modern medicine, a large number of medicinal preparations are recommended for the treatment of liver disorders and quite often claimed to offer significant relief. Attempts are being made globally to get scientific evidences for these traditionally reported herbal drugs. This scenario provides a severe necessity to carry out research in the area of hepatotoxicity.^[4]

Hence, this study aims at painstakingly investigating the histological effects of *Rauwolfia vomitoria* extract on carbon tetrachloride induced hepatotoxicity in adult wistar rats.

2. Materials and Method

2.1 Drug Preparation

The drugs used for this research work include the following as stated below:

Rauwolfia vomitoria leaves were collected from Eket in Akwa Ibom State and was dried in an oven at a temperature of 50°C and crushed using laboratory blender. Extraction was done using ethanol. 300mg of this extract/kg body weight was dissolved in 10mls of distilled water and administered to the animals.

Carbon tetrachloride was obtained from the Department of Biochemistry, University of Calabar, Cross Rivers State, Nigeria.

2.2 Experimental Protocols

Twenty four Wistar rats were procured from the animal house of the Anatomy Department, University of Calabar, Cross-River State, Nigeria. They were bred in the experimental Animal House of University of Uyo, Akwa Ibom State. They were allowed for a period of five days for acclimatization under normal temperature (27°C -30°C) before their weights were taken. They were fed *ad libitum* with water and guinea feed pellets from Agro Feed Mill Nigeria Ltd.

The animals were allocated into four groups of six animals each. The groups were designated as groups A, B, C, and D. Group A animals served as the control and received 0.35ml of distilled water. The experimental groups B, C, and D received different doses of drugs as follows: Group B received 0.55ml of extract of *Rauwolfia vomitoria*, Group C received 0.41ml of carbon tetrachloride, while Group D received 0.8ml of extract plus 0.41ml of carbon tetrachloride. The drugs were administered once in a day between the hours of 12-3.30pm for a period of twenty one days. The drugs were administered orally using intubations method. After the twenty first day, the animals were weighed and their weight recorded.

Twenty four hours after the last administration, the animals were anaesthetized under chloroform vapour and were dissected. Liver tissues were removed from the animals and weighed. They were trimmed down to a size of 3mm x 3mm thick and fixed in zenkers fluid for four (4) hours for histological and histochemical studies.

2.3 Tissue Processing

For easy study of sections under microscope, the tissues passed through several processes of fixation, dehydration, clearing, infiltration, embedding, sectioning and staining. Fixation was carried out in zenkers fluid. The tissues remained in the fluid for four (4) hours. After fixation, the tissues were washed overnight under a stream tap water. Dehydration of the fixed tissues was carried out in different percentages of alcohol 50%, 70% and 95% absolute. After dehydration, tissues were cleared in xylene for two (2) hours after which infiltration was done in molten paraffin wax at a temperature of 60°C for two (2) hours, each in two changes and then sectioning of the tissues. We made use of hematoxylin and eosin method for histological studies

3. Result

3.1 Physical and Behavioural Changes

At the beginning of the experiments, all the animals looked healthy and agile. During the one week of acclimatization, their stool was normal. On administration of carbon tetrachloride, generally, these signs of toxicity were observed;

- Labored breathing
- Staggering / loss of balance
- Convulsion
- Decreased food intake

These signs were not observed following administration of *Rauwolfia vomitoria*.

3.2 Morphometric Analysis of Body Weight

Table 1.0: Comparison of mean initial and final body weight and weight change in all the groups (A,B,C &D)
(Mean \pm SEM given for each measurement)

	GP. A	GP. B	GP. C	GP. D	F-RATIO	PROB.OF SIG.
INITIAL BODY WT.	104.50 \pm 4.79	111.75 \pm 4.64	164.75 \pm 7.63	129.50 \pm 8.96	68.230	<0.0001
FINAL BODY WT.	112.50 \pm 6.60	121.50 \pm 10.66	133.25 \pm 8.53	137.75 \pm 10.01	30.510	<0.0001
WT. CHANGE	8.00 \pm 7.70	9.75 \pm 6.50	31.50 \pm 15.08	8.25 \pm 5.67	16.150	<0.0001

The final body weight for group A (Control), groups B, and D showed a statistically significant increase (P<0.001). The initial body weight for group C treated with carbon tetrachloride was significantly higher (P<0.001) than the control and other experimental groups (B and D) animals. The weight change for group C showed a statistically significant increase compared with the control and other experimental groups (P<0.001).

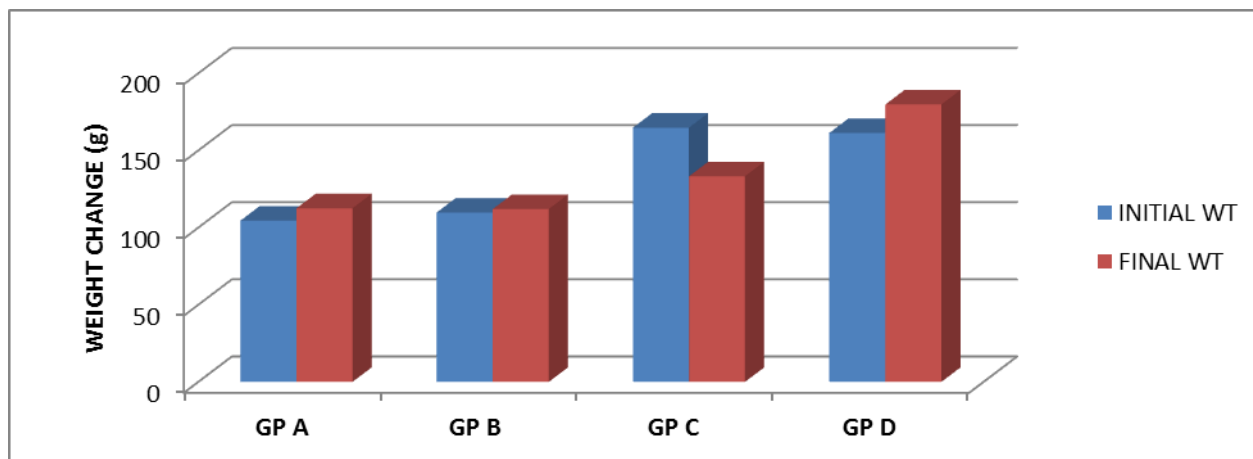


Figure 1.0 : The bar chat representation of the mean initial and final body weight

The weight of animals in group C were significantly higher ($P < 0.001$) than group A (Control) and groups B, D and F. before administration. After the administration, the weight of animals in group A (control) and group B, D increased statistically while the group C animals showed a significant decrease ($P < 0.001$) compared to the weight before administration.

3.3 Morphometric Analysis of Liver Weights

The results obtained from calculations of relative liver weight of the various groups are presented in table 2.0
 Table 2.0: comparison of mean relative liver weight for group A (control) and experimental groups (B,C,D). (Mean±SEM given for each measurement)

	GP. A	GP. B	GP. C	GP. D	F-RATIO	PROB. OF SIG.
LIVER WT.	4.79±0.045	4.66±0.161	7.33±0.625	4.72±0.070	53.84	<0.0001

The relative liver weight for group C (carbon tetrachloride administered) were significantly higher ($P < 0.001$) than that of the group A (control) and other experimental groups (B, and D). The values for groups B, D were similar to the group A (control)

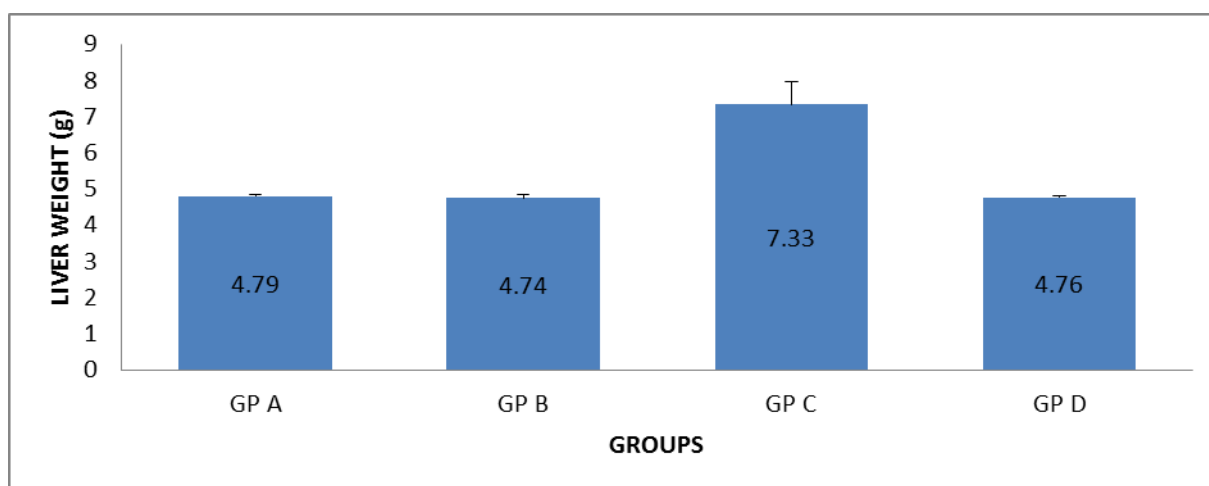


Figure 2.0: The bar chart representation of the relative liver weight of the various groups.

The group C (carbon tetrachloride administered) were significantly higher ($P < 0.001$) than the control group (A) and groups B, D.

3.4 Histopathological Findings

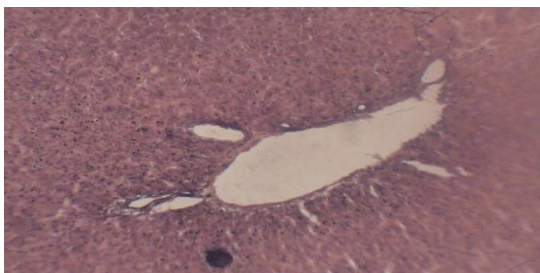


FIG. 3.0: MICROGRAPH 1 (Group A control)

The micrograph shows normal hepatic architecture. The central vein is prominent, and the radially placed hepatic cells are shown. The sinusoids are well dilated.

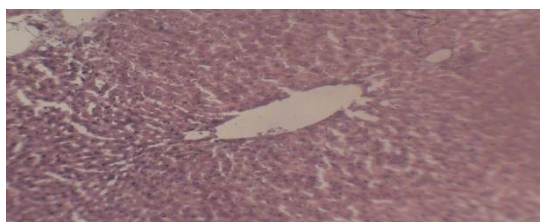


FIG. 4.0: MICROGRAPH 2 (Treated with *Rauwolfia vomitoria* extract; Group B)

The micrograph shows non-disruption of the liver architecture. The central vein and sinusoids are well distended and hepatic plates are differentiated. It indicates essentially normal liver histology.

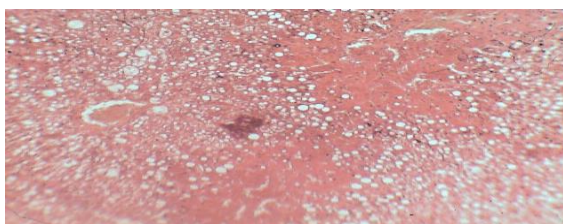

FIG. 5.0: MICROGRAPH 3 (Treated with carbon tetrachloride; Group C)

The micrograph shows distortion of the liver architecture. There is poor differentiation of the hepatic plates and loss of nuclei. There is also necrosis of the hepatocytes.

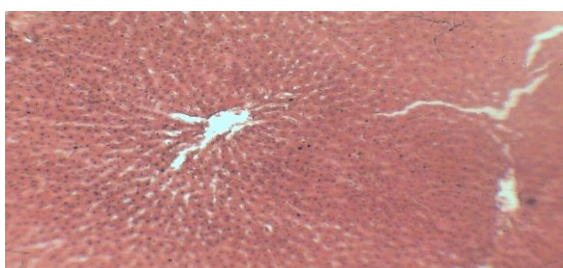

FIG. 6.0 MICROGRAPH 4 (Treated with *Rauwolfia vomitoria* extract + carbon tetrachloride; Group D)

The micrograph shows non-disruption of the liver architecture. The hepatocytes radiates from the central vein. The central vein and sinusoids are well distended and the hepatic plates are differentiated.

4. DISCUSSION

Carbon tetrachloride has toxicological effect on the liver, kidney and other visceral organs. Studies on the toxic effects of this chemical on the liver have been reported^[1]. These reports have all presented carbon tetrachloride as a hepatotoxin. The results of this study agree with previous researchers that carbon tetrachloride has toxicological effect on the liver of wistar rats (*Rattus norvegicus*). The liver showed necrosis, infiltration by inflammatory cells, congestion of the central vein and distortion of liver cell architectures. These results tend to agree with Ossowska et al, 1996^[8] that the effects of carbon tetrachloride toxicity are not easily reversible. It seems variance with Akpanabiatu et al, 2004^[2] who postulated that the effect of carbon tetrachloride toxicity on the liver was not long lasting and it was reversible.

It was also observed that the group in which the rats were treated with *Rauwolfia vomitoria* extract + carbon tetrachloride (i.e. group D) tolerated carbon tetrachloride in their system. There was no histological difference in the liver compared with the control. This may have contained antioxidant properties which protected the animals against the effect of carbon tetrachloride toxicity.

Observation of the body weight difference in groups reveals gradual increase in weight of animals for the control group A. This could have been physiological as the only substance they were exposed to was water and food. Comparing the results of weight difference reveals severe loss of weight by the carbon tetrachloride exposed group (C). This is probably as a result of loss of appetite by the animals in the group. The groups that were treated with extract of *Rauwolfia vomitoria* only (B), extract of *Rauwolfia vomitoria* + carbon tetrachloride (D), showed increase in weight which is similar to the control group. Extract of *Rauwolfia vomitoria* in this instance functions primarily as a dietary supplement enhancing growth. Previous researches cited in literatures of *Rauwolfia vomitoria* did not state pre and post experimental weight, hence weight changes were not determined in their works.

The relative organ weights also showed significant differences in groups. There was relative increase in liver weight for the carbon tetrachloride exposed animals compared to the control and groups B and D animals. This organ weight increase was irrespective of the fact that there was total body weight loss. This could have been pathological and one may deduce that the increase in liver weight was not growth but inflammation. Antioxidant properties of *Rauwolfia vomitoria* could have been responsible for the control or prevention of inflammation in the groups treated with it.

Administration of extract of *Rauwolfia vomitoria* alone did not cause weight loss to the animals compared with the animals in control group. By this observation, one may deduce that administration of extract of *Rauwolfia vomitoria* may boost the tolerance capacity for carbon tetrachloride induced toxicity. Thus, the protective effect of extract of *Rauwolfia vomitoria* against carbon tetrachloride induced liver damage recorded in the present study is attributed to their antioxidant properties.

5. Conclusion

The extract of *Rauwolfia vomitoria* did not induce any histopathological lesions in the liver tissues of the rats. Rat tissues are very similar in many aspects to those of human. The findings of this study suggests that *Rauwolfia vomitoria* administered to individuals exposed to carbon tetrachloride poisoning could provide some protection against carbon tetrachloride toxicity and perhaps ameliorate the effects of carbon tetrachloride toxicity on the liver.

6. Recommendation

This study has opened a way for possible means of preventing damage to man tissues by carbon tetrachloride. I recommend that extract from the root bark of this plant should be administered to see if it is possible to demonstrate a possible counter effect on the liver. However, further work is needed particularly on the effect of this drug on other organs like kidney, spleen etc.

References

- ¹Agency for Toxic Substances and Disease Registry (ATSDR). (2005). Toxicological profile for Carbon Tetrachloride (update). Atlanta, G.A U.S Department of Health and Human Services, Public Health Service.
- ²Akpanabiatu M.I., Igiri A. O. Eyong E.O, Eteng M.U. (2003). Biochemical and histological effects of Eleophorbia drupifera leaf extract in wistar albino rats. Pharm. Biol. 41: 96-99.
- ³Amole O.O., Onabanjo A.O. (1999). Antipyretic effect of the extract of *Rauwolfia vomitoria* (Afzel) in rabbits Nig. J. Nat. Prod. Med. 3: 77-78.
- ⁴Anusha M., M. Venkateswarlu, V. Prabhakaran, I S. Shareen Taj, B. Pushpa Kumari, and D. Ranganayakulu Hepatoprotective activity of aqueous extract of *Portulaca oleracea* in combination with lycopene in rats Indian Journal of Pharmacology. Sep-Oct 2011; 43(5)563
- ⁵Hansel R. (1968). Flavonoide, endaugestacting and vertedung ulcer daspflama system, wirking pharm press, China, pas. 6: 121-124.
- ⁶Demis, D.L., Capodice, J.L., Gorroochum, P., Katz, A.E., Buttyan, R., (2006): Antipoprater cancer activity of a \square -carboline alkaloid enriched extract from *Rauwolfia vomitoria*. *Int. J. Oncol.* 29 (5): 1065-1073.
- ⁷ Jaeschke H, Gores GJ, Cederbaum AI, Hinson JA, Pessayre D, Lemasters JJ. Mechanisms of hepatotoxicity. *Toxicol Sci.* 2002;65:166–76. [PubMed]
- ⁸ Ossowska K, Lorenc-Koci E, Schulze G, Wolfarth S (1996) The influence of dizocilpine (MK-801) on the reserpine-enhanced electromyographic stretch reflex in rats. *Neurosci Lett* 203:73–76.
- ⁹Perry, L.M. 1980. Medicinal Plants of East and Southeast Asia: Attributed Properties and Uses. MIT Press, Cambridge, Mass.
- ¹⁰Pettit DK, Hoffman AS, Horbett TA. (1994) *J Biomed Mater Res.* Jun;28(6):685-91. Correlation between corneal epithelial cell outgrowth and monoclonal antibody binding to the cell binding domain of adsorbed fibronectin.
- ¹¹Principe, P., (1989): The economic significance of plants and their constituents as drugs. In: Wagner, H., Hikino, H., Farnsworth, N.R., (Eds.), *Economic and Medicinal Research*, Vol. 3, Academic Press, London, pp. 1-17.
- ¹² Shavarov Z. (1965). The healing powers of herbs with special reference to obstetrics and gynaecology 43-44