

# Effects of maxillary molar intrusion with zygomatic anchorage on the stomatognathic system in anterior open bite patients

Seden Akan\*, Ilken Kocadereli\*\*, Alper Aktas\*\*\* and Ferda Taşar\*\*\*

\*Department of Orthodontics, Baskent University Istanbul Hospital and Departments of \*\*Orthodontics and,

\*\*\*Oral and Maxillofacial Surgery, Faculty of Dentistry, Hacettepe University, Ankara, Turkey

*Correspondence to:* Seden Akan, Baskent Üniversitesi Istanbul Uygulama ve Arastirma Hastanesi, Ortodonti Anabilim Dalı, Mahir İz Cad. No: 43, 34662 Altunizade, Istanbul, Turkey. E-mail: sedenakandt@hotmail.com

**SUMMARY** The aim of this study was to evaluate the effects of intrusion of the maxillary posterior teeth with zygomatic anchorage on the dentofacial system, on electromyographic (EMG) activity of the masticatory muscles, and on vibration of the temporomandibular joint. The study sample consisted of 19 subjects (13 females, 6 males) with a mean age of 17.7 years. Lateral cephalometric and posteroanterior (PA) radiographs, EMG, and electrovibratographic (EVG) records were obtained before (T0) and after (T1) intrusion. Paired *t*- and Wilcoxon signed ranks tests were used for statistical evaluation. Maxillary molar intrusion of  $3.37 \pm 1.21$  mm was obtained with a force of 400 g in an average period of  $6.84 \pm 1.64$  months. At T1, all measurements showed that facial growth direction, ANB angle, convexity, and overjet were decreased ( $P < 0.05$ ). SNB angle, facial depth, and overbite were significantly increased ( $P < 0.05$ ). Upper lip-E plane distance was increased ( $P < 0.05$ ). Evaluation of the PA radiographs showed that the right and left molar reference angles were unchanged. EMG and EVG analysis showed that the stomatognathic system at T0 was maintained at T1. Intrusion of the maxillary posterior teeth with zygomatic anchorage is an effective treatment alternative for anterior open bite correction.

## Introduction

An open bite is one of the main symptoms of an overall dentofacial deformity. Most subjects with an anterior open bite (AOB) are characterized by overeruption of the maxillary molars (Schudy, 1965). When orthodontic or surgical intrusion of the overerupted maxillary teeth is performed, the mandible rotates, resulting in open bite closure (Bell, 1980).

Intrusion of the molar teeth with traditional orthodontic mechanics is difficult. The multiloop edgewise archwire has been recommended for open bite closure in non-growing patients, but with this approach, the correction is achieved mainly through extrusion of the incisors without skeletal change (Kim, 1987; Kim *et al.*, 2000).

Until recently, there was no orthodontic approach for predictable intrusion of the maxillary posterior teeth in non-growing patients. Skeletal anchorage has been suggested for the orthodontic movement of teeth (Ödman *et al.*, 1988; Costa *et al.*, 1998; Kokich, 2000).

Due to increased interest in the functional aspects of the stomatognathic system, diagnosis of malocclusion and evaluation of the results of orthodontic treatment should not be restricted only to clinical and cephalometric evaluation. Facial musculature is directly and intimately related to the development of malocclusions; its correct functioning is fundamental in obtaining equilibrium of the stomatognathic system and treatment planning.

Electromyographic (EMG) analysis of the masticatory muscles, which has good reproducibility, provides useful data regarding the functional impact of morphological

discrepancies and permits functional evaluation of treatment of occlusal relationships (Ferrario *et al.*, 1999; Alarcón *et al.*, 2000). Currently, many areas of health care, such as medicine, physiotherapy, and speech therapy include superficial EMG examinations to assist in diagnoses, establishing a more accurate prognosis and accompanying muscular performance during various types of treatment. Despite its usefulness, no studies have evaluated the behaviour of these muscles in patients with an AOB treated with intrusion of the maxillary posterior teeth with zygomatic anchorage.

With developing technology, orthodontists must evaluate more than subjective findings (e.g. palpation and auscultation) when evaluating the temporomandibular joint (TMJ). There is a need to objectively assess the patient's joint health and document both pre-treatment conditions and the response to treatment.

Electrovibratography (EVG) is a method to objectively evaluate the TMJs and identify vibration patterns that help to distinguish primary TMJ dysfunction from other painful conditions. This method is the electronic recording of TMJ sounds that has a high specificity. TMJ sounds are frequently found among temporomandibular joint dysfunction (TMD) patients (Ishigaki *et al.*, 1992; Mazzetto *et al.*, 2008). It has been reported that certain groups of TMD patients show a higher incidence of TMJ sounds (Agerberg and Carlsson, 1975; Mazzetto *et al.*, 2008), and it is important to demonstrate the diagnostic specificity and sensitivity of these sounds (Elfving *et al.*, 2002).

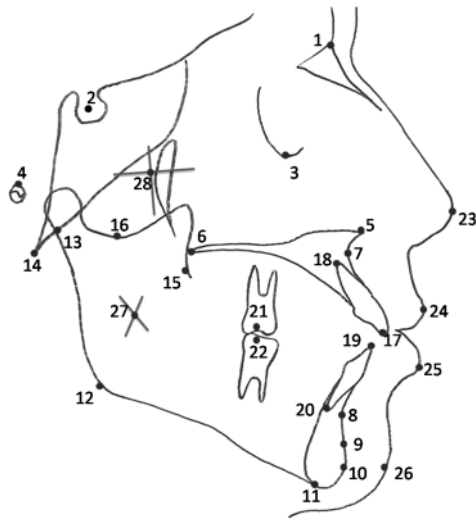
The aim of this study was to evaluate the effects of intrusion of the maxillary posterior teeth with zygomatic anchorage on the dentofacial system, on EMG activity of the masticatory muscles, and on joint vibration analysis of the TMJ in AOB patients.

## Subjects and methods

This research was approved by the ethics committee of Hacettepe University (LUT 06/90-4).

### Subject selection

This study included 19 patients (13 females, six males) with a mean age of 17.7 years (range: 13.1–25.9 years). Eight patients who had Class I occlusions were treated with upper

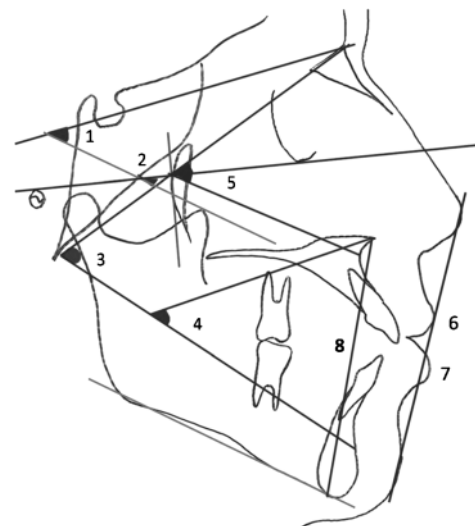


**Figure 1** Cephalometric landmarks used to evaluate changes in skeletal and dental structures and soft tissues. 1-N, nasion: most anterior point of the frontonasal suture in the midsagittal plane; 2-S, sella: centre of the sella turcica of the sphenoid bone; 3-Or, orbitale: lowest point in the inferior margin of the orbita; 4-Po, porion: most superior point of the external auditory meatus; 5-ANS, anterior nasal spine: tip of anterior nasal spine; 6-PNS, posterior nasal spine: tip of posterior nasal spine; 7- point A: most posterior point in the concavity between ANS and the dental alveolus; 8-point B: most posterior point in the concavity along the anterior surface of the symphysis; 9-Pm, suprapogonion: midpoint of the curve between B and Pogonion; 10-Pg, pogonion: most anterior point on the midsagittal symphysis; 11-Me, menton: the most inferior point of the symphysis; 12-Go, gonion: the most convex point along the inferior border of the ramus; 13-Ar, articulare: the point of intersection of the dorsal contour of the mandibular condyle and the temporal bone; 14-Ba, basion: the midpoint on the anterior margin of the foramen magnum of the occipital bone; 15-R1: most concave point on the anterior border of the ramus; 16-R3: most inferior border along the top of the ramus; 17-U1: tip of the maxillary central incisor; 18-U1a: root apex of the maxillary central incisor; 19-L1: tip of the mandibular central incisor; 20-L1a: root apex of the mandibular central incisor; 21-U6: central sulcus of the maxillary first molar; 22-L6: sulcus between mesial and middle tubercles of the mandibular first molar; 23-Pn, pronasale: tip of the nose; 24-Ls, labrale superior: most anterior point on the curve of the upper lip; 25-Li, labrale inferior: most anterior point on the curve of the lower lip; 26-Pog', soft-tissue pogonion: most anterior point of the soft-tissue chin; 27-Xi point: a point located at the centre of the ramus; 28-CF, Centre of face: point where the PTV and FH planes intersect.

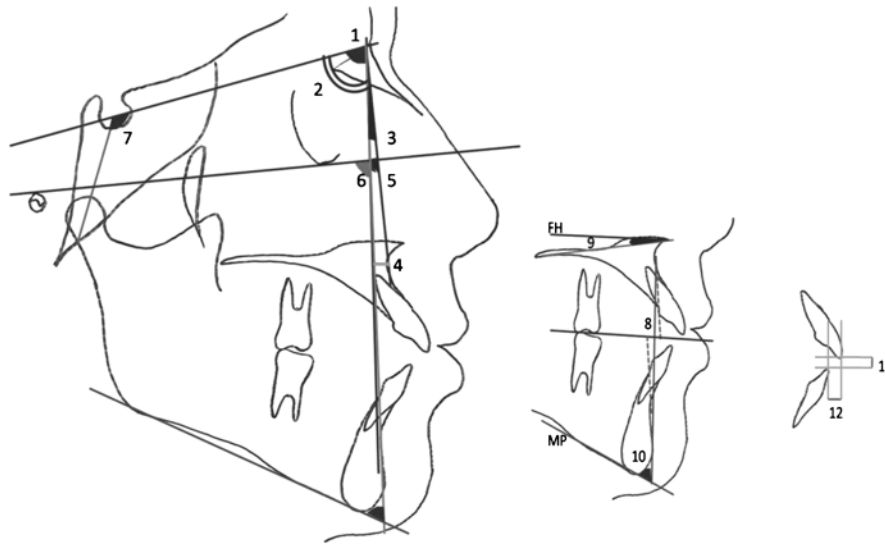
first premolar extractions and the 11 subjects with a Class II malocclusion with a non-extraction treatment approach. Treatment commenced with intrusion mechanics. At the end of intrusion, brackets were immediately bonded and fixed orthodontic therapy was initiated. At the start of treatment, all patient had an AOB greater than 1 mm; a mean of  $-3.21 \pm 1.37$  mm. Lateral cephalograms and posteroanterior (PA) radiographs were taken before (T0) and after (T1) intrusion. Treatment of the patients and manual tracing of the cephalograms was performed by one author (SA). Twenty-six measurements were made on each lateral cephalogram to assess the dental, skeletal, and soft tissue changes and two measurements on the PA radiographs to assess buccal tipping of the maxillary molars (Figures 1–5).

### Surgery

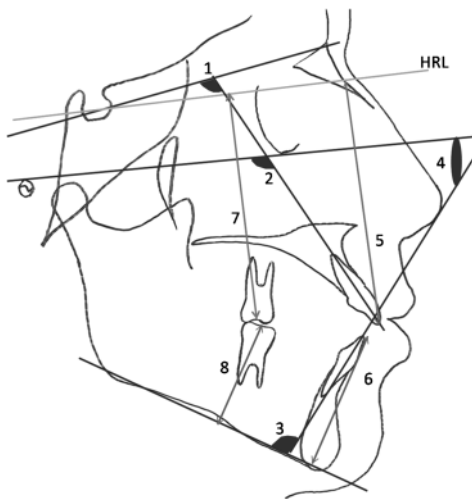
Placing of the miniplates was conducted by the same surgeon (AA). After rinsing the mouth for 1 minute with 0.2 per cent chlorhexidine gluconate, local anaesthetic was infiltrated bilaterally at the zygomatic process areas. A 1 cm vertical incision was made along the zygomatic buttress ending at the mucogingival junction. Using blunt dissection, the zygomatic process of the maxilla was totally exposed. An 'I' shaped titanium miniplate (Bollard ZygoAnchor: Surgi-Tec, Bruges, Belgium, Figure 6) was adjusted to fit the contour of the lower face of each zygomatic process and fixed by two or three bone screws (length 5 or 7 mm) with the long arm exposed to the oral cavity from the incised wound. The wound was closed and



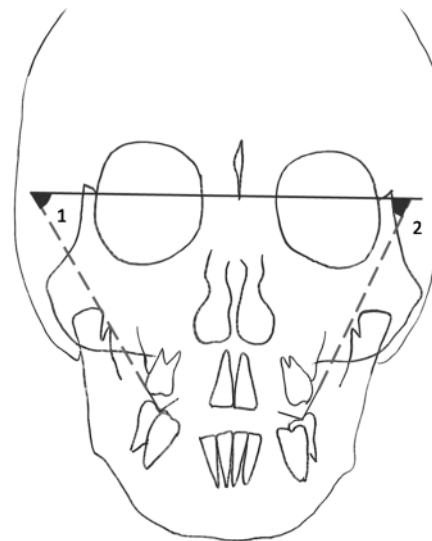
**Figure 2** Measurements used for evaluation of facial growth direction and aesthetic changes. 1-GoGnSN: angle formed by SN and the mandibular plane, 2-FMA: angle formed by Frankfort horizontal plane and the mandibular plane, 3-total face height: angle formed by the mandibular plane and N-CF, 4-lower face height: angle formed by Xi-ANS and Xi-Pm, 5-maxillary height: the angle between N-CF and CF-A, 6-upper lip-E plane: distance from Ls to the E-line, 7-lower lip-E plane: distance from Li to the E-line, 8-ANS-Me: line between ANS and Me.



**Figure 3** Measurements used for evaluation of maxillo-mandibular and dental changes. 1-SNA: angle formed by SN and NA, 2-SNB: angle formed by SN and NB, 3-ANB: angle formed by NA and NB, 4-convexity: distance from point A perpendicular to N-Pg, 5-facial depth: angle formed by NPg and FH, 6-maxillary depth: angle formed by NA and FH, 7-saddle angle: angle formed by SN and Sar, 8-wits appraisal: the distance between points A perpendicular to OP and B perpendicular to OP, 9-overbite depth indicator (ODI: 'PD-FH'+ 'AB-MD') 'PD-FH': angle formed by ANS-PNS and FH', 10-AB-MP: angle formed by AB and MP, 11-overbite: distance between U1i and L1i in the horizontal plane, 12: overjet: distance between U1i and L1i in the vertical plane.



**Figure 4** Measurements used for evaluation of dentoalveolar changes. 1-U1-SN: angle formed by the axial inclination of the maxillary incisor and SN, 2-U1-FH: angle formed by the axial inclination of the maxillary incisor and FH, 3-IMPA: angle formed by the axial inclination of the mandibular incisor and MP, 4-FMIA: angle formed by the axial inclination of the mandibular incisor and FH, 5-U1-HRL: perpendicular distance between U1 and the HRL plane, 6-L1-MD: perpendicular distance between L1 and the MP, 7-U6-HRL: perpendicular distance between U6 and the HRL plane, 8-L6-MD: perpendicular distance between L6 and the MP.



**Figure 5** Measurements used for evaluation of buccal tipping changes of the maxillary molar. 1-right molar reference angle: angle formed by right zygomaticofrontal suture (ZR) and right molar reference, 2-left molar reference angle: angle formed by left zygomaticofrontal suture (ZL) and left molar reference.

sutured. During the healing period, instructions were given to the patients on how to clean the wound area. Seven days later, the sutures were removed and force was applied to the miniplates.

When oral hygiene was poor, swelling and cheek irritation were experienced but recovered following recommendations for brushing of the miniplate and the surrounding mucosa. No miniplate failure was observed during treatment. In those patients that required fixed orthodontic therapy with maximum anchorage, the miniplate was left *in situ* until the end of treatment as anchorage. Otherwise, the miniplate was surgically removed at the end of intrusion, and fixed orthodontic treatment was commenced.

#### *Orthodontic treatment and fabrication of the appliance*

All patients received a standard, bondable fixed intraoral appliance constructed from 0.9 mm stainless steel round wire and adapted 3 mm away from the palate. To serve as a reference indicator on the radiographic records, a 0.5 mm stainless steel wire was placed in the acrylic plate (Figure 7). The intraoral appliance was bonded on the occlusal surfaces of the maxillary posterior teeth. A 9 mm nickel titanium closed coil spring (GAC International Inc., Bohemia, New York, USA) with an intrusive force of 400 g/per side was applied.

#### *Evaluation of TMJ and masticatory muscles*


To evaluate masticatory muscle activity during rest, maximum clenching and swallowing, EMG records were obtained with BioPAK records (version 2.03, BioResearch Associates Inc., Milwaukee, Wisconsin, USA) at T0 and T1.

The environment in which EMG and EVG recordings were obtained was calm, quiet, and semi-dark. The patients were seated in a comfortable upright position on an office chair, with the Frankfort plane parallel to the floor, with their feet on the floor, and arms resting on their thighs.

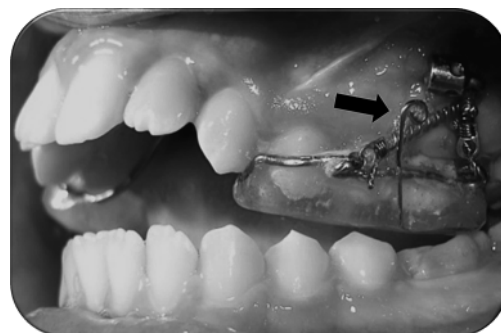
Single use bipolar surface electrodes and BioEMG 8 channel amplifier were used to obtain the EMG records

during physiological rest (for 10 seconds), maximum clenching, and swallowing of saliva. Before placing the electrodes, the patient's skin was cleaned with alcohol to eliminate any grease or other residue. The reference electrode was positioned over the clavicle and active differential electrodes on the belly of the masseter (MM), temporalis anterior (TA), digastricus anterior (DA), and sternocleidomastoid (SCLM) muscles on both the right and left sides (Figure 8A). The position of the electrodes was determined by palpation, and maximum voluntary contraction was performed to ensure that the muscles were accurately located. Muscle contractions, recorded during physiological activity using surface electrodes placed bilaterally, were measured in microvolts ( $\mu\text{V}$ ). Calibration values adjusted in the programme (20  $\mu\text{V}$  for rest position and 200  $\mu\text{V}$  for functional records) were not changed while taking the EMG records. Differences during function between the left and right muscle groups were checked and changes at T0 and T1 were evaluated.

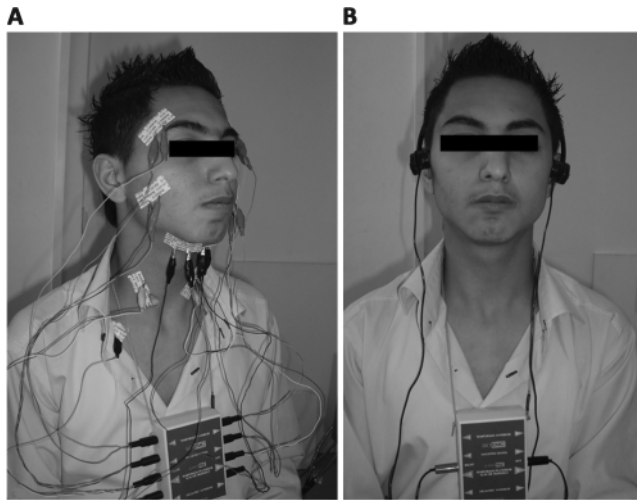
TMJ vibrations were evaluated by EVG at T0 and T1 using the BioJVA system (BioResearch Associates Inc.). This system, which has piezoelectric accelerometer sensors that were attached to the right and left TMJs, includes an amplifier to transfer and record the collected data (Figure 8B). After positioning the sensors, the patients were asked to open their mouths as wide as possible and maximum vertical opening was calculated by subtracting the amount of the AOB from the distance between the incisal edges of the upper and lower central incisors. The patient was asked to open and close their mouth, synchronized with a metronome working as the opening/closing time circle at 1.5 seconds on the computer screen. Measurements during opening and closing movements were undertaken separately for each EVG record. Three regions were selected on the vibration curve during both opening and closing movement. The average value was defined as the mean frequency of these three regions. The results were recorded as total integral ( $i$ ), which is the total amount of energy in the vibration, integral below 300 Hz ( $i < 300 \text{ Hz}$ ) above 300 Hz ( $i > 300 \text{ Hz}$ ).



**Figure 6** Schematic view of the zygomatic anchorage miniplate used in the study.



**Figure 7** Intraoral appliance used in study for intrusive force application.



**Figure 8** (A) Position of various active electrodes on the masticatory muscles in electromyographic analysis. (B) Position of the sensors in electrovibratographic analysis.

### Statistical analysis

The cephalometric variables, EMG, and EVG data were analysed using the Statistical Package for Social Sciences, version 16 (SPSS Inc., Chicago, Illinois, USA). The mean, standard deviation, minimum and maximum values were given as descriptive statistics. Normal distribution of permanent variables was investigated using the Shapiro–Wilk test. Variables with a normal distribution were evaluated using paired *t*-tests and those not normally distributed by Wilcoxon signed ranks test.  $P < 0.05$  was accepted as statistically significant.

To determine the method error of the radiographic measurement, 10 randomly selected lateral cephalograms and PA radiographs were remeasured by the same author (SA) after 2 weeks. To evaluate the method error, the formula of Dahlberg and intraclass correlation coefficients (*r*) were calculated. The method errors ranged from 0.4 to 0.7 mm for linear measurements and from 0.6 to 0.9 degrees for angular measurements. Intraclass correlation coefficients showed that the lowest correlation (0.867) was for maxillary depth and the highest (0.982) for U1-SN for angular measurements. For linear measurements, the lowest rate was 0.996 for overjet and the highest rate 0.927 for L6-MD.

### Results

The AOB was corrected in all patients. This was achieved by counter clockwise rotation of the mandible (on average 4.16 degrees,  $P < 0.05$ ) and maxillary molar intrusion (on average 3.37 mm,  $P < 0.05$ , Figure 9). Measurements on the PA radiographs showed that the maxillary molars were tipped slightly buccally, which was statistically insignificant (Table 1).

Comparison of the EVG records of the right and left TMJs while opening and closing the mouth at T0 and T1 is shown in Table 2. There were no significant differences between T0 and T1 ( $P > 0.05$ ). Evaluation of EMG rest measurements showed that there was no significant change in the investigated muscles between T0 and T1 ( $P > 0.05$ ; Table 2).

Table 2 shows the comparison of EMG measurements of the muscles at T0 and T1, during clenching. A statistically significant decrease was found only for MM left measurement ( $P < 0.05$ ).

At T0 and T1 during swallowing, both the left and right TA, MM, SCLM, and DA muscle groups showed no significant difference ( $P > 0.05$ ) (Table 2).

### Discussion

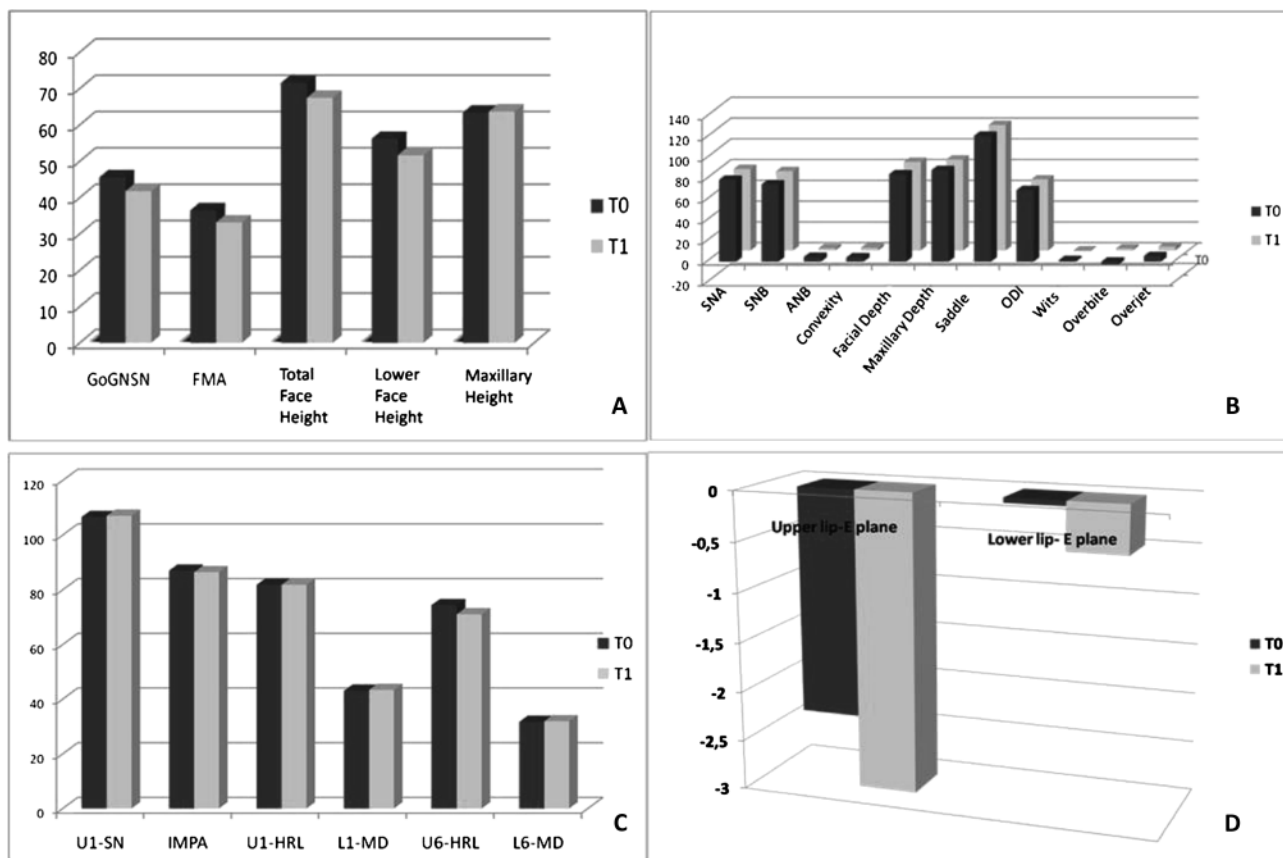
Skeletal anchorage allows management of some dentofacial deformities. Miniplates that can serve as absolute anchorage for the intrusion of overerupted teeth have been recommended (Costa *et al.*, 1998; Daimaruya *et al.*, 2001; Erverdi and Acar, 2005).

When segmental intrusion is required, the teeth can be grouped using segmental archwires or acrylic blocks which surround the crowns of the teeth. The intraoral appliance used in this study was made of two stainless steel bars with an acrylic block. It was hypothesized that the acrylic block would work as a bite block and thus some of the masticatory muscles would contribute to intrusion (Iscan and Sarisoy, 1997).

Applying an apically directed force to intrude maxillary posterior teeth will tip the molars buccally and impede intrusion. As a lingual force component must be applied to avoid this, two transpalatal bars made of 0.9 mm rigid wire were added to the intraoral appliance in this research. It has been hypothesized that an intrusion appliance that includes a transpalatal arch passing 3–5 mm away from palatal mucosa, similar to that used in the present study, has the additional advantage of an intermittent intrusive force of the tongue on the posterior teeth (McLaughlin and Bennett, 1991) and avoids irritation of the palatal mucosa (Erverdi *et al.*, 2004; Park *et al.*, 2005; Kravitz *et al.*, 2007; Xun *et al.*, 2007) during intrusion.

When evaluating intrusion, an adequate plane of reference is important because changes in these planes during treatment can clinically alter perception of the intrusion obtained (Kiliaridis *et al.*, 1989). A line 7 degrees below the sella–nasion (SN) plane was defined as the horizontal reference line and amount of molar intrusion was measured from U6 to this line. This line helps simulate natural head position and is minimally affected by treatment.

Park *et al.* (2003), who used an intrusion force of 200–300 g to the upper molars, observed no root resorption. Yao *et al.* (2004) applied a force of 150–200 g to each tooth during intrusion of the maxillary first and second



**Figure 9** Bar charts showing the changes in (A) facial growth direction, (B) dentoskeletal, (C) dental, and (D) soft tissue measurements.

molars. Erverdi *et al.* (2006) and Sugawara and Nishimura (2005) applied a 400 g intrusive force to the posterior segments which they blocked with acrylic. In the present study, similar to other investigations (Sugawara and Nishimura, 2005; Erverdi *et al.*, 2006), an intrusive force of 400 g was used on each maxillary posterior tooth segment.

Approximately 3.4 mm of molar intrusion was achieved in this study in approximately 6.8 months. Sherwood *et al.* (2002) achieved 2 mm of maxillary molar intrusion in 5.5 months and Erverdi *et al.* (2004) and Erverdi *et al.* (2007) 2.6 mm in 5.1 months and 3.6 mm in 9.6 months, respectively.

In the present study, GoGnSN angle was decreased by a mean of 3.8 degrees, FMA angle by a mean of 3.8 degrees, total face height angle by a mean of 3.9 degrees, ANS–Me distance by a mean of 2.8 mm, and upper face height angle by mean of 4.2 degrees ( $P < 0.05$ ). Thus mandibular autorotation occurred due to intrusion of the maxillary posterior teeth. As a result of mandibular anterior rotation, a 2.0 degree increase in SNB ( $P < 0.05$ ) and a 2.4 degree decrease in ANB ( $P < 0.05$ ) were observed. Overbite increased by 4.8 mm ( $P < 0.05$ ) and overjet decreased by 1.7 mm ( $P < 0.05$ ). Similar to other studies (Sherwood *et al.*, 2002; Erverdi *et al.*, 2004), statistically significant

decreases were found in wits appraisal, facial depth angle, and convexity.

Posteroanterior cephalometric analysis showed that there were no significant differences between T0 and T1 in right and left side measurements, indicating that use of an intraoral appliance prevents buccal tipping of the posterior teeth.

Many researchers have stated that joint differences should be evaluated in an open bite malocclusion subject even when there are no clinical TMD symptoms (Schellhas, 1989; Castelo *et al.*, 2005). The major problem in treating AOB patients is the loss of centric occlusion of the anterior teeth (Koak *et al.*, 2000). For this reason, anterior mandibular movement guidance is lost and an increasing rate of TMD frequently occurs because of interference from the posterior teeth (Kerstein and Farrell, 1990).

Tanaka *et al.* (2003) stated that there are dysfunctions in masticatory muscles and TMJs in most of open bite cases and that an unstable occlusion negatively affects stomatognathic system functions. Kuroda *et al.* (2007) reported successful treatment of a patient with a severe skeletal AOB and TMD by intruding the mandibular molars with titanium screw anchorage. Those authors suggested that molar intrusion with skeletal anchorage

**Table 1** Comparison of cephalometric measurements before (T0) and after (T1) intrusion ( $n:19$ ).

Measurement	T0	T1	Difference	<i>P</i>
SNA angle†	79.32 ± 4.04	79.00 ± 3.59	-0.32 ± 0.88	0.119
SNB angle†	74.21 ± 5.35	76.21 ± 4.40	2.00 ± 1.91	0.001*
ANB angle†	5.11 ± 2.81	2.79 ± 2.85	-2.42 ± 1.30	0.001*
Convexity (mm)†	4.68 ± 3.83	3.21 ± 4.28	-1.47 ± 1.47	0.001*
Facial depth angle††	83.84 ± 4.51	84.95 ± 4.47	1.11 ± 1.76	0.014*
Maxillary depth angle†	88.52 ± 3.81	88.00 ± 3.45	-0.52 ± 1.31	0.088
Saddle angle††	122.31 ± 6.42	121.74 ± 5.89	-0.58 ± 3.25	0.448
Overbite depth indicator (ODI)††	69.74 ± 4.84	69.16 ± 5.54	0.58 ± 2.43	0.314
Wits (mm)††	1.89 ± 3.86	0.01 ± 3.68	-1.89 ± 1.94	0.001*
Overbite†	-3.21 ± 1.37	1.58 ± 1.35	4.79 ± 1.36	0.001*
Overjet†	5.37 ± 3.53	3.68 ± 2.31	-1.68 ± 2.00	0.002*
GoGnSN angle††	45.58 ± 7.33	41.79 ± 7.29	-3.79 ± 1.87	0.001*
FMA angle††	36.32 ± 7.03	33.05 ± 6.91	-3.26 ± 1.56	0.001*
Total face height†	71.84 ± 7.25	67.89 ± 6.34	-3.94 ± 1.54	0.001*
Lower face height††	57.05 ± 4.92	52.84 ± 4.63	-4.16 ± 1.71	0.001*
ANS-Me (mm)††	82.22 ± 3.33	79.44 ± 3.38	-2.82 ± 0.07	0.001*
Maxillary height†	63.16 ± 4.63	63.58 ± 4.40	0.42 ± 2.01	0.714
U1-SN angle††	106.21 ± 6.24	106.68 ± 6.03	0.47 ± 3.17	0.523
U1-FH angle†	113.11 ± 8.93	114.95 ± 6.09	1.84 ± 6.77	0.252
IMPA†	86.63 ± 7.23	87.89 ± 6.88	-0.74 ± 2.86	0.448
FMIA†	55.74 ± 9.72	57.79 ± 9.09	2.05 ± 3.41	0.017*
U1-HRL (mm)††	81.89 ± 3.41	81.95 ± 3.39	0.05 ± 1.02	0.826
L1-MD (mm)†	43.47 ± 3.34	43.74 ± 3.19	0.26 ± 0.56	0.059
U6-HRL (mm)†	74.68 ± 4.41	71.32 ± 4.20	-3.37 ± 1.21	0.001*
L6-MD (mm)†	32.05 ± 3.29	31.21 ± 3.33	0.16 ± 0.83	0.429
Upper lip-E plane (mm)†	-2.26 ± 3.29	-3.00 ± 3.25	-0.74 ± 1.05	0.011*
Lower lip-E plane (mm)†	-0.05 ± 3.59	-0.47 ± 3.17	-0.42 ± 1.17	0.135
Right molar reference angle††	73.79 ± 12.05	74.42 ± 11.22	0.63 ± 6.38	0.671
Left molar reference angle††	75.53 ± 12.85	73.37 ± 13.37	-1.16 ± 7.79	0.526

†Tested with Wilcoxon test.

††Tested with paired *t*-test.\**P* < 0.05.

might be a useful treatment option to improve function, occlusion, and facial aesthetics in patients with a severe AOB and TMD.

EMG and EVG analysis permits evaluation of joint behaviour and muscle activity under various clinical conditions, as well as after skeletodental alterations resulting from intrusion of the maxillary posterior teeth. There are some studies (Umemori *et al.*, 1999; Erverdi *et al.*, 2002, 2004, 2006; Sherwood *et al.*, 2002; Park *et al.*, 2004; Yao *et al.*, 2005; Seres and Kocsis, 2009) that showed intrusion of the maxillary posterior teeth, but the functional effects of this therapy were not considered.

Sounds of TMJ could be the precursor of dysfunction in joints and muscles (Elfving *et al.*, 2002). Different disorders result in different vibration patterns (Oster *et al.*, 1984). It has been reported that subjects with TMJ disorders have a higher vibration energy level compared with healthy subjects of all frequency ranges and when intracapsular disorders in the TMJ develop this become symptomatic,  $i > 250$ – $300$  Hz of energy increase (Hutta *et al.*, 1987; Kiliaridis *et al.*, 1989; Ishigaki *et al.*, 1993). Mazzetto *et al.* (2008) stated that individuals with a normal condyle–disc relationship

show low vibration energy and underlined that evaluation of joint noises using EVG is important for diagnosis and treatment planning. Christensen and Orloff (1992) reported that repeatability of EVG records is high.

In the present study, it was observed that energy values  $i < 300$  Hz were significantly higher than those at T0 of  $i > 300$  Hz. As the study group comprised clinically asymptomatic individuals in terms of TMD, the low frequency energy value at T0 was not unexpected.

After intrusion of the maxillary posterior teeth, differences in total integral,  $i < 300$  Hz and  $i > 300$  Hz were not found to be statistically significant. Thus molar intrusion with zygomatic anchorage does not affect negatively on joint vibrations.

Without considering aetiology, dysfunctions in masticatory muscles such as muscle activity and unbalanced coordination are mostly observed in patients with an open bite (Lowe, 1980), but the relationship between occlusion and muscle functions has not yet been clarified (Lowe, 1980).

The effects of intrusion of the maxillary posterior teeth with zygomatic anchorage on the masticatory muscles were evaluated in this study using surface EMG which has been

**Table 2** Comparison of electrovibratographic (EVG) and electromyographic (EMG) data before (T0) and after (T1) intrusion ( $n:19$ ).

	T0	T1	Difference	P
Open mouth EVG				
Total integral R†	11.02 ± 10.92	8.45 ± 7.25	-2.56 ± 11.05	0.324
Total integral L†	11.64 ± 10.11	9.67 ± 9.05	-1.96 ± 11.56	0.426
$i < 300$ Hz R†	8.59 ± 9.02	6.10 ± 5.81	-2.49 ± 8.79	0.233
$i < 300$ Hz L†	9.14 ± 8.39	7.11 ± 6.39	-2.03 ± 8.13	0.291
$i > 300$ Hz R††	2.43 ± 1.90	2.25 ± 1.46	-0.17 ± 2.27	0.744
$i > 300$ Hz L†	2.53 ± 1.75	2.54 ± 1.82	0.01 ± 2.19	0.984
Closed mouth				
Total integral R†	10.14 ± 9.39	7.62 ± 5.71	-2.52 ± 10.89	0.327
Total integral L††	11.12 ± 13.95	10.04 ± 8.47	-1.08 ± 11.37	0.841
$i < 300$ Hz R†	7.74 ± 7.53	5.59 ± 4.72	-2.15 ± 8.65	0.293
$i < 300$ Hz L††	8.73 ± 11.61	7.29 ± 6.63	-1.43 ± 9.32	0.647
$i > 300$ Hz R††	2.38 ± 1.89	2.87 ± 4.06	0.49 ± 3.15	0.632
$i > 300$ Hz L††	2.41 ± 2.32	2.38 ± 1.47	-0.03 ± 2.15	0.523
EMG				
Rest TAR††	3.53 ± 1.76	2.95 ± 0.85	-0.58 ± 1.34	0.184
Rest TAL††	2.95 ± 1.44	3.92 ± 1.97	0.96 ± 2.16	0.067
Rest MMR††	3.74 ± 1.97	3.35 ± 2.03	-0.39 ± 2.69	0.144
Rest MML†	3.18 ± 1.51	2.85 ± 1.59	-0.34 ± 1.73	0.407
Rest SCLMR†	2.79 ± 2.25	2.27 ± 1.61	-0.25 ± 3.03	0.467
Rest SCLML†	4.06 ± 2.07	4.05 ± 1.79	-0.01 ± 2.85	0.987
Rest DAR†	4.24 ± 2.24	4.01 ± 1.80	-0.23 ± 2.63	0.706
Rest DAL†	3.57 ± 2.15	3.66 ± 1.69	0.09 ± 2.65	0.885
Swallow TAR†	7.14 ± 7.18	7.37 ± 3.92	0.23 ± 6.44	0.877
Swallow TAL†	6.38 ± 2.65	6.95 ± 3.65	0.56 ± 3.32	0.470
Swallow MMR††	8.87 ± 8.92	7.45 ± 4.65	-1.42 ± 10.09	0.586
Swallow MML†	7.02 ± 3.61	6.04 ± 3.35	-0.98 ± 3.20	0.200
Swallow SCLMR††	6.51 ± 6.87	4.04 ± 2.40	-2.46 ± 6.06	0.201
Swallow SCLML†	6.05 ± 2.92	5.18 ± 1.84	-0.86 ± 2.67	0.176
Swallow DAR†	18.87 ± 9.11	16.27 ± 7.66	-2.60 ± 7.65	0.156
Swallow DAL†	17.02 ± 7.57	16.59 ± 6.34	-0.43 ± 6.14	0.766
Clench TAR†	41.81 ± 18.96	39.78 ± 23.19	-2.02 ± 20.29	0.669
Clench TAL†	34.64 ± 18.20	31.97 ± 17.52	-2.67 ± 15.63	0.466
Clench MMR†	34.56 ± 25.34	30.96 ± 23.00	-3.60 ± 28.93	0.594
Clench MML†	36.81 ± 21.12	28.54 ± 16.87	-8.27 ± 15.88	0.036*
Clench SCLMR††	8.07 ± 7.72	6.52 ± 7.09	-1.56 ± 10.72	0.209
Clench SCLML††	6.68 ± 4.09	5.12 ± 2.49	-1.56 ± 5.03	0.184
Clench DAR††	11.01 ± 10.72	9.48 ± 6.87	-1.53 ± 10.01	0.463
Clench DAL††	10.22 ± 7.87	10.31 ± 9.53	0.09 ± 6.91	0.952

†Tested with paired  $t$ -test.

††Tested with Wilcoxon test.

\* $P < 0.05$ .

shown to be a repeatable method (Burdette and Gale, 1990; Ferrario *et al.*, 1991). Rest EMG values for the MM of 0.5–1.4  $\mu$ V and for TA of 1.0–1.9  $\mu$ V are quoted for healthy individuals (BioPak; Ferrario *et al.*, 1993). Normal values stated for DA and SCLM muscles range between 1.0 and 1.5  $\mu$ V (BioPak). For the participants in the present study, resting EMG values for all muscles at T0 and T1 were higher than these normal values. There were no statistically significant differences between T0 and T1 for DA and SCLM muscles.

There is a converse relationship between vertical dimension and elevator muscle activity (Proffit and Fields, 1983). In open bite cases, muscle activity is expected to decrease because of growth in the vertical direction (Proffit and Fields, 1983; Bakke *et al.*, 1990). However, weak muscle activity may also cause an open bite (Kiliaridis *et*

*al.*, 1989); so an increase of masticatory muscle activity will contribute to long-term stability. The zygomatic anchorage plate and intraoral appliance combination used in this study had a decreasing effect (although not significant) on masticatory muscle activity. Long-term stability and masticatory muscle activity should be evaluated.

It has been stated that TA shows 161.7–181.9  $\mu$ V and MM 156.8–216.2  $\mu$ V electric activity when clenching in healthy individuals (Ferrario *et al.*, 1993). In the current research, EMG values of TA and MM muscles were found to be lower than these amounts during clenching. After treatment, except for a slight increase in the right DA muscle, all muscle activity was found to be generally decreased; however, these decreases were not statistically significant. Treatment mechanics and more importantly the



acrylic block included in the intraoral appliance used could have affected muscle activity.

Non-significant changes in EMG activities were also found during swallowing. During swallowing, except for the left TA, all the muscle activity was decreased. In normal individuals, TA and MM work bilaterally during swallowing, with the MM muscle being the most active (BioPak). Because the mouth is closed while swallowing, DA is minimally active (BioPak). In this study, in agreement with the data, TA and MM muscles worked symmetrically, whereas the DA muscle demonstrated high activity, contrary to the literature. This may be due to the decrease in swallowing activity of the tongue during the 6 months of treatment with acrylic blocks. In individuals with an open bite, the tongue is trying to make an oral seal by using the teeth while swallowing. It is accepted that this activity of the tongue in individuals with an open bite causes abnormal swallowing patterns (Stormer and Pancherz, 1999).

There are a number of limitations in the present study: the sample size was small with a large age range, the surface electrodes can detect only myoelectrical activity near the electrode and cannot measure actual physical force production of the muscles, and joint vibration analysis can be affected by external vibrations. However, as EMG and EVG analysis application were non-invasive, patient compliance was good.

## Conclusions

Cephalometric measurements showed that the vertical dimension was decreased on average by 3.37 mm due to maxillary molar intrusion. In addition, an average of 4.16 degrees of mandibular anterior autorotation was achieved after intrusion of the maxillary posterior teeth. Intrusion of the maxillary posterior teeth using zygomatic bone anchorage and an intraoral appliance is a successful treatment alternative for open bite correction and has, within the limitations of the recording system used, no recordable effects on the TMJs and masticatory muscles.

## References

- Agerberg G, Carlsson G E 1975 Symptoms of functional disturbances of the masticatory system. A comparison of frequencies in a population sample and in a group of patients. *Acta Odontologica Scandinavica* 33: 183–190
- Alarcón J A, Martín C, Palma J C 2000 Effect of unilateral posterior crossbite on the electromyographic activity of human masticatory muscles. *American Journal of Orthodontics and Dentofacial Orthopedics* 118: 328–334
- Bakke M, Holm B, Jensen B L, Michler L, Møller E 1990 Unilateral, isometric bite force in 8–68-year-old women and men related to occlusal factors. *Scandinavian Journal of Dental Research* 98: 149–158
- Bell W H 1980 Surgical correction of dentofacial deformities. Saunders, Philadelphia
- Burdette B H, Gale E N 1990 Reliability of surface electromyography of the masseteric and anterior temporal areas. *Archives of Oral Biology* 35: 747–751
- Castelo P M, Gavião M B, Pereira L J, Bonjardim L R 2005 Relationship between oral parafunctional/nutritive sucking habits and temporomandibular joint dysfunction in primary dentition. *International Journal of Paediatric Dentistry* 15: 29–36
- Christensen L V, Orloff J 1992 Reproducibility of temporomandibular joint vibrations (electrovibratography). *Journal of Oral Rehabilitation* 19: 253–263
- Costa A, Raffaini M, Melsen B 1998 Miniscrews as orthodontic anchorage: a preliminary report. *International Journal of Adult Orthodontics and Orthognathic Surgery* 13: 201–209
- Daimaruya T, Nagasaka H, Umemori M, Sugawara J, Mitani H 2001 The influences of molar intrusion on the inferior alveolar neurovascular bundle and root using the skeletal anchorage system in dogs. *Angle Orthodontist* 71: 60–70
- Elfving L, Helkimo M, Magnusson T 2002 Prevalence of different temporomandibular joint sounds, with emphasis on disk-displacement, in patients with temporomandibular disorders and controls. *Swedish Dental Journal* 26: 9–19
- Erverdi N, Acar A 2005 Zygomatic anchorage for enmasse retraction in the treatment of severe Class II division 1. *Angle Orthodontist* 75: 483–490
- Erverdi N, Keles A, Nanda R 2004 The use of skeletal anchorage in open bite treatment: a cephalometric evaluation. *Angle Orthodontist* 74: 381–390
- Erverdi N, Tosun T, Keles A 2002 A new anchorage site for the treatment anterior openbite: zygomatic anchorage case report. *World Journal of Orthodontics* 43: 147–153
- Erverdi N, Usumez S, Solak A 2006 New generation open-bite treatment with zygomatic anchorage. *Angle Orthodontist* 76: 519–526
- Erverdi N, Usumez S, Solak A, Koldas T 2007 Noncompliance open-bite treatment with zygomatic anchorage. *Angle Orthodontist* 77: 986–990
- Ferrario V F, Sforza C, Serrao G 1999 The influence of crossbite on the coordinated electromyographic activity of human masticatory muscles during mastication. *Journal of Oral Rehabilitation* 26: 575–581
- Ferrario V F, Sforza C, Miani A Jr., D'Addona A, Barbini E 1993 Electromyographic activity of human masticatory muscles in normal young people. Statistical evaluation of reference values for clinical applications. *Journal of Oral Rehabilitation* 20: 271–280
- Ferrario V F S, D'Addona C, Miani A Jr. 1991 Reproducibility of electromyographic measures: a statistical analysis. *Journal of Oral Rehabilitation* 18: 513–521
- Hutta J L, Morris T W, Katzberg R W, Tallents R H, Espeland M A 1987 Separation of internal derangements of the temporomandibular joint using sound analysis. *Oral Surgery, Oral Medicine, Oral Pathology* 63: 151–157
- Iscan H N, Sarisoy L 1997 Comparison of the effects of passive posterior bite-blocks with different construction bites on the craniofacial and dentoalveolar structures. *American Journal of Orthodontics and Dentofacial Orthopedics* 112: 171–178
- Ishigaki S, Bessette R, Maruyama T 1992 The distribution of internal derangement in patients with temporomandibular joint dysfunction: prevalence, diagnosis and treatments. *Cranio* 10: 289–296
- Ishigaki S, Bessette R W, Maruyama T 1993 Vibration of the temporomandibular joints with normal radiographic imagings: comparison between asymptomatic volunteers and symptomatic patients. *Cranio* 11: 88–94
- Kerstein R B, Farrell S 1990 Treatment of myofascial pain-dysfunction syndrome with occlusal equilibration. *Journal of Prosthetic Dentistry* 63: 695
- Kiliaridis S, Mejersjo C, Thilander B 1989 Muscle function and craniofacial morphology: a clinical study in patients with myotonic dystrophy. *European Journal of Orthodontics* 11: 131–138
- Kim Y H 1987 Anterior openbite and its treatment with multiloop edgewise archwire. *Angle Orthodontist* 57: 290–321
- Kim Y H, Han U K, Lim D D, Serrao M L 2000 Stability of anterior openbite correction with multiloop edgewise archwire therapy: a

- cephalometric follow-up study. *American Journal of Orthodontics and Dentofacial Orthopedics* 118: 43–54
- Koak J Y, Kim K N, Heo S J 2000 A study on the mandibular movement of anterior openbite patients. *Journal of Oral Rehabilitation* 27: 817–822
- Kokich V G 2000 Comprehensive management of implant anchorage in the multidisciplinary patient. In: Higuchi K W (ed). *Orthodontic applications of osseointegrated implants* Quintessence, Carol Stream, pp. 21–32
- Kravitz N D, Kusnoto B, Tsay T P, Hohlt W F 2007 The use of temporary anchorage devices for molar intrusion. *Journal of the American Dental Association* 138: 56–64
- Kuroda S, Sugawara Y, Tamamura N, Takano-Yamamoto T 2007 Anterior open bite with temporomandibular disorder treated with titanium screw anchorage: evaluation of morphological and functional improvement. *American Journal of Orthodontics and Dentofacial Orthopedics* 131: 550–560
- Lowe A A 1980 Correlations between orofacial muscle activity and craniofacial morphology in a sample of control and anterior open-bite subjects. *American Journal of Orthodontics* 78: 89–98
- Mazzetto M O, Hotta T H, Carrasco T G, Mazzetto R G 2008 Characteristics of TMD noise analyzed by electrovibratography. *Cranio* 26: 222–228
- McLaughlin R P, Bennett J C 1991 Anchorage control during leveling and aligning with a preadjusted appliance system. *Journal of Clinical Orthodontics* 25: 687–696
- Oster C *et al.* 1984 Characterization of temporomandibular joint sounds. A preliminary investigation with arthrographic correlation. *Oral Surgery, Oral Medicine, Oral Pathology* 58: 10–16
- Ödman J, Lekholm U, Jemt T, Brånemark P I, Thilander B 1988 Osseointegrated titanium implants—a new approach in orthodontic treatment. *European Journal of Orthodontics* 10: 98–105
- Park H S, Jang B K, Kyung H M 2005 Maxillary molar intrusion with micro-implant anchorage (MIA). *Australian Orthodontic Journal* 21: 129–135
- Park H S, Kwon T G, Kwon O W 2004 Treatment of open bite with microscrew implant anchorage. *American Journal of Orthodontics and Dentofacial Orthopedics* 126: 627–636
- Park Y C, Lee S Y, Kim D H, Jee S H 2003 Intrusion of posterior teeth using mini-screw implants. *American Journal of Orthodontics and Dentofacial Orthopedics* 123: 690–694
- Proffit W R, Fields H W 1983 Occlusal forces in normal- and long-face children. *Journal of Dental Research* 62: 571–574
- Schellhas K P 1989 Unstable occlusion and temporomandibular joint disease. *Journal of Clinical Orthodontics* 23: 332–337
- Schudy F F 1965 The rotation of the mandible resulting from growth: its implications in orthodontic treatment. *Angle Orthodontist* 35: 36–50
- Seres L, Kocsis A 2009 Closure of severe skeletal anterior open bite with zygomatic anchorage. *Journal of Craniofacial Surgery* 20: 478–482
- Sherwood K H, Burch J G, Thompson W J 2002 Closing anterior open bites by intruding molars with titanium miniplate anchorage. *American Journal of Orthodontics and Dentofacial Orthopedics* 122: 593–600
- Stormer K, Pancherz H 1999 Electromyography of the perioral and masticatory muscles in orthodontic patients with atypical swallowing. *Journal of Orofacial Orthopedics* 60: 13–23
- Sugawara J, Nishimura M 2005 Minibone plates: the skeletal anchorage system. *Seminars in Orthodontics* 11: 47–56
- Tanaka E, Iwabe T, Watanabe M, Kato M, Tanne K 2003 An adolescent case of anterior open bite with masticatory muscle dysfunction. *Angle Orthodontist* 73: 608–613
- Umemori M, Sugawara J, Mitani H, Nagasaka H, Kawamura H 1999 Skeletal anchorage system for open-bite correction. *American Journal of Orthodontics and Dentofacial Orthopedics* 115: 166–174
- Xun C, Zeng X, Wang X 2007 Microscrew anchorage in skeletal anterior open-bite treatment. *Angle Orthodontist* 77: 47–56
- Yao C C, Lee J J, Chen H Y, Chang Z C, Chang H F, Chen Y J 2005 Maxillary molar intrusion with fixed appliances and mini-implant anchorage studied in three dimensions. *Angle Orthodontist* 75: 754–760
- Yao C C, Wu C B, Wu H Y, Kok S H, Chang H F, Chen Y J 2004 Intrusion of the overerupted upper left first and second molars by mini-implants with partial-fixed orthodontic appliances: a case report. *Angle Orthodontist* 74: 550–557