Helminth Fauna of Carnivores distributed in North-Western Tohoku, Japan, with Special Reference to *Mesocestoides paucitesticulus* and *Brachylaima tokudai*

Hiroshi SATO, Yasushi IHAMA, Takashi INABA, Makoto YAGISAWA and Haruo KAMIYA*
Department of Parasitology, Hirosaki University School of Medicine, 5 Zaifu-cho, Hirosaki 036–8562, Japan
(Received 8 June 1999/Accepted 25 August 1999)

ABSTRACT. In the winter of 1998–1999, we collected parasitological data from 54 wild carnivores in the north-western part of Tohoku region, Japan. These consisted of 38 martens (*Martes melampus melampus*), 14 raccoon dogs (*Nyctereutes procyonoides viverrinus*) and 2 foxes (*Vulpes vulpes japonica*). Collected helminth parasites were 11 nematode, 10 trematode, 3 cestode, and a single acanthocephalan species, including 5 hitherto unknown species for this research area or the mainland of Japan (Honshu). *Mesocestoides paucitesticulus* was for the first time recorded from martens as well as from carnivores distributed in Honshu. *Brachylaima tokudai* originally recorded from *Urotrichus talpoides* in the central part of Honshu was for the first time found from a raccoon dog.—KEY WORDS: helminth, *Martes melampus*, *Nyctereutes procyonoides*.

J. Vet. Med. Sci. 61(12): 1339–1342, 1999

Our previous report [12] added several helminth species that had not been recorded from carnivores distributed in the north-western part of Tohoku region, Japan [15]. These are *Taenia polyacantha* from foxes (*Vulpes vulpes japonica*), *Pygidiopsis summa* from a raccoon dog (*Nyctereutes procyonoides viverrrinus*), *Eucoleus aerophilus*, *Aonchotheca putorii*, and *Soboliphyme baturini* from martens (*Martes melampus melampus*). But, still remain more helminth species to be recorded. For example, we found destrobilates of unarmed cestodes from the small intestine of martens. Fortunately, our recent survey on wild carnivores collected from October, 1998 to March, 1999 found their strobilae that are critical for species identification.

All examined carcasses of wild carnivores were obtained from a taxidermist living in Hirosaki, Aomori Pref., after his process. These included 38 martens, 14 raccoon dogs, and 2 foxes. Of them, 31 martens, 13 raccoon dogs and one fox were collected in 21, 10 and one administrative units, respectively, of the western part of Aomori Pref., so-called Tsugaru area. The rests were collected in 5 administrative units of the northern part of Akita Pref. Parasitological examinations were carried out as described previously [12].

As shown in Table 1, 11 nematode, 10 trematode, 3 cestode, and a single acanthocephalan species were found from examined animals. Five helminth species were firstly collected from carnivores distributed in this research area: *Mesocestoides paucitesticulus* Sawada *et* Kugi, 1973, *Metagonimus miyatai* Saito, Chai, Kim, Lee *et* Rim, 1997, *Brachylaima tokudai* Yamaguti, 1954, *Pterothominx* sp. (Capillaridae) of Uchida, Uchida, Murata *et* Udagawa, 1984, and *Pearsonema plica* (Rudolphi, 1819) Moravec, 1982. In addition, miliary white nodules caused by the protozoon, *Hepatozoon* sp., were found in the heart and diaphragm of 11 martens.

M. paucitesticulus was collected from the small intestine of 7 martens (2 males and 5 females) caught in Fukaura, Goshogawara, Imabetsu, Iwaki, Kanagi, or Nishimeya, Aomori Pref. and Kazuno, Akita Pref. as well as one female raccoon dog caught in Fukaura, Aomori Pref. From all animals except for one marten, destrobilated adults were found, ranging one to 104 per animal in number. Recovered strobilae were a few and lacked gravid proglottides (Fig. 1), and their measurements were partly possible (Table 2). Adults of *M. paucitesticulus* have been recorded only from raccoon dogs, foxes and dogs collected in Shikoku (Ehime Pref.) and Kyushu islands (Oita Pref.) of Japan [4–6, 13]. Accordingly, this species is for the first time recorded from martens as well as from carnivores distributed in the mainland of Japan (Honshu). The other species, *M. lineatus* having more than 60 testes in number, distributes also in Japan, and natural definitive hosts for it include dogs, cats, foxes, raccoon dogs and martens. Only the latter species has been recorded from 14 human patients living in the central part of Honshu [7, 8]. In addition, Kamiya and Ohbayashi [3] recorded destrobilated adults of unidentified *Mesocestoides* sp. from a *V. vulpes schrencki* in Hokkaido island of Japan.

Four adult flukes of *M. miyatai* were recovered from the small intestine of one male raccoon dog collected in Kizukuri, Aomori Pref. Flukes measuring 0.724–0.908 mm by 0.296–0.449 mm were flattened, somewhat footsole-shaped, and covered with conspicuous, scale-shaped spines particularly in anterior half of body (Fig. 2). Main measurements of the flukes were identical with the original description [11]. *M. yokagawai* and *M. takahashii* have been occasionally found from raccoon dogs and foxes caught in northern Tohoku [12, 15]. Furthermore, metacercariae of *M. otsurui* have been recorded from gobiid freshwater fishes, *Tridentiger brevispinis*, collected in the eastern part of Aomori Pref. [10]. In addition to these 3 species, we firstly confirm the distribution of *M. miyatai* in Aomori Pref. This species is known to cause a zoonosis in Korea [11].

* CORRESPONDENCE TO: KAMIYA, H., Department of Parasitology, Hirosaki University School of Medicine, 5 Zaifu-cho, Hirosaki 036–8562, Japan.

Table 1. Helminth parasites found from wild carnivora (23 male and 15 female martens, 8 male and 6 female raccoon dogs, and 2 female foxes) in the north-western part of Tohoku region, Japan

Helminth species	Location	Hosts (% of incidence)
[Nematoda]		
Trichuris vulpis	large intestine	foxes (100%)
Aonchotheca putorii	stomach	martens (71%)
* *Pterothominx* sp. of Uchida *et al.*, 1984	stomach	raccoon dogs (14%)
* *Pearsonema plica*	urinary bladder	martens (5%)
Ancylostoma kusimaense	small intestine	raccoon dogs (86%); foxes (50%)
Arthrostoma miyazakiense	small intestine	raccoon dogs (64%); foxes (50%)
Molineus legerae	small intestine	raccoon dogs (21%); foxes (50%)
Molineus patens	small intestine	martens (45%)
Soboliphyme baturini	stomach	martens (3%)
Toxocara canis	small intestine	foxes (50%)
Toxocara tanuki	small intestine	raccoon dogs (50%)
[Trematoda]		
Echinostoma hortense	small intestine	martens (3%)
Echinoparyphium recurvatus	small intestine	raccoon dogs (7%)
Concinnum ten	pancreatic duct	martens (61%)
Euryhelmis constaricensis	small intestine	martens (29%)
* *Metagonimus miyatai*	small intestine	raccoon dogs (7%)
Metagonimus takahashii	small intestine	raccoon dogs (7%); foxes (50%)
Metagonimus yokogawai	small intestine	raccoon dogs (7%)
* *Brachylaima tokudai*	small intestine	raccoon dogs (7%)
Pseudotroglotrema sp.	small intestine	martens (3%); raccoon dogs (7%)
Alaria alata	small intestine	foxes (50%)
[Cestoda]		
Taenia pisiformis	small intestine	raccoon dogs (7%); foxes (50%)
* *Mesocestoides paucitesticulus*	small intestine	martens (18%); raccoon dogs (7%)
Spirometra erinaceieuropaei	small intestine	raccoon dogs (7%); foxes (50%)
Larvae of *S. erinaceieuropaei*	peritoneum	martens (5%)
[Acanthocephala]		
Juvenile form of *Centrorynchus elongatus*	small intestine	martens (8%)

* Newly-found species from this research area.

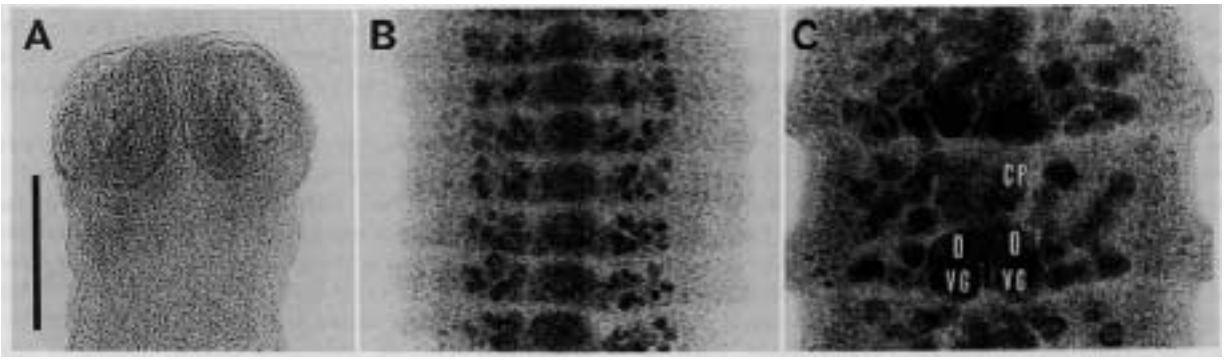

Fig. 1. *Mesocestoides paucitesticulus* Sawada *et* Kugi, 1973 found from a marten. Scolex (A), and immature (B) and mature proglottides (C). Semichon's carmine stain, scale bar=0.200 mm. Abbreviation: CP, Cirrus pouch; O, ovary; VG, vitelline gland.

Specimens of *B. tokudai*, 37 in number, were detected in the small intestine of one male raccoon dog that died from a traffic accident on Oct. 11, 1998 in Ajigasawa, Aomori Pref. All these flukes were developing adults without developed uterus and eggs, varing in worm size. Measurements of 6 most developed specimens are shown in Table 3. The body with unarmed body surface was elongated, with blunt anterior and pointed posterior ends (Fig. 3). Morphological

Table 2. Measurements of *Mesocestoides paucitesticulus* from different hosts and localities in Japan (in mm)*

Host	*Nyctereutes procyonoides*	*Vulpes vulpes japonica*	*Martes melampus*	*Nyctereutes procyonoides*
Locality	Ehime Pref.	Oita Pref.	Aomori Pref.	Aomori Pref.
Reference	Sawada & Kugi, 1973 [13]	Kugi, 1977 [4]	The present work	The present work
Worm length	150–270	50–450	> 34.8 (Not gravid)	0.97–2.47 (Destrobilated)
Worm width	0.71–1.5	0.9–1.1	> 0.50–0.71	
No. of segments	470–500	Max. 763	> 243	
Scolex	0.401–0.415×0.360	0.455×0.350	0.383–0.388×0.245–0.265	0.296–0.367×0.224–0.265
Sucker	0.166×0.138	0.126×0.098	0.189–0.191×0.135–0.143	0.179–0.189×0.138–0.179
Neck (length × width)	12.5–13.8×0.124–0.138	6.2×0.182	>3.50–5.56×0.31–0.45	
Fully mature seg.	196th–248th	265th	≥ 222–230th	
(width x length)	0.45–0.48×0.35–0.37	0.44×0.25	0.49–0.63×0.27–0.39	
No. of testes	32–38	34–38	26–37	
Testis	0.056–0.063×0.042–0.045	0.021–0.042	0.056–0.074×0.036–0.046	
Cirrus pouch	0.105–0.133×0.063–0.070	0.112×0.035–0.042	0.112×0.061–0.077	
Ovary	With two subspherical lobes	With two subspherical lobes	With two subspherical lobes	
	0.111–0.124×0.069	0.070×0.035	0.122–0.194×0.056–0.071	
Vitelline gland	0.069×0.035**	0.028×0.021	0.061–0.071×0.041–0.051	
Egg	0.050×0.035	0.028–0.032×0.025		
Embryonic hooklet	0.013	0.014		

* Our fragmented specimens from a marten was sexally mature, but not gravid, and at least two scolex and three strobilae were examined. Our specimens from a raccoon dog was destrobilated adults, and seven scolecies were measured. Blanks mean no data.

** This value might be a typographic error, since Kugi and Sawada [6] firstly reported it as 0.069 × 0.055, and the latter value might be correct.

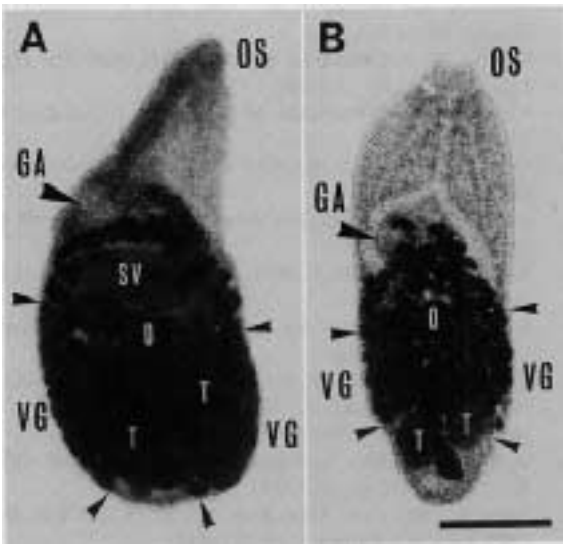

Fig. 2. *Metagonimus miyatai* Saito *et al.*, 1997 found from a raccoon dog. Anterior portion of fluke (A) is distorted at fixation, and fluke (B) has incompletely developed genital organs, particularly seminal vesicle and vitelline gland. Semichon's carmine stain, scale bar=0.200mm. Abbreviation: GA, genitoacetabulum; O, ovary; OS, oral sucker; SV, seminal vesicle; T, testis; VG, vitelline gland (Terminals of VG are shown by small arrowheads). Note VG distribution unique to *M. miyatai*; VG ends in front of the posterior end of the left testis.

features and measurements of our specimens from a raccoon dog well coincided with its original description. *B. tokudai* has been recorded only from *Urotrichus talpoides* distributed in the central part (Nagano Pref.) of Honshu [16]. Asato and Hasegawa [1] found *Brachylaima* sp. closely resembling *B. ishigakiense* Kamiya *et* Machida, 1977 [2] from dogs living in Okinawa Pref. Our report of *B. tokudai* from the raccoon dog is a new host record, and the first record of *Brachylaima* species from wild carnivores in Japan.

Pterothominx sp. collected from the stomach of 2 raccoon dogs caught in Nishimeya, Aomori Pref. is identical to "*Capillaria* sp." described by Uchida *et al.* [14] from raccoon dogs caught in Kanagawa Pref., and we reclassified it according to the system by Moravec [9]. Since morphological features and measurements of this species have been described and illustrated in detail by Uchida *et al.* [14], no further decription is made here except for an indication that their description has typographical errors in body width of parasites; it may be correct that body width of the male was 0.036–0.040 mm instead of 0.36–0.40 mm, and the female 0.048–0.064 mm instead of 0.48–0.64 mm.

In the last two years [12, the present study], we collected 12 nematode, 12 trematode, 4 cestode, and a single acanthocephalan species from wild carnivores living in north-western Tohoku, Japan. Still, this is an incomplete list of helminth species parasitic to them, and further efforts are needed particularly on helminth parasites from foxes, since we have examined only a limited number of this animal species.

We would like to express our sincere gratitude to Mr. Masayuki Sasamura for providing animal samples. This study was supported in part by a grant-in-aid for "The Control of Emerging and Reemerging Disease in Japan" from the Ministry of Health and Welfare, Japan.

Table 3. Comparison of *Brachylaima tokudai* collected in this study with its original description (in mm)*

Host	Urotrichus talpoides	Nyctereutes procyonoides
Locality	Kiso, Nagano Pref.	Ajigasawa, Aomori Pref.
Reference	Yamaguti, 1954 [16]	The present work
Worm length	1.3–3.5	1.02–1.23
Worm width	0.30–0.45	0.26–0.39
Oral sucker; Length	0.25–0.30	0.189–0.219
Width	0.23–0.29	0.168–0.199
Pharynx	0.080–0.110	0.079–0.112
	× 0.090–0.126	× 0.094–0.117
Acetabulum; Length	0.17–0.26	0.128–0.158
Width	0.17–0.24	0.122–0.153
Testes	0.12–0.31	0.138–0.179
	× 0.10–0.22	(in diameter)
Ovary	0.10–0.21	0.087–0.117
	× 0.12–0.18	× 0.074–0.087
Eggs	0.027–0.033	
	× 0.012–0.015	

* Range of measurements by Yamaguti [16] is based on unknown numbers of adult flukes, that by us based on 6 depeloping adults. Blanks mean no data.

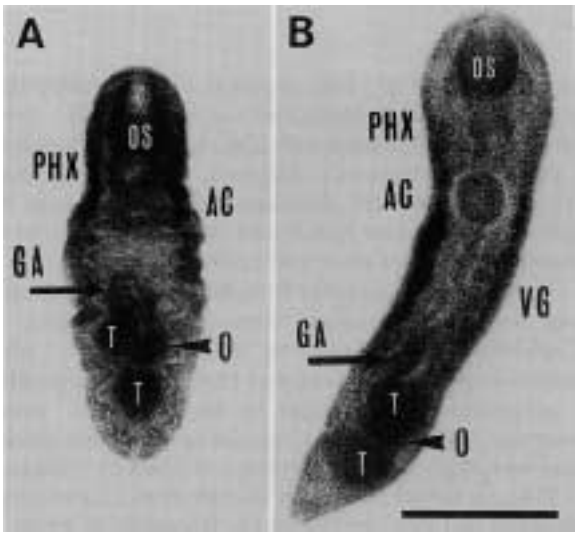

Fig. 3. *Brachylaima tokudai* Yamaguti, 1954 found from a raccoon dog. These two (A & B) are incompletely developed adults. Semichon's carmine stain, scale bar=0.400 mm. Abbreviation: AC, acetabulum; GA, genital atrium; O, ovary; OS, oral sucker: PHX, pharynx; T, testis; VG, vitelline gland.

REFERENCES

1. Asato, R. and Hasegawa, H. 1982. *Jpn. J. Parasitol.* 31 (*Suppl.*): 60 (in Japanese).
2. Kamiya, H. and Machida, M. 1977. *Bull. Natl. Sci. Mus., Tokyo, A (Zool.)* 3: 125–129.
3. Kamiya, H. and Ohbayashi, M. 1975. *Jpn. J. Vet. Res.* 23: 60–68.
4. Kugi, G. 1977. *Jpn. J. Parasitol.* 26: 25–27 (in Japanese with English summary).
5. Kugi, G. 1983. *J. Jpn. Vet. Med. Assoc.* 36: 464–468 (in Japanese).
6. Kugi, G. and Sawada, I. 1973. *Jpn. J. Parasitol.* 22: 31 (in Japanese).
7. Kumada, N. 1989. [*Sai-shin-Igaku*] 44: 895–898 (in Japanese with English summary).
8. Kumada, N., Mizuno, S., Kato, Y., Mizuno, T. and Oya, H. 1972. *Jpn. J. Parasitol.* 21: 336–345.
9. Moravec, F. 1982. *Folia Parasitol. (Praha)* 29: 119–132.
10. Oyamada, T., Kudo, N., Kitahara, T. and Takatou, Y. 1996. *Jpn. J. Parasitol.* 45: 275–279.
11. Saito, S., Chai, J.-Y., Kim, K-H., Lee, S.-H. and Rim, H-J. 1997. *Korean J. Parasitol.* 35: 223–232.
12. Sato, H., Inaba, T., Ihama, Y. and Kamiya, H. 1999. *J. Vet. Med. Sci.* 61: 1023–1026.
13. Sawada, I. and Kugi, G. 1973. *Jpn. J. Parasitol.* 22: 45–47.
14. Uchida, A., Uchida, K., Murata, Y. and Udagawa, T. 1984. *Bull. Asabu Univ. Vet. Med.* 5: 133–144 (in Japanese with English summary).
15. Yagisawa, M. 1978. *Hirosaki Med. J.* 30: 239–284 (in Japanese with English summary).
16. Yamaguti, S. 1954. *Acta Med. Okayama* 8: 391–405.