

Disentangling the Alien and Anarchic Hand

Clelia Marchetti

“S. Maugeri” Foundation, Rehabilitation Institute of Veruno, Italy

Sergio Della Sala

University of Aberdeen, UK

“Anarchic hand” is the term by which we propose to identify complex goal-directed movements of a hand, which are performed against the patient’s will, and that cannot be voluntarily inhibited. This phenomenon should be differentiated from the feeling of nonbelonging of a hand, known in the literature since the report of Brion and Jedinak (1972), to which the term “alien hand” should be retained. Anarchic hand, which is linked with anterior lesions of the corpus callosum and the supplementary motor area contralateral to the wayward hand, should be conceived as a “frontal” sign. Alien hand, which has been reported after posterior lesions of the corpus callosum, probably encroaching upon the parietal cortex, should be thought of as a partial hemisomatognosia, that is, a unilateral “loss of the knowledge or sense of one’s own body and bodily condition” (Beaumont, Kenealy, & Rogers, 1996, p. 108). This distinction will ease the description and the interpretation of new cases of alien and anarchic hand and will avoid some of the confusion currently present in the field.

SOME ORDER IN THE ANARCHY

Alien hand is one of the most intriguing phenomena in neurology. Its interpretation is still debated, and some of the disagreement is due to blurred definitions of the symptom. Clinical pictures quite different from one another, caused by lesions to different regions of the brain and due to different aetiologies, are subsumed under the label of “alien hand”.

The term, which underlines the “alien” characteristics of the symptom, dates back to Brion and Jedynek (1972), who defined “*main étrangère*” (foreign

Correspondence and request for reprints should be sent to Professor Sergio Della Sala, Department of Psychology, University of Aberdeen, AB24 2UB Aberdeen, Scotland; e-mail: sergio@aberdeen.ac.uk.

We thank George Watson who introduced us to Le Fanu’s novels. This paper draws extensively from previous collaborative work with Hans Spinnler.

hand, or strange hand, as the authors themselves translated the sign in the English abstract of their paper) as the failure to recognise the ownership of one's left limb, when this is held by the right out of visual control. They reported the sign of the *main étrangère* in four patients: three affected by a tumour in the posterior part of the corpus callosum (CC) and the fourth presenting a left posterior paracallosal angioma¹ (see Fig. 1).

The patients reported by Brion and Jedynak (1972, p. 262, 1974) did not present with any involuntary movement: they felt their left hand as a foreign body which they failed to recognise. Their description of the symptom is compelling:

Le patient qui se tient ses mains l'une dans l'autre derrière le dos, ne reconnaît pas l'appartenance de la main gauche ... le déficit ne porte pas sur la reconnaissance tactile de la main, mais sur *la reconnaissance de son appartenance*.

(Translation: The patient who holds his hands one within the other behind his back does not recognise the left hand as his own ... The sign does not consist in the lack of tactile recognition of the hand as such, but in *the lack of recognition of the hand as one's own*.)

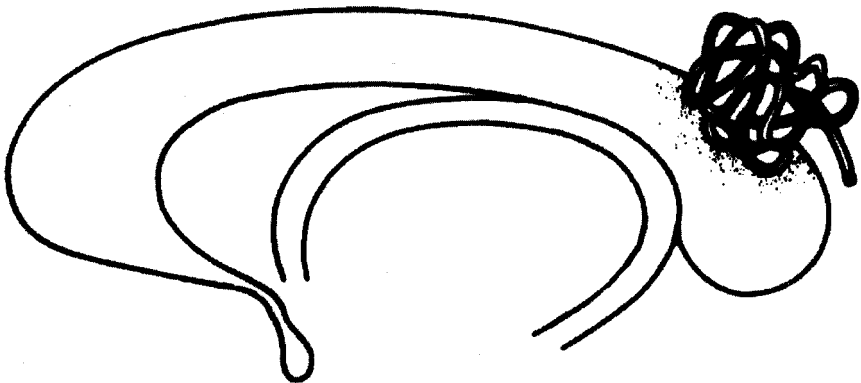


FIG. 1. Redrawing of one of the sketches reported by Brion and Jedynak (1972) in their postmortem study of four patients showing alien hand. It appears clear that the angioma encroaches upon the posterior part of the corpus callosum, invading the surrounding parietal cortex.

¹ Arterovenous malformation consisting of a tangle of dilated vessels.

Therefore, the sign of the alien hand, as the authors acknowledged, can be considered a circumscribed hemisomatognosia, possibly due to the involvement of the parietal cortex as well as to the lesion of the CC.

Clinical pictures similar to those observed by Brion and Jedynak have been reported in patients affected by different diseases. For example, Ventura, Goldman, and Hildebrand (1995) described the feeling of nonbelonging of her left arm in a patient with a right capsulothalamic haemorrhage with mesencephalic extension, and recently Kaufer, Mendez, Mischel, Verity, & Benson (1996) reported the case of a man presenting features of a diffuse demyelinating disease showing left alien arm.

In 1979, Bogen, discussing the sequelae of callosal lesions, translated Brion and Jedynak's sign as "alien hand".² However, in his definition, he added the term "active motor misbehaviour" to the experience of nonbelonging of the patients' left "alien" hand. Bogen (1985, p. 313) later described alien hand as an autonomous hand which "behaves in a way which the patient finds foreign, alien, or at least uncooperative". Goldberg, Mayer, and Toglia (1981) gave to the term "alien hand" yet another meaning. In their definition, the feeling of not belonging of the hand, and the patients' lack of recognition of their hand, assumed by Brion and Jedynak to be the key feature of alien hand, was not mentioned. On the contrary, the presence of autonomous, wayward movements that the "alien" hand performed against the patient's will was duly stressed. They reported (1981, p. 685) the case of two patients with infarction involving the anterior portion of the CC and the left medial frontal cortex, and referred to the presence of complex and co-ordinated movements "that appeared to be dissociated from conscious volition". Both patients complained that their hand had a will of its own, but never denied that the bizarre hand was their own. A similar case, patient HM, had been reported as early as 1908 by Goldstein, who named the phenomenon *Spontanbewegungen*—spontaneous movements (see Fig. 2), and interpreted it as the effect of the lesion of the gyrus fornicatus (currently cingulate gyrus) of the hemisphere contralateral to the pathological hand.

From our discussion, it is clear that the two signs have only the name in common. The abrupt modification of the definition of alien hand, the meaning of which was lost in translation, is partly responsible for the taxonomic confusion. In turn, this terminological tangle undermined the possibility of providing a sound interpretation of either of these two phenomena. We suggest limiting the term "alien hand", which well describes the feeling of the hand not being recognised as one's own, to the partial hemisomatognosia reported by Brion and Jedynak. We propose instead the term "anarchic hand" (Della Sala, Machetti, & Spinnler, 1991, 1994) for the phenomenon firstly described by Goldstein

² In a recent television interview (A. Ahujia: Discovery Channel, 1997), Bogen acknowledged that this choice was unfortunate.

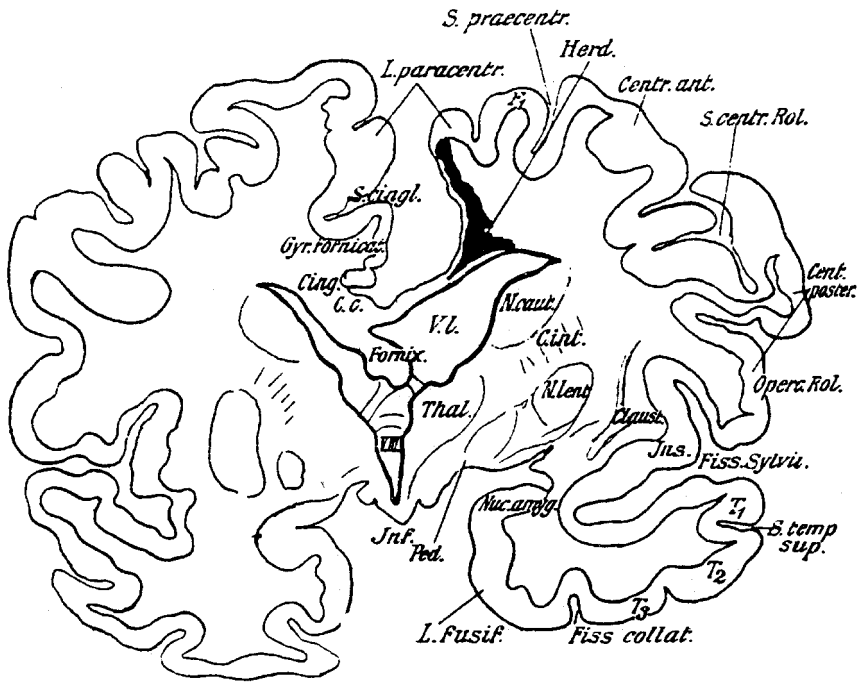


FIG. 2. Goldstein's (1909) coronal outline of the postmortem study of the brain of the patient HM, whose anarchic hand he reported a year before. The softening (*Herd*) encroaches upon the right medial frontal area and includes the anterior part of the corpus callosum. In his paper, Goldstein linked the lesion of the right cingulate gyrus (i.e. gyrus fornicatus) to the left anarchic hand sign shown by HM.

(Goldstein, 1908, 1909; see Della Sala et al., 1994 for a historical review), and recently restated by Bogen (1985) and by Goldberg et al. (1981). This term emphasises better the apparent self-government of the hand which *acts* at cross purposes to the will of the patient, who, however, perceive it as part of his/her own body.

It also occurs to us that in many instances the term "alien hand" has been used as a misnomer to identify clinical signs that have little in common with either of the two phenomena as defined in the foregoing. For instance, alien hand has been used to describe involuntary movements shown by patients suffering from corticobasal degeneration³ (Gibb, Luthert, & Marsden, 1989; Doody & Jankovic, 1992; Rinne, Lee, Thomson, & Marsden, 1994) or other

³ Slowly progressive brain disease characterised by apraxia, balance problems, myoclonus, oculomotor disorders, akinetic-rigid syndrome, visuoconstructive deficits, and a tendency of the patients' arms and hands to levitate and of their fingers to wander like tentacles (Gibb, Luthert, & Marsden, 1989).

degenerative diseases like Alzheimer's dementia (Ball et al., 1993). The pathological hand of these patients is seen to wander involuntarily and to perform purposeless movements. Often, the arm levitates spontaneously, sometimes with tentacular movements of the fingers. Furthermore, adding to the chaos of definitions and terminology, Magnani, Mazzucchi, Poletti, Scoditti, and Parma, (1987) misinterpreted as alien hand, a grasping reaction⁴ shown by a patient with a stroke in the left mediofrontal region. In fact, their patient RV never showed unwanted purposeful actions, but only pursuit movements following objects in space, ending with a final grip, which he had difficulty in releasing. Moreover, Levine and Rinn (1986) called alien hand the deficit shown by a patient affected by optic ataxia (the failure to reach or grasp an object in sight) who was unable to exert voluntary control on uncoordinated movements following an infarction in the territory of the right posterior cerebral artery. All these latter signs are different from either alien or anarchic hand, and should be kept separate in the taxonomies of involuntary movements.

The misuse of the term alien hand as a misnomer is even more evident in the popular science press and in the media. For instance Oliver Sacks in a recent publication calls "alien" a phantom limb (1995, p. 149); and in a television documentary (*The Mind Traveller*, BBC 2, 31 October 1996) he described as a typical alien hand the involuntary movements showed by a patient affected by the Parkinson-dementia-motorneuron disease complex of Guam (see Reed and Brody, 1975).

Moreover, other signs, similar to anarchic hand, but due to different lesions, are reported in the literature. Among these it is worth mentioning the intermanual conflict (Bogen, 1985; Tanaka, Yoshida, Kawahata, Hashimoto, & Obayashi, 1996) often reported in split-brain patients, and first observed by Akelaitis (1944), who labelled it "diagonistic dysparxia", and interpreted it as a psychiatric manifestation accompanied by "schizoid pattern on the Rorschach test", or alternatively as a variant of the epileptic fits brought on as a result of surgery. This phenomenon consists of co-ordinated complex actions performed by the hand ipsilateral to the dominant hemisphere which counteracts those planned by the patient and performed with the dominant hand. Diametrically opposed in its clinical expression is the phenomenon known as "mirror movements" in which one hand involuntarily mimics the other when this is performing an action (Togglieb, Robb, & Day, 1992). Mirror movements usually occur after lesions involving the frontomesial cortex *but not* the corpus callosum (e.g. Chan & Ross, 1988). To add to the taxonomic confusion, the term "mirror movement" has also been used in the literature to identify associated movements which appear in symmetric muscles on the opposite side of the

⁴ The term *grasping reaction* "covers a range of behaviours which share with the grasp reflex the tendency to take hold of the object stimulus, but are differentiated by the type of stimulation suitable to elicit them ..." (De Renzi & Barbieri, 1992, p.295).

body, whenever one side is moved voluntarily. These movements are normal in children and occur in complex genetic syndromes (e.g. see Hermsdoerfer, Danek, Winter, Marquardt, & Mai, 1995).

To interpret a phenomenon, it is first necessary to provide a definition that delineates its specificity.

DEFINITION OF ANARCHIC HAND

Anarchic hand defines the occurrence of complex movements of an upper limb which are clearly goal-directed and well executed but unintended (Della Sala et al., 1994). These unwanted movements cannot be voluntarily interrupted and might interfere with the desired actions carried out by the other (healthy) hand. The patients are aware of the bizarre and potentially hazardous behaviour of their hand but cannot inhibit it. They often refer to the feeling that one of their hands behaves as if it has a will of its own, but never deny that this capricious hand is part of their own body. The bewilderment comes from the surprising and unwanted actions, not from a sensation of lack of belonging of the hand.

Anarchic hand is a phenomenon so bizarre that it verges on the comic. One of our patients (GP) once, at dinner, much to her dismay saw her left hand taking some fish bones from leftovers and putting them into her mouth (Della Sala et al., 1994). Another patient of ours (GC) often complained that her hand did what it wanted to do, and tried to control its wayward behaviour by hitting it violently or talking to it in anger and frustration (Della Sala et al., 1991). Parkin (1996) reported that his patient, MP (Parkin & Barry, 1991, p. 175) had problems in choosing television channels, because "no sooner had the right hand selected one station the left hand would press another button".

Given its oddness, the symptom also enthralls people who are nonexpert in neuroscience. Examples of anarchic hands can be found in novels and films alike. The readers might remember the scene from *Dr. Strangelove*, the irreverent movie that Stanley Kubrick based on the novel by Peter George (1963), in which a German-American mad nuclear scientist (played by Peter Sellers) was throttled by his right hand and started to slap it to defend himself. The similarity between Sellers' performance and the phenomenology observed in some patients is overwhelming. So much so that "Dr. Strangelove syndrome" has been proposed, albeit unsuccessfully (probably because of a noncinephile reviewer) as a descriptive label for the alien hand syndrome (Boller, pers. comm. 1993). Perhaps less well known are other descriptions. Maurice Renard (1929) wrote a story about a pianist whose mutilated hands have been surgically substituted by those of a criminal, and which apparently acted on their own will; the moviegoer might remember some films taken from this story, among them, the famous *Mad Love* (1935) starring Peter Lorre, or the more recent *The Hands of Orlac*, directed by E.T. Greville (1960). Julio Cortazar (1979/1974) portrayed a girl whose hand "does not want to listen and

sometimes to her consternation does whatever it likes'' (our translation). As early as 1863, Sheridan Le Fanu wrote about a ''disembodied'' hand which tried to choke the hapless person it was persecuting, a theme taken up by Sam Raimi in his horror movie *Evil Dead 2: Dead by Dawn* (1987), who shot the scene of actor Bruce Campbell being strangled by a disembodied hand. Similarly macabre is the ''Bizarre situations'' in William Boyd's collection of short stories, *On the Yankee station* (1988). Boyd's character is a patient who underwent callosotomy and, without wanting to, shot his best friend's wife using his left (anarchic) hand. Indeed, the phenomenon is peculiar enough to be described even in the popular press devoted to the grotesque (e.g. *Bizarre*, UK July/August 1997, pp. 66–67), and discussed in television shows dedicated to the unusual (e.g. A. Ajuja, Discovery Channel).

ANATOMO-FUNCTIONAL ARCHITECTURE OF ANARCHIC HAND

Several anatomico-functional hypotheses have been put forward to account for anarchic hand. For many years a section of the corpus callosum (CC), either surgical or due to a pathological process, has been held responsible for the phenomenon (Bogen, 1985). However, a careful analysis of the literature shows that in all cases of anarchic hand with a lesion allegedly limited to the CC, signs and symptoms of cortical involvement are also duly reported (for a review see Della Sala et al., 1994). For instance, some of these patients also presented with transcortical motor aphasia (also known as supplementary motor area aphasia⁵) or transient hemiparesis (Leiguarda, Starkstein, & Berthier, 1989; Tanaka, Iwasa, & Yoshida, 1990; Watson & Heilman, 1983). Moreover, if the isolated lesion of the corpus callosum suffices to elicit the sign, the anarchic hand must always be ipsilateral to the hemisphere dominant for praxis (i.e. the left hand in right-handers). This assumption has been disputed by the observation of right-handed patients with a *right* anarchic hand (Della Sala et al., 1991; Goldberg et al., 1981; McNabb, Carroll, & Mastaglia, 1988). Recently, a patient has been reported who showed a clear right-sided dominance for praxis but nevertheless had a left (i.e. contralateral to praxis) anarchic hand (Marchetti & Della Sala, 1997). The callosal hypothesis is also contentious on other grounds: It seems unlikely that a disconnection of the primary motor cortex from the parietal areas where the motor engrams are supposedly seated could give rise to a ''positive'' sign (i.e. the appearance of nonapraxic involuntary movements) instead of a ''negative'' sign (i.e. the apraxic performance of voluntary movements), which would mimic the effect of a lesion of the same areas (however, case AW,

⁵ Impairment of language characterised by the relatively good ability to repeat spoken language, relatively well-preserved comprehension, nonfluent verbal output, and difficulty in naming but which benefits from cues. Its pathology is located in the dominant frontal lobe (Benson, 1993).

recently reported by Baynes, Tramo, Reeves, & Gazzaniga, 1997, showed clear left anarchic hand after a stroke of the CC, but her cortical lesions apparently were confined to posterior areas, sparing the frontal lobes).

An account alternative to the pure CC lesion hypothesis postulates the need of a double lesion of both the corpus callosum and the medial frontal cortex (in particular the supplementary motor area: SMA⁶) for anarchic hand to emerge (Della Sala et al., 1991; Goldberg et al., 1981). The SMA lies in the medial surface of the frontal lobe (see Fig. 3) and corresponds largely to the medial portion of Brodmann's (1909) area 6. Its role in the organisation, storage, and generation of actions recently aroused a great deal of interest (Lüders, 1996; Picard & Strick, 1996; Zilles, et al., 1995). The various dishomogeneous subregions of the SMA are interconnected strongly with one another and the pre-SMA is also heavily linked to the prefrontal cortex (Bates & Goldman-Rakic, 1993; Luppino, Matelli, & Rizzolatti, 1990), where the decisions of what to do and when to do it are probably taken (Passingham, 1996).

Unfortunately, the anatomical and neurophysiological specifications add little to our understanding of the mechanisms giving rise to anarchic hand. Furthermore, the lesions shown by patients are normally too large to allow any fine-grained anatomo-functional correlative speculation.

For the sake of our argument it suffices to remind the readers that the motor functions of the SMA are supported by neuroanatomical (Tanji, 1994), and stimulation studies (Lim et al., 1994; Penfield & Welch, 1951); by evoked potential investigations (Deecke, 1987), by analyses of regional blood flow and PET studies (Deiber et al., 1991; Larsson, Gulyas, & Roland, 1996; Roland, Larsen, Lassen & Skinhoj, 1980), as well as by functional MRI (Rao et al., 1993). All these studies converge in demonstrating that the SMAs store and organise motor subroutines (Goldberg, 1985) related to internal drives (predictive movements) (Halsband, Ito, Tanji, 1993).

The premotor medial systems centred on the SMAs are connected with a lateral motor system (centred on a region sometimes referred to as premotor cortex: PMC). This lateral system is considered to be responsible for the so-called "responsive movements" which are generated in response to external stimuli (Mushiake, Inase, & Tanji, 1991; Rizzolatti, Matelli, & Pavesi, 1983). A word of caution, it has to be remembered that the functional dissociation between internally and externally triggered movement is not absolute (Brust, 1996; Remy, Zilbovicius, Leroywilling, Syrota, & Samson, 1994). The coordination of manual activities depends upon the balance of the medial and the lateral systems. There is some agreement (Feinberg, Schindler, Flanagan & Haber, 1992; Goldberg, 1985) that anarchic hand results from the imbalance of this complex mechanism: A lesion of the SMA leaves the contralateral hand at

⁶ Neuroanatomically minded readers are referred to comprehensive textbooks on the topic, such as Lüders's (1996).

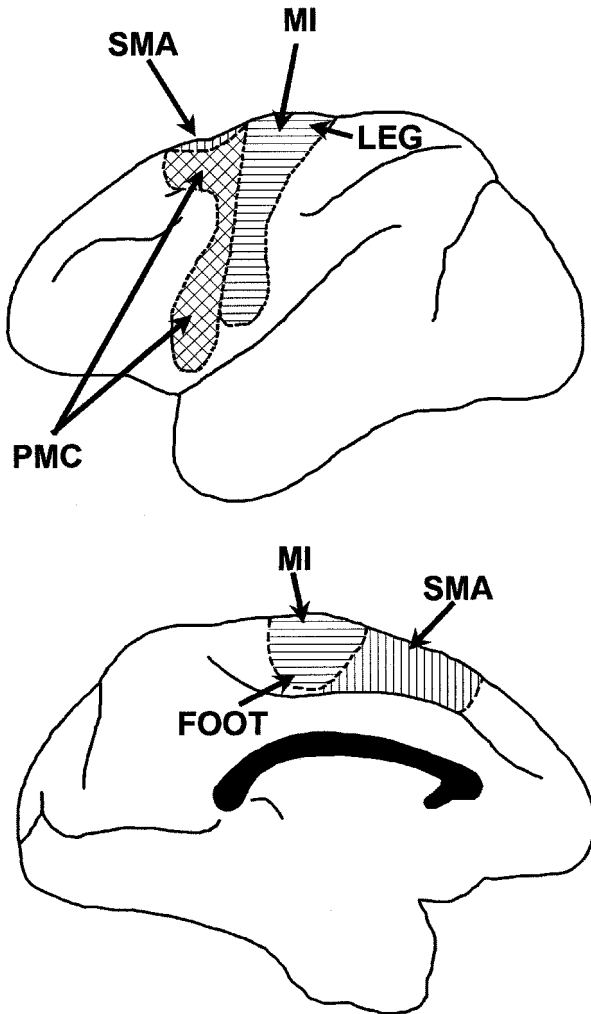


FIG. 3. The primary motor area (MI), the premotor cortex (PMC), and the supplementary motor area (SMA) in the dorsal (above) and mesial (below) surface of the left hemisphere of a monkey. (Redrawn from Brodal's, 1992, fig. 9.7.)

the mercy of external stimuli which operate through the PMC, and therefore behaves anarchically. This interpretation is supported by the findings of studies investigating the reflexive saccades in brain-lesioned patients. These investigations demonstrated that patients with lesions in the medial aspects of the frontal lobes are unable to inhibit reflexive oculomotor responses to stimuli presented in the contralateral visual hemifield (Paus et al., 1991).

Convolved *post-hoc* compromises between the frontal and the callosal hypotheses to interpret anarchic hand have been proposed (e.g. Feinberg et al., 1992; see also Chan & Ross, 1997, for further fractionation of the syndrome). According to such hypotheses, the frontal anarchic hand would always be the right and the callosal the left. The “frontal” anarchic hand sign would always be associated with grasping and compulsive manipulation of tools, whereas the “callosal” anarchic hand behaviour would be characterised by intermanual conflict. However, left anarchic hands coupled with “frontal” signs can be gleaned from the literature (Della Sala et al., 1994; Goldberg & Bloom, 1990; Goldstein, 1909; Trojano, Cresci, Lanzillo, Elefante, & Caruso, 1993). Furthermore, following this logic, a patient with a lesion encroaching upon both the CC and the left SMA should show two different kinds of anarchic hand: a left callosal and a right frontal. Patients with this specific combination of lesions do not show the predicted symptomatology (e.g. Della Sala et al., 1991). Until such a patient is reported, the principle of Occam’s razor suggests keeping these fractionation hypotheses on hold.

CONCLUSIONS

Inasmuch as it is due to the release of the lateral system from the inhibition of the medial system, anarchic hand can be conceived as a frontal “release sign”. Anarchic hand shares some characteristics with these signs: dependence on environmental triggers, impulsiveness, irrepressibility. We disagree with Tanaka et al. (1996), who claim that anarchic hand can be traced back simply to a complex form of grasping or groping,⁷ because its actions are clearly goal-directed. We maintain that it should be conceived as a fragment of the frontal motor syndrome (Della Sala et al., 1991, 1994). The term “alien hand” instead should be used solely in connection with the hemisomatognosic-like symptom of the lack of recognition of one’s own hand, linked to more posterior lesions.

Even if one accepts this taxonomy, several questions remain unanswered and many topics are still open to debate.

THOUGHTS FOR FUTURE INVESTIGATIONS

Chronic vs. Acute Anarchic Hand

A contention about anarchic hand concerns the locus of lesion deemed necessary and sufficient so that the symptom becomes chronic. Two different hypotheses have been put forward. Goldberg and Bloom (1990) suggested that recovery might be due to a compensatory mechanism from the intact hemisphere: SMA from the nondamaged hemisphere would take over the control of the proximal

⁷ Groping is a subtype of grasping reaction elicited by “a progressive retreat of the stimulus, as the hand approaches it” (De Renzi & Barbieri, 1992, p.295): the patient’s hand instinctively pursues the stimulus.

segments of the ipsilateral arm. A bilateral damage would hinder this compensatory process and anarchic hand would become chronic. Such a prediction seems to be supported by the bilateral case reported by Gasquoine (1993). However, cases of anarchic hand following unilateral lesion have been observed nine months (Trojano et al., 1993) to eight years (Della Sala et al., 1994) after the brain damage, and no compensation occurred. Della Sala et al. (1991) proposed instead that a callosal lesion might be sufficient for the anarchic hand to appear, but a simultaneous lesion to both the corpus callosum and the SMA should be present for the sign to become chronic. Papagno and Marsile (1993) uphold this hypothesis and hinted at the role exerted by the size of the callosal lesion. They maintained that in the presence of a mesiofrontal lesion, a coexisting callosal damage should involve at least the anterior two-thirds of it, in order to impede any recovery. The role of the callosal lesion for anarchic hand to chronicise is further validated by the case of a patient, LB, whom we have recently observed. LB, a left-handed man had a stroke in the right mesial frontal cortex documented by CT and SPECT scans, showed left-sided motor neglect and left anarchic hand. His lesion spared the corpus callosum. He did not show clinical signs of callosal disconnection. However, his anarchic hand sign was very overt: He was afraid of falling asleep because his hand would attempt to smother him; he resorted talking to his hand, to which he attributed its own will, scolding it, stirring it up or cherishing it, to make it to perform according to his desires. The sign was coupled with an overwhelming grasping, a clear groping, and several instances of motor perseveration. Two months later the anarchic hand recovered, but the other signs persisted. Case LB supports the notion that anarchic hand may arise from lesion confined to the mesiofrontal cortex without any callosal involvement (Leiguarda, Starkstein, & Berthier, 1993; McNabb et al., 1988; Trojano et al., 1993). Some further insight into the relationship between anarchic hand and its anatomical counterpart might derive from assessing various patients in a group study. In fact, several authors reporting the effects of lesions to the anterior communicating artery territory do not mention anarchic hand, which is not an easy sign to overlook (Bogousslavsky and Regli, 1990; Irle, 1992; Stenhouse et al., 1991). It would be interesting to investigate the difference between the lesion sites of patients who present with anarchic hand and those who do not (for a similar approach on other frontal signs see De Renzi & Barbieri, 1992 and De Renzi, Cavalleri, & Facchini, 1996), to follow up the patients longitudinally to assess the correlation between presence of the symptom and interval from onset, and to look for evidence of anarchic foot (Chan et al., 1996; Della Sala et al., 1994).

A Cognitive Account of Anarchic Hand

The hypothesis outlined in the foregoing is in line with the idea that anarchic hand might be conceived as a fragment of the frontal motor syndrome which

manifests itself as utilisation behaviour (Lhermitte, 1983) when fully blown. Utilisation behaviour defines the spontaneous occurrence of complex compulsive motor actions, performed with both hands, according to an appropriate motor program, which, however, are inappropriate within the context and triggered entirely by external stimuli (Lhermitte, 1986). It has been interpreted in cognitive terms as a deficit of the supervisory system within the frame of reference of the Norman and Shallice model of action control (Brazzelli, Colombo, Della Sala, & Spinnler, 1994; Shallice, Burgess, Shon, & Boxter, 1989). This overriding supervisory system has been mapped on to the prefrontal neuronal network (Norman & Shallice, 1986; Shallice, 1988), conceived as "the seat of high level processes that modulate lower level ones" (Shallice & Burgess, 1996, p. 1405). Utilisation behaviour has been accounted for by postulating that in the absence of a working supervisory system, perceptual inputs (environmental triggers) will activate uninhibited action schemata: The simple sight of an object will activate the schemata of the action linked with that object (Brazzelli et al., 1994; Della Sala, 1995; Shallice et al., 1989). Recently a fractionation of the supervisory system has been proposed (e.g. Shallice & Burgess, 1996). Anarchic hand may thus be interpreted in cognitive terms as an unilateral manifestation of the supervisory system derangement (Della Sala et al., 1994). If one accepts this working hypothesis, then one has to assume that the anatomical mapping of the different fractions of the supervisory system should conform with functional hemispheric differences. Indeed, within the fractionation hypothesis, pains have already been taken to consider some possible hemispheric differences in the anatomical mapping of the various subsystems (Shallice & Burgess, 1996; Shallice et al., 1994). The interpretation of anarchic hand within the frame of the model of action control, postulates that the supervisory system is split within the two frontal lobes and monitors actions through an interaction of its two halves. Of course, this speculation needs support from future detailed single case studies.

An alternative account of alien hand is the intriguing hypothesis that there may be two consciousnesses in a single individual. This notion derives from split-brain experiments (Sperry, 1982), which could be seen to overturn the idea itself of a "holistic mind" (for a critical review see Jacobson, 1995, chapter 2.11). This startling assumption led researchers to maintain that anarchic hand could be due to the right hemisphere, lacking language and memory, attempting to assert its independence using tactile and visual modes (Baynes et al., 1997). However, it is difficult to reconcile the experimental and observational evidence of anarchic hand with the hypothesis that the two hemispheres might be equipped with two independent spheres of consciousness. If this were the case, why do anarchic hand patients always consider one and the same hand, left or right, as weird? They are always well aware of their odd behaviour and consciously try to overrule the unwanted action by appeasing the wayward hand. As to the right hemisphere cognitive system independence hypothesis, it runs

into troubles in accounting for right-sides anarchic hand after left hemisphere lesions in right-handers (Della Sala et al., 1991; Goldberg et al., 1981).

In conclusion, anarchic hand can be accounted for in cognitive terms as a lack of inhibition of an unwanted action triggered by environmental stimuli and conflicting with the consciously set overall goal.

Manuscript received 2 September 1997

Revised manuscript received 9 March 1998

REFERENCES

- Akelaitis, A.J. (1944.) Studies on the corpus callosum: IV. Diagnostic dyspraxia in epileptics following partial and complete section of the corpus callosum. *American Journal of Psychiatry*, 101, 594–599.
- Ball, J., Lantos, P.L., Jackson, M., Marsden, C.D., Scadding, J.W., & Rossor, M.N. (1993). Alien hand sign in association with Alzheimer's histopathology. *Journal of Neurology, Neurosurgery and Psychiatry*, 56, 1020–1023.
- Bates, J.F. & Goldman-Rakic, P.S. (1993). Prefrontal connections of medial motor areas in the rhesus monkey. *Journal of Comparative Neurology*, 336, 211–228.
- Baynes, K., Tramo, M.J., Reeves, A.G., & Gazzaniga, M.S. (1997). Isolation of a right hemisphere cognitive system in a patient with anarchic (alien) hand sign. *Neuropsychologia*, 35, 1159–1173.
- Beaumont, J.G., Kenealy, P.M., & Rogers, M.J.C. (1996). *The Blackwell dictionary of neuropsychology*. Oxford, UK: Blackwell.
- Benson, D.F. (1993). Aphasia. In K.M. Heilman & E. Valenstein (Eds.), *Clinical neuropsychology*. (3rd ed., (pp. 17–36). New York: Oxford University Press.
- Bogen, J.E. (1979). The callosal syndrome. In K.M. Heilman & E. Valenstein (Eds.), *Clinical neuropsychology* (1st ed., pp. 308–359), Oxford, UK: Oxford University Press.
- Bogen, J.E. (1985). The callosal syndrome. In K.M. Heilman & E. Valenstein (Eds.), *Clinical neuropsychology* (2nd ed., pp. 295–338), Oxford, UK: Oxford University Press.
- Bogousslavsky, J., & Regli, F. (1990). Anterior cerebral artery territory infarction in the Lausanne stroke registry. *Archives of Neurology*, 47, 144–150.
- Boyd, W. (1988). *On the Yankee station* (pp. 25–35). London: Penguin.
- Brazzelli, M., Colombo, N., Della Sala, S., & Spinnler, H. (1994). Sparing and impaired cognitive abilities after bilateral frontal damage. *Cortex*, 30, 27–51.
- Brion S., & Jedynak C.P. (1972). Trouble du transfert interhémisphérique à propos de trois observations de tumeurs du corps calleux: le signe de la main étrangère. *Revue Neurologique*, 136, 257–266.
- Brion, s., & Jedynak, C.P. (1974). Séméiologie calleuse dans les tumeurs et les malformations vasculaires. In F. Michel & B. Schott (Eds.), *Les syndromes de disconnexion calleuse chez l'homme* (pp. 253–264). Colloque International de Lyon, France.
- Brodal, P. (1992). *The central nervous system. Structure and function*. New York: Oxford University Press.
- Brodmann, K. (1909). *Vergleichende Lokalisationslehre der Grosshirnrinde*. Leipzig: J.A. Barth.
- Brust, J.C.M. (1996). Lesions of the supplementary motor area. In H.O. Lüders (Ed.), *Supplementary sensorimotor area. Advances in neurology*, 70 (pp. 237–248). Philadelphia, PA: Lippincott-Raven.
- Chan, J.L., Chen, R.S., & Ng, K.K. (1996). Leg manifestation in alien hand syndrome. *Journal of the Formosan Medical Association*, 95, 342–346.

- Chan, J.L., & Ross, E.D. (1988). Left-handed mirror writing following right anterior cerebral artery infarction: evidence for nonmirror transformation of motor programs by right supplementary motor area. *Neurology*, *38*, 59–63.
- Chan, J.-L., & Ross, E. (1997). Alien hand syndrome: influence of neglect on the clinical presentation of frontal and callosal variants. *Cortex*, *33*, 287–299.
- Cortazar, J. (1979). *Ottadetro: Collo di gattino nero* (F. Nicolitti Rossini, Trans.), (pp. 107–123). Turin, Italy: Einaudi. (Original work published 1974, Madrid: Alianza Editorial)
- Deecke, L. (1987). Bereitschaftspotential as an indicator of movement preparation in supplementary motor area and motor cortex. In *Motor areas of cerebral cortex* (Ciba Foundation Symposium, 132) (pp. 231–250). Chichester, UK: Wiley.
- Deiber, M.-P., Passingham, R.E., Colebatch, J.G., Friston, K.J., Nixon, P.D., & Frackowiak R.S.J. (1991). Cortical areas and the selection of movement: a study with positron emission tomography. *Experimental Brain Research*, *84*, 393–402.
- De Renzi, E., & Barbieri, C. (1992). The incidence of the grasp reflex following hemispheric lesion and its relation to frontal damage. *Brain*, *115*, 293–313.
- De Renzi, E., Cavalleri, F., & Facchini, S. (1996). Imitation and utilization behaviour. *Journal of Neurology, Neurosurgery and Psychiatry*, *61*, 396–400.
- Della Sala, S. (1995). Anarchy in the central nervous system: restoring order through neuropsychology. *Aberdeen University Review*, *193*, 70–82.
- Della Sala, S., Marchetti, C., & Spinnler, H. (1991). Right-sided anarchic (alien) hand: a longitudinal study. *Neuropsychologia*, *29*, 1113–1127.
- Della Sala, S., Marchetti, C., & Spinnler, H. (1994). The anarchic hand: a fronto-mesial sign. In F. Boller & J. Grafman (Eds.), *Handbook of neuropsychology* (Vol. 9, pp. 233–255), Amsterdam: Elsevier.
- Doody R.S., & Jankovic, J. (1992). The alien hand and related signs. *Journal of Neurology, Neurosurgery and Psychiatry*, *55*, 806–810.
- Feinberg, T.E., Schindler, R.J., Flanagan, N.G., & Haber, L.D. (1992). Two alien hand syndromes. *Neurology*, *42*, 19–24.
- Gasquoin, P.G. (1993). Bilateral alien hand signs following destruction of the medial frontal cortices. *Neuropsychiatry, Neuropsychology and Behavioral Neurology*, *6*, 49–53.
- George, P. (1963). *Dr. Strangelove or: How I learned to stop worry and love the bomb*. London: Transworld.
- Gibb, W.R.G., Luthert, P.J., & Marsden C.D. (1989). Corticobasal degeneration. *Brain*, *112*, 1171–1192.
- Goldberg, G. (1985). Supplementary motor area structure and function. *Review and hypotheses*. *Behavioral and Brain Sciences*, *8*, 567–616.
- Goldberg, G., & Bloom, K.K. (1990). The alien hand sign. Localization, lateralization and recovery. *American Journal of Physical Medicine and Rehabilitation*, *69*, 228–238.
- Goldberg, G., Mayer, N.H., & Togli, J.U. (1981). Medial frontal cortex infarction and the alien hand sign. *Archives of Neurology*, *38*, 683–686.
- Goldstein, K. (1908). Zur Lehre von der motorischen Apraxie. *Journal für Psychologie und Neurologie*, *XI*, 169–187.
- Goldstein, K. (1909). Der makroskopische Hirnbefund in meinem Falle von linksseitiger motorischer Apraxie. *Neurologisches Zentralblatt*, *28*, 898–906.
- Gottlieb, D., Robb, K., & Day, B. (1992). Minor movements in the alien hand syndrome. *American Journal of Physical Medicine and Rehabilitation*, *71*, 297–300.
- Halsband, U., Ito, N., Tanji, J., & Freund, H.-J. (1993). The role of premotor cortex and the supplementary motor area in the temporal control of movement in man. *Brain*, *116*, 243–266.
- Hermesdoerfer, J., Danek, A., Winter, T., Marquardt, C., & Mai, N. (1995). Persistent mirror movements: force and timing of “mirroring” are task-dependent. *Experimental Brain Research*, *104*, 126–134.

- Irle, E., Wowra, B., Kunert, H.J., Hampl, J., & Kunze, S. (1992). Memory disturbances following anterior communicating artery rupture. *Annals of Neurology*, *31*, 473–480.
- Jacobson, M. (1995). *Foundations of neuroscience*. New York: Plenum.
- Kaufer, D., Mendez, M.F., Mischel, P.S., Verity, M.A., & Benson, D.F. (1996). Alien hand syndrome in adult-onset orthochromatic leukodystrophy. Disconnection of a limb from supplementary motor areas. *Behavioural Neurology*, *9*, 5–10.
- Larsson, J., Gulyas, B., & Roland, P.E. (1996). Cortical representation of self-paced finger movement. *Neuroreport*, *7*, 463–468.
- Le Fanu, S. (1992). *The house in the churchyard*. Chapter 12: Some odd facts about the tiled house—being an authentic narrative of the ghost of a hand. Belfast: Appletree Press. (Original work published 1863).
- Leiguarda, R., Starkstein, S., & Berthier, M. (1989). Anterior callosal haemorrhage. A partial interhemispheric disconnection syndrome. *Brain*, *112*, 1019–1037.
- Leiguarda, R., Starkstein, S., Nogues, M., Berthier, M., & Arbelaitz, R. (1993). Paroxysmal alien hand syndrome. *Journal of Neurology, Neurosurgery and Psychiatry*, *56*, 788–792.
- Levine, D., & Rinn, W.E. (1986). Opticosensory ataxia and alien hand syndrome after posterior cerebral artery territory infarction. *Neurology*, *36*, 1094–1097.
- Lhermitte, F. (1983). 'Utilisation behaviour' and its relation to lesions of the frontal lobes. *Brain*, *106*, 237–255.
- Lhermitte, F. (1986). Human autonomy and the frontal lobes: II. Patient behavior in complex and social situations: the 'environmental dependency syndrome'. *Annals of Neurology*, *19*, 335–343.
- Lim, S.H., Dinner, D.S., Pillay, P.K., Lüders, H., Morris, H.H., Klem, G., Wyllie, E., & Award, I.A. (1994). Functional anatomy of the human supplementary sensorimotor area: results of extraoperative electrical stimulation. *Electroencephalography and Clinical Neurophysiology*, *91*, 179–193.
- Lüders, H.O., (Ed.) (1996). *Supplementary sensorimotor area. Advances in neurology*, *70*. Philadelphia, PA: Lippincott-Raven.
- Luppino, G., Matelli, M., & Rizzolatti, G. (1990). Cortico-cortical connections of two electrophysiologically identified arm representations in the mesial agranular frontal cortex. *Experimental Brain Research*, *82*, 214–218.
- Magnani, G., Mazzucchi, A., Poletti, A., Scoditti, U., & Parma, M. (1987). Involuntary grasping and groping responses to space-related visual stimuli. *Movement Disorders*, *2*, 9–23.
- Marchetti, C., & Della Sala, S. (1997). On crossed apraxia. Description of a right-handed apraxic patient with right supplementary motor area damage. *Cortex*, *33*, 341–354.
- McNabb, A.W., Carroll, W.M., & Mastaglia, F.L. (1988). "Alien hand" and loss of bimanual coordination after dominant anterior cerebral artery territory infarction. *Journal of Neurology, Neurosurgery and Psychiatry*, *51*, 218–222.
- Mushiake, H., Inase, M., & Tanji, J. (1991). Neuronal-activity in the primate premotor, supplementary, and precentral motor cortex during visually guided and internally determined sequential movements. *Journal of Neurophysiology*, *66*, 705–718.
- Norman, D.A., & Shallice, T. (1986). Attention to action: willed and automatic control of behaviour. In G.E. Schwartz & D. Shapiro (Eds.), *Consciousness and self-regulation*. New York: Plenum.
- Papagno, C., & Marsile, C. (1995). Transient left-sided alien hand with callosal and unilateral fronto-mesial damage: a case study. *Neuropsychologia*, *33*, 1703–1709.
- Parkin A., & Barry, C. (1991). Alien hand and other cognitive deficits following ruptured aneurysm of the anterior communicating artery. *Behavioral Neurology*, *4*, 167–179.
- Parkin, A.J. (1996). The alien hand. In P.W. Halligan & J.C. Marshall (Eds.), *Method in madness: Case studies in cognitive neuropsychiatry* (pp. 173–183), Hove, UK: Psychology Press.
- Passingham, R.E. (1996). Functional specialization of the supplementary motor area in monkeys

- and humans. In H.O. Lüders (Ed.), *Supplementary sensorimotor area. Advances in neurology*, 70 (pp. 105–116). Philadelphia, PA: Lippincott-Raven.
- Paus, T., Kalina, M., Patočková, L., Angerová, Y., Cerny, R., Mecir, P., Bauer, J., & Krabec, P. (1991). Medial vs lateral frontal lobe lesions and differential impairment of central-gaze fixation maintenance in man. *Brain*, 114, 2051–2067.
- Penfield, W., & Welch, K. (1951). The supplementary motor area of the cerebral cortex: A clinical and experimental study. *American Medical Association: Archives of Neurology and Psychiatry*, 66, 289–317.
- Picard, N., & Strick, P.L. (1996). Motor areas of the medial wall—a review of their location and functional activation. *Cerebral Cortex*, 6, 342–353.
- Rao, S.M., Binder, J.R., Bandettini, P.A., Hammeke, T.A., Yetkin, F.Z., Jesmanowicz, A., Lisk, L.M., Morris, G.L., Mueller, W.M., Estkowski, L.D., Wong, E.C., Haughton, V.M., & Hyde, J.S. (1993). Functional magnetic resonance imaging of complex human movements. *Neurology*, 43, 2311–2318.
- Reed D.M., & Brody, J.A. (1975). Amyotrophic lateral sclerosis and parkinsonism–dementia on Guam, 1945–1972: I. Descriptive epidemiology. *American Journal of Epidemiology*, 101, 287–301.
- Remy, P., Zilbovicius, M., Leroywilling, A., Syrota, A., & Samson, Y. (1994). Movement-related and task-related activations of motor cortical areas. A positron emission tomographic study. *Annals of Neurology*, 36, 19–26.
- Renard, M. (1929). *The hands of Orlac*, (F. Crewe-Jones Trans.). New York: E.P. Cutton.
- Rinne, J.O., Lee, M.S., Thomson, P.D., & Marsden, C.D. (1994). Corticobasal degeneration: A clinical study of 36 cases. *Brain*, 117, 1183–1196.
- Rizzolatti, G., Matelli, M., & Pavesi, G. (1983). Deficits in attention and movement following the removal of postarcuate (area 6) and prearcuate (area 8) cortex in macaque monkeys. *Brain*, 106, 655–673.
- Roland, P.E., Larsen, B., Lassen, N.A., & Skinhoj, E. (1980). Supplementary motor area and other cortical areas in organization of voluntary movements in man. *Journal of Neurophysiology*, 43, 119–136.
- Sacks, O. (1995). Scotoma: Forgetting and neglect in science. In R.B. Silvers (Ed.), *Hidden histories of science* (pp. 141–187). London: Granta.
- Shallice, T. (1988). *From neuropsychology to mental structure*. Cambridge, UK: Cambridge University Press.
- Shallice, T., & Burgess, P.W. (1996). The domain of supervisory processes and temporal organization of behaviour. *Philosophical Transactions: Biological Sciences*, 351, 1405–1412.
- Shallice, T., Burgess, P.W., Shon, F., & Boxter, D.M. (1989). The origins of utilization behaviour. *Brain*, 112, 1587–1598.
- Shallice, T., Fletcher, P., Frith, C.D., Grasby, P., Frackowiak, R.S.J., & Dolan, R.J. (1994). Brain regions associated with the acquisition and retrieval of verbal episodic memory. *Nature*, 386, 633–635.
- Sperry, R.W. (1982). Forebrain commissurotomy and conscious awareness. In J. Orbach (Ed.), *Neuropsychology after Lashley* (pp. 497–522), Hillsdale, NJ: Erlbaum.
- Tanaka, Y., Iwasa, H., & Yoshida, M. (1990). Diagnostic dyspraxia: case report and movement-related potentials. *Neurology*, 40, 657–661.
- Tanaka, Y., Yoshida, A., Kawahata, N., Hashimoto, R., & Obayashi, T. (1996). Diagnostic dyspraxia. Clinical characteristics, responsible lesion and possible underlying mechanism. *Brain*, 119, 859–873.
- Tanji, J. (1994). The supplementary motor area in the cerebral cortex. *Neuroscience Research*, 19, 251–268.
- Trojano, L., Cresci, C., Lanzillo, B., Elefante, R., & Caruso, G. (1993). How many alien hand syndromes? Follow-up study of a case. *Neurology*, 43, 2710–2712.

- Ventura, M.G., Goldman, S., & Hildebrand, J. (1995). Alien hand syndrome without a corpus callosum lesion *Journal of Neurology, Neurosurgery and Psychiatry*, *58*, 735–737.
- Watson, R.T., & Heilman, K.M. (1983). Callosal apraxia. *Brain*, *106*, 391–403.
- Zilles, K., Schlaug, G., Geyer, S., Luppino, G., Matelli, M., Qu, M., Schleicher, A., & Schormann, T. (1995). Mapping of human and macaque sensorimotor areas by integrating architectonic, transmitter receptor, MRI and PET data. *Journal of Anatomy*, *187*, 515–537.