

# Pheochromocytoma: an update on genetics and management

Asterios Karagiannis, Dimitri P Mikhailidis<sup>1</sup>, Vasilios G Athyros and Faidon Harsoulis

Division of Endocrinology, Second Propedeutic Department of Internal Medicine, Medical School, Hippokraton Hospital, Aristotle University of Thessaloniki, Thessaloniki 54642, Greece

<sup>1</sup>Department of Clinical Biochemistry, Royal Free University College Medical School, Royal Free Hospital, University College London (University of London), Pond Street, London NW3 2QG, UK

(Correspondence should be addressed to D P Mikhailidis; Email: mikhailidis@aol.com)

## Abstract

Pheochromocytomas (PHEOs) are rare neoplasms that produce catecholamines and usually arise from the adrenal medulla and are considered to be an adrenal paraganglioma (PGL). Closely related tumors of extraadrenal sympathetic and parasympathetic paraganglia are classified as extraadrenal PGLs. Most PHEOs are sporadic, but a significant percentage (~25%) may be found in patients with germline mutations of genes predisposing to the development of von Hippel–Lindau disease, neurofibromatosis 1, multiple endocrine neoplasia type 1 (MEN1) and 2 (MEN2), and the PGL/PHEOs syndrome, based on the described mutations of the genes for succinate dehydrogenase subunit D (SDHD), B (SDHB), and C (SDHC). As one out of four PHEOs turns out to be a hereditary clinical entity, screening for genetic alterations is important, as it provides useful information for a rational diagnostic approach and management. This review discusses the genetics, the pathophysiology of hypertension, the clinical picture, the biochemical and imaging diagnosis, and the preferred therapeutic approach for PGLs/PHEOs. Furthermore, it emphasizes the need for genetic testing in cases with apparently sporadic PHEOs.

*Endocrine-Related Cancer* (2007) 14 935–956

## Introduction

The adrenal medulla and ganglia of the sympathetic nervous system (SNS) are derived from the embryonic neural crest. The endocrine cells of this sympathoadrenal system synthesize and secrete catecholamines and exhibit a characteristic histochemical (chromaffin) reaction when treated with oxidizing agents. Pheochromocytomas (PHEOs), according to the [World Health Organization \(2004\)](#) classification, are rare tumors arising from catecholamine-producing cells in the adrenal medulla – an intraadrenal paraganglioma (PGL). Adrenal and extraadrenal PGLs produce significant amounts of catecholamines and give rise to the well-known clinical picture of PHEOs. In contrast, the parasympathetic PGLs (mainly in head and neck) rarely produce significant amounts of catecholamines.

During the last few years, a considerable amount of new data, concerning the genetics of PHEO/PGL, have accumulated and changed the whole approach to such

patients. It has been shown that in about 25% of cases, PHEO/PGLs develop secondary to germline mutations in any of five susceptibility genes ([Dluhy 2002](#), [Neumann \*et al.\* 2002](#), [Amar \*et al.\* 2005a](#), [Gimenez-Roqueplo \*et al.\* 2006](#), [Pacak \*et al.\* 2007](#)).

A classic PHEO, a solitary tumor of the adrenal medulla, reminds us of a ‘tip of an iceberg’ because this expression suggests that beyond a single tumor there is potentially a broader clinical picture awaiting exploration. This review summarizes the important relevant data related to this fascinating clinical entity.

## Prevalence

The prevalence of PHEOs is not precisely known. Among the general population in Olmsted County, Minnesota, USA, a PHEO occurs in about 1 or 2 per 100 000 adults per year ([Beard \*et al.\* 1983](#)). This figure suggests that if 20% of the adult population is hypertensive, approximately five PHEOs would be expected among 100 000 hypertensives each year. In a large series of patients

screened biochemically for suspicion of PHEO, the incidence has been reported to be as high as 1.9%, occurring equally in men and women (Smythe *et al.* 1992). On the other hand, a large number of patients with PHEO have nonclassic symptoms such as abdominal pain, vomiting, dyspnea, heart failure, hypotension, or sudden death, suggesting that the majority of PHEOs are not diagnosed during life (Sibal *et al.* 2006).

## Etiology–genetics

Most PHEOs are sporadic and arise from chromaffin cells of the adrenal medulla, but in about 9–23% of cases tumors develop from extraadrenal chromaffin tissue and are then referred as PGLs (Bravo & Tagle 2003, Sibal *et al.* 2006). In children, multifocal and extraadrenal PHEOs are found in 30–43% of cases (Khafagi *et al.* 1991, Levine & DiGeorge 2000). Malignant PHEOs account for up to 26–35% of cases (Whalen *et al.* 1992, Mundschenk & Lehnert 1998) and the prevalence of malignancy in sporadic adrenal PHEOs is 9% (Bravo & Tagle 2003). About 10% of patients with PHEOs present with metastatic disease at the time of their initial work-up (Goldstein *et al.* 1999). Approximately up to 25% of patients with apparent sporadic PHEOs, without family history of the disease, may in fact be carriers of germline mutations predisposing to the development of neurofibromatosis 1 (NF1), von Hippel–Lindau (VHL), multiple endocrine neoplasia type 1 (MEN1) and 2 (MEN2), and the PHEO/PGL syndromes based on the described mutations of the genes for succinate dehydrogenase subunit D (SDHD), B (SDHB), and C (SDHC) (Baysal *et al.* 2000, Neumann *et al.* 2002, Amar *et al.* 2005a).

## Neurofibromatosis type 1 (NF1)

PHEO constitutes a minor but established feature of NF1. This is an autosomal-dominant disorder, with a PHEO frequency estimated at 0.1–5.7% but rising to 20–50% in hypertensive patients with NF1 (Riccardi 1981, Zoller *et al.* 1997, Bausch *et al.* 2007). The clinical diagnosis of NF1 requires two of the following seven criteria (Gutmann *et al.* 1997): six or more café-au-lait spots; two or more cutaneous neurofibromas or a plexiform neurofibroma, inguinal, or axillary freckles; two or more benign iris hamartomas (Lish nodules); at least one optic-nerve glioma; dysplasia of sphenoid bone or pseudoarthrosis; and a first degree relative with NF1, according to the preceding criteria.

NF1 is caused by inactivating mutations of neurofibromin, a tumor suppressor gene, which encodes a GTPase-activating protein involved in

the inhibition of Ras activity, which controls cellular growth and differentiation. The susceptibility gene, the NF1 gene, is localized to chromosome subband 17q11.2 (Gutmann *et al.* 1994). In most cases, PHEOs are benign (90%) and single (84%), followed by bilateral (10%) and sympathetic PGLs (6%; Walther *et al.* 1999a, Bausch *et al.* 2006). Most of them occur in adults and produce predominantly norepinephrine (NE) and therefore present with hypertension and noradrenergic symptomatology.

## VHL disease

VHL is an autosomal-dominant disease with an incidence of 1 in 3600 births (Maher *et al.* 1991). PHEO develops in ~20% of patients with VHL, with a mean age at onset in the second decade of life, although such tumors often occur even later. VHL is caused by mutations of the VHL gene localized to chromosome 3p25–26. A germline mutation in the VHL gene predisposes carriers to tumors in multiple organs (Lonser *et al.* 2003). The gene is a tumor suppressor that encodes a protein (pVHL) which is involved in blood vessel formation by regulating the activity of hypoxia inducible factor (HIF)-1 $\alpha$  (Iliopoulos *et al.* 1996). This protein inhibits the accumulation of hypoxia-induced proteins through ubiquitin-mediated degradation of HIF-1 $\alpha$ , under conditions of normoxemia (Hes *et al.* 2003). In carriers of VHL gene mutations, the regulation of genes such as the vascular endothelial growth factor and other genes involved in cellular growth seems to be lost, predisposing the VHL carriers to both benign and malignant tumors in multiple organs. Loss of pVHL function reduces HIF degradation and increases vascular endothelial growth factor that leads to angiogenesis (Kaelin 2002). These tumors may include hemangioblastoma in the retina (also referred to as retinal angioma); cerebellum and spine; renal cell carcinoma (clear cell type); PHEO; islet tumors of the pancreas; endolymphatic sac tumors; and cysts and cystadenoma in the kidney, pancreas, epididymis, and broad ligament (Choyke *et al.* 1995). If present, metastases from renal cell carcinoma and neurological complications from cerebellar hemangioblastomas are the most common causes of death.

On the basis of its clinical expression, VHL disease has been divided into four subtypes with a central role for PHEO (Maher *et al.* 1996, Koch *et al.* 2002, Hes *et al.* 2003). Patients with VHL type 1 disease have loss of pVHL function, due to gene deletions or specific missense mutations and develop retinal or central nervous system hemangioblastomas and renal carcinoma, but they are not at risk for PHEO. Patients with type 2 disease have mainly specific missense mutations and develop hemangioblastoma and PHEO. They are

also at low (type 2A) or high (type 2B) risk for renal cell carcinoma. A small percentage of patients with VHL (type 2C) will have only PHEO without the other tumors. In this type, the missense mutation has the gain of function effect causing PHEO, but these particular missense mutations do not substantially affect pVHL-mediated HIF degradation. Thus, even the loss of the second VHL gene would not lead to development of hemangioblastoma or renal cell carcinoma in patient with a type 2C mutation. Knowledge of the VHL mutation could tailor clinical attention and surveillance to the organs at risk and potentially reduce the psychological anxiety and the cost of unnecessary investigations.

PHEO may present as the first or only manifestation of VHL (VHL type 2C; [Hes et al. 2003](#)). Consequently, VHL carriers can present as apparently sporadic PHEO. VHL catecholamine-producing tumors are most commonly PHEOs (90%), although sympathetic PGLs have been described. Approximately half of PHEOs are bilateral and most produce NE ([Eisenhofer et al. 1999, 2001b](#)). There are uncommon examples of malignant catecholamine-producing tumors in VHL, frequently sympathetic PGLs ([Pujol et al. 1995](#)).

## MEN1

MEN1 is an autosomal-dominant syndrome characterized by primary hyperparathyroidism, pancreatic islet cell neoplasms, and pituitary adenomas caused by inactivating mutations of the MEN1 locus coding for the suppressor protein menin localized to chromosome 11q13. MEN1 is very rarely associated with PHEO, all unilateral, rarely malignant, and most characterized by hypertension and predominant NE production ([Schussheim et al. 2001](#)).

## MEN2

MEN2 is an autosomal-dominant syndrome caused by activating mutations in the RET proto-oncogene located on chromosome 10q11.2, which encodes a transmembrane receptor tyrosine kinase involved in the regulation of cell proliferation and apoptosis, causing constitutive activation of the receptor. As a result of tissue-specific expression, calcitonin-producing parafollicular cells and adrenomedullary chromaffin cells initially undergo hyperplasia with a high rate of subsequent neoplastic transformation. MEN2A is characterized by medullary thyroid carcinoma (MTC), hyperparathyroidism, and PHEO. MEN2B is characterized by MTC, mucosal ganglioneuromas, and PHEOs ([Gagel et al. 1988, Brandi et al. 2001](#)). PHEO occurs in approximately half of gene carriers and is almost always located within the adrenal glands.

Bilateral PHEOs occur in approximately half of patients with MEN2 who have PHEO and are usually confined to the adrenal medulla; their development is frequently asynchronous, with separation by as much as 15 years ([Recasens et al. 2007](#)). PHEOs occur most commonly with codon 634 (MEN2A) or 918 (MEN2B) RET proto-oncogene mutations ([Eng et al. 1996](#)). Malignant PHEOs are uncommon, <5%, and are generally found in patients with large tumors ([Chevinsky et al. 1990](#)). The pattern of catecholamine production in MEN2 PHEO differs from that seen in other hereditary forms of PHEO. Epinephrine (E) is produced in disproportionately large amounts, resulting in an early clinical phenotype characterized by attacks of palpitations, nervousness, anxiety, and headaches rather than the more common patterns of hypertension seen with sporadic or other hereditary tumors ([Hamilton et al. 1978, Gagel et al. 1988, Eisenhofer et al. 1999, Yip et al. 2003, Young & Abboud 2006](#)).

## Paragangliomas (PGLs)

PGLs are rare tumors that arise from chromaffin cells. They represent 10–18% of all chromaffin tissue-related tumors that are reported at a rate of 2–8 cases/million a year. According to their origin, they are classified as sympathetic or parasympathetic ([Lack 1997](#)).

### Sympathetic PGLs

They are derived from the sympathetic chain and usually are located in the chest, abdomen, or pelvis. The clinical picture is a consequence of either the secretion of catecholamines or the size of the tumors with consequent impingement on other structures. The morphology of adrenal PHEOs and extraadrenal PGLs is usually very similar. The frequency of malignancy is much higher in sympathetic tumors with extraadrenal location.

### Parasympathetic PGLs

They are tumors of the parasympathetic ganglia usually found in the head and neck region, arising from the cell nests located adjacent to blood vessels, such as the carotid body or the ganglion jugulare. Unlike PGLs in the abdomen, they are usually biochemically silent, and malignancy is seen in <10% of the cases ([Lack 1997](#)).

In a large series of 236 patients with 297 benign PGLs evaluated at the Mayo Clinic during 1978–1998, the mean age at diagnosis was  $47 \pm 16$  years ([Erickson et al. 2001](#)). Of the 297 PGLs, 205 were in the head and neck region and 92 were below the neck. They were discovered and diagnosed incidentally on imaging in 9% of patients. The most frequent PGLs in the neck were carotid body tumors, and those most common below the

neck were abdominal periaortic–pericaval tumors. The most frequent symptoms for the patients with head and neck tumors were palpable neck mass (55%) and cranial nerve palsies (16%). The clinical presentations of these tumors were dominated by local mass effects (neck mass, tinnitus, and cranial nerve dysfunction) and only a small proportion (4%) was hyperfunctional. In patients with PGLs below the neck, one or more of the classic catecholamine excess pentad of headaches (26%), palpitations (21%), perspiration (25%), pallor (12%), and orthostasis (6%) were observed; hypertension was present in 64%. Their location were periaortic and pericaval, perirenal, mediastinal, intracardiac, pulmonary parenchymal, intraspinal, sacral, duodenal, jejunal, pancreatic, or in the organ of Zuckerkandl, bladder, or prostate (Neumann et al. 2004, Benn et al. 2006). Retroperitoneal PGLs are most likely to be malignant and present with pain or a mass. They tend to metastasize to the lungs, lymph nodes, and bones or they can extend locally and may destroy adjacent vertebrae and can cause spinal compression (O’Riordain et al. 1996, Edström Elder et al. 2003). Disease-causing mutations in three genes (SDHB, SDHD, and SDHC) encoding-subunits of succinate dehydrogenase of mitochondrial complex II are responsible for most cases of familial PGLs. SDH has an important function in the Krebs cycle and the mitochondrial respiratory chain.

### PGL–SDHD

PGL–SDHD is an autosomal-dominant syndrome characterized by familial and isolated head and neck parasympathetic PGLs and less frequently by sympathetic PGLs and PHEOs, caused by mutations in SDHD gene located on chromosome 11q21–23 (Baysal et al. 1997, Baysal et al. 2002, Benn et al. 2006). Head and neck PGLs are generally regarded as benign tumors but can extend into the skull. In addition, SDHD mutation carriers should be observed for multifocal tumors, infrequent malignancy, and the possibility of extra-adrenal PHEOs (Benn et al. 2006). The hereditary nature of the disease may be masked by maternal imprinting of SDHD, resulting in only paternal transmission of SDHD-associated disease (Baysal et al. 2002), although recently a different mechanism has been proposed to account for exclusive paternal transmission (Hensen et al. 2004). PHEOs may be unilateral or bilateral and the mean age of diagnosis is 43 years.

### PGL–SDHB

PGL–SDHB is an autosomal-dominant syndrome characterized by sympathetic extraadrenal PGLs and

malignant disease (Brouwers et al. 2006, Timmers et al. 2007a,b). The syndrome is caused by inactivating mutations in the tumor suppressor SDHB gene located on chromosome 1p35–36 (Astuti et al. 2001). These mutations cause mitochondrial complex II destabilization and may activate the hypoxic/angiogenic pathway predisposing to tumor formation, with a very strong association with a malignant intra- or extraadrenal phenotype. Malignant PHEOs are reported in 35% in these patients (Neumann et al. 2004). In a series of 44 patients with malignant PGLs, SDHB mutations were found in 30% and nearly one-third had metastases originating from an adrenal primary tumor and two-thirds from an extraadrenal tumor. The latter patients had a frequency of SDHB mutations of 48%. This high frequency of SDHB mutations justifies the priority for SDHB germline mutations testing in these patients (Brouwers et al. 2006).

In another recent study of 29 patients with SDHB-related abdominal or thoracic PGLs, the mean age of diagnosis was  $33.7 \pm 15.7$  years, 76% had hypertension and 90% lacked a family history of PGL. All primary tumors, but one, originated from extraadrenal locations. Symptoms were related to tumor mass effect rather to catecholamine excess and the predominant biochemical phenotype consisted of hypersecretion of NE/dopamine, with 10% of tumors being silent (Timmers et al. 2007b). Therefore, SDHB mutation in a patient with single initial tumor is a prognostic factor for malignancy (Havekes et al. 2007). In families with SDHB mutations, maternal imprinting has not been noted. There is also an increased risk for renal cell carcinoma and papillary thyroid cancer (Schiavi et al. 2005).

### Other PGLs

A PGL caused by mutations in SDHC gene located on chromosome 1q21 has been described as an autosomal-dominant syndrome, without maternal imprinting. It is characterized by benign and seldom multifocal head and neck parasympathetic PGL (Schiavi et al. 2005). Another autosomal-dominant syndrome with familial head and neck parasympathetic PGLs has been described exclusively in children of fathers carrying the gene which was mapped to chromosome 11q13.1 but not identified yet (Mariman et al. 1995, Baysal et al. 1997).

### Genetic testing

Hereditary catecholamine-producing PHEOs and PGLs can be caused by germline mutations in any of the five above-described genes and mutation testing is

now routinely available for the four of the above genes. Extensive clinical experience demonstrates that germline mutations are responsible for about 25% of cases instead of 10% thought to be hereditary previously (Dluhy 2002). Most importantly, 7.5–27% of tumors without an obvious syndrome or family history result from otherwise unsuspected germline mutations in one of these four genes. Despite these high figures of unsuspected germline mutations, most experts agree that testing must be restricted to patients who fulfill several clinical criteria (Amar *et al.* 2005a, Gimenez-Roqueplo *et al.* 2006, Jimenez *et al.* 2006 Pacak *et al.* 2007).

### Family history

Familial PHEOs/PGLs syndromes are inherited in an autosomal-dominant manner; thus, an affected individual has a one in two (50%) chance of passing on the mutation to each child. A family history may be found in patients with VHL-, MEN2-, NF1-, and SDHD-related syndromes. In families with SDHD mutation, inheritance is complicated by the maternal imprinting phenomenon. It must be reminded that carriers of the SDHB or SDHD gene mutations do not necessarily have evidence of tumors. Those mutations have an age-related penetrance, and the lifetime risk of developing PGLs approaches 100% by the age of 70 years (Benn *et al.* 2006). In the absence of any family history, sudden deaths should be recorded, bearing in mind that 50% of catecholamine-producing tumors remain undiagnosed until death.

### Age in presentation

Hereditary tumors usually occur at a younger age than sporadic tumors, but the age range is wide being 5–69 years for the mutation carriers and 4–81 years in the

group of patients with no identified tumors (Gimenez-Roqueplo *et al.* 2006). Genetic testing is more necessary in young adults, especially for VHL disease, as 36% of PHEOs/PGLs in children occur secondary to germline mutations (Barontini *et al.* 2006).

### Tumor location – metastases

Patients with SDHB/SDHD gene mutations commonly present with extraadrenal often multifocal disease. SDHB gene mutations carry a high risk of malignant disease and therefore testing for such mutations is warranted and identification of a mutation in the SDHB gene is a high risk factor for malignancy. In contrast, malignant disease and extraadrenal tumors are rare in MEN2, so testing for RET gene mutations is not rewarding; furthermore, it is inappropriate to test for RET gene mutations in tumors characterized by an increase in urinary or plasma NE but not E. This differs from PHEOs in VHL syndrome which do not produce significant amounts of E (Table 1).

### Pathophysiology of hypertension

PHEO, even if they do not secrete, synthesize catecholamines at increased rates that may be up to 27 times the synthetic rate of the normal adrenal medulla. This persistent overproduction is due to lack of feedback inhibition on tyrosine hydroxylase. Catecholamines are then produced in quantities that greatly exceed the vesicular storage capacity and accumulate in the cytoplasm. Catecholamines in the cytoplasm are subject to intracellular metabolism; the excess catecholamines and their metabolites diffuse out of the PHEO cells into the circulation (Fitzerald & Goldfren 2004). In contrast to the normal adrenal medulla, PHEO cells ordinarily

**Table 1** Familial pheochromocytomas

	Family history/syndromic presentation	Adrenal tumors					Pheo/PGL
		Age <35 years	Bilateral	Extraadrenal	Malignant		
RET	+	+	++	–	–	Pheo	
VHL	+	++	+++	+	±	Pheo SPgl	
SDHD	+	±	+	+++	±	Pheo SPgl PPgl	
SDHB	+	±	+	+++	+++	Pheo SPgl PPgl	
NF1	+	±	±	Clinical criteria of NF1		Pheo SPgl	

SPgl, sympathetic paraganglioma; PPgl, parasympathetic paraganglioma.



contain more NE than E. The PHEO of the adrenal medulla in adults contain both catecholamines, whereas the extraadrenal PGLs rarely secrete E.

Traditionally, the hypertension of PHEO has been thought to result solely from the action of circulating catecholamines on cardiovascular circulating receptors. The activity of the SNS was thought to be normal or depressed reflexly because of baroreceptor resetting, and neurally released NE was considered of minor physiological importance in comparison with the effects of markedly elevated plasma catecholamine levels. However, clinical and experimental studies suggest that the SNS is intact, markedly enhanced and that SNS function is integral to the maintenance of elevated blood pressure (BP) in this form of catecholamine-induced hypertension (Langer et al. 1980, Johnson et al. 1983). The elevation of sympathetic activity during elevation of circulating catecholamines is postulated to be due to loading of sympathetic vesicles with catecholamines, increased sympathetic neuronal impulse frequency, and selective desensitization of presynaptic  $\alpha_2$ -adrenergic receptors, which results in enhanced release of neuronal NE during nerve stimulation. Therefore, because of enhanced SNS activity and excessive stores of NE in sympathetic nerve terminals, any direct or reflexly mediated stimulus to the SNS could release excessive quantities of NE into the synaptic cleft and produce a hypertensive crisis. The easier access of NE released from the postganglionic neuron at its receptor site on effector cells can result in marked symptoms with relatively small increments in circulating NE. These findings account for the observation that spontaneous or evoked crises in BP can occur without additional increases in the elevated plasma catecholamine levels and that BP may be normal despite high circulating catecholamine levels. This may account for the paroxysms of hypertension that are triggered by pain, emotional upset, intubation, anesthesia, or surgical skin incision and explain the elevations in serum and urine catecholamines that can occur for 10 days or longer after a successful surgical resection of PHEO (Bravo et al. 1990, Bravo & Tagle 2003).

Many PHEOs secrete significant amounts of neuropeptide Y (NPY) along with NE. NPY has potent direct and indirect cardiovascular effects. It increases coronary and peripheral vascular resistance independently of  $\alpha$ -adrenergic mechanisms by interacting with vascular G-protein-coupled receptors (O'Hare & Schwartz 1989). In some vascular beds, NPY has no direct vasoconstrictor effects but potentiates NE-induced vasoconstriction (Macho et al. 1989). NPY appears to contribute to hypertension in most patients

with PHEO. In contrast, few PGLs secrete NPY (deS Senanayake et al. 1995). PHEOs secrete many other peptides, many of which contribute to clinical symptoms, such as PTHrP (hypercalcemia), adrenocorticotrophin (ACTH; Cushing's syndrome), erythropoietin (erythrocytosis), and IL-6 (fever). Most PHEOs secrete chromogranin A which can be assayed as a tumor marker, and many secrete other peptides which have not been documented to produce clinical manifestations (Grossrubatscher et al. 2006).

## Clinical picture

The clinical picture is characterized by diverse manifestations reflecting the variations of hormone secretion, the patterns of release, and the individual-to-individual differences in catecholamine sensitivities (Eisenhofer et al. 2004, Amar et al. 2005b, Reisch et al. 2006, Sibal et al. 2006). As mentioned before, there is no correlation between circulating levels of catecholamines and hypertension. Plasma catecholamines were increased in periods of normotension in some patients and sudden increases in BP may not be encountered with further elevations in plasma catecholamines. In general, the hypertension is paroxysmal in 48% of patients, persisted in 29%, and 13% have normal BP (Bravo et al. 1979). NE-secreting tumors are usually associated with sustained hypertension. Tumors that secrete large amounts of E together with NE are associated with episodic hypertension. Pure E-producing tumors can produce hypotension rather than hypertension (Fitzgerald & Goldfren 2004). Large (~50 g) cystic PHEOs are often asymptomatic because the secreted catecholamines are metabolized within the tumor, and only a small amount of free catecholamines is released into circulation. Symptoms typically include a sudden rise of BP with concurrent episodes of headache (80%), diaphoresis (70%), and palpitations (60%). The episodes usually last minutes or hours; symptoms usually begin abruptly and subside shortly. These episodic paroxysms may not recur for months or may recur many times daily. Each patient tends to have a different pattern of symptoms, with the frequency of severity of episodes usually increasing over time. In one study, this symptomatic triad was found to have a sensitivity of 90.9% and specificity of 93.8% (Plouin et al. 1981). Other symptoms may include anxiety (50%), a sense of dread, tremor, or paresthesias. However, about 8% of patients may be completely asymptomatic, usually those with familial forms of the disease or with large, cystic tumors (Kudva et al. 1999). Approximately 5% of adrenal incidentalomas have proved to be PHEOs and

diagnosis relies on imaging phenotype and measurement of fractionated metanephrines and catecholamines in 24 h urine (Young 2007). The ‘typical’ clinical signs and symptoms occur more frequently in patients with benign tumors. Abdominal pain and dorsalgia occur more frequently in malignant PHEOs and short history and extraadrenal localization are suspicious for malignancy (Glodny *et al.* 2001). High preoperative 24-h urinary dopamine levels, high tumor weight, elevated tumor dopamine concentration, and postoperative persistent arterial hypertension are factors that increase the likelihood of malignant PHEO (Houbert *et al.* 1999).

Attacks can occur spontaneously or may occur with bladder catheterization, anesthesia, and surgery. Attacks can be induced by seemingly benign activities, such as bending, rolling over in bed, exertion, abdominal palpation, or micturition (with bladder PGLs). Other disorders can dominate the clinical picture such as hypercalcemia, Cushing’s syndrome, thyroid carcinoma, diabetes mellitus, or acute abdomen (Yip *et al.* 2003). Cardiovascular episodes, such as shock, myocarditis, dilated cardiomyopathy, cardiac arrhythmias, pulmonary edema, and heart failure, and neurological disorders, such as altered mental status, stroke, seizures, focal neurological signs, and symptoms, may also dominate the clinical picture and be the main cause of death (Sutton *et al.* 1981, Sibal *et al.* 2006). The administration of nonselective  $\beta$ -blocker therapy without preceding  $\alpha$ -blockade in a patient with PHEO may precipitate a crisis with hemodynamic collapse (Sloand & Thompson 1984). The opposite phenomenon has been described in an interesting case report. The administration of unopposed  $\alpha$ -blockade induced a state of  $\beta$ -adrenergic overstimulation with tachycardia, diastolic dysfunction, diffuse edema, and hypotension with peripheral vasodilation. The patient responded to small doses of 5 mg propranolol (Kantorovich & Pacak 2005).

A percentage of patients with PHEOs may present with minor or no signs and symptoms and some patients remain undiagnosed despite advances in diagnostic techniques. Elderly patients appear to present a special diagnostic challenge. A contributory factor to the delay in the antemortem diagnosis of PHEOs in the elderly may be a decrease in baroreceptor function with age, or concomitant diseases, the signs and symptoms of which can confound the diagnosis.

Patients with sustained hypertension usually exhibit episodes of orthostatic hypotension and even syncope, which are due to vasomotor receptor desensitization or diminished intravascular volume. Patients with tumors secreting E may present with sinus tachycardia and

peripheral vasoconstriction; the radial pulse can become thready or even nonpalpable during a hypertensive crisis. Vasoconstriction is also responsible for the pallor and mottled cyanosis that can occur with paroxysms of hypertension. Reflex vasodilation usually follows an attack of hypertension and can cause facial flushing. After an intense and prolonged attack of hypertension, shock may ultimately occur. This may be due to loss of vascular tone, low plasma volume, arrhythmias, or cardiac damage. In malignant PHEOs, metastases are usually functional and can cause recurrent hypertension and symptoms, many months or years after surgery that was thought to be curative. Metastases can cause a variety of problems as space-occupying lesions (Bouloux 2002, Bravo 2004). PHEOs or secreting PGLs may recur after initial surgery. The risk of recurrence is fairly high and these patients should be followed up indefinitely. The risk is higher in younger patients, with larger tumors and was more likely to have familial disease or bilateral extraadrenal or right-sided tumors (Amar *et al.* 2005b). On the other hand, no recurrence was found in 71 patients with benign tumors followed up for 144 months (Edström Elder *et al.* 2003).

### Biochemical diagnosis

The optimal approach to biochemical confirmation of catecholamine-secreting tumors is debatable. When performed under appropriate clinical settings, currently available tests can establish the diagnosis in more than 95% of cases. Given that PHEOs are a heterogeneous group of hormone-secreting tumors with variable metabolism, it is prudent to recommend that for a high diagnostic accuracy, multiple tests should be performed. The combination of different tests may increase sensitivity and specificity. Readily available biochemical tests include 24-h urinary catecholamines (NE and E) and vanillyl-mandelic acid (VMA), 24-h urinary total and fractionated metanephrines (normetanephrine and metanephrine), plasma concentrations of NE and E, and plasma concentrations of free metanephrines.

Whereas levels of free catecholamines are increased by even minimal anxiety and stress, levels of metanephrines are much less affected. Therefore, plasma catecholamines and metanephrines must be measured in a supine patient at rest for at least 20 min after insertion of an indwelling cannula in the forearm (Lenders *et al.* 2002, Eisenhofer *et al.* 2003) or in a seated ambulatory patient by standard venipuncture (Sawka *et al.* 2003). However, measurement of plasma metanephrines in blood samples collected from

patients in the supine position preserves the high diagnostic sensitivity of the test (Lenders *et al.* 2007).

### Urinary free catecholamines and metabolites

To detect the presence of a PHEO, 24 h urinary free NE and E and their metabolites (normetanephrine, metanephrine, and VMA) are commonly assayed. The demonstration of urinary NE > 170 µg/24 h, of urinary E more than 35 µg/24 h, urinary total metanephrines at least 1.8 mg/24 h, and urinary VMA at least 11.0 mg/24 h makes the diagnosis highly probable (Bravo & Tagle 2003, Kudva *et al.* 2003). Large cystic tumors may release mainly metabolized catecholamines into the circulation as reflected by a relatively high ratio of metabolites to free catecholamines in urine (Crout & Sjoerdsma 1964).

### Plasma catecholamines

The majority of patients with hormonally active PHEOs have elevated plasma levels of both NE and E, many exclusively NE and a much smaller proportion exclusively E. These differences in plasma catecholamine levels reflect differences in the expression of phenylethanolamine *N*-methyltransferase (PNMT), the enzyme that converts NE to E (Feldman *et al.* 1979). In a large series of 93 patients with either adrenal ( $n=80$ ) or extraadrenal ( $n=13$ ) PHEO, only three patients had plasma NE values that fell within the 95% upper confidence limits for values obtained in 104 patients with essential hypertension (i.e., 811 pg/ml). None had values that fell within the 95% upper confidence limits for gender- and age-matched 58 normotensive subjects (i.e., 402 pg/ml; Lenders *et al.* 1993). However, 30% of patients with adrenal and 62% of patients with extraadrenal PHEOs had plasma E values below the 95% upper confidence limits obtained in 104 patients with essential hypertension (i.e., 135 pg/ml; Lenders *et al.* 1993).

BP must be recorded during plasma sampling for catecholamine measurements. PHEO cannot be excluded if normal plasma catecholamine values are obtained when the patient is normotensive and asymptomatic. However, normal plasma catecholamine levels in a hypertensive and symptomatic patient make the diagnosis of a PHEO highly unlikely.

### Plasma metanephrines

Newer techniques, such as liquid chromatography, allow the separate measurement of normetanephrine, the *O*-methylated metabolite of NE, and metanephrine, the *O*-methylated metabolite of E. Most methods also allow additional measurements of methoxytyramine,

the *O*-methylated metabolite of dopamine (Eisenhofer *et al.* 2005). Measurements of the fractionated metabolites, although they are not widely available, are superior to measurements of total metanephrines in that they allow better detection of tumors that produce predominantly or only one of the three *O*-methylated metabolites (Eisenhofer 2003, Rosano *et al.* 1991, Gardet *et al.* 2001, Václavík *et al.* 2007).

PHEOs contain considerable amounts of the membrane-bound form of catechol-*O*-methyltransferase (COMT), resulting in local metabolism of catecholamines to free metanephrines (Eisenhofer *et al.* 1998). It has been shown that over 90% of circulating metanephrine and between 23 and 40% of circulating normetanephrine are produced by the metabolism of the parent catecholamines within the adrenal glands (Eisenhofer *et al.* 1995a,b). This makes the adrenals the single largest tissue source of circulating metanephrines in the body, with production surpassing by far that of metanephrines by the liver (Eisenhofer *et al.* 1995a).

In a large series of 208 patients with PHEOs, 23% had normal plasma NE concentrations compared with only 4% with normal levels of normetanephrine (Eisenhofer *et al.* 2003). Similarly, 68% of patients had normal plasma concentrations of E compared with only 47% with normal levels of metanephrine. Plasma levels of normetanephrine < 112 pg/ml and of metanephrine < 61 pg/ml virtually exclude PHEO. With plasma concentrations of normetanephrine above 400 pg/ml or of metanephrine above 236 pg/ml, the probability of PHEO is so high that the immediate task is to locate the tumor. When intermediate values are obtained, further investigation with pharmacologic tests is needed.

In another study, only 1 of 33 patients with PHEO had normal levels of both normetanephrine and metanephrine, a patient with a dopamine-secreting PGL (Sawka *et al.* 2003). Such tumors are extremely rare and are usually found as extraadrenal PGLs. Predominance of dopamine and relative lack of production of the other catecholamines in such tumors are due to deficiency in tumor cells of dopamine-β-hydroxylase, the enzyme that converts dopamine to NE (Eisenhofer *et al.* 2005).

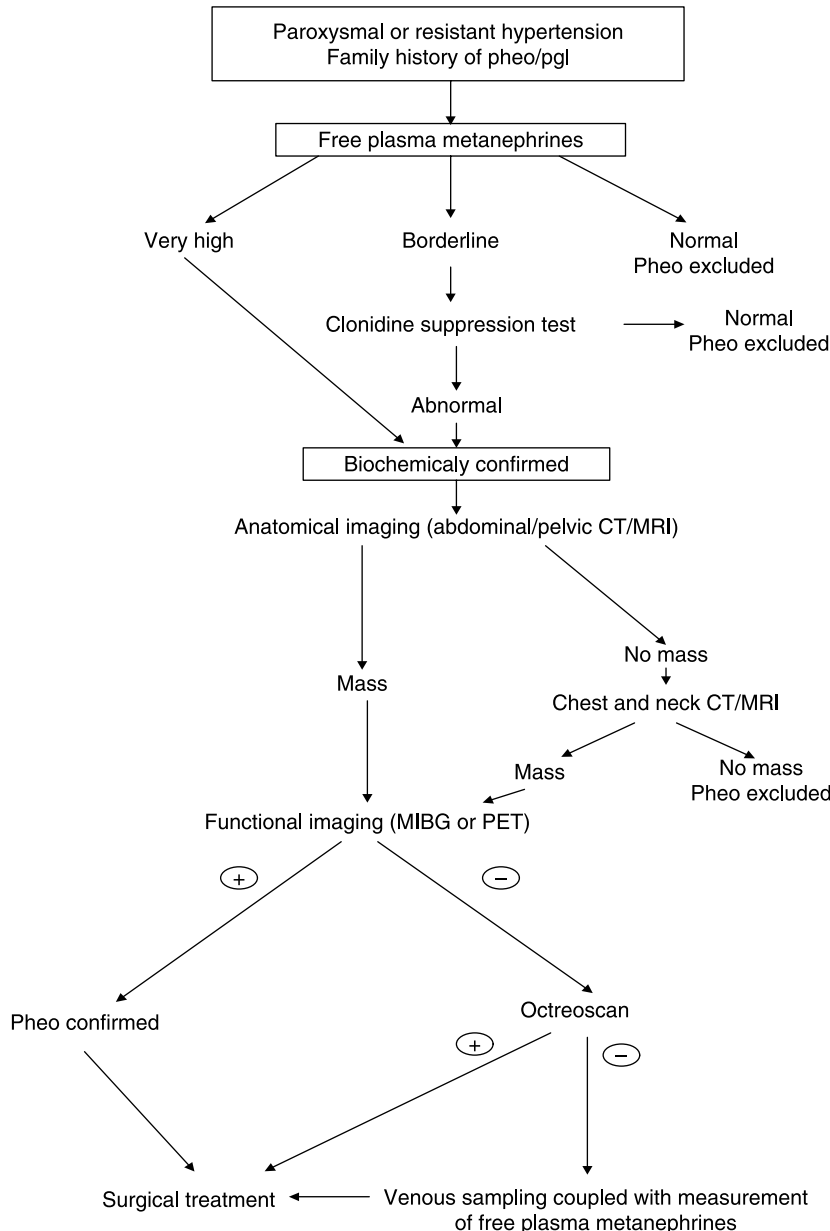
A multicenter cohort study examined the sensitivity and specificity of several biochemical tests in 214 patients with proven PHEOs (138 sporadic, 48 VHL, 23 MEN2, 3 NF1) and in 644 patients in whom the diagnosis was suspected but excluded (Lenders *et al.* 2002). In this study, the sensitivity of plasma free metanephrines was clearly superior to plasma catecholamines (99 vs 92% in sporadic PHEOs, and 97 vs 69% in hereditary PHEOs). The specificity of free metanephrines was also better in hereditary PHEOs (96 vs



89%), but was relatively low (82%), although superior to plasma catecholamines (72%). Test sensitivity for urinary fractionated metanephrines was similar to plasma free metanephrines, but lacked specificity for both hereditary (82%) and sporadic (45%) disease. In sporadic PHEOs, urinary catecholamines had excellent sensitivity (97%) and total metanephrines the best specificity (89%). The combination of different tests did not improve the diagnostic yield beyond that of a single test of plasma free metanephrines. The

advantage of plasma metanephrines is that they are continuously produced and released by the tumor, in contrast with plasma catecholamines which are released intermittently. The above results have led the authors to recommend against the use of multiple biochemical tests to exclude PHEO in favor of a single test of plasma free metanephrines (Fig. 1).

The combination of resting plasma catecholamines (NE plus E) at least 2000 pg/ml and urinary metanephrines (normetanephrine plus metanephrine) at least



**Figure 1** Algorithm for the biochemical and imaging diagnosis of pheo/PGL. Pheo, pheochromocytoma; PGL, paraganglioma; CT, computed tomography; MRI, magnetic resonance imaging; MIBG, metaiodobenzylguanidine; PET, positron emission tomography.

1.8 mg/24 h has a diagnostic accuracy close to 98% in both sporadic and hereditary PHEOs (Bravo & Tagle 2003). Assays for plasma catecholamines and urinary metanephrines have the lowest false-negative rates (7%), and assays of urinary NE and E the next higher (14%). Urinary VMA measurements have high false-negative rates (41%) and should not be used for screening purposes (Bravo & Tagle 2003). However, all four tests have excellent specificity when elevated. When available, the measurement of plasma free metanephrines should be performed, especially when hereditary PHEO is suspected. However, whether the measurement of plasma free metanephrines should be the sole diagnostic test for PHEO remains to be determined.

### Serum chromogranin-A (CgA)

CgA has been suggested as an alternative diagnostic test to catecholamines for the detection of PHEO, because neither its secretion nor its measurement is influenced by drugs commonly used for the treatment of hypertension in PHEO patients. However, mild degrees of renal impairment can lead to significant increases in serum concentration of CgA, because the kidneys play a major role in its clearance. Therefore, although CgA is relatively sensitive (86%) in the diagnosis of PHEO, it has poor diagnostic specificity. When combined with elevated plasma catecholamines in patients with creatinine clearance of at least 80 ml/min, its diagnostic specificity increases to 98% (Canale & Bravo 1994, d'Herbomez et al. 2007).

### Clinical situations and medication-associated false-positive results

When testing for PHEO, some consideration should be given to possible causes of false-positive results, including clinical situations, medications, inappropriate sampling conditions, and diet (Table 2). Biochemical testing for PHEO should ideally be carried out after discontinuation of medications known to influence catecholamine levels and their metabolites or interfere

**Table 2** Disorders that may increase both plasma and urinary catecholamines metabolites to levels often seen in pheochromocytoma

- 
- 1) Acute myocardial ischemia or infarction
  - 2) Acute cerebrovascular event
  - 3) Severe congestive heart failure
  - 4) Acute clonidine withdrawal
  - 5) Acute alcohol withdrawal
  - 6) Monotherapy with pure arterial vasodilators (as hydralazine or minoxidil)
  - 7) Cocaine abuse
- 

directly with biochemical analyses. Tricyclic antidepressants are the established cause of false-positive results, probably due to the inhibition of NE reuptake (Esler et al. 1991, Veith et al. 1994, Young 1997). Phenoxybenzamine (POB), a nonspecific  $\alpha$ -adrenoreceptor blocker commonly used in the treatment of patients with PHEO, may lead in high rates of false-positive results (Eisenhofer et al. 2003). False-positive elevations of plasma metanephrines and catecholamines with selective  $\alpha_1$ -adrenoreceptor blockers, such as doxazosin, are not a problem (Eisenhofer et al. 2003), while with calcium channel blockers appear restricted to NE, an effect most likely due to the reflexive sympathetic activation occurring with the short-acting agents (Wenzel et al. 1997).

Drugs that inhibit central sympathetic outflow, such as clonidine, methyldopa, and bromocriptine, decrease plasma catecholamines in normal and hypertensive subjects, but have little effect on the excessive catecholamine secretion by PHEO. Labetalol can increase plasma catecholamines and urinary metanephrines determined by HPLC (high pressure liquid chromatography) to values seen in PHEO (Feldman 1987). Acetaminophen can cause spurious increases in plasma free metanephrines. In addition, a urinary metabolite of buspirone, an anxiolytic drug, is artificially measured as metanephrine, resulting in marked increase in measured metanephrine excretion (Cook et al. 1995).

### Pharmacologic tests

Basal levels of plasma catecholamines are usually several-fold higher in patients with PHEO than in other subjects, even taking into account normal variations due to postural change, exercise, and emotional arousals. Basal total plasma catecholamine levels  $\geq 2000$  pg/ml is diagnostic of PHEO, while  $< 500$  pg/ml essentially rules it out. Concentrations in between, especially those exceeding 1000 pg/ml in medically stable patients, suggest the need for further testing and confirmation by pharmacologic tests, either provocative or suppressive.

### Provocative tests

A provocative test, with administration of histamine or glucagon, is rarely employed when the clinical findings are highly suggestive of PHEO, but the BP is normal or slightly elevated and plasma catecholamines are between 500 and 1000 pg/ml (Bravo & Gifford 1984). A positive glucagon stimulation test requires at least a 3.0-fold increase and/or more than 2000 pg/ml in total plasma catecholamines. This test

has high specificity (100%) but low sensitivity (81%). In addition, the glucagon stimulation test has proven insensitive in familial forms of PHEO (Walther *et al.* 1999b). Close monitoring of BP is required and phentolamine must be at hand for the treatment of severe hypertensive crises.

### Suppression tests

Suppression tests seem more physiologic and safer than provocative tests. The most widely used is the clonidine suppression test, which was introduced by Bravo *et al.* (1981) to address the problem of how to distinguish patients with PHEO from those with false-positive biochemical results after initial testing for the tumor. Clonidine, by activating  $\alpha_2$ -adrenoreceptors in the brain and the sympathetic nerve endings, suppresses NE release from sympathetic nerves. Therefore, decreases in elevated plasma NE levels after clonidine suggest sympathetic activation, whereas a lack of decrease suggests PHEO.

The clonidine suppression test is carried out after an overnight fast with the patient supine. Plasma catecholamines and metanephrines are measured before and 3 h after a single oral dose of clonidine (0.3 mg/70 kg, adjusted for body weight as necessary; Eisenhofer *et al.* 2003). A normal response is defined as a fall of plasma catecholamines from baseline of at least 50% and below 500 pg/ml. When the test is performed in patients with plasma catecholamines of at least 1000 pg/ml, the false-positive and false-negative rates are 2% (Bravo & Tagle 2003).

Another strategy to improve the sensitivity and specificity of the clonidine suppression test is to measure plasma normetanephrine. In hypertensive patients without PHEO, normetanephrine consistently decreases after the administration of clonidine. On the other hand, plasma normetanephrine levels do not fall and remain elevated after clonidine in 96% of patients with PHEO compared with only 67% for NE. Therefore, this metabolite may be a better endpoint marker for the clonidine suppression test than the parent amine, because PHEO cause larger, more consistent, and less episodic increases of normetanephrine than of NE (Eisenhofer *et al.* 1998, 2001a, Raber *et al.* 2000).

A remaining minor limitation is that responses of plasma metanephrine cannot be used to distinguish true- from false-positive results for this metabolite. This is due to the fact that over 90% of circulating metanephrine is normally derived from metabolism of E within adrenal chromaffin cells, a process that is independent of E release (Eisenhofer *et al.* 1995a,b). Indeed, plasma metanephrine concentrations do not

decrease after clonidine in patients without PHEO (Gutmann *et al.* 1994). In addition, clonidine-induced changes of E offer limited help (Gross *et al.* 1987, Mannelli *et al.* 1987).

### Localization

Only after the diagnosis of PHEO has been confirmed by biochemical studies, localization of the tumor should be attempted combining at least two imaging techniques (Fig. 1). Anatomical imaging studies, such as computed tomography (CT) and magnetic resonance imaging (MRI), should be combined with functional imaging studies, such as nuclear medicine methods, in order to locate adrenal, extraadrenal, recurrent, or metastatic PHEOs (Ilias & Pacak 2004). The clinicopathological behavior of these tumors may help localize them more precisely. Adrenal tumors are common in patients 60 years or older, are rarely associated with extraadrenal tumors, and may be bilateral when occurring in patients with familial syndromes. Therefore, age and the presence of family history are important considerations when determining the type and location of PHEO. The majority of tumors (95%) occur within the abdomen (Bravo 1994). The most common extraadrenal sites are the superior and inferior paraaortic areas (75%), the bladder (10%), the thorax (10%), and the head, neck, and pelvis (5%) (Whalen *et al.* 1992).

### Anatomical imaging

CT and MRI are common initial imaging modalities providing high sensitivity but less than optimal specificity (Ilias & Pacak 2004, Qiao *et al.* 2007). They should be carried out over the abdomen first, because PHEO are mostly situated within the adrenal medulla. If no adrenal masses are seen, attention should be focused initially to the paraspinous area. The majority of PGLs occurs in the paraaortic region or around the renal hilum and may be visible on CT/MRI (Mayo-Smith *et al.* 2001).

Adrenal PHEOs of 0.5–1.0 cm or larger or extraadrenal PHEOs at least 1.0–2.0 cm in size can be detected by CT preferably with scanning sections of 2–5 mm thickness (Quint *et al.* 1987, Pacak *et al.* 2001c,d). CT densitometry may help to differentiate adrenal adenomas from metastases (Dunnick & Korobkin 2002). Small PHEOs (1–2 cm in diameter) are usually homogeneous in appearance, with soft tissue density (~40–50 Hounsfield units) and show uniform enhancement with contrast. Larger PHEOs may undergo hemorrhage and can be unhomogeneous,

while areas of low density can be seen after tumor necrosis (Dacie & White 1993, Sohaib *et al.* 2001). If the CT of the abdomen and pelvis is negative, a CT of the chest and neck should be performed (Braedel *et al.* 1986, Bender *et al.* 1997). Spiral CT is preferred for the detection of small thoracic tumors (Shin *et al.* 1986). If the PHEO tumor has been localized, there is no need to proceed to MRI, but functional imaging is required to confirm that the tumor is indeed a PHEO and to rule out metastatic disease.

If the CT is negative, in a patient with biochemically proven PHEO, MRI should be performed. MRI, with or without gadolinium enhancement, provides the highest sensitivity among current imaging techniques. On MRI T<sub>1</sub> sequences, PHEOs have a signal like those of liver, kidney, and muscle and can be differentiated easily from adipose tissue. PHEOs appear hyperintense to the liver or muscle on T<sub>2</sub>-weighted image, whereas benign tumors appear isointense. However, such intense signals can be elicited by hemorrhages or hematomas, adenomas, and carcinomas, so an overlap with PHEOs must be considered and specific additional imaging is needed to confirm that the tumor is PHEO (Varghese *et al.* 1997, Mayo-Smith *et al.* 2001, Prager *et al.* 2002). MRI should be substituted for CT in children, pregnant women, and situations where radiation exposure must be minimized (Witteles *et al.* 2000).

### Functional imaging

Adrenal masses are present in about 5–9% of the general population (Angeli & Terzolo 2002, Grumbach *et al.* 2003, Thompson & Young 2003). In patients without known primary cancers, about 90% of incidental masses are benign. In patients without clinical evidence of adrenal hyperfunction, about 85% are nonfunctional. Nonetheless, every adrenal mass should be evaluated to rule out hypersecretion, malignancy, or metastasis to the adrenal gland. The prevalence of malignancy in sporadic adrenal PHEOs is 9% (Bravo & Tagle 2003) and about 10% of patients with PHEOs present with metastatic disease at the time of their initial work-up (Goldstein *et al.* 1999). Given that there is no consensus on the existence of absolute clinical, laboratory, or imaging criteria to predict malignancy and multiplicity of PHEOs (van der Harst *et al.* 2000, Thompson 2002), the need to exclude metastatic disease or multiple tumors is important. This need might be fulfilled with functional imaging modalities using various radiopharmaceuticals that provide physicians with whole body, PHEO-specific, scans.

PHEO cells usually abundantly express specific catecholamine plasma membrane and vesicular transporter systems, enabling imaging with metaiodobenzylguanidine ([<sup>131</sup>I]MIBG) and [<sup>123</sup>I]MIBG scintigraphy, as well as several positron emission tomography (PET) ligands (Fig. 1). The functional imaging test of choice is [<sup>123</sup>I]MIBG scintigraphy (sensitivity, 83–100%; specificity, 95–100%), or, if this is not available, then [<sup>131</sup>I]MIBG scintigraphy should be performed (sensitivity, 77–90%; specificity, 95–100%; Bravo 1994, Nielsen *et al.* 1996, Furuta *et al.* 1999, van der Harst *et al.* 2001, Cecchin *et al.* 2006, Pacak *et al.* 2007).

If the MIBG scan is negative, PET imaging using 6-[<sup>18</sup>F]-fluorodopamine (DA), [<sup>18</sup>F]-dihydroxyphenylalanine (DOPA), [<sup>11</sup>C]-hydroxyephedrine, or [<sup>11</sup>C]-epinephrine are new promising, specific radionuclide techniques for localization of PHEOs (Shulkin *et al.* 1992, Pacak *et al.* 2001a, Ilias & Pacak 2004, Kaji *et al.* 2007). [<sup>18</sup>F]DA has been proven to be an excellent agent to localize adrenal and extraadrenal PHEOs, including metastatic lesions (Pacak *et al.* 2001a). [<sup>18</sup>F]DA is also more specific for the diagnosis of PHEOs than other amines such as DOPA, because the latter are taken up as amines by all body cells and are converted to DA (Ilias & Pacak 2004). In cases of aggressive PHEOs, which can be both [<sup>123</sup>I]MIBG scintigraphy and 6-[<sup>18</sup>F]-fluorodopamine negative, [<sup>18</sup>F]-fluorodeoxyglucose PET ([<sup>18</sup>F]-FDG) may be useful in the diagnostic localization of metastatic PHEO (Shulkin *et al.* 1999, Mamede *et al.* 2006, Timmers *et al.* 2007a). FDG PET is not recommended for initial diagnostic localization, because its sensitivity is slightly less than that of MIBG and its specificity is considerably lower due to uptake of FDG by a variety of other neoplastic and nonneoplastic processes (Shulkin *et al.* 1999).

If the PET study is also negative, the patient probably has an unusual type of PHEO (in which tumor cells do not express the NE transporter system or may have a low number of catecholamine storage granules), or malignant PHEO, and scintigraphy nonspecific ligands, such as somatostatin receptor, scintigraphy with octreoscan should be carried out (Fig. 1). Somatostatin receptor scintigraphy, with either [<sup>123</sup>I]Tyr3-octreotide or [<sup>111</sup>In]DTPA-octreotide, has been used in patients with PHEOs (Krenning *et al.* 1993, Lastoria *et al.* 1995, Lauriero *et al.* 1995, Tenenbaum *et al.* 1995, Kopf *et al.* 1997, Limouris *et al.* 1997). Octreoscan studies may be negative in most patients with benign PHEOs, despite positive [<sup>123</sup>I]MIBG or [<sup>131</sup>I]MIBG studies (Maurea *et al.* 1996, van der Harst *et al.* 2001). Malignant or metastatic



PHEOs are better detected with octreoscan compared with [ $^{123}\text{I}$ ]MIBG (87 vs 57%) (van der Harst *et al.* 2001), because MIBG as well as [ $^{18}\text{F}$ ]DA are sometimes negative in patients with malignant PHEOs, possibly due to decreased expression of the cell membrane NE transporter by less well-differentiated cells (Ramachandran *et al.* 1993, Houben *et al.* 1994).

Venous sampling coupled with measurement of catecholamines or, preferably, free metanephrines to localize the tumor through the discovery of a secretory gradient is an ultimate modality to be used with caution in selected cases, where all imaging have failed (Newbould *et al.* 1991, Chew *et al.* 1994, Pacak *et al.* 2001d). If this is technically impossible, a repeat noninvasive localization work-up after 2–6 months is a more attractive and preferable choice.

## Management

After precise localization, surgical removal of the tumor should follow with the expectation that all symptoms will be relieved in the majority of patients with benign PHEOs and in the hope that metastatic spread will be limited in the minority with malignant ones. Appropriate anti-hypertensive drugs are used to manage hypertension, prevent cardiovascular complications, and diminish the magnitude of postoperative hypotension.

The preoperative use of the nonselective  $\alpha$ -blocker POB was mainly advocated to counteract the sudden release of catecholamines during surgical intervention (Ross *et al.* 1967, Perry & Gould 1972). The dose is increased over a period of 14 days, starting with 10 mg b.d. Under tight BP control, the dose is increased by 10 mg per day up to 1 mg/kg per day, in three divided doses (Kinney *et al.* 2002). However, POB produces significant orthostatic hypotension and reflex tachycardia, while it may prolong and contribute to the hypotension that follows operation. Yet, despite adequate  $\alpha$ -blockade, total elimination of cardiovascular disturbances is seldom achieved, and hypertensive crises have been reported in patients during manipulation of the tumor (Desmonts & Marty 1984). It has also been reported that similar perioperative complications occurred whether or not patients received preoperative  $\alpha$ -blockers (Newell *et al.* 1988, Boutros *et al.* 1990). In another study, fewer perioperative complications were observed in those not given  $\alpha$ -blockers (Ulchaker *et al.* 1999).

Selective postsynaptic  $\alpha_1$ -receptor antagonists, such as prazosin, terazosin, and doxazosin, have been used to circumvent some of the side effects of POB. Since these drugs leave the presynaptic receptors on the neuronal surface open, they do not produce reflex tachycardia

(Prys-Roberts 2000). In addition, they have a shorter duration of action, permitting more rapid adjustment of dosage and a reduced duration of postoperative hypotension (Bravo & Tagle 2003). Gradual increase of dose from 1 to 16 mg once a day is necessary.

$\beta$ -Blockers should be given to control tachycardia and arrhythmias, but only after  $\alpha$ -blockers have been started. Nonselective  $\beta$ -blockers lead to the loss of  $\beta_2$ -receptor-mediated vasodilatation and the unopposed effects of  $\alpha$ -receptors cause vasoconstriction leading to arterial hypertension and increased afterload, causing myocardial infarction and pulmonary edema (Wark & Larkins 1978, Sloand & Thompson 1984, Baysal *et al.* 2000).

Calcium channel blockers have been used alone or with selective  $\alpha_1$ -receptor blockers to successfully control BP and symptoms in patients with PHEO (Serfas *et al.* 1983, Lenders *et al.* 1985, Takahashi *et al.* 1989). They relax arteriolar smooth muscle and decrease peripheral vascular resistance by inhibiting NE-mediated release of intracellular calcium and/or transmembrane calcium influx in vascular smooth muscle (Lehmann *et al.* 1983). These drugs do not produce hypotension and therefore may be used safely in patients who are normotensive but have occasional episodes of paroxysmal hypertension. In addition, they are useful in managing cardiovascular complications because they prevent catecholamine-induced coronary vasospasm and myocarditis. Hypertensive crises are controlled with nitroprusside, nitroglycerine, or phentolamine.

The combination of CT or MRI with MIBG scintigraphy has contributed to the precise localization of PHEO. In addition, the availability of new drugs and procedures to safeguard intraoperative hemodynamics and the introduction of innovative surgical techniques have dramatically changed the surgical approach to PHEO.

Since its first description in 1992, laparoscopic adrenalectomy has become the preferred method for the removal of the tumor (Gagner *et al.* 1992). However, for the time being, there are few studies comparing intraoperative hemodynamic stability in laparoscopic versus conventional open surgery with heterogeneous results (Fernandez-Cruz *et al.* 1996, Inabnet *et al.* 2000, Sprung *et al.* 2000, Edwin *et al.* 2001, Kazaryan *et al.* 2004, Kim *et al.* 2004). There are no randomized trials. In two studies, the intraoperative hemodynamic values during laparoscopic adrenalectomy were comparable to those of traditional open surgery (Sprung *et al.* 2000, Weismann *et al.* 2006). In the past, the upper limit for endoscopic resection of PHEO was 6 cm; however, as experience has grown, many authors currently report excisions up to 11 cm (Kalady *et al.* 2004). The advantages of the minimal invasive techniques are shorter hospital stay and recovery time, decreased requirements

for analgesics, a cosmetically better result, and patient satisfaction. In cases of bilateral sporadic or hereditary PHEO, adrenal sparing surgery preserving adrenocortical function should be favored (Neumann *et al.* 1999).

Patients with PHEO have a high plasma volume requirement during and after surgery. Expansion of intravascular volume either with plasma volume expanders or 2 l normal saline the evening before surgery and the generous replacement of blood loss during the procedure greatly reduce the frequency and the severity of postoperative hypotension. It is well known that intraoperative hypertensive episodes are related to a sudden and marked catecholamine release from the tumor (Joris *et al.* 1999). In most cases, this is a consequence of direct tumor manipulation (Fernandez-Cruz *et al.* 1996), but it may also be triggered by the pneumoperitoneum of the laparoscopy approach due to its mechanical effect on the tumor (Tauzin-Fin *et al.* 2004).

The principal responsible factor for the postoperative severe hypotension seems to be the shrunken blood volume, which is no longer supported by intense vasoconstriction. In addition, the sudden decrease of catecholamines in the immediate postoperative period leads to an increase in insulin secretion and simultaneous decrease in the formation of glucose from glycogen and fat, resulting in hypoglycemia. Biochemical evidence that the tumor is successfully removed cannot be obtained immediately, because plasma catecholamines remain high for some days (Bravo *et al.* 1979). This is probably due to the emptying of extratumoral pools of catecholamines and should not be interpreted only as a partial response to surgery. The normalization of plasma and urinary catecholamine and metanephrine concentrations should be checked 10 days after surgery. If these concentrations remain high, [<sup>123</sup>I]MIBG scintigraphy should be performed and may disclose distant metastases, for which MIBG uptake was masked before surgery by the higher metabolic activity of the primary tumor (Plouin & Gimenez-Roqueplo 2006). PHEO is considered a curable cause of hypertension. If the BP remains high after operation, some of the tumor may have been left behind, or a renal artery may have been injured, with induction of renovascular hypertension.

Since PHEO can recur, patients must be followed up for the rest of their lives, particularly if they have inherited or extraadrenal tumors (Lenders *et al.* 2005). The prognosis is usually excellent for benign PHEOs. In a large series, the risk of recurrence was 3.4-fold higher with a familial disease, 3.1-fold higher with a right rather than a left tumor, and 11.2-fold higher with extraadrenal tumors (Amar *et al.* 2005b). In patients with one of the familial syndromes, repeated catecholamine assays in combination with plasma

calcitonin levels and palpation of the neck for medullary thyroid cancer should be continued for life.

## Management of malignant PHEO

Malignant PHEO is compatible with prolonged survival, with symptom-free intervals varying from months to decades. Metastases may appear many years after removal of an apparently benign tumor, and there is at present no certain way to predict which tumors will progress to malignancy. Prognostic factors that have been suggested for future malignancy include large tumor size, local tumor extension at the time of surgery, and the DNA ploidy pattern with DNA diploid being benign and DNA aneuploidy and tetraploidy having a more aggressive nature (Nativ *et al.* 1992). It has also been reported that the expression of inhibin/activin  $\beta$ B-subunit was absent or weak in malignant PHEO, while it was strong or moderate in almost all benign adrenal tumors (Salmenkivi *et al.* 2001). Another study suggested that the lack of NPY mRNA expression may differentiate malignant from benign PHEOs (Helman *et al.* 1989). Various other molecular markers have been proposed, such as expression of human telomerase reverse transcriptase, heat shock protein 90, serotonin II-derived peptide (Eisenhofer *et al.* 2004). In clinical practice, the only reliable criterion of malignancy is the presence of distant metastases.

Factors associated with better prognosis seem to include early diagnosis and excision of the primary tumor and, whenever possible, aggressive excision of any recurrence or soft-tissue metastases (Eisenhofer *et al.* 2004). In cases not suitable for surgery, pharmacological treatment with  $\alpha$ -methyl-paratyrosine, an inhibitor of catecholamine synthesis, may improve quality of life but has no effect on tumor progression (Steinsapir *et al.* 1997). Conventional radiotherapy may provide effective palliation in patients with painful metastases. [<sup>131</sup>I]MIBG can be used as therapeutic option, given that the tumor shows uptake of MIBG. This may yield partial remission in 24–54% of patients and has even been reported to produce complete remission (Eisenhofer *et al.* 2004, Salmenkivi *et al.* 2004). If [<sup>131</sup>I]MIBG uptake is low, octreotide should be another therapeutic option, because several PHEOs express type 2 and 3 somatostatin receptors. However, the available data are rare and inconsistent (Eisenhofer *et al.* 2004). Another option is the application of high-dose [<sup>131</sup>I]MIBG (Rose *et al.* 2003). In case of no radionuclide uptake, chemotherapy should be administered. Given that there is no evidence-based chemotherapy protocol, the most widely used is the CVD protocol combining cyclophosphamide, vincristine, and dacarbazine (Averbuch *et al.* 1988).

In rapidly progressive metastatic PHEOs, chemotherapy should be used as first-line therapy (Scholz *et al.* 2007). There are also reports for beneficial and additive effects of combined regime of chemotherapy and [<sup>131</sup>I]MIBG therapy (Shapiro *et al.* 2001, Sisson 2002). Radiofrequency ablation of hepatic and bone metastasis has shown promise in some selected cases (Pacak *et al.* 2001b). Promising new therapies might be developed such as inhibition of heat shock protein 90 and human telomerase reverse transcriptase or anti-angiogenic drugs (Eisenhofer *et al.* 2004).

## Conclusions

It is widely accepted that a significant percentage of patients with sporadic PHEO and functional PGL may have germline mutations predisposing to the development of more generalized diseases. Several clinical characteristics, such as young age at onset, the presence of bilateral, extraadrenal, or multiple tumors or a malignant tumor should be seen as indications for genetic testing. The classical clinical picture, the biochemical testing, and the proper use of at least two imaging, anatomical and functional, techniques will confirm the diagnosis. The surgical removal of the tumor in sporadic cases will cure the patient, but in familial syndromes this has to be supplemented by a careful clinical follow-up for future recurrences. Therefore, in sporadic PHEOs, genetic testing will provide additional information necessary for a rational approach and management.

## Acknowledgements

The authors declare that there is no conflict of interest that would prejudice the impartiality of this scientific work.

## References

- Amar L, Bertherat J, Baudin E, Ajzenberg C, Bressac-de Paillerets B, Chabre O, Chamontin B, Delemer B, Giraud S, Murat A *et al.* 2005a Genetic testing in pheochromocytoma or functional paraganglioma. *Journal of Clinical Oncology* **23** 8812–8818.
- Amar L, Servais A, Gimenez-Roqueplo AP, Zinzindohoue F, Chatellier G & Plouin PF 2005b Year of diagnosis features at presentation, and risk of recurrence in patients with pheochromocytoma or secreting paraganglioma. *Journal of Clinical Endocrinology and Metabolism* **90** 2110–2116.
- Angeli A & Terzolo M 2002 Adrenal incidentaloma—a modern disease with old complications. *Journal of Clinical Endocrinology and Metabolism* **87** 4869–4871.
- Astuti D, Douglas F, Lennard TW, Aligianis IA, Woodward ER, Evans DG, Eng C, Latif F & Maher ER 2001 Germline SDHD mutation in familial pheochromocytoma. *Lancet* **357** 1181–1182.
- Averbuch SD, Steakley CS, Young RC, Gelmann EP, Goldstein DS, Stull R & Keiser HR 1988 Malignant pheochromocytoma: effective treatment with a combination of cyclophosphamide, vincristine, and dacarbazine. *Annals of Internal Medicine* **109** 267–273.
- Barontini M, Levin G & Sanso G 2006 Characteristics of pheochromocytoma in a 4- to 20-year-old population. *Annals of the New York Academy of Sciences* **1073** 30–37.
- Bausch B, Koschker AC, Fassnacht M, Stoevesandt J, Hoffmann MM, Eng C, Allolio B & Neumann HP 2006 Comprehensive mutation scanning of NF1 in apparently sporadic cases of pheochromocytoma. *Journal of Clinical Endocrinology and Metabolism* **91** 3478–3481.
- Bausch B, Borozdin W, Mautner VF, Hoffmann MM, Boehm D, Robledo M, Cascon A, Harenberg T, Schiavi F, Pawlu C *et al.* 2007 Germline NF1 mutational spectra and loss-of-heterozygosity analyses in patients with pheochromocytoma and neurofibromatosis type 1. *Journal of Clinical Endocrinology and Metabolism* **92** 2784–2792.
- Baysal BE, Farr JE, Rubinstein WS, Galus RA, Johnson KA, Aston CE, Myers EN, Johnson JT, Carrau R, Kirkpatrick SJ *et al.* 1997 Fine mapping of an imprinted gene for familial nonchromaffin paragangliomas, on chromosome 11q23. *American Journal of Human Genetics* **60** 121–132.
- Baysal BE, Ferrell RE, Willett-Brozick JE, Lawrence EC, Myssiorek D, Bosch A, van der Mey A, Taschner PE, Rubinstein WS, Myers EN *et al.* 2000 Mutations in SDHD, a mitochondrial complex II gene, in hereditary paraganglioma. *Science* **287** 848–851.
- Baysal BE, Willett-Brozick JE, Lawrence EC, Drovdic CM, Savul SA, McLeod DR, Yee HA, Brackmann DE, Slattery WH III, Myers EN *et al.* 2002 Prevalence of SDHB, SDHC, and SDHD germline mutations in clinic patients with head and neck paragangliomas. *Journal of Medical Genetics* **39** 178–183.
- Beard CM, Sheps SG, Kurland LT, Carney JA & Lie JT 1983 Occurrence of pheochromocytoma in Rochester, Minnesota, 1950 through 1979. *Mayo Clinic Proceedings* **58** 802–804.
- Bender BU, Altehofer C, Januszewicz A, Gartner R, Schmidt H, Hoffmann MM, Heidemann PH & Neumann HP 1997 Functioning thoracic paraganglioma: association with Von Hippel–Lindau syndrome. *Journal of Clinical Endocrinology and Metabolism* **82** 3356–3360.
- Benn DE, Gimenez-Roqueplo AP, Reilly JR, Bertherat J, Burgess J, Byth K, Croxson M, Dahia PL, Elston M, Gimm O *et al.* 2006 Clinical presentation and penetrance of pheochromocytoma/paraganglioma syndromes. *Journal of Clinical Endocrinology and Metabolism* **91** 827–836.
- Bouloux PMC 2002 Pheochromocytoma, paragangliomas, and neuroblastoma. In *Oxford Textbook of Endocrinology and Diabetes*, pp 775–789. Eds JA Wass & SM Shalet. New York: Oxford University Press.

- Boutros AR, Bravo EL, Zanettin G & Straffon RA 1990 Perioperative management of 63 patients with pheochromocytoma. *Cleveland Clinic Journal of Medicine* **57** 613–617.
- Braedel HU, Lindinger A, Berberich R, Schindler E & Crisp-Lindgren N 1986 Multiple extra-adrenal and thoracic pheochromocytomas. *Urology* **28** 95–99.
- Brandi ML, Gagel RF, Angeli A, Bilezikian JP, Beck-Peccoz P, Bordi C, Conte-Devolx B, Falchetti A, Gheri RG, Libroia A et al. 2001 Guidelines for diagnosis and therapy of MEN type 1 and type 2. *Journal of Clinical Endocrinology and Metabolism* **86** 5658–5671.
- Bravo EL 1994 Evolving concepts in the pathophysiology, diagnosis, and treatment of pheochromocytoma. *Endocrine Reviews* **15** 356–368.
- Bravo EL 2004 Pheochromocytoma: current perspectives in the pathogenesis, diagnosis, and management. *Arquivos Brasileiros de Endocrinologia and Metabologia* **48** 746–750.
- Bravo EL & Gifford RW Jr 1984 Current concepts. Pheochromocytoma: diagnosis, localization and management. *New England Journal of Medicine* **311** 1298–1303.
- Bravo EL & Tagle R 2003 Pheochromocytoma: state-of-the-art and future prospects. *Endocrine Reviews* **24** 539–553.
- Bravo EL, Tarazi RC, Gifford RW & Stewart BH 1979 Circulating and urinary catecholamines in pheochromocytoma. Diagnostic and pathophysiologic implications. *New England Journal of Medicine* **301** 682–686.
- Bravo EL, Tarazi RC, Fouad FM, Vidt DG & Gifford RW Jr 1981 Clonidine-suppression test: a useful aid in the diagnosis of pheochromocytoma. *New England Journal of Medicine* **305** 623–626.
- Bravo E, Fouad-Tarazi F, Rossi G, Imamura M, Lin WW, Madkour MA, Wicker P, Cressman MD & Saragoca M 1990 A reevaluation of the hemodynamics of pheochromocytoma. *Hypertension* **15** 1128–1131.
- Brouwers FM, Eisenhofer G, Tao JJ, Kant JA, Adams KT, Linehan WM & Pacak K 2006 High frequency of SDHB germline mutations in patients with malignant catecholamine-producing paragangliomas: implications for genetic testing. *Journal of Clinical Endocrinology and Metabolism* **91** 4505–4509.
- Canale MP & Bravo EL 1994 Diagnostic specificity of serum chromogranin-A for pheochromocytoma in patients with renal dysfunction. *Journal of Clinical Endocrinology and Metabolism* **78** 1139–1144.
- Cecchin D, Lumachi F, Marzola MC, Opocher G, Scaroni C, Zucchetta P, Mantero F & Bui F 2006 A meta-iodobenzylguanidine scintigraphic scoring system increases accuracy in the diagnostic management of pheochromocytoma. *Endocrine-Related Cancer* **13** 525–533.
- Chevinsky AH, Minton JP & Falko JM 1990 Metastatic pheochromocytoma associated with multiple endocrine neoplasia syndrome type II. *Archives of Surgery* **125** 935–938.
- Chew SL, Dacie JE, Reznick RH, Newbould EC, Sheaves R, Trainer PJ, Lowe DG, Shand WS, Hungerford J & Besser GM 1994 Bilateral pheochromocytomas in von Hippel–Lindau disease: diagnosis by adrenal vein sampling and catecholamine assay. *Quarterly Journal of Medicine* **87** 49–54.
- Choyke PL, Glenn GM, Walther MM, Patronas NJ, Linehan WM & Zbar B 1995 Von Hippel–Lindau disease: genetic, clinical, and imaging features. *Radiology* **194** 629–642.
- Cook FJ, Chandler DW & Snyder DK 1995 Effect of buspirone on urinary catecholamine assays. *New England Journal of Medicine* **332** 401.
- Crout JR & Sjoerdsma A 1964 Turnover and metabolism of catecholamines in patients with pheochromocytoma. *Journal of Clinical Investigation* **43** 94–102.
- Dacie JE & White FE 1993 Radiology of endocrine disease. In *Atlas of Endocrine Imaging*, pp 1–78. Eds GM Besser & MO Thorner. London: Wolfe.
- Desmots JM & Marty J 1984 Anaesthetic management of patients with pheochromocytoma. *British Journal of Anaesthesia* **56** 781–789.
- d’Herbomez M, Forzy G, Bauters C, Tierny C, Pigny P, Carnaille B, Pattou F, Wémeau JL & Rouaix N 2007 An analysis of the biochemical diagnosis of 66 pheochromocytomas. *European Journal of Endocrinology* **156** 569–575.
- Dluhy RG 2002 Pheochromocytoma – death of an axiom. *New England Journal of Medicine* **346** 1486–1488.
- Dunnick NR & Korobkin M 2002 Imaging of adrenal incidentalomas: current status. *American Journal of Roentgenology* **179** 559–568.
- Edström Elder E, Hjelm Skog AL, Höög A & Hamberger B 2003 The management of benign and malignant pheochromocytoma and abdominal paraganglioma. *European Journal of Surgical Oncology* **29** 278–283.
- Edwin B, Kazaryan AM, Mala T, Pfeffer PF, Tonnessen TI & Fosse E 2001 Laparoscopic and open surgery for pheochromocytoma. *BMC Surgery* **1** 2.
- Eisenhofer G 2003 Editorial: biochemical diagnosis of pheochromocytoma—is it time to switch to plasma-free metanephrines? *Journal of Clinical Endocrinology and Metabolism* **88** 550–552.
- Eisenhofer G, Friberg P, Pacak K, Goldstein DS, Murphy DL, Tsigos C, Quyyumi AA, Brunner HG & Lenders JW 1995a Plasma metadrenalines: do they provide useful information about sympatho-adrenal function and catecholamine metabolism? *Clinical Science* **88** 533–542.
- Eisenhofer G, Rundquist B, Aneman A, Friberg P, Dakak N, Kopin IJ, Jacobs MC & Lenders JW 1995b Regional release and removal of catecholamines and extraneuronal metabolism to metanephrines. *Journal of Clinical Endocrinology and Metabolism* **80** 3009–3017.
- Eisenhofer G, Keiser H, Friberg P, Mezey E, Huynh TT, Hiremagalar B, Ellingson T, Duddempudi S, Eijssbouts A & Lenders JW 1998 Plasma metanephrines are markers of pheochromocytoma produced by catechol-O-methyltransferase within tumors. *Journal of Clinical Endocrinology and Metabolism* **83** 2175–2185.
- Eisenhofer G, Lenders JW, Linehan WM, Walther MM, Goldstein DS & Keiser HR 1999 Plasma normetanephrine



- and metanephrine for detecting pheochromocytoma in von Hippel–Lindau disease and multiple endocrine neoplasia type 2. *New England Journal of Medicine* **340** 1872–1879.
- Eisenhofer G, Huynh TT, Hiroi M & Pacak K 2001a Understanding catecholamine metabolism as a guide to the biochemical diagnosis of pheochromocytoma. *Reviews in Endocrine and Metabolic Disorders* **2** 297–311.
- Eisenhofer G, Walther MM, Huynh TT, Li ST, Bornstein SR, Vortmeyer A, Mannelli M, Goldstein DS, Linehan WM, Lenders JW *et al.* 2001b Pheochromocytomas in von Hippel–Lindau syndrome and multiple endocrine neoplasia type 2 display distinct biochemical and clinical phenotypes. *Journal of Clinical Endocrinology and Metabolism* **86** 1999–2008.
- Eisenhofer G, Goldstein DS, Walther MM, Friberg P, Lenders JW, Keiser HR & Pacak K 2003 Biochemical diagnosis of pheochromocytoma: how to distinguish true-from false-positive test results. *Journal of Clinical Endocrinology and Metabolism* **88** 2656–2666.
- Eisenhofer G, Bornstein SR, Brouwers FM, Cheung NK, Dahia PL, de Krijger RR, Giordano TJ, Greene LA, Goldstein DS, Lehnert H *et al.* 2004 Malignant pheochromocytoma: current status and initiatives for future progress. *Endocrine-Related Cancer* **11** 423–436.
- Eisenhofer G, Goldstein DS, Sullivan P, Csako G, Brouwers FM, Lai EW, Adams KT & Pacak K 2005 Biochemical and clinical manifestations of dopamine-producing paragangliomas: utility of plasma methoxytyramine. *Journal of Clinical Endocrinology and Metabolism* **90** 2068–2075.
- Eng C, Clayton D, Schuffenecker I, Lenoir G, Cote G, Gagel RF, van Amstel HK, Lips CJ, Nishisho I, Takai SI *et al.* 1996 The relationship between specific RET proto-oncogene mutations and disease phenotype in multiple endocrine neoplasia type 2. International RET mutation consortium analysis. *JAMA* **276** 1575–1579.
- Erickson D, Kudva YC, Ebersold MJ, Thompson GB, Grant CS, van Heerden JA & Young WF Jr 2001 Benign paragangliomas: clinical presentation and treatment outcomes in 236 patients. *Journal of Clinical Endocrinology and Metabolism* **86** 5210–5216.
- Esler MD, Wallin G, Dorward PK, Eisenhofer G, Westerman R, Meredith I, Lambert G, Cox HS & Jennings G 1991 Effects of desipramine on sympathetic nerve firing and nor-epinephrine spillover to plasma in humans. *American Journal of Physiology* **260** R817–R823.
- Feldman JM 1987 Falsely elevated urinary excretion of catecholamines and metanephrines in patients receiving labetalol therapy. *Journal of Clinical Pharmacology* **27** 288–292.
- Feldman JM, Blalock JA, Zern RT & Wells SA Jr 1979 The relationship between enzyme activity and the catecholamine content and secretion of pheochromocytomas. *Journal of Clinical Endocrinology and Metabolism* **49** 445–451.
- Fernandez-Cruz L, Taura P, Saenz A, Benarroch G & Sabater L 1996 Laparoscopic approach to pheochromocytoma: hemodynamic changes and catecholamine secretion. *World Journal of Surgery* **20** 762–768.
- Fitzgerald P & Goldfren A 2004 Adrenal medulla. In *Basic and Clinical Endocrinology*, edn 7, pp 439–477. Eds FS Greenspan & DG Gardner. New York: Lange Medical Books.
- Furuta N, Kiyota H, Yoshigoe F, Hasegawa N & Ohishi Y 1999 Diagnosis of pheochromocytoma using [<sup>123</sup>I]-compared with [<sup>131</sup>I]-metaiodobenzylguanidine scintigraphy. *International Journal of Urology* **6** 119–124.
- Gagel RF, Tashjian AH, Cummings T, Papathanasopoulos N, Kaplan MM, DeLellis RA, Wolfe HJ & Reichlin S 1988 The clinical outcome of prospective screening for multiple endocrine neoplasia type 2a. An 18-year experience. *New England Journal of Medicine* **318** 478–484.
- Gagner M, Lacroix A & Bolte E 1992 Laparoscopic adrenalectomy in Cushing’s syndrome and pheochromocytoma. *New England Journal of Medicine* **327** 1033.
- Gardet V, Gatta B, Simonnet G, Tabarin A, Chene G, Ducassou D & Corcuff JB 2001 Lessons from an unpleasant surprise: a biochemical strategy for the diagnosis of pheochromocytoma. *Journal of Hypertension* **19** 1029–1035.
- Gimenez-Roqueplo AP, Lehnert H, Mannelli M, Neumann H, Opocher G, Maher ER & Plouin PF 2006 Pheochromocytoma, new genes and screening strategies. *Clinical Endocrinology* **65** 699–705.
- Glodny B, Winde G, Herwig R, Meier A, Kühle C, Cromme S & Vetter H 2001 Clinical differences between benign and malignant pheochromocytomas. *Endocrine Journal* **48** 151–159.
- Goldstein RE, O’Neill JA Jr, Holcomb GW III, Morgan WM III, Neblett WW III, Oates JA, Brown N, Nadeau J, Smith B, Page DL *et al.* 1999 Clinical experience over 48 years with pheochromocytoma. *Annals of Surgery* **229** 755–764.
- Gross MD, Shapiro B, Sisson JC & Zweifler A 1987 Clonidine-induced suppression of plasma catecholamines in states of adrenal medulla hyperfunction. *Journal of Endocrinological Investigation* **10** 359–364.
- Grossrubatscher E, Dalino P, Vignati F, Gambacorta M, Pugliese R, Boniardi M, Rossetti O, Marocchi A, Bertuzzi M & Loli P 2006 The role of chromogranin A in the management of patients with pheochromocytoma. *Clinical Endocrinology* **65** 287–293.
- Grumbach MM, Biller BM, Braunstein GD, Campbell KK, Carney JA, Godley PA, Harris EL, Lee JK, Oertel YC, Posner MC *et al.* 2003 Management of the clinically inapparent adrenal mass (‘incidentaloma’). *Archives of Internal Medicine* **138** 424–429.
- Gutmann DH, Cole JL, Stone WJ, Ponder BA & Collins FS 1994 Loss of neurofibromin in adrenal gland tumors from patients with neurofibromatosis type I. *Genes, Chromosomes and Cancer* **10** 55–58.
- Gutmann DH, Aylsworth A, Carey JC, Korf B, Marks J, Pyeritz RE, Rubenstein A & Viskochil D 1997 The diagnostic evaluation and multidisciplinary management of neurofibromatosis 1 and neurofibromatosis 2. *Journal of the American Medical Association* **278** 51–57.

- Hamilton BP, Landsberg L & Levine RJ 1978 Measurement of urinary epinephrine in screening for pheochromocytoma in multiple endocrine neoplasia type II. *American Journal of Medicine* **65** 1027–1032.
- van der Harst E, Bruining HA, Jaap Bonjer H, van der Ham F, Dinjens WN, Lamberts SW, de Herder WW, Koper JW, Stijnen T, Proye C *et al.* 2000 Proliferative index in pheochromocytomas: does it predict the occurrence of metastases? *Journal of Pathology* **191** 175–180.
- van der Harst E, de Herder WW, Bruining HA, Bonjer HJ, de Krijger RR, Lamberts SW, van de Meiracker AH, Boomsma F, Stijnen T, Krenning EP *et al.* 2001 [<sup>123</sup>I]metaiodobenzylguanidine and [<sup>111</sup>In]octreotide uptake in benign and malignant pheochromocytomas. *Journal of Clinical Endocrinology and Metabolism* **86** 685–693.
- Havekes B, Corssmit EP, Jansen JC, van der Mey AG, Vriends AH & Romijn JA 2007 Malignant paragangliomas associated with mutations in the succinate dehydrogenase D gene. *Journal of Clinical Endocrinology and Metabolism* **92** 1245–1248.
- Helman LJ, Cohen PS, Averbuch SD, Cooper MJ, Keiser HR & Israel MA 1989 Neuropeptide Y expression distinguishes malignant from benign pheochromocytoma. *Journal of Clinical Oncology* **7** 1720–1725.
- Hensen EF, Jordanova ES, van Minderhout IJ, Hogendoorn PC, Taschner PE, van der Mey AG, Devilee P & Cornelisse CJ 2004 Somatic loss of maternal chromosome 11 causes parent-of-origin-dependent inheritance in SDHD-linked paraganglioma and pheochromocytoma families. *Oncogene* **23** 4076–4083.
- Hes FJ, Hoppener JW & Lips CJ 2003 Pheochromocytoma in Von Hippel–Lindau disease. *Journal of Clinical Endocrinology and Metabolism* **88** 969–974.
- Houben K, Dardashti K & Howard BD 1994 PC12 variants deficient in norepinephrine transporter mRNA have wild type activities of several other related transporters. *Neurochemical Research* **19** 743–751.
- Houbert J, Ziegler WH, Hauri D & Jaeger P 1999 Pheochromocytomas: can malignant potential be predicted? *Urology* **53** 679–683.
- Ilias I & Pacak K 2004 Current approaches and recommended algorithm for the diagnostic localization of pheochromocytoma. *Journal of Clinical Endocrinology and Metabolism* **89** 479–491.
- Iliopoulos O, Levy AP, Jiang C, Kaelin WG Jr & Goldberg MA 1996 Negative regulation of hypoxia-inducible genes by the von Hippel–Lindau protein. *PNAS* **93** 10595–10599.
- Inabnet WB, Pitre J, Bernard D & Chapis Y 2000 Comparison of the hemodynamic parameters of open and laparoscopic adrenalectomy for pheochromocytoma. *World Journal of Surgery* **24** 574–578.
- Jimenez C, Cote G, Arnold A & Gagel RF 2006 Should patients with apparently sporadic pheochromocytomas or paragangliomas be screened for hereditary syndromes? *Journal of Clinical Endocrinology and Metabolism* **91** 2851–2858.
- Johnson MD, Smith PG, Mills E & Schanberg SM 1983 Paradoxical elevation of sympathetic activity during catecholamine infusion in rats. *Journal of Pharmacology and Experimental Therapeutics* **227** 254–259.
- Joris JL, Hamoir EE, Hartstein GM, Meurisse MR, Hubert BM, Charlier CJ & Lamy ML 1999 Hemodynamic changes and catecholamine release during laparoscopic adrenalectomy for pheochromocytoma. *Anesthesia and Analgesia* **88** 16–21.
- Kaelin WG Jr 2002 Molecular basis of the VHL hereditary cancer syndrome. *Nature Reviews. Cancer* **2** 673–682.
- Kaji P, Carrasquillo JA, Linehan WM, Chen CC, Eisenhofer G, Pinto PA, Lai EW & Pacak K 2007 The role of 6-[<sup>18</sup>F]fluorodopamine positron emission tomography in the localization of adrenal pheochromocytoma associated with von Hippel–Lindau syndrome. *European Journal of Endocrinology* **156** 483–487.
- Kalady MF, McKinlay R, Olson JA Jr, Pinheiro J, Lagoo S, Park A & Eubanks WS 2004 Laparoscopic adrenalectomy for pheochromocytoma. A comparison to aldosteronoma and incidentaloma. *Surgical Endoscopy* **18** 621–625.
- Kantorovich V & Pacak K 2005 A new concept of unopposed beta-adrenergic overstimulation in a patient with pheochromocytoma. *Annals of Internal Medicine* **142** 1026–1028.
- Kazaryan AM, Kuznetsov NS, Shulutko AM, Beltsevich DG & Edwin B 2004 Evaluation of endoscopic and traditional open approaches to pheochromocytoma. *Surgical Endoscopy* **18** 937–941.
- Khafagi FA, Shapiro B, Fischer M, Sisson JC, Hutchinson R & Beierwaltes WH 1991 Pheochromocytoma and functioning paraganglioma in childhood and adolescence: role of iodine 131 metaiodobenzylguanidine. *European Journal of Nuclear Medicine* **18** 191–198.
- Kim HH, Kim GH & Sung GT 2004 Laparoscopic adrenalectomy for pheochromocytoma: comparison with conventional open adrenalectomy. *Journal of Endourology* **18** 251–255.
- Kinney MA, Narr BJ & Warner MA 2002 Perioperative management of pheochromocytoma. *Journal of Cardiothoracic and Vascular Anesthesia* **16** 359–369.
- Koch CA, Pacak K & Chrousos GP 2002 The molecular pathogenesis of hereditary and sporadic adrenocortical and adrenomedullary tumors. *Journal of Clinical Endocrinology and Metabolism* **87** 5367–5384.
- Kopf D, Bockisch A, Steinert H, Hahn K, Beyer J, Neumann HP, Hensen J & Lehnert H 1997 Octreotide scintigraphy and catecholamine response to an octreotide challenge in malignant pheochromocytoma. *Clinical Endocrinology* **46** 39–44.
- Krenning EP, Kwekkeboom DJ, Bakker WH, Breeman WA, Kooij PP, Oei HY, van Hagen M, Postema PT, de Jong M & Reubi JC 1993 Somatostatin receptor scintigraphy with [<sup>111</sup>In-DTPA-D-Phe1]- and [<sup>123</sup>I-Tyr3]-octreotide: the Rotterdam experience with more than 1000 patients. *European Journal of Nuclear Medicine* **20** 716–731.

- Kudva YC, Young WF Jr, Thompson GB, Grant CS & van Heerden JA 1999 Adrenal incidentaloma: an important component of the clinical presentation spectrum of benign sporadic pheochromocytoma. *Endocrinologist* **9** 77–80.
- Kudva YC, Sawka AM & Young WF Jr 2003 Clinical review 164: the laboratory diagnosis of adrenal pheochromocytoma: the Mayo clinic experience. *Journal of Clinical Endocrinology and Metabolism* **88** 4533–4539.
- Lack EE 1997 *Tumors of the Adrenal Gland and Extra-Adrenal Paraganglia*, 3 edn. Washington, DC: Armed Forces Institute of Pathology.
- Langer SZ, Cavero I & Massingham R 1980 Recent developments in noradrenergic neurotransmission and its relevance to the mechanism of action of certain antihypertensive agents. *Hypertension* **2** 372–382.
- Lastoria S, Maurea S, Vergara E, Acampa W, Varrella P, Klain M, Muto P, Bernardy JD & Salvatore M 1995 Comparison of labeled MIBG and somatostatin analogs in imaging neuroendocrine tumors. *Quarterly Journal of Medicine* **39** 145–149.
- Lauriero F, Rubini G, D'Addabbo F, Rubini D, Schettini F & D'Addabbo A 1995 I-131 MIBG scintigraphy of neuroectodermal tumors. Comparison between I-131 MIBG and In-111 DTPA-octreotide. *Clinical Nuclear Medicine* **20** 243–249.
- Lehmann HU, Hochrein H, Witt E & Mies HW 1983 Hemodynamic effects of calcium antagonists. *Hypertension* **5** II66–II73.
- Lenders JW, Sluiter HE, Thien T & Willemsen J 1985 Treatment of a phaeochromocytoma of the urinary bladder with nifedipine. *BMJ* **290** 1624–1625.
- Lenders JW, Eisenhofer G, Armando I, Keiser HR, Goldstein DS & Kopin IJ 1993 Determination of metanephrines in plasma by liquid chromatography with electrochemical detection. *Clinical Chemistry* **39** 97–103.
- Lenders JW, Pacak K, Walther MM, Linehan WM, Mannelli M, Friberg P, Keiser HR, Goldstein DS & Eisenhofer G 2002 Biochemical diagnosis of pheochromocytoma: which test is best? *Journal of the American Medical Association* **287** 1427–1434.
- Lenders JW, Eisenhofer G, Mannelli M & Pacak K 2005 Pheochromocytoma. *Lancet* **366** 665–675.
- Lenders JW, Willemsen JJ, Eisenhofer G, Ross HA, Pacak K, Timmers HJ & Sweep CG 2007 Is supine rest necessary before blood sampling for plasma metanephrines? *Clinical Chemistry* **53** 352–354.
- Levine LS & DiGeorge AM 2000 Pheochromocytoma. In *Nelson Textbook of Pediatrics*, edn 16, pp 1741–1743. Eds RE Behrman, RM Kliegman & HB Jenson. Philadelphia, USA: Saunders.
- Limouris GS, Giannakopoulos V, Stavraka A, Toubanakis N & Vlahos L 1997 Comparison of In-111 pentetretotide, Tc-99m (V)DMSA and I-123 mIBG scintimaging in neural crest tumors. *Anticancer Research* **17** 1589–1592.
- Lonser RR, Glenn GM, Walther M, Chew EY, Libutti SK, Linehan WM & Oldfield EH 2003 Von Hippel–Lindau disease. *Lancet* **361** 2059–2067.
- Macho P, Perez R, Huidobro-Toro JP & Domenech RJ 1989 Neuropeptide Y(NPY): a coronary vasoconstrictor and potentiator of catecholamine-induced coronary constriction. *European Journal of Pharmacology* **167** 67–74.
- Maher ER, Iselius L, Yates JR, Littler M, Benjamin C, Harris R, Sampson J, Williams A, Ferguson-Smith MA & Morton N 1991 Von Hippel–Lindau disease: a genetic study. *Journal of Medical Genetics* **28** 443–447.
- Maher ER, Webster AR, Richards FM, Green JS, Crossey PA, Payne SJ & Moore AT 1996 Phenotypic expression in von Hippel–Lindau disease: correlations with germline VHL gene mutations. *Journal of Medical Genetics* **33** 328–332.
- Mamede M, Carrasquillo JA, Chen CC, Del Corral P, Whatley M, Ilias I, Ayala A & Pacak K 2006 Discordant localization of 2-[<sup>18</sup>F]-fluoro-2-deoxy-D-glucose in 6-[<sup>18</sup>F]-fluorodopamine- and [(123)I]-metaiodobenzylguanidine-negative metastatic pheochromocytoma sites. *Nuclear Medicine Communications* **27** 31–36.
- Mannelli M, De Feo ML, Maggi M, Pupilli C, Opocher G, Valenza T, Baldi E & Serio M 1987 Usefulness of basal catecholamine plasma levels and clonidine suppression test in the diagnosis of pheochromocytoma. *Journal of Endocrinological Investigation* **10** 377–382.
- Mariman EC, van Beersum SE, Cremers CW, Struycken PM & Ropers HH 1995 Fine mapping of a putatively imprinted gene for familial non-chromaffin paragangliomas to chromosome 11q13.1: evidence for genetic heterogeneity. *Human Genetics* **95** 56–62.
- Maurea S, Cuocolo A, Reynolds JC, Neumann RD & Salvatore M 1996 Diagnostic imaging in patients with paragangliomas. Computed tomography, magnetic resonance and MIBG scintigraphy comparison. *Quarterly Journal of Medicine* **40** 365–371.
- Mayo-Smith WW, Boland GW, Noto RB & Lee MJ 2001 State-of-the-art adrenal imaging. *Radiographics* **21** 995–1012.
- Mundschenk J & Lehnert H 1998 Malignant pheochromocytoma. *Experimental and Clinical Endocrinology and Diabetes* **106** 373–376.
- Nativ O, Grant CS, Sheps SG, O'Fallon JR, Farrow GM, van Heerden JA & Lieber MM 1992 The clinical significance of nuclear DNA ploidy pattern in 184 patients with pheochromocytoma. *Cancer* **69** 2683–2687.
- Neumann HP, Bender BU, Reincke M, Eggstein S, Laubenberg J & Kirste G 1999 Adrenal-sparing surgery for phaeochromocytoma. *British Journal of Surgery* **86** 94–97.
- Neumann HP, Bausch B, McWhinney SR, Bender BU, Gimm O, Franke G, Schipper J, Klisch J, Althoefer C, Zerres K *et al.* 2002 Germ-line mutations in nonsyndromic pheochromocytoma. *New England Journal of Medicine* **346** 1459–1466.
- Neumann HP, Pawlu C, Peczkowska M, Bausch B, McWhinney SR, Muresan M, Buchta M, Franke G, Klisch J, Bley TA *et al.* 2004 Distinct clinical features of paraganglioma syndromes associated with SDHB and SDHD gene mutations. *Journal of the American Medical Association* **292** 943–951.

- Newbould EC, Ross GA, Dacie JE, Bouloux PM, Besser GM & Grossman A 1991 The use of venous catheterization in the diagnosis and localization of bilateral pheochromocytomas. *Clinical Endocrinology* **35** 55–59.
- Newell KA, Prinz RA, Brooks MH, Glisson SN, Barbato AL & Freeark RJ 1988 Plasma catecholamine changes during excision of pheochromocytoma. *Surgery* **104** 1064–1073.
- Nielsen JT, Nielsen BV & Rehling M 1996 Location of adrenal medullary pheochromocytoma by I-123 metaiodobenzylguanidine SPECT. *Clinical Nuclear Medicine* **21** 695–699.
- O'Hare MM & Schwartz TW 1989 Expression and precursor processing of neuropeptide Y in human pheochromocytoma and neuroblastoma tumors. *Cancer Research* **49** 7010–7014.
- O'Riordain DS, Young WF, Grant CS, Carney JA & van Heerden JA 1996 Clinical spectrum and outcome of functional extraadrenal paraganglioma. *World Journal of Surgery* **20** 916–921.
- Pacak K, Eisenhofer G, Carrasquillo JA, Chen CC, Li ST & Goldstein DS 2001a 6-[18F]fluorodopamine positron emission tomographic (PET) scanning for diagnostic localization of pheochromocytoma. *Hypertension* **38** 6–8.
- Pacak K, Fojo T, Goldstein DS, Eisenhofer G, Walther MM, Linehan WM, Bachenheimer L, Abraham J & Wood BJ 2001b Radiofrequency ablation: a novel approach for treatment of metastatic pheochromocytoma. *Journal of the National Cancer Institute* **93** 648–689.
- Pacak K, Goldstein DS, Doppman JL, Shulkin BL, Udelsman R & Eisenhofer G 2001c A 'pheo' lurks: novel approaches for locating occult pheochromocytoma. *Journal of Clinical Endocrinology and Metabolism* **86** 3641–3646.
- Pacak K, Linehan WM, Eisenhofer G, Walther MM & Goldstein DS 2001d Recent advances in genetics, diagnosis, localization, and treatment of pheochromocytoma. *Annals of Internal Medicine* **134** 315–329.
- Pacak K, Eisenhofer G, Ahlman H, Bornstein SR, Gimenez-Roqueplo AP, Grossman AB, Kimura N, Mannelli M, McNicol AM & Tischler AS 2007 Pheochromocytoma: recommendations for clinical practice from the First International Symposium. *Nature Clinical Practice. Endocrinology & Metabolism* **3** 92–102.
- Perry LB & Gould AB Jr 1972 The anesthetic management of pheochromocytoma effect of preoperative adrenergic blocking drugs. *Anesthesia and Analgesia* **51** 36–40.
- Plouin PF & Gimenez-Roqueplo AP 2006 Initial work-up and long-term follow-up in patients with pheochromocytomas and paragangliomas. *Best Practice and Research. Clinical Endocrinology and Metabolism* **20** 421–434.
- Plouin PF, Degoulet P, Tugaye A, Ducrocq MB & Menard J 1981 Screening for pheochromocytoma: in which hypertensive patients? A semiological study of 2585 patients, including 11 with pheochromocytoma *La Nouvelle Presse Médicale* **10** 869–872.
- Prager G, Heinz-Peer G, Passler C, Kaczirek K, Schindl M, Scheuba C, Vierhapper H & Niederle B 2002 Can dynamic gadolinium-enhanced magnetic resonance imaging with chemical shift studies predict the status of adrenal masses? *World Journal of Surgery* **26** 958–964.
- Prys-Roberts C 2000 Pheochromocytoma – recent progress in its management. *British Journal of Anaesthesia* **85** 44–57.
- Pujol P, Bringer J, Faurous P & Jaffiol C 1995 Metastatic pheochromocytoma with a long-term response after iodine-131 metaiodobenzylguanidine therapy. *European Journal of Nuclear Medicine* **22** 382–384.
- Qiao HS, Feng XL, Yong L, Yong Z, Lian ZJ & Ling LB 2007 The MRI of extraadrenal pheochromocytoma in the abdominal cavity. *European Journal of Radiology* **62** 335–341.
- Quint LE, Glazer GM, Francis IR, Shapiro B & Chenevert TL 1987 Pheochromocytoma and paraganglioma: comparison of MR imaging with CT and I-131 MIBG scintigraphy. *Radiology* **165** 89–93.
- Raber W, Rafflesberg W, Bischof M, Scheuba C, Niederle B, Gasic S, Waldhausl W & Roden M 2000 Diagnostic efficacy of unconjugated plasma metanephrines for the detection of pheochromocytoma. *Archives of Internal Medicine* **160** 2957–2963.
- Ramachandran B, Houben K, Rozenberg YY, Haigh JR, Varpertian A & Howard BD 1993 Differential expression of transporters for norepinephrine and glutamate in wild type, variant, and WNT1-expressing PC12 cells. *Journal of Biological Chemistry* **268** 23891–23897.
- Recasens M, Oriola J, Fernández-Real JM, Roig J, Rodríguez-Hermosa JI, Font JA, Galofre P, López-Bermejo A & Ricart W 2007 Asymptomatic bilateral adrenal pheochromocytoma in a patient with a germline V804M mutation in the RET proto-oncogene. *Clinical Endocrinology* **67** 29–33.
- Reisch N, Peczkowska M, Januszewicz A & Neumann HP 2006 Pheochromocytoma: presentation, diagnosis and treatment. *Journal of Hypertension* **24** 331–339.
- Riccardi VM 1981 Von Recklinghausen neurofibromatosis. *New England Journal of Medicine* **305** 1617–1627.
- Rosano TG, Swift TA & Hayes LW 1991 Advances in catecholamine and metabolite measurements for diagnosis of pheochromocytoma. *Clinical Chemistry* **37** 1854–1867.
- Rose B, Matthay KK, Price D, Huberty J, Klencke B, Norton JA & Fitzgerald PA 2003 High-dose 131I-metaiodobenzylguanidine therapy for 12 patients with malignant pheochromocytoma. *Cancer* **98** 239–248.
- Ross EJ, Prichard BN, Kaufman L, Robertson AI & Harries BJ 1967 Preoperative and operative management of patients with pheochromocytoma. *BMJ* **1** 191–198.
- Salmenkivi K, Arola J, Voutilainen R, Ilvesmaki V, Haglund C, Kahri AI, Heikkila P & Liu J 2001 Inhibin/activin betaB-subunit expression in pheochromocytomas favors benign diagnosis. *Journal of Clinical Endocrinology and Metabolism* **86** 2231–2235.
- Salmenkivi K, Heikkila P, Haglund C & Arola J 2004 Malignancy in pheochromocytomas. *Acta Pathologica, Microbiologica, et Immunologica Scandinavica* **112** 551–559.



- Sawka AM, Jaeschke R, Singh RJ & Young WF Jr 2003 A comparison of biochemical tests for pheochromocytoma: measurement of fractionated plasma metanephrines compared with the combination of 24-hour urinary metanephrines and catecholamines. *Journal of Clinical Endocrinology and Metabolism* **88** 553–558.
- Schiavi F, Boedeker CC, Bausch B, Peczkowska M, Gomez CF, Strassburg T, Pawlu C, Buchta M, Salzmann M, Hoffmann MM *et al.* 2005 Predictors and prevalence of paraganglioma syndrome associated with mutations of the SDHC gene. *Journal of the American Medical Association* **294** 2057–2063.
- Scholz T, Eisenhofer G, Pacak K, Dralle H & Lehnert H 2007 Current treatment of malignant pheochromocytoma. *Journal of Clinical Endocrinology and Metabolism* **92** 1217–1225.
- Schussheim DH, Skarulis MC, Agarwal SK, Simonds WF, Burns AL, Spiegel AM & Marx SJ 2001 Multiple endocrine neoplasia type 1: new clinical and basic findings. *Trends in Endocrinology and Metabolism* **12** 173–178.
- deS Senanayake P, Denker J, Bravo EL & Graham RM 1995 Production, characterization, and expression of neuro-peptide Y by human pheochromocytoma. *Journal of Clinical Investigation* **96** 2503–2509.
- Serfas D, Shoback DM & Lorell BH 1983 Pheochromocytoma and hypertrophic cardiomyopathy: apparent suppression of symptoms and noradrenaline secretion by calcium-channel blockade. *Lancet* **2** 711–713.
- Shapiro B, Gross MD & Shulkin B 2001 Radioisotope diagnosis and therapy of malignant pheochromocytoma. *Trends in Endocrinology and Metabolism* **12** 469–475.
- Shin MS, Gupta KL & Ho KJ 1986 Thoracic pheochromocytoma: computerized tomographic characteristics. *Southern Medical Journal* **79** 244–245.
- Shulkin BL, Wieland DM, Schwaiger M, Thompson NW, Francis IR, Haka MS, Rosenspire KC, Shapiro B, Sisson JC & Kuhl DE 1992 PET scanning with hydroxyephedrine: an approach to the localization of pheochromocytoma. *Journal of Nuclear Medicine* **33** 1125–1131.
- Shulkin BL, Thompson NW, Shapiro B, Francis IR & Sisson JC 1999 Pheochromocytomas: imaging with 2-[fluorine-18]fluoro-2-deoxy-D-glucose PET. *Radiology* **212** 35–41.
- Sibal L, Jovanovic A, Agarwal SC, Peaston RT, James RA, Lennard TW, Bliss R, Batchelor A & Perros P 2006 Pheochromocytomas presenting as acute crises after beta blockade therapy. *Clinical Endocrinology* **65** 186–190.
- Sisson JC 2002 Radiopharmaceutical treatment of pheochromocytomas. *Annals of the New York Academy of Sciences* **970** 54–60.
- Sloand EM & Thompson BT 1984 Propranolol-induced pulmonary edema and shock in a patient with pheochromocytoma. *Archives of Internal Medicine* **144** 173–174.
- Smythe GA, Edwards G, Graham P & Lazarus L 1992 Biochemical diagnosis of pheochromocytoma by simultaneous measurement of urinary excretion of epinephrine and norepinephrine. *Clinical Chemistry* **38** 486–492.
- Sohaib SAA, Bomanji J, Evanson J & Renzek RH 2001 Imaging of the endocrine system. In *Diagnostic Radiology: a Textbook of Medical Imaging*, edn 4, pp 1367–1399. Eds R Grainger, D Allison, A Adam & A Dixon. London: Churchill Livingstone.
- Sprung J, O'Hara JF Jr, Gill IS, Abdelmalak B, Sarnaik A & Bravo EL 2000 Anesthetic aspects of laparoscopic and open adrenalectomy for pheochromocytoma. *Urology* **55** 339–343.
- Steinsapir J, Carr AA, Prisant LM & Bransome ED Jr 1997 Metyrosine and pheochromocytoma. *Archives of Internal Medicine* **157** 901–906.
- Sutton MG, Sheps SG & Lie JT 1981 Prevalence of clinically unsuspected pheochromocytoma. Review of a 50-year autopsy series. *Mayo Clinic Proceedings* **56** 354–360.
- Takahashi S, Nakai T, Fujiwara R, Kutsumi Y, Tamai T & Miyabo S 1989 Effectiveness of long-acting nifedipine in pheochromocytoma. *Japanese Heart Journal* **30** 751–757.
- Tauzin-Fin P, Sesay M, Gosse P & Ballanger P 2004 Effects of perioperative alpha1 block on haemodynamic control during laparoscopic surgery for pheochromocytoma. *British Journal of Anaesthesia* **92** 512–517.
- Tenenbaum F, Lumbroso J, Schlumberger M, Mure A, Plouin PF, Caillou B & Parmentier C 1995 Comparison of radiolabeled octreotide and meta-iodobenzylguanidine (MIBG) scintigraphy in malignant pheochromocytoma. *Journal of Nuclear Medicine* **36** 1–6.
- Thompson LD 2002 Pheochromocytoma of the adrenal gland scaled score (PASS) to separate benign from malignant neoplasms: a clinicopathologic and immunophenotypic study of 100 cases. *American Journal of Surgical Pathology* **26** 551–566.
- Thompson GB & Young WF Jr 2003 Adrenal incidentaloma. *Current Opinion in Oncology* **15** 84–90.
- Timmers HJ, Kozupa A, Chen CC, Carrasquillo JA, Ling A, Eisenhofer G, Adams KT, Solis D, Lenders JW & Pacak K 2007a Superiority of fluorodeoxyglucose positron emission tomography to other functional imaging techniques in the evaluation of metastatic SDHB-associated pheochromocytoma and paraganglioma. *Journal of Clinical Oncology* **25** 2262–2269.
- Timmers HJ, Kozupa A, Eisenhofer G, Raygada M, Adams KT, Solis D, Lenders JW & Pacak K 2007b Clinical presentations, biochemical phenotypes, and genotype–phenotype correlations in patients with succinate dehydrogenase subunit B-associated pheochromocytomas and paragangliomas. *Journal of Clinical Endocrinology and Metabolism* **92** 779–786.
- Ulchaker JC, Goldfarb DA, Bravo EL & Novick AC 1999 Successful outcomes in pheochromocytoma surgery in the modern era. *Journal of Urology* **161** 764–767.
- Václavík J, Stejskal D, Lačňák B, Lazárová M, Jedelský L, Kadalová L, Janošová M, Fryšák Z & Vlček P 2007 Free plasma metanephrines as a screening test for pheochromocytoma in low-risk patients. *Journal of Hypertension* **25** 1427–1431.
- Varghese JC, Hahn PF, Papanicolaou N, Mayo-Smith WW, Gaa JA & Lee MJ 1997 MR differentiation of

- phaeochromocytoma from other adrenal lesions based on qualitative analysis of T2 relaxation times. *Clinical Radiology* **52** 603–606.
- Veith RC, Lewis N, Linares OA, Barnes RF, Raskind MA, Villacres EC, Murburg MM, Ashleigh EA, Castillo S & Peskind ER 1994 Sympathetic nervous system activity in major depression. Basal and desipramine-induced alterations in plasma norepinephrine kinetics. *Archives of General Psychiatry* **51** 411–422.
- Walther MM, Herring J, Enquist E, Keiser HR & Linehan WM 1999a Von Recklinghausen's disease and pheochromocytomas. *Journal of Urology* **162** 1582–1586.
- Walther MM, Reiter R, Keiser HR, Choyke PL, Venzon D, Hurley K, Gnarr JR, Reynolds JC, Glenn GM, Zbar B et al. 1999b Clinical and genetic characterization of pheochromocytoma in von Hippel–Lindau families: comparison with sporadic pheochromocytoma gives insight into natural history of pheochromocytoma. *Journal of Urology* **162** 659–664.
- Wark JD & Larkins RG 1978 Pulmonary oedema after propranolol therapy in two cases of phaeochromocytoma. *BMJ* **1** 1395–1396.
- Weismann D, Fassnacht M, Weinberger F, Hamelmann W, Diehl S, Lorenz K, Baerlechner E, Reincke M, Beuschlein F, Knoefel W et al. 2006 Intraoperative haemodynamic stability in patients with phaeochromocytoma – minimally invasive vs conventional open surgery. *Clinical Endocrinology* **65** 352–358.
- Wenzel RR, Allegranza G, Binggeli C, Shaw S, Weidmann P, Luscher TF & Noll G 1997 Differential activation of cardiac and peripheral sympathetic nervous system by nifedipine: role of pharmacokinetics. *Journal of the American College of Cardiology* **29** 1607–1614.
- Whalen RK, Althausen AF & Daniels GH 1992 Extra-adrenal pheochromocytoma. *Journal of Urology* **147** 1–10.
- Wittles RM, Kaplan EL & Roizen MF 2000 Sensitivity of diagnostic and localization tests for pheochromocytoma in clinical practice. *Archives of Internal Medicine* **160** 2521–2524.
- World Health Organization 2004 WHO classification of tumors 2004. In *Pathology and Genetics of Tumors of Endocrine Organs*, Eds RA De Lellis, RV Lloyd, PV Heitz & C Eng. France: IARC Press.
- Yip L, Cote GJ, Shapiro SE, Ayers GD, Herzog CE, Sellin RV, Sherman SI, Gagel RF, Lee JE & Evans DB 2003 Multiple endocrine neoplasia type 2: evaluation of the genotype-phenotype relationship. *Archives of Surgery* **138** 409–416.
- Young WF Jr 1997 Pheochromocytoma: issues in diagnosis & treatment. *Comprehensive Therapy* **23** 319–326.
- Young WF 2007 Clinical practice. The incidentally discovered adrenal mass. *New England Journal of Medicine* **356** 601–610.
- Young WF Jr & Abboud AL 2006 Editorial: paraganglioma – all in the family. *Journal of Clinical Endocrinology and Metabolism* **91** 790–792.
- Zoller ME, Rembeck B, Oden A, Samuelsson M & Angervall L 1997 Malignant and benign tumors in patients with neurofibromatosis type 1 in a defined Swedish population. *Cancer* **79** 2125–2131.