Case Report

Anterior interosseous nerve palsy following the use of elbow crutches

Feiran Wu, MA (Cantab)., MB., BChir., MRCS., Adil Ismaeel, MB., BS., MRCS., Rehan Siddiqi, MB., BS., FRCS.

Department of Orthopaedics
Central Manchester University Hospitals NHS Foundation Trust, Oxford Road, Manchester M13 9WL, United Kingdom.

Citation: Wu F, Ismaeel A, Siddiqi R. Anterior interosseous nerve palsy following the use of elbow crutches. **North Am J Med Sci** 2011; 3: 296-298. **doi**: 10.4297/najms.2011.3296

Abstract

Context: Lesions of the anterior interosseous nerve are rare and comprise less than 1% of all upper extremity nerve palsies. Traumatic causes include blunt trauma, forearm fractures, penetrating injury and local pressure from a plaster cast, but has never before been described in association with crutch use. This is the first reported case of the use of elbow crutches causing symptomatic anterior interosseous nerve compression. **Case Report:** This case describes a 30-year-old male who developed an inability to pinch with his left hand following the use of elbow crutches for a foot injury. On examination he was unable to flex the interphalangeal joint of his left thumb. A diagnosis of anterior interosseous palsy was made and the patient was treated conservatively and crutch use was ceased. At six weeks follow-up the patient made a complete recovery with full function of his left hand. **Conclusion:** This report highlights the importance of adequate education in the safe use of elbow crutches for all patients. The side effects of inappropriate use should be carefully examined for during follow-up care.

Keywords: Anterior interosseous nerve palsy, crutch palsy, compression neuropathy, flexor digitorum profundus (FDP), flexor digitorum superficialis (FDS), flexor pollicis longus (FPL).

Correspondence to: Mr. Feiran Wu, Department of Orthopaedics, Central Manchester University Hospitals NHS Foundation Trust, Oxford Road, Manchester M13 9WL, UK. Email:feiran.wu@gmail.com

Introduction

Lesions of the anterior interosseous nerve [AIN] are rare and comprise less than 1% of upper limb palsies [1]. It is an exclusively motor branch of the median nerve and provides innervation to flexor pollicis longus, the medial part of flexor digitorum profundus involving the index and sometimes the middle finger, and to pronator quadratus. Entrapment of the nerve results in a characteristic appearance on pinching, which may be mistaken for a tendon rupture [2]. We present a case of a patient who developed AIN palsy following the use of elbow crutches.

Case Report

A 30-year-old fit and healthy male presented to fracture clinic four days after suffering a stubbing injury to his left big toe and superficial abrasion to his left heel. He attended casualty on the day of the injury where the wounds were dressed. X-rays reviewed an undisplaced fracture of the base of the left little toe distal phalanx. He was given elbow crutches with instructions for partial weight bearing on the affected leg and discharged with a fracture clinic appointment.

In clinic, the patient complained of a gradual onset of difficulty in pinching and gripping objects with his left hand since the injury. He denied pain or recent trauma to this limb. On examination, the patient was unable to flex the interphalangeal joint of the left thumb. [Figures 1 and 2] Movements of the left index and middle fingers were normal and there were no areas of paraesthesia. Since there was no history of trauma or predisposing conditions, we believe the patient developed an anterior interosseous nerve palsy following the inappropriate use of elbow crutches over four days. He was subsequently placed in a plaster cast boot and was advised to fully weight bear without the use of crutches. The patient failed to attend two nerve conduction study appointments. However, by

the time he came to a six-week follow-up clinic after the injury, he had made a complete clinical recovery in hand movement and function. The patient was subsequently lost to further follow-up.

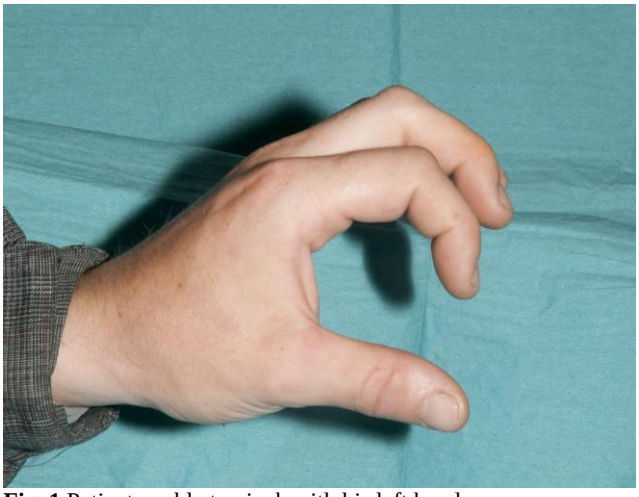

Fig. 1 Patient unable to pinch with his left hand.

Fig. 2 Patient unable to flex interphalangeal joint of the thumb.

Discussion

Lesions of AIN was first described by Parsonage and Turner in 1948 [3]. Many causes for AIN palsy have subsequently been described in literature, and can be divided into traumatic and non-traumatic / spontaneous. Spontaneous causes include entrapment neuropathy, neuralgic amyotrophy and isolated neuritis. Traumatic causes range from blunt trauma, local pressure from sleeping on the affected arm or poorly applied cast, excessive exercise, penetrating injury, forearm fractures and open reduction and internal fixation [2, 4]. To our knowledge there are no reports of elbow crutches causing symptomatic AIN compression.

AIN palsy can be described as complete, where flexor digitorum profundus and flexor pollicis longus are both affected, or incomplete, where only one muscle is affected. It differs from other lesions of the median nerve in that sensory complaints are essentially absent. As a result of these factors, AIN palsy can often mimic single tendon lesions, leading to difficulties with diagnosis. In the literature, there are cases of AIN entrapment with unnecessary surgical exploration of FPL tendon [5, 6]. The classical symptom is an inability to form an 'O' with the thumb and index finger, and the loss of ability to perform fine tasks despite an intact sensory innervation. Weakness of the pronator quadratus muscle is generally unnoticed [1].

Spontaneous ruptures of flexor pollicis longus tendon are rare and are generally associated with distinct underlying pathologies, such as rheumatoid arthritis. The patient usually hears a snap or feels pain as the tendon yields [7]. Several clinical tests have been described to distinguish between palsy of FPL and rupture of this tendon [8-10].

Electrodiagnosis with nerve-conduction study or electromyography is the investigation of choice to differentiate between nerve palsy and tendon rupture [2]. In the present case, however, the patient made a full recovery before electrodiagnostic studies could be carried out, thereby ruling out the possibility of rupture of flexor pollicis longus.

Treatment of AIN palsy is related to the specific disease aetiology. Conservative management includes removal of precipitating causes such as crutches and casts, immobilisation and anti-inflammatory medication. Surgical exploration is generally only necessary after a period of conservative management has failed [2, 11].

Conclusion

We believe all patient should be taught safe and effective usage of elbow crutches when they initially receive them. The side effects of inappropriate use should be carefully examined for during follow-up care.

References

1. Nigst H, Dick W. Syndromes of compression of the median nerve in the proximal forearm (pronator teres syndrome; anterior interosseous nerve syndrome). Arch Orthop Trauma Surg 1979; 93(4):307-312.
2. Seror P. Anterior interosseous nerve lesions. Clinical and electrophysiological features. J Bone Joint Surg Br 1996;78(2):238-241.
3. Parsonage MJ, Turner JWA. Neuralgic amyotrophy; the shoulder-girdle syndrome. Lancet 1948; 1(6513): 973-978.
4. Nagano A. Spontaneous anterior interosseous nerve palsy. J Bone Joint Surg Br 2003;85(3):313-318.
5. Hill NA, Howard FM, Huffer BR. The incomplete anterior interosseous nerve syndrome. J Hand Surg Am 1985;10(1):4-16.
6. Joist A, Probst A, Böhm A, Sprakel B, Joosten U. Differential anterior interosseous nerve syndrome diagnosis. Nervenarzt 1998;69(4):335-337.
7. Imai S, Kubo M, Kikuchi K, Ueba H, Matsusue Y.

Spontaneous rupture of the flexor digitorum profundus and superficialis of the index finger and the flexor pollicis longus without labor-associated tendon loading. J Hand Surg Am 2004; 29(4): 587-590.

8. O'Neill DB, Zarins B, Gelberman RH, Keating TM, Louis D. Compression of the anterior interosseous nerve after use of a sling for dislocation of the acromioclavicular joint. A report of two cases. J Bone Joint Surg Am 1990;72(7):1100-1102.
9. Mody BS. A simple clinical test to differentiate rupture of flexor pollicis longus and incomplete anterior interosseous paralysis. J Hand Surg Br. 1992;17(5):513-514.
10. Melton JTK, Murray JRD, Lowdon IMR. A simple clinical test of flexor pollicis longus rupture. J Hand Surg Br 2005;30(6):624-625.
11. Werner CO. The anterior interosseous nerve syndrome. Int Orthop 1989;13(3):193-197.