

Asymmetries of visual attention after circumscribed subcortical vascular lesions

B Fimm, R Zahn, M Mull, S Kemeny, F Buchwald, F Block, M Schwarz

Abstract

Objective—To investigate the role of the basal ganglia and the thalamus for basic processes of visuospatial attention

Methods—Fifteen patients with acute circumscribed vascular lesions (10 with haemorrhage and five with infarction) were included in the study. The lesions were confined exclusively to subcortical structures, such as the basal ganglia, internal capsule, and thalamus, which was confirmed by initial CT on the day of referral and MRI taken 14–28 days after clinical onset. These patients were examined with two computerised attentional tasks (one detection and one search task) measuring spatial visual attention.

Results—There was a clear attentional asymmetry in patients with right hemispheric lesions (RHLs) in the visual search task. Seven out of eight patients with RHLs tended to be slower and/or missed significantly more target stimuli in the left sided part of a stimulus array consisting of 25 small squares than in right sided parts, although none of these patients showed signs of visual hemineglect in the visual detection task presenting visual information simultaneously to the right and left visual hemispace. All but one of these patients showed lesions in the posterior limb of the internal capsule and the putamen. On the other hand, patients with left hemispheric lesions were not impaired in the search task with only one patient showing more contralesional omissions of target stimuli than could be expected from the behaviour of normal controls.

Conclusions—The results are in line with previous results showing a dominant role of right hemispheric neuronal structures for spatial attention. Furthermore, the data suggest that even with right hemispheric subcortical lesions without cortical involvement deficits in spatial orienting of attention to the left hemispace can be seen. These asymmetries of visual attention in the absence of neglect symptoms are supposed to be caused (1) by a disruption of the motor corticostriato-pallidothalamo-cortical neuronal circuit or (2) by a (partial) disconnection of relevant parts within the posterior attention network—namely, parietal and thalamic structures.

(J Neurol Neurosurg Psychiatry 2001;71:652-657)

Keywords: spatial attention; visual search; basal ganglia

Attention deficits are among the most frequent neuropsychological consequences of brain injury. These deficits are heterogenous, covering impairments of alertness, sustained attention, divided attention, and selective attention. Case studies and recent developments in neuroimaging confirmed a special role of frontal and parietal cortical areas of the right hemisphere for intensity aspects of attention such as alertness and sustained attention as well as visuospatial attention.¹⁻⁴ Apart from these left-right differences, Posner *et al*⁵ suggested anterior and posterior attentional networks with the posterior parts (superior parietal cortex, superior colliculus, pulvinar nucleus) subserving visuospatial attention and an anterior network (with the anterior portion of the cingulate gyrus as the main structure) being mainly involved in the selection of stimuli and executive processes. With the exception of some midbrain structures and the pulvinar nucleus of the thalamus, no other subcortical structures are explicitly claimed to participate in attentional processes.

However, evidence from the animal literature suggests a potential role of the basal ganglia in spatial attention. Unilateral destruction of dopaminergic terminals in the striatum of rats by application of 6-OHDA resulted in orienting reactions to the ipsilesional side and increased time to initiate contralateral responses.^{7,8} Similar impairments in patients with Parkinson's disease were reported by Ebersbach *et al*.⁹ They found a spontaneous tendency of hemiparkinsonian patients to explore the visual field ipsilesional to the supposed main locus of dopaminergic striatal depletion. Caplan *et al*¹⁰ reported neuropsychological deficits in a sample of 18 patients with caudate nucleus infarcts with three patients (each of them with right caudate and internal capsule lesions) showing contralesional neglect. Similar results were described by Giroud *et al*¹¹ in two patients with putaminal infarcts. Unfortunately, the hemineglect syndrome was not quantified by means of standardised procedures in either study. However, Ferro *et al*¹² could show trimodal, visual, or auditory extinction in patients with right striatocapsular infarcts including the caudate and lenticular nuclei and the posterior limb of the internal capsule.

In their comprehensive review of the literature on neuropsychological disorders after subcortical lesions Cappa and Vallar concluded that besides the inferoposterior parietal cortex, thalamic nuclei such as the pulvinar nucleus contribute to visuospatial attention.¹³ The associations between lesions in the basal

Neurologische Klinik,
Universitätsklinikum
Aachen, Pauwelsstraße
30, 52074 Aachen,
Germany
B Fimm
R Zahn
F Buchwald
F Block

Klinik für
Radiologische
Diagnostik,
Neuroradiologie
M Mull
S Kemeny

Neurologische Klinik
Dortmund,
Beurhausstraße 40,
44137 Dortmund,
Germany
M Schwarz

Correspondence to:
Dr B Fimm
fimm@
neuropsych.rwth-aachen.de

Received 22 December 2000
and in revised form
11 May 2001
Accepted 6 July 2001

Table 1 Clinical and demographic variables of the patients

Patient	Age	Sex	Aetiology	Side of the lesion	Vol (cm ³)	CN	PUT	GB	Thalamus	Int caps	Ext caps	White matter
P01	73	M	H	L	0.5	—	—	—	X	Post	—	Paraventr
P02	58	F	H	L	8.0	—	—	—	X	Post	—	Paraventr
P03	79	F	H	L	6.0	—	—	—	Dorsomed	—	—	—
P04	41	M	H	R	63.8	—	X	X	X	Post	X	Right frontal
P05	55	F	H	R	15.0	—	X	—	—	Post	—	—
P06	68	M	H	R	50.0	—	Post	Post	Postlat	Post last 1/3	X	—
P07	50	M	H	L	3.8	—	X	X	Antlat	Post	—	Paraventr
P08	49	M	I	R	11.3	—	X	X	—	—	—	Paraventr
P09	46	F	H	R	6.5	—	—	—	dorsolat	post	—	paraventr
P10	29	M	H	R	1.1	Head	X	—	—	—	—	—
P11	45	F	I	R	2.5	Body	X	—	—	Post	—	Paraventr
P12	36	F	I	L	3.5	—	—	—	Ventrolat	Post	—	—
P13	67	M	I	R	6.1	Body	X	X	—	Ant	—	Paraventr
P14	37	M	H	L	.5	Postbody	Dorsolat	—	—	—	—	—
P15	74	M	I	L	12.0	—	—	—	Post	Post	X	Paraventr

H=Haemorrhage; I=infarction; L=left; R=right; X=lesion; CN=caudate nucleus; PUT=putamen; GB=globus pallidus; Int caps=internal capsule; Ext caps=external capsule; ant=anterior; post=posterior; paraventr=paraventricular; lat=lateral.

Bold lines represent patients with right sided lesion and visual attentional deficit with respect to the left hemisphere.

ganglia and neglect were suggested to be less close. One criticism of these studies concerns the heavy reliance on CT data as MR is able to show additional cortical lesions in apparently pure subcortical damage as judged by CT.¹⁴

Furthermore, the studies mainly focused on the neglect syndrome disregarding symptoms of attentional asymmetries that cannot, with respect to their extent, be conceived as complete inattention of one half of the extrapersonal space but as an impairment or slowing in processing information presented on one side of the extrapersonal space. Such attentional asymmetries, which did not reach the level of impairment such as found in visual hemineglect, have been occasionally reported.^{15–18}

To specify the functional role of the thalamus and the basal ganglia in selective visual attention, we investigated patients with circumscribed subcortical vascular lesions and applied several computerised tasks proved to be sensitive measures of visual attention asymmetries even in cases of recovered or only minor hemineglect.^{15–19}

Methods

Fifteen patients with circumscribed subcortical vascular lesions (10 with haemorrhage—five left sided and five right sided; five with infarction—two left sided and three right sided) were examined 2 to 3 weeks after stroke. The lesions were confined to subcortical structures exclusively, such as the basal ganglia, internal capsule, and thalamus as judged by an initial CT on the day of referral and MRI taken 14–28 days after clinical onset. There was no cortical involvement and no diffuse white matter lesions as judged by MRI. Brain CT was made in axial slice orientation in parallel to the orbitomeatal line with a slice thickness of 8 mm in the supratentorial and 4 mm in the infratentorial parts of the brain. The CT scanner used was a Somatom DRH (Siemens). Brain MRI was performed on a Siemens Magnetom with 1.5 Tesla using axial T1 and T2 weighted images. In addition a T1 coronal three dimensional data set was acquired in six patients. The volume of the lesions was defined by applying the approximative formula $\text{height} \times \text{length} \times \text{width} / 2$ (see Niizuma *et al*²⁰ and Kothari *et al*²¹). For haemorrhages this was

based on the initial CT on the day of referral and for infarctions T2 weighted MRI was used.

Table 1 gives an overview on demographic and clinical data of the patients. None of the patients showed clinically clear signs of visual hemineglect.

NEUROPSYCHOLOGICAL MEASUREMENT

Two computerised subtests of the test for attentional performance²² were used to measure basic aspects of spatial attention.

Neglect

In this test, subjects have to fixate a central square within which a sequence of randomly changing single letters (zero to two changes/trial) is displayed with the patient having to respond to each change by orally naming the new letter. This task was used to ensure central fixation of the patient at the beginning of each trial. In addition, the display is permanently filled with randomly located three digit numbers that provide simultaneous visual stimulation in both hemifields during the whole task. Within the gaps between these three digit numbers a peripheral three digit target appears in random locations in either left or right visual field within 13 degrees of the central square. During its presentation, the three digit target is randomly changing its value, thus appearing to flicker slightly. The target onset occurs between 1500–6000 ms after trial onset and the target is presented for a maximum of 3 seconds. Twelve targets are presented in each quadrant, giving a total of 48 targets. Subjects have to respond as quickly as possible to the onset of the target by pressing a button with the right hand. Relevant dependent variables were median reaction time for targets in the left or in the right visual field as well as omissions. Furthermore the difference in reaction time between left and right visual hemifield was of special interest. Sturm and Willmes²³ could demonstrate a high sensitivity of this task for neglect symptoms and a high correspondance with cancellation performance in a single case with neglect. Furthermore, the improvement of neglect symptoms as a result of alertness therapy could be similarly measured both with cancellation tasks and with this neglect task.




Figure 1 Sample stimulus display of the visual scanning task. The square with the open upper side has to be detected.

Visual scanning

This task investigates the capacity of active scanning of the visual field. A target pattern, a square opened on the upper side, has to be detected in a 5×5 arrangement of squares with

openings on other sides (an example is shown in fig 1). The patients were asked to press the left out of two horizontally arranged buttons with the left hand as soon as they had found the target, and they had to press the right button by using their right hand in cases when no target was present within the 25 squares. They were instructed to use a fixed search strategy—that is, searching line by line, from left to right as if they were reading. Among the 100 trials of the task, 50 contained a target with 10 targets per line and per row of the stimulus arrangement. The time needed to scan the whole stimulus arrangement, the time to find targets in the different columns of the arrangement, the number of omissions in the different columns, and a measure of search strategy (correlation between reaction time and stimulus position after “numbering” the positions line by line from left to right) were obtained. In addition, variables indicating attentional asymmetry were introduced—namely, the difference in reaction time or omissions between the far left and the far right column.

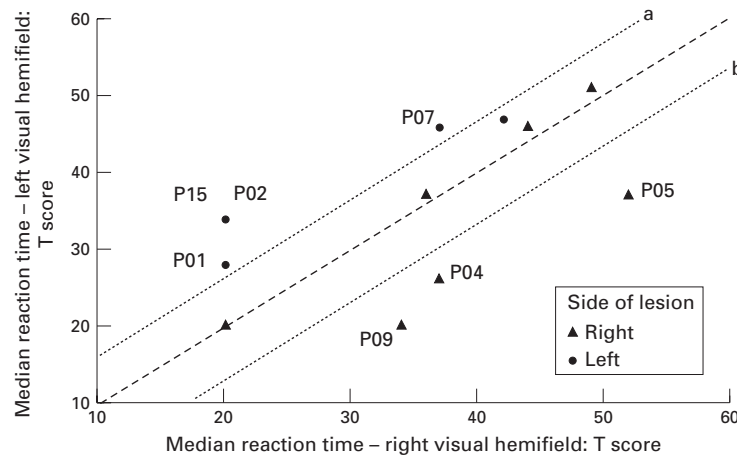


Figure 2 Neglect task: age corrected T scores of the median reaction times to targets in the right and left visual hemifield. The space between the two lines a and b denotes patients without any significant asymmetries between the visual hemifields. Five patients showed identical T score combinations (T score left/T score right: 3×20/20 and 2×20/34). The identities of patients with significant asymmetries between both hemifields are displayed.

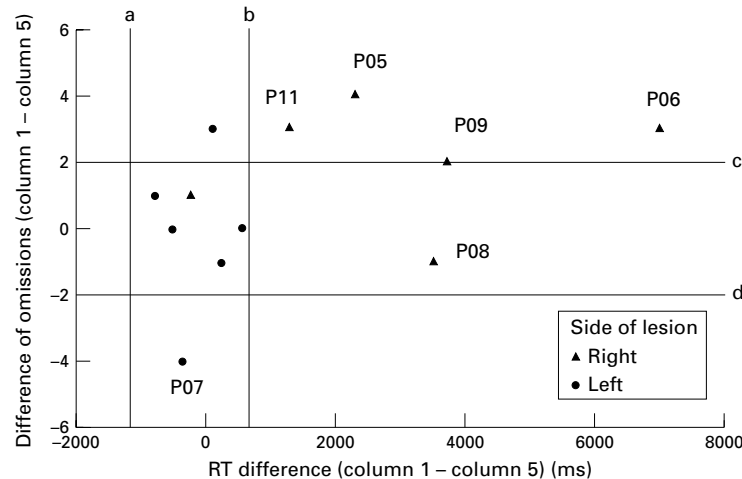


Figure 3 Visual scanning task: left-right differences (column 1 minus 5 of the stimulus arrangement) in reaction time and omissions. The space between the two vertical (a and b) and horizontal (c and d) lines respectively denotes the performance of 80% of normal controls. The identities of patients with attentional asymmetries between both hemifields are shown. Two additional patients with RHL missing at least 9 out of 10 target stimuli in the far left column (P04, P13) and one additional patient with LHL with nine omissions in the far right column (P12) are not displayed as a computation of respective times was not possible.

DATA ANALYSIS

The data were analyzed using SPSS for Windows version 8.0. The rationale of the study was to use standardised values. Because the experimental tasks used had been standardised on the basis of 200 normal controls, T scores for the different parameters could be computed for each patient, thus allowing the classification of the patient's performance as clearly impaired (on the basis of percentile rank 10 or $T < 37$) or not. The distribution of the patients with respect to impairment (yes/no) and lesion side (left/right) was analyzed for several test parameters by using χ^2 statistics. The patients' lesions documented with CT and MRI were visualised using computer software²⁴ developed in our functional imaging laboratory; the resulting picture shows a spatial overlay of the lesions superimposed on normalised MRI. Within the overlay darker shades of grey represent an increasing overlap of the individual lesions and identify the commonly affected cerebral structures.

Results

NEGLECT TASK

A clear right-left difference emerged in the neglect task. As illustrated in figure 2, patients with right sided lesions (RHL) showed (1) no difference between the hemifields or (2) lowered performance with respect to stimuli in the left hemifield and patients with left sided lesions (LHL) did the opposite. Patients displayed outside the area between lines a and b in figure 2 showed significant ($p < 0.05$) asymmetries between the hemifields; four patients with left sided lesions (patients P01, P02, P07, and P15) and three patients (P09, P04, and P05) with significant slowing concerning contralesional stimuli. All patients with LHL had exclusive or predominant thalamic lesions; this also held true for two out of the three patients with RHL. These results suggest that the processing of contralesional visual stimuli when there are

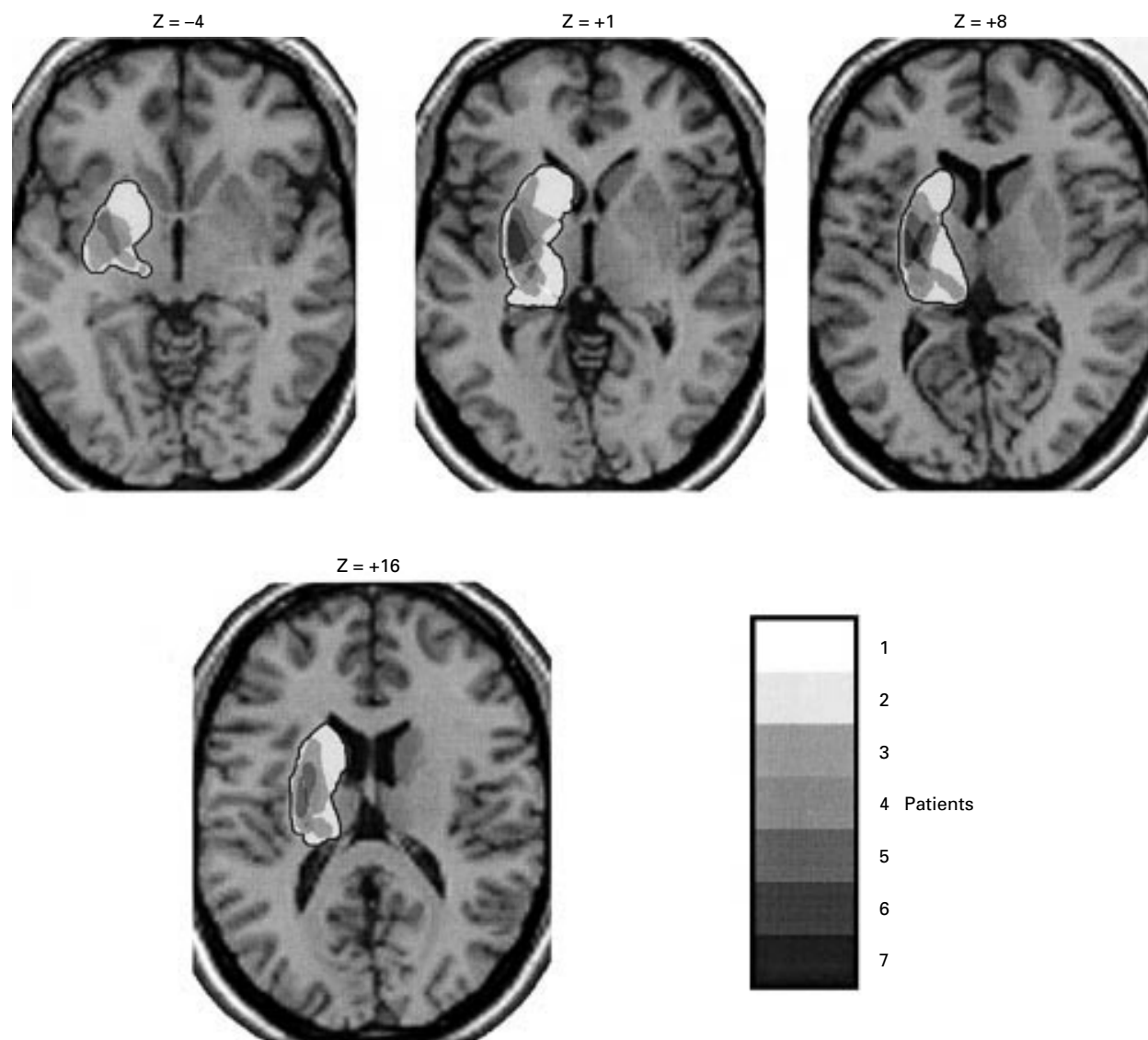


Figure 4 Patients with visual attentional asymmetry to the left hemifield—superposition of the individual lesions. We used a self developed computer program to transform the lesion data to Talairach normalised space and to superimpose the individual lesions on T1 weighted normalised transversal MRI (MNI template, SPM99 software package). The levels of increasing overlap were depicted in darker shades of grey. Transversal slices with the overlaid lesions were generated only at basal ganglia level (Talairach Z coordinates -4 , $+1$, $+8$, $+16$).

no eye movements involved seems to be impaired after thalamic lesions.

VISUAL SCANNING

In this task attentional asymmetries were defined by computing the difference between (a) median reaction times with target stimuli in the far left and the far right column of the stimulus arrangement ($Rt_{left} - Rt_{right}$) and (b) the number of omissions (maximum 10) of these two columns ($om_{left} - om_{right}$). These new parameters are displayed in figure 3.

The space between the two vertical lines denotes the performance of 80% of normal controls concerning Rt_{diff} , the two horizontal stripes show the analogue situation with respect to Om_{diff} . As can easily be detected, five out of six patients with RHL (P05, P06, P08, P09, and P11) showed attentional asymmetries in the sense of impaired processing of contralesional visual information. Two additional patients with RHL missing at least nine out of 10 target stimuli in the far left column are not

displayed as a computation of respective reaction times was not possible (P04, P13). Thus, seven out of eight patients with RHL were impaired in the processing of contralesional visual information. One additional patient with LHL (P12) with four omissions in the far left and nine omissions in the far right column is also not shown in figure 3. Consequently, only two patients with LHL could be considered as having contralesional attentional asymmetries (P07 and P12).

This was not an effect of global impairment in visual scanning, eye movement, or selective attention as a comparison (Mann-Whitney *U* test) of patients with RHL and those with LHL with respect to their T scores of their total search time of the whole stimulus arrangement and their omissions did not yield any significant differences.

The association between side of lesion and occurrence of contralesional attentional asymmetries (based on the T scores) was highly

significant (Fisher's exact test: $\chi^2=11.34$; $p<0.01$) and clearly points to the fact that these deficits were predominant in patients with RHL. Seven out of eight patients with RHL showed an attentional asymmetry to the left but only two out of seven patients with LHL were impaired when processing contralesional stimuli. No asymmetry was found in five patients with LHL and one patient with RHL.

CORRELATIONS BETWEEN ATTENTIONAL ASYMMETRIES AND LESION CHARACTERISTICS

No clearcut association between the size of the right sided lesion and the amount of attentional asymmetry could be established. Even small lesions within the right frontostriato-pallidothalamic system at different locations provoked the deficiencies in the processing of contralesional stimuli. Remarkably, the putamen was involved in six out of seven and the posterior limb of the internal capsule (PLIC) was lesioned in five out of seven patients (among them two patients with exclusive lesions covering the putamen and PLIC and one patient with thalamic and PLIC lesions without involvement of additional structures). Four patients showed more extensive lesions covering the lentiform nucleus, internal capsule, and/or thalamus or caudate nucleus. A superposition of the individual lesions of the patients with attentional asymmetry (fig 4) shows common areas in the dorsolateral lentiform nucleus, especially the putamen, and (to a lesser degree) the PLIC. The only patient with RHL without attentional asymmetries had an exclusive lesion of the head of the caudate nucleus without any other impaired structures. However, no association between attentional asymmetries and atrophy could be detected.

Discussion

In this study we investigated basic attentional functions in patients with circumscribed subcortical haemorrhages and infarctions within the striatopallidothalamic system. Our results demonstrate a clear attentional asymmetry in patients with RHL in visual search. Seven out of eight patients with RHL tended to be slower or missed much more target stimuli in the left sided part of the stimulus array in the visual search task. Patients with LHL performed normally in this task with only two patients showing more contralesional omissions of target stimuli than could be expected from the behaviour of normal controls. This right hemispheric dominance for visual search processes is in line with previous results on neuronal correlates of spatial attention processes. Studies on patients with circumscribed vascular lesions²⁵⁻²⁷ as well as data on the functional neuroanatomy based on PET or fMRI⁴ suggest a predominant role of right parietal cortical structures and to a lesser degree right frontal areas in spatial visual attention shifts. However, case studies repeatedly described neglect symptoms after right sided vascular thalamic²⁸ and also basal ganglia²⁹ lesions. Furthermore, the participation of the right basal ganglia and thalamus in this posterior attention network has recently been shown in a functional MRI study.⁴ Thus, our

results might again demonstrate an important role of right hemispheric basal ganglia or thalamic structures within this network although none of our patients showed signs of visual hemineglect in the visual detection task presenting visual information simultaneously to the right and left visual hemispace. In addition, clinically no signs of acute hemineglect could be found.

There is one limitation in assigning neuropsychological functions to different subcortical structures in our study as the vascular aetiology led to combined lesions of the basal ganglia, thalamus, and internal capsule in most patients. The diversity of lesions within the group with right sided lesions and spatial attention deficits complicates unequivocal statements on the functional role of the basal ganglia and thalamus within the attention network. A superposition of the individual lesions found in these patients disclosed a strong overlap in the dorsolateral lentiform nucleus—namely, the putamen. The structures of the haemorrhages within this group correspond to posterolateral and lateral types of striatocapsular haemorrhage according to Chung *et al*,³⁰ although without rupture into the lateral ventricle in our patients. The middle and posterior portions of the putamen are predominantly affected. In primates these parts of the putamen are somatotopically associated with arm and face movements.³¹ Accordingly, the putamen is considered to be an integral part of a frontostriato-pallidothalamo frontal circuit^{31,32} being involved in motor control,³³ motor sequencing,³⁴ and the automatic execution of learned motor plans.³⁵

Because five out of seven patients with RHL with spatial attention deficits also had a lesion within the posterior limb of the internal capsule it is not certain if the basal ganglia or thalamic nuclei themselves are responsible for the spatial attention deficit. Instead, a lesion of the thalamoparietal projections transversing through the posterior limb of the internal capsule via the superior peduncle of the thalamus could lead to a disconnection of functionally relevant structures within the posterior attentional network—namely, the parietal cortex and the pulvinar nucleus.⁶ As none of the patients showed any clinical or psychometric signs of acute visual hemineglect we suppose that no neuronal key structure involved in the shift of visual attention was impaired. In accordance with our results, this association between lesions in the right posterior internal capsule and neglect symptoms has been repeatedly reported.^{12,13,36,37}

In summary, circumscribed right subcortical vascular lesions lead to spatial attention deficits of visual search in the contralesional external space. We suppose that the basal ganglia, in particular the putamen, and the posterior limb of the internal capsule form an integral part of the anterior and the posterior attention network being responsible for the orienting of visual attention. The lesion characteristics of the patients lend support to the fact that the subclinical neglect symptoms found in visual search may be caused (a) by a disruption of the

motor frontostriato-pallido-thalamo-frontal neuronal circuit and/or (b) by a (partial) disconnection of relevant parts within the posterior attention network—namely, parietal and thalamic structures.

- 1 Dimond SJ. Performance by split-brain humans on lateralized vigilance tasks. *Cortex* 1979;15:43–50.
- 2 Sturm W, Desimone A, Krause BJ, et al. Functional anatomy of intrinsic alertness: evidence for a fronto-parietal-thalamic-brainstem network in the right hemisphere. *Neuropsychologia* 1999;37:797–805.
- 3 Karnath HO, Niemeier M, Dichgans J. Space exploration in neglect. *Brain* 1998;121:2357–67.
- 4 Gitelman DR, Nobre AC, Parrish TB, et al. A large-scale distributed network for covert spatial attention. Further anatomical delineation based on stringent behavioural and cognitive controls. *Brain* 1999;122:1093–106.
- 5 Posner MI, Petersen SE. The attention system of the human brain. *Annu Rev Neurosci* 1990;13:25–42.
- 6 Posner MI, Raichle ME. *Images of mind*. New York: Freeman, 1994.
- 7 Brown VJ, Robbins TW. Simple and choice reaction time performance following unilateral striatal dopamine depletion in the rat. *Brain* 1991;114:513–25.
- 8 Brasted PJ, Humby T, Dunnett SB, et al. Unilateral lesions of the dorsal striatum in rats disrupt responding in egocentric space. *J Neurosci* 1997;15:8919–26.
- 9 Ebersbach G, Trottenberg T, Hättig H, et al. Directional bias of initial visual exploration. A symptom of neglect in Parkinson's disease. *Brain* 1996;119:79–87.
- 10 Caplan LR, Schmahmann JD, Kase CS, et al. Caudate infarcts. *Arch Neurol* 1990;47:133–43.
- 11 Giroud M, Lemesle M, Madinier G, et al. Unilateral lenticular infarcts: radiological and clinical syndromes, aetiology, and prognosis. *J Neurol Neurosurg Psychiatry* 1997;63:611–15.
- 12 Ferro JM, Kertesz A, Black SE. Subcortical neglect: Quantitation, anatomy, and recovery. *Neurology* 1987;37:1487–92.
- 13 Cappa SF, Vallar G. Neuropsychological disorders after subcortical lesions: implications for neural models of language and spatial attention. In: Vallar G, Cappa SF, Wallesch CW, eds. *Neuropsychological disorders associated with subcortical lesions*. Oxford: Oxford University Press 1992:7–41.
- 14 Godefroy O, Rousseaux M, Pruvo JP, et al. Neuropsychological changes related to unilateral lenticulostratial infarcts. *J Neurol Neurosurg Psychiatry* 1994;57:480–5.
- 15 Fimm B. Mikroanalyse von Aufmerksamkeitsprozessen. In: Gauggel S, Kerkhoff G, eds. *Fallbuch Neuropsychologie*. Göttingen: Hogrefe, 1996:25–38.
- 16 Ladavas E, Del Pesce M, Provinciali L. Unilateral attention deficits and hemispheric asymmetries in the control of visual attention. *Neuropsychologia* 1989;27:353–66.
- 17 Gainotti G, D'Erme P, Bartolomeo P. Early orientation of attention toward the half space ipsilateral to the lesion in patients with unilateral brain damage. *J Neurol Neurosurg Psychiatry* 1991;54:1082–9.
- 18 Smania N, Martini MC, Gambina G, et al. The spatial distribution of visual attention in hemineglect and extinction patients. *Brain* 1998;121:1759–70.
- 19 Hildebrandt H, Benetz J, Schröder A, et al. Behandlungserfolge bei Gesichtsfeldausfall und Neglect durch kompensatorisches Training und sensible Anbahnung. *Neurologische Rehabilitation* 1998;4:132–6.
- 20 Niizuma H, Shimizu Y, Yonemitsu T, et al. Results of stereotactic aspiration in 175 cases of putaminal hemorrhage. *Neurosurgery* 1989;24:814–19.
- 21 Kothari RU, Brott T, Broderick JP, et al. The ABCs of measuring intracerebral hemorrhage volumes. *Stroke* 1996;27:1304–5.
- 22 Zimmermann P, Fimm B. *Test for attentional performance (TAP)*. Würselen: PSYTEST, 1995.
- 23 Sturm W, Willmes K. On the functional neuroanatomy of intrinsic and phasic alertness. *Neuroimage* 2001;14:76–84.
- 24 Kemeny S, Zahn R, Krings T, et al. Applications in neuroscience of a computer based talairach overlay tool. *Neuroimage* 2000;11:S526.
- 25 Marshall JC, Halligan PW. The yin and the yang of visuo-spatial neglect: a case study. *Neuropsychologia* 1994;32:1037–57.
- 26 Beschin N, Cocchini G, Della Sala S, et al. What the eyes perceive, the brain ignores: a case of pure unilateral representational neglect. *Cortex* 1997;33:3–26.
- 27 Ladavas E, Petronio A, Umiltà C. The deployment of visual attention in the intact field of hemineglect patients. *Cortex* 1990;26:307–17.
- 28 Watson RT, Valenstein E, Heilman KM. Thalamic neglect. Possible role of the medial thalamus and nucleus reticularis in behavior. *Arch Neurol* 1981;38:501–6.
- 29 Damasio AR, Damasio H, Chui HC. Neglect following damage to frontal lobe or basal ganglia. *Neuropsychologia* 1980;18:123–32.
- 30 Chung C-S, Caplan LR, Yamamoto Y, et al. Striatocapsular haemorrhage. *Brain* 2000;123:1850–62.
- 31 Alexander GE, Crutcher MD. Functional architecture of basal ganglia circuits: neural substrates of parallel processing. *TINS* 1990;13:266–71.
- 32 Alexander G, DeLong MR, Strick PL. Parallel organization of functionally segregated circuits linking basal ganglia and cortex. *Annu Rev Neurosci* 1986;9:357–81.
- 33 Jaeger D, Gilman S, Aldridge JW. Neuronal activity in the striatum and pallidum of primates related to the execution of externally cued reaching movements. *Brain Res* 1995;694:111–27.
- 34 Agostino R, Berardelli A, Formica A, et al. Sequential arm movements in patients with Parkinson's disease. *Brain* 1992;115:1481–95.
- 35 Marsden CD. The mysterious motor function of the basal ganglia: the Robert Wartenberg lecture. *Neurology* 1982;32:514–39.
- 36 Ferro J, Kertesz A. Posterior internal capsule infarction associated with neglect. *Arch Neurol* 1984;41:422–4.
- 37 Vallar G. The anatomical basis of spatial hemineglect in humans. In: Robertson IH, Marshall JC, eds. *Unilateral neglect: clinical and experimental studies*. Hove: Lawrence Erlbaum Associated, 1993:27–59.



Asymmetries of visual attention after circumscribed subcortical vascular lesions

B Fimm, R Zahn, M Mull, S Kemeny, F Buchwald, F Block and M Schwarz

J Neurol Neurosurg Psychiatry 2001 71: 652-657
doi: 10.1136/jnp.71.5.652

Updated information and services can be found at:
<http://jnp.bmj.com/content/71/5/652>

	<i>These include:</i>
References	This article cites 29 articles, 13 of which you can access for free at: http://jnp.bmj.com/content/71/5/652#BIBL
Email alerting service	Receive free email alerts when new articles cite this article. Sign up in the box at the top right corner of the online article.

Notes

To request permissions go to:
<http://group.bmj.com/group/rights-licensing/permissions>

To order reprints go to:
<http://journals.bmj.com/cgi/reprintform>

To subscribe to BMJ go to:
<http://group.bmj.com/subscribe/>