

*Full Length Research Paper*

# **Anti-ulcer and hematological properties of virgin coconut oil (VCO) against indomethacin-induced gastric ulcer in experimental rats**

**Joshua Onyeagoziri Okafor\*, Parker Elijah Joshua and Chimere Young Ukegbu**

<sup>1</sup>Department of Biochemistry, University of Nigeria, Nsukka, Nigeria.

<sup>2</sup>Department of Applied Biology and Biotechnology, Enugu State University of Science and Technology, Enugu, Enugu State, Nigeria.

Received 29 June, 2018; Accepted 31 July, 2018

Previous studies have reported various health benefits of virgin coconut oil (VCO) such as weight management, treatment of burns, infections, improve phagocytic activity, etc. The present study was conducted to investigate the anti-ulcer and hematological properties of VCO against indomethacin-induced gastric ulcers using rat model. Twenty-four Wistar albino rats were used for the study and were divided into 6 groups of 4 rats each. Group 1 rats served as the normal control; group 2 (positive control) rats were administered indomethacin only, at a dose of 100 mg/kg body weight. Group 3 rats were treated with a standard drug (cimetidine) at a dose of 100 mg/kg body weight. Groups 4 (3 ml/kg body weight VCO), 5 (6 ml/kg body weight VCO) and 6 (9 ml/kg body weight VCO) rats were treated as stated. The gastric juice volume of group 6 showed a statistically significant reduction ( $p < 0.05$ ) in the gastric juice volume when compared with the positive control group. There was a significant increase ( $p < 0.05$ ) in the packed cell volume (PCV), hemoglobin concentration and red blood cell count of VCO treated groups 4, 5 and 6 when compared with the positive control. Nonetheless, there was a significant decrease in the HDL-cholesterol, TAG concentration and total cholesterol level of the tests groups 4, 5 and 6 when compared with the positive control. Histological findings revealed that stomach sections of rats in groups 4 and 5 showed moderate widespread mucosal necrosis and ulceration, while that of group 6 rats showed focal area of mucosal ulceration with evidence of healing by fibrosis when compared with the positive control. The findings of this research revealed that VCO possesses ulcer ameliorative properties and could therefore be used for the treatment of gastric ulcers.

**Key words:** Virgin coconut oil (VCO), ulcer, cholesterol, hematology, gastric juice.

## **INTRODUCTION**

Gastric ulcer refers to sores in the stomach lining or the duodenum. It is one of the most common ailments

suffered by people especially in the developing countries (Balogun et al., 2013). In Nigeria, at least one member of

\*Corresponding author. E-mail: [Joshua.okafor@unn.edu.ng](mailto:Joshua.okafor@unn.edu.ng).

each family has suffered from, or may still suffer from stomach ulcers. Gastric ulcers are caused by *Helicobacter pylori* infection and/or the use of non-steroidal anti-inflammatory drugs (NSAIDs). More than 50% of the world population is believed to be infected with *H. pylori*, the infection usually occurring during childhood days, although adults are not immune. The Gram-negative bacterium is responsible for about 90% of duodenal ulcers and more than 60% of gastric ulcers (Kogilavani et al., 2014). *H. pylori* produces the enzyme urease which breaks down urea to ammonia and carbon dioxide (Minkara et al., 2014). The ammonia reacts with the stomach acid (HCL), producing ammonium chloride, increasing the stomach pH and facilitating the survival of the bacterium. In developing countries, there is little or no effective regulation of medications by the appropriate government bodies.

Current treatment for stomach ulcers includes: anti-secretory drugs (Proton pump inhibitors, antihistaminic (H2) and anticholinergic (M1)) and cyto-protective (sucralfate and prostaglandin analogues) agents (Reham et al., 2017). In addition to being expensive, treatment of ulcer with these drugs produces undesirable side effects or resistant strains of *H. pylori* (Balogun et al., 2013). This has stimulated the interest of scientists towards finding ulcers treatments using natural plant products, which would produce no resistant bacteria strains, and negligible contraindications; this interest has opened the field of “nutraceuticals”. Coined by Stephen De Felice defined nutraceuticals as foods or components of food which provide medical/health benefits including the prevention and treatment of diseases (Karla,2003). Examples of nutraceuticals include lycopene in tomatoes, omega 3 fatty acids in salmon, and medium chain saturated fatty acids in coconut oil (Loomba and Jothi, 2013).

Virgin coconut oil (VCO) may be defined as oil obtained from fresh mature coconut (*Cocos nucifera*) kernel by mechanical or natural means with or without the use of heat and without subjecting the oil to any chemical refining or bleaching (Mohammad et al., 2014). Dietary oils capable of lowering low density lipoprotein (LDL) cholesterol level and increasing high density Lipoprotein (HDL) cholesterol level are known to be beneficial to health (Nevin and Rajamohan, 2004). However, saturated oils are believed to aggregate and cause cardiovascular diseases; unsaturated oils on the other hand do not clog blood vessels and therefore cause fewer of such diseases. It then follows that dietary oils with high concentrations of polyunsaturated fats are better for the health than those with higher saturated fats content (Nevin and Rajamohan, 2008). Virgin coconut oil is an exception; it contains saturated fatty acids yet very beneficial to health (Mouna et al., 2012). This is because VCO contains mostly saturated medium chain fatty acids (MCFAs) which are easily metabolized by the body. VCO

also contains antioxidants like polyphenols, tocopherols, and antioxidants vitamins (Ahmad et al., 2015). Based on the aforementioned premise, this study has been designed to investigate the anti-ulcer effect of VCO and its effect on hematology and lipid profiles.

### Significance statement

The riddle of the etiopathogenesis of gastric ulcer remains unresolved. This is a current pursuit for a highly efficient anti-ulcer drug from natural source. Thus, this research is geared towards investigating the anti-ulcer activity of VCO on Wistar albino rats.

### MATERIALS AND METHODS

#### Plant

Fresh matured nuts (12-13 months old) of *Cocos nucifera*, with no haustoria were obtained from Awgu Local Government Area, Enugu State of Nigeria and were identified at International Center for Ethnomedicine and Drug development (InterCEDD) with herbarium voucher no InterCEDD/16287. The nuts were de-husked, cracked mechanically to obtain the coconut meat, and the coconut meat was ground using a motorized grinder.

#### Animals

The animals used for the study were albino mice (21-33 g), for LD<sub>50</sub>, and adult male Wistar albino rats (120±137 g), for the animal model. Animals were obtained from the Animal House of the Department of Zoology and Environmental Biology, University of Nigeria, Nsukka. The animals were acclimatized for 1 week before the experiment and were fed with standard rat's pellets (Pfizer Livestock feeds Plc, Enugu, Nigeria) and tap water was given *ad libitum*. Animal experimental studies were conducted according to the guidelines of Institutional Animal Ethical Committee of Faculty of Biological Sciences, University of Nigeria, Nsukka.

#### Experimental design

Twenty-four adult male Wistar albino rats were acclimatized for 1 week at the same conditions of temperature and pressure, and the same animal feeds were used for all the rats. The rats were divided randomly into six groups of four animals each and treated as follows:

- Group 1: Normal control (No indomethacin + No VCO)
  - Group 2: Positive control (Untreated group): (Indomethacin)
  - Group 3: Standard control (Indomethacin + Cimetidine/Standard Drug)
  - Group 4: Low-dose treatment (Indomethacin + 3 ml/kg body weight VCO)
  - Group 5: Mid-dose treatment (Indomethacin + 6 ml/kg body weight VCO)
  - Group 6: High-dose treatment: (Indomethacin + 9 ml/kg body weight VCO)
- Rats were fasted overnight prior to the commencement of treatment

Cimetidine (standard drug) and VCO were administered orally for 4 days. On the 5th day, after an overnight fasting, gastric ulcer was induced in the rats of groups 2 to 6 with 100 mg/kg body weight (p.o) indomethacin using standard procedures. Four hours after induction, blood was collected through ocular puncture and the rats were sacrificed. Blood samples collected were used for biochemical analysis. Stomachs were removed and opened along the greater curvature to remove gastric contents. Gastric ulcers were viewed and counted with the aid of a magnifying hand lens (x10). The experimental design is a modified method of Reham et al. (2017).

#### Preparation of indomethacin sample

The stock concentration of indomethacin was prepared by adopting the method of Hiroshini et al. (1987). A known weight (500 mg) of the standard drug was dissolved in 2 ml of distilled water and water was added to bring the stock concentration to 25 mg/ml. The dose used was 100 mg/kg body weight.

#### Preparation of cimetidine (Standard drug)

The stock concentration of cimetidine was prepared by adopting the method of Hiroshini et al. (1987). 800 mg of the standard drug was dissolved in 10 ml of distilled water to get a stock concentration of 80 mg/ml. The dose used was 100 mg/kg body weight.

#### Preparation of VCO

VCO was prepared using the method of Divina and Keith (2006) as described:

- (1) Fresh matured nuts were de-husked manually.
- (2) The de-husked nuts were de-shelled manually and the coconut meat and testa fed into a motorized coconut shredder.
- (3) The milk from the grated coconut meat was extracted by hand. The milk obtained was set aside, while the coconut milk residue (sapal) was prepared for the second extraction.
- (4) The sapal was mixed with distilled water at a ratio of 2 sapal: 1 water. The mixture was pressed to obtain the second milk extraction.
- (5) The first and second milk extracts were mixed by stirring vigorously for about 10 min.
- (6) The resulting mixture was kept in a refrigerator for 3 h and allowed to stand.
- (7) The coconut cream (oily part) was separated from the coco skim milk (watery part) by scooping the cream from the top. The coco skim milk was discarded, while the coconut cream was transferred into a beaker and used for subsequent procedures.
- (8) The coconut cream was placed in a water bath and heated slowly at 50°C for 2.5 h to separate the coconut protein (latik) from the coconut oil. The coconut oil was separated from the latik by straining the mixture through a muslin cloth. The latik was discarded while the coconut oil was retained.
- (9) The coconut oil was dried by incubating at 50°C for 12 h to remove all residual moisture.
- (10) The oil was filtered and stored
- (11) The resulting oil was called VCO.

#### Acute toxicity studies

Acute toxicity studies were conducted by a modification of Loke (1983) method as described by Mouna et al. (2012). Twenty-four

albino mice were divided into two phases I and II, with each group subdivided into four groups made up of three animals each.

#### Experimental protocol for acute toxicity studies

##### Phase I

Group 1: Mice were administered with 2 ml/kg body weight of VCO.  
Group 2: Mice were administered with 4 ml/kg body weight of VCO.  
Group 3: Mice were administered with 6 ml/kg body weight of VCO.  
Group 4: Mice were administered with 6 ml/kg body weight of distilled water.

##### Phase II

Group 1: Mice were administered with 8 ml/kg body weight of VCO.  
Group 2: Mice were administered with 10 ml/kg body weight of VCO.  
Group 3: Mice were administered with 12 ml/kg body weight of VCO.  
Group 4: Mice were administered with 12 ml/kg body weight of distilled water.

The mice were monitored closely for 24 h for signs of toxicity and lethality. The median lethal dose (LD<sub>50</sub>) was calculated using the formula:

$$LD_{50} = \sqrt{(D_0 \times D_{100})}$$

where D<sub>0</sub> = highest dose that caused no mortality and D<sub>100</sub> = lowest dose that produced mortality.

#### Methods for biochemical examination

##### Determination of gastric juice volume

Gastric juice volume was determined according to the method of Balogun et al. (2013). The gastric content was centrifuged at 3000 rpm for 10 min, then separated and the volume measured using a graduated cylinder.

##### Total cholesterol concentration

The total cholesterol concentration was determined using QCA commercial enzyme kit as described by Allain et al. (1976).

##### Determination of low density lipoprotein-cholesterol concentration

Low density lipoprotein-cholesterol (LDL-cholesterol) concentration was determined using QCA Commercial Kits as described by Assmann et al. (1984).

##### Estimation of triacylglycerol concentration

Triacylglycerol concentration was determined using Randox Enzyme Kit as described by Albers et al. (1978).

**Table 1.** Percentage yield of virgin coconut oil (VCO).

Weight of VCO (g)	Weight of coconut meat (g)	Percentage yield
228	1900	12

**Table 2.** Acute Toxicity Results.

Phase	Groups of mice	Doses of VCO (ml/kg)	Mortality
Phase I	Group 1	2	0/3
	Group 2	4	0/3
	Group 3	6	0/3
Phase II	Group 1	8	0/3
	Group 2	10	0/3
	Group 3	12	0/3

n=3.

#### **Determination of packed cell volume (PCV)**

This was done using the procedure described by Ochei and Kolhartar (2008).

#### **Determination of total white blood cell (WBC) count**

Total WBC concentration was determined using by the method of Ramnik (2003).

#### **Determination of red blood cell (RBC) count**

RBC concentration was determined using the method described by Cheesbrough (2000).

#### **Determination of haemoglobin concentration**

This was done using the method described by Ochei and Kolhaktar (2008).

#### **Assay for aspartate aminotransferase activity**

A Randox Commercial Enzyme kit according to the methods of Reitman and Frankel (1957) and Schmidt and Schmidt (1963) was used.

#### **Assay for alanine aminotransferase (ALT) activity**

A Randox Commercial Enzyme Kit based on the methods of Reitman and Frankel (1957) and Schmidt and Schmidt (1963) was used.

#### **Assay for alkaline phosphatase (ALP) activity**

This was done using a Commercial Enzyme Kit according to the

method of Klein et al. (1960).

#### **Histopathological examination**

The histological examination of the tissues of the pancreas of Wistar albino rats was done using the method of Drury et al. (1967).

#### **Statistical analysis**

Results from the experimental study were expressed as mean  $\pm$  standard deviation (SD) and test of statistical significance was carried out using one-way analysis of variance (ANOVA). The means were separated using Duncan Multiple Test. The statistical packaged used was the statistical product and service solutions (SPSS), version 20. Differences at  $p < 0.05$  were considered statistically significant.

## **RESULTS**

### **Percentage yield of VCO**

As presented in Table 1, the percentage yield of VCO was found to be 12% with respect to the starting material.

### **Acute toxicity results**

The extract was found to be non-toxic, although there was furring and decreased activity/movement following the administration of a high dose (12 ml/kg body weight VCO) in the phase II. The LD<sub>50</sub> was calculated to be more than 12 ml/kg body weight (Table 2).

**Table 3.** Effects of VCO on the ulcer parameters of experimental rats.

Group	Gastric juice volume (ml)
Group 1	0.13 ± 0.05 <sup>a</sup>
Group 2	0.46 ± 0.15 <sup>b</sup>
Group 3	0.45 ± 0.31 <sup>b</sup>
Group 4	0.21 ± 0.10 <sup>ab</sup>
Group 5	0.26 ± 0.13 <sup>ab</sup>
Group 6	0.14 ± 0.05 <sup>a</sup>

Data are expressed as mean ± SD (n = 4). Values with different alphabet in the superscript has a statistical significant difference at p < 0.05 while same alphabet has no significant difference. Group 1=Normal Control (No Indomethacin + No treatment). Group 2=Positive Control (Indomethacin-Induced + Untreated Rats). Group 3=Standard Control (Indomethacin-Induced Rats + 100mg/kg body weight of cimetidine). Group 4=Low Dose Treatment (Indomethacin-Induced Rats + 3 ml/kg body weight of VCO). Group 5=Mid Dose Treatment (Indomethacin-Induced Rats + 6 ml/kg body weight of VCO). Group 6=High Dose Treatment (Indomethacin-Induced Rats + 9 ml/kg body weight of VCO).

**Table 4.** Effects of VCO on haematological parameters of experimental rats.

Group	PCV (%)	Hb (g/dl)	RBC (×10 <sup>6</sup> mm <sup>-3</sup> )	WBC (mm <sup>-3</sup> )
Group 1	47.00 ± 3.65 <sup>c</sup>	13.08 ± 0.66 <sup>b</sup>	12.50 ± 0.68 <sup>bc</sup>	4700 ± 258.20 <sup>bc</sup>
Group 2	38.75 ± 4.11 <sup>a</sup>	9.12 ± 0.59 <sup>a</sup>	7.30 ± 0.60 <sup>a</sup>	3800 ± 516.40 <sup>a</sup>
Group 3	45.00 ± 3.74 <sup>bc</sup>	13.19 ± 0.93 <sup>b</sup>	14.33 ± 1.56 <sup>c</sup>	6150 ± 191.49 <sup>d</sup>
Group 4	44.25 ± 5.38 <sup>b</sup>	13.60 ± 0.50 <sup>b</sup>	12.30 ± 2.32 <sup>bc</sup>	5050 ± 660.81 <sup>c</sup>
Group 5	45.25 ± 2.22 <sup>bc</sup>	13.38 ± 0.97 <sup>b</sup>	11.20 ± 1.13 <sup>b</sup>	4100 ± 258.20 <sup>ab</sup>
Group 6	47.75 ± 5.74 <sup>c</sup>	13.43 ± 0.61 <sup>b</sup>	12.78 ± 1.83 <sup>bc</sup>	4300 ± 476.10 <sup>ab</sup>

Data are expressed as mean ± SD (n = 4). Values with different alphabet in the superscript has a statistical significant difference at p < 0.05 while same alphabet has no significant difference. Group 1=Normal Control (No Indomethacin + No treatment). Group 2=Positive Control (Indomethacin-Induced + Untreated Rats). Group 3=Standard Control (Indomethacin-Induced Rats + 100mg/kg body weight of cimetidine). Group 4=Low Dose Treatment (Indomethacin-Induced Rats + 3 ml/kg body weight of VCO). Group 5=Mid Dose Treatment (Indomethacin-Induced Rats + 6 ml/kg body weight of VCO). Group 6=High Dose Treatment (Indomethacin-Induced Rats + 9 ml/kg body weight of VCO).

### Effect of VCO on the gastric juice volume of indomethacin-challenged rats

There was a non-significant (p > 0.05) increase in the gastric juice volume of rats in the treatment groups (4, 5 and 6) as compared to the normal control (Table 3). However, such an increase was found to be non-dose dependent. Group 5 rats (0.26 ml ± 0.13 ml) were found to have the highest juice volume when compared with groups 4 (0.21 ± 0.10 ml) and 6 (0.14 ± 0.05 ml).

From Table 4, a non-significantly (p > 0.05) difference was observed in the PCV of VCO treated groups 5 and 6 when compared with the negative control; nevertheless; group 4 showed a significant decrease in the PCV when compared with the negative control. There was a significant increase (p < 0.05) in the PCV of VCO treated groups when compared with the positive control. The

haemoglobin (Hb) concentration of groups 4, 5 and 6 rats were found to be non-significantly (p > 0.05) higher as compared to the negative control; notwithstanding the Hb concentration of the test groups 4, 5 and 6 rats was found to be significantly (p < 0.05) higher than the positive control. The RBC concentration of groups 4, 5 and 6 rats treated with VCO was found to be significantly (p < 0.05) higher than the positive control, while the RBC concentration of groups 4, 5 and 6 rats was observed to be non-significant (p > 0.05) when compared with the negative control. The WBC of groups 4, 5 and 6 rats was found to be significantly (p < 0.05) higher when compared with the positive control. The total WBC count of the test groups were however found to be non-significantly (p > 0.05) different when compared with the negative control.

From Table 5, a dose-dependent non-significant (p > 0.05) decrease in the HDL-cholesterol concentration of

**Table 5.** Effects of VCO on lipid parameters of experimental rats.

Group	LDL (mmol/L)	TAG (mmol/L)	T.Chol. (mmol/L)
Group 1	2.35 ± 0.80 <sup>a</sup>	1.14 ± 0.08 <sup>a</sup>	3.98 ± 0.80 <sup>ab</sup>
Group 2	2.67 ± 0.37 <sup>a</sup>	1.75 ± 0.10 <sup>b</sup>	5.10 ± 0.77 <sup>b</sup>
Group 3	2.45 ± 0.84 <sup>a</sup>	1.18 ± 0.24 <sup>a</sup>	4.14 ± 0.74 <sup>ab</sup>
Group 4	2.35 ± 0.76 <sup>a</sup>	1.17 ± 0.09 <sup>a</sup>	3.94 ± 0.65 <sup>ab</sup>
Group 5	2.21 ± 0.97 <sup>a</sup>	1.28 ± 0.13 <sup>a</sup>	3.80 ± 0.95 <sup>a</sup>
Group 6	2.36 ± 0.34 <sup>a</sup>	1.19 ± 0.21 <sup>a</sup>	3.83 ± 0.45 <sup>a</sup>

Data are expressed as mean ± SD (n = 4). Values with different alphabet in the superscript has a statistical significant difference at p < 0.05 while same alphabet has no significant difference. Group 1=Normal Control (No Indomethacin + No treatment). Group 2=Positive Control (Indomethacin-Induced + Untreated Rats). Group 3=Standard Control (Indomethacin-Induced Rats + 100mg/kg body weight of cimetidine). Group 4=Low Dose Treatment (Indomethacin-Induced Rats + 3 ml/kg body weight of VCO). Group 5=Mid Dose Treatment (Indomethacin-Induced Rats + 6 ml/kg body weight of VCO). Group 6=High Dose Treatment (Indomethacin-Induced Rats + 9 ml/kg body weight of VCO).

**Table 6.** Effects of VCO on the activities of liver marker enzymes of experimental rats.

Group	ALT (IU/L)	AST (IU/L)	ALP (IU/L)
Group 1	37.08 ± 2.88 <sup>a</sup>	34.60 ± 3.30 <sup>a</sup>	47.13 ± 5.45 <sup>a</sup>
Group 2	41.71 ± 9.65 <sup>a</sup>	35.73 ± 2.14 <sup>a</sup>	51.20 ± 8.73 <sup>a</sup>
Group 3	36.21 ± 6.05 <sup>a</sup>	32.80 ± 2.59 <sup>a</sup>	46.25 ± 6.40 <sup>a</sup>
Group 4	44.50 ± 10.07 <sup>a</sup>	38.10 ± 9.41 <sup>a</sup>	47.75 ± 10.69 <sup>a</sup>
Group 5	37.67 ± 7.22 <sup>a</sup>	42.53 ± 1.76 <sup>a</sup>	41.00 ± 11.22 <sup>a</sup>
Group 6	41.33 ± 8.22 <sup>a</sup>	40.38 ± 10.26 <sup>a</sup>	48.25 ± 5.74 <sup>a</sup>

Data are expressed as mean ± SD (n = 4). Values with different alphabet in the superscript has a statistical significant difference at p < 0.05 while same alphabet has no significant difference. Group 1=Normal Control (No Indomethacin + No treatment). Group 2=Positive Control (Indomethacin-Induced + Untreated Rats). Group 3=Standard Control (Indomethacin-Induced Rats + 100mg/kg body weight of cimetidine). Group 4=Low Dose Treatment (Indomethacin-Induced Rats + 3 ml/kg body weight of VCO). Group 5=Mid Dose Treatment (Indomethacin-Induced Rats + 6 ml/kg body weight of VCO). Group 6=High Dose Treatment (Indomethacin-Induced Rats + 9 ml/kg body weight of VCO).

the test groups (4, 5 and 6) as compared to the normal control was observed. There was a significant decrease in the HDL-cholesterol concentration of the tests groups 4, 5 and 6 when compared with the positive control. The LDL-cholesterol assay revealed a non-significant (p > 0.05) difference in groups 4, 5 and 6 treated with VCO when compared with the positive control and the negative control group. There was a significant (p < 0.05) decrease in the triacylglyceride (TAG) concentration of the VCO treated groups (4 to 6) when compared with the positive control. Also, as can be observed in Table 5, there was a significant decrease (p < 0.05) in the total cholesterol level of treatment groups 5 and 6 when compared with the positive control group; however, group 4 showed no significant difference (p < 0.05) in the total cholesterol concentration when compared with the positive control.

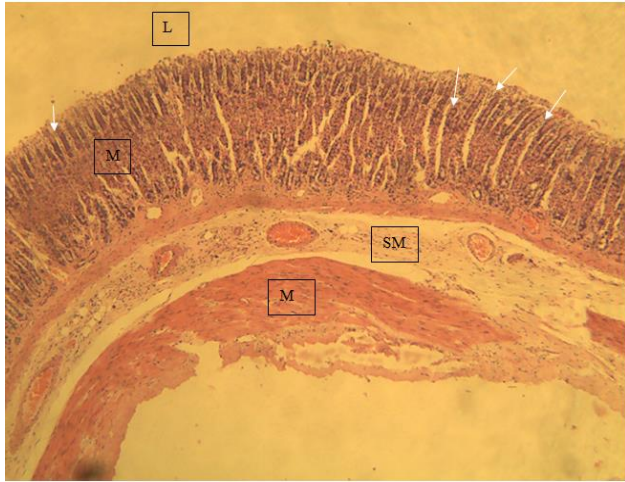
From Table 6, there was no significant (p > 0.05) increase or decrease in the activities of ALT, AST and

ALP of the treatment groups (4, 5 and 6) as compared to the positive control and the negative control.

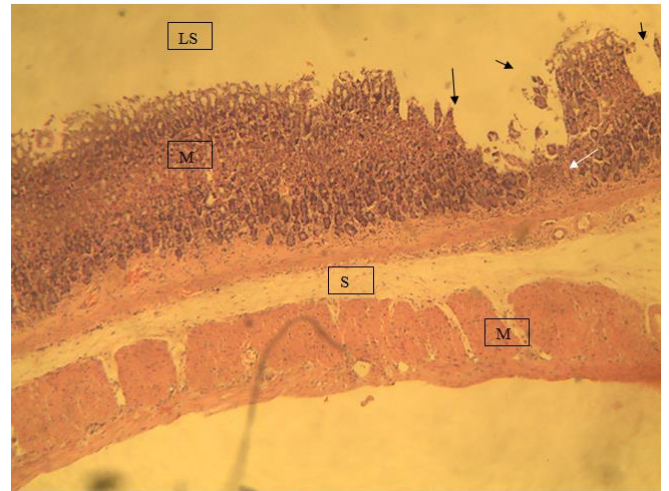
### Histological

Plate 1 shows the stomach tissues of normal control (group 1) rats. Sections of the stomach collected from the animals in group 1 showed the normal gastric histomorphology for laboratory rats. Normal structures of the mucosa (M), sub-mucosa (SM) and muscularis layers (ML) were observed. Normal gastric pits (white arrow) are lined by low columnar epithelial cells and opening into the mucosa were observed. Normal lamina propria of mucosa containing abundant inflammatory and immune cells was observed. The submucosa and muscularis mucosa both showed the normal histomorphology: Luminal side (LS); H&E x40.

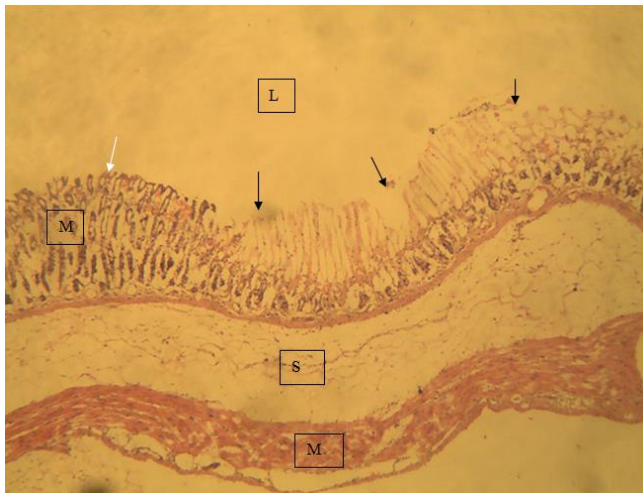
As shown in Plate 2, sections of the stomach collected



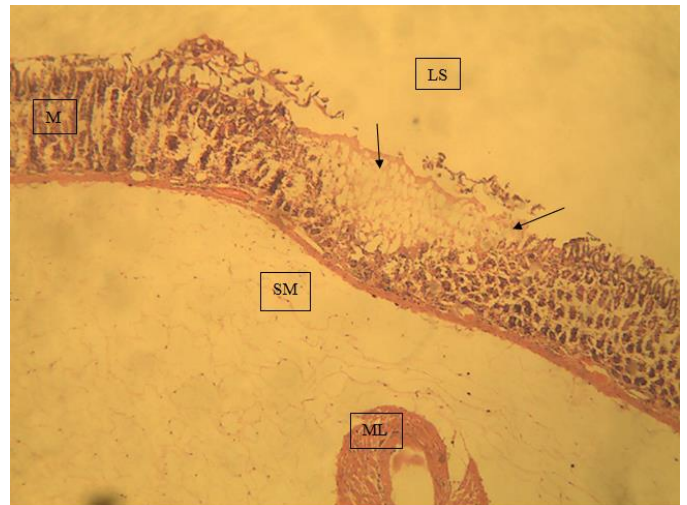
**Plate 1.** Photomicrograph of stomach tissues of normal control (group 1) rats.



**Plate 3.** Photomicrograph of stomach tissues of standard control (group 3) rats.



**Plate 2.** Photomicrograph of stomach tissues of positive control (group 2) rats



**Plate 4.** Photomicrograph of stomach tissues of low-dose VCO treatment (group 4) rats.

from the animals in group 2 showed multiple, widespread, and mucosal ulceration (arrow) when compared with normal gastric mucosa (white arrow): Luminal surface (LS); Submucosa (SM); Mucosa (M); Muscularis layer (ML); H&E  $\times 40$

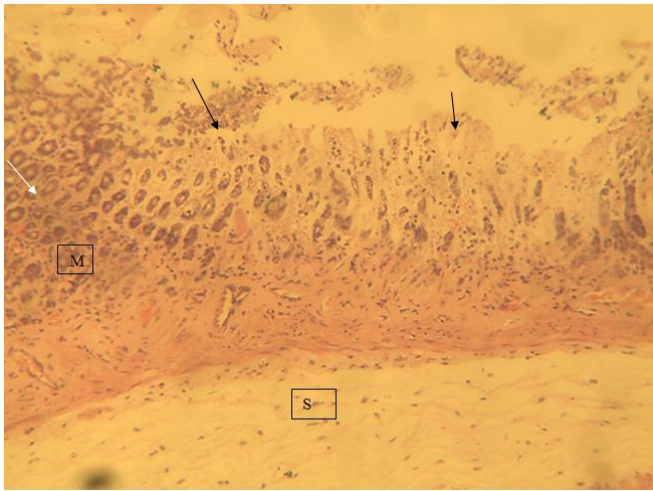
As shown in Plate 3, sections of the stomach collected from animals in group 3 (standard control) showed multifocal mucosal ulcerations (arrow). However, the affected areas showed evidence of healing by fibrosis (white arrow): Luminal surface (LS); Mucosa (M); Submucosa (SM); Muscularis layer (ML); H&E  $\times 40$ .

In Plate 4, sections of the stomach collected from group 4 rats treated with 3 ml/kg body weight VCO showed

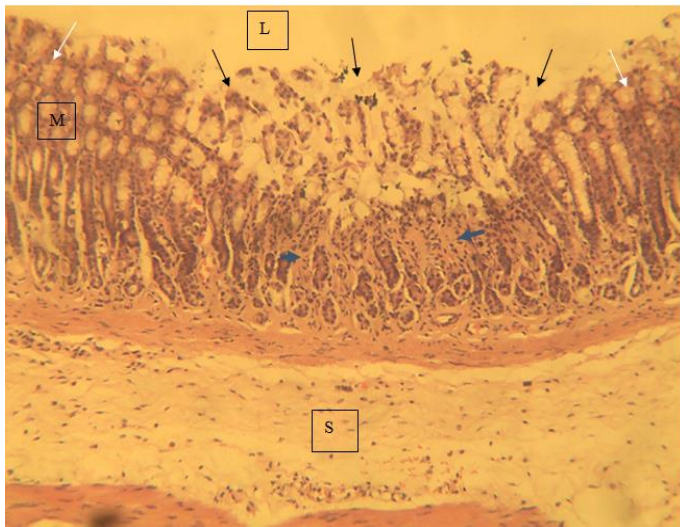
moderate widespread mucosal necrosis and ulceration (arrow): Luminal surface (LS); Mucosa (M); Submucosa (SM); Muscularis layer (ML); H&E  $\times 40$ .

Plate 5 shows sections of the stomach collected from the animals in group 5 administered with 100 mg/kg body weight indomethacin and treated with a mid-dose of 6 ml/kg body weight VCO. There was a wide area of mucosal necrosis and ulceration (black arrow) when compared with the relatively normal mucosa (white arrow): Luminal surface (LS); Mucosa (M); Submucosa (SM); H&E  $\times 100$ .

In Plate 6, stomach tissue sections collected from the animals in group 6 showed focal area of mucosal



**Plate 5.** Photomicrograph of stomach tissues of mid-dose VCO treatment (group 5) rats.



**Plate 6.** Photomicrograph of stomach tissues of high-dose VCO treatment (group 6) rats.

ulceration (black arrow) with evidence of healing by fibrosis (blue arrow) when compared with the relatively normal gastric mucosa (white arrow): Luminal surface (LS); Mucosa (M); Submucosa (SM); H&E  $\times 100$ .

## DISCUSSION

Gastric ulcers are sores in the intestinal mucosa caused by the use of non-steroidal anti-inflammatory drugs (NSAIDs) or the Gram-negative bacterium, *H. pylori*. VCO contains predominantly medium chain fatty acids

(MCFA) which are potent bactericidal and antimicrobial agents (Fabian, 2014). VCO also stimulate prostaglandin synthesis, platelet aggregation and wound healing, and can therefore be used to treat NSAIDs-induced ulceration. It also contains antioxidant vitamins and stimulates the activities of enzymatic antioxidants thereby minimizing damage caused by peroxidation and free radicals generation (Nevin and Rajamhan, 2005; Ahmad et al., 2015).

From Table 2, it can be deduced that VCO is safe for consumption. Results from Table 3 shows that there was a non-significant ( $p > 0.05$ ) increase in the gastric juice volume of rats in the treatment groups (4, 5 and 6) as compared to the normal control. However, the gastric juice volume of the treatment groups was found to be lower when compared with the positive control however only group 6 showed a statistically significant reduction in the gastric juice volume when compared with the positive control group. VCO stimulates prostaglandin secretion thereby reducing the volume of gastric acid secreted into the lumen, leading to a consequent decrease in gastric juice volume. The results obtained are in agreement with the works of Ikwebe et al. (2017) where the effect of ethanolic extracts of selected dietary spices on gastric acid secretion in Wistar rats was evaluated.

From Table 4, there was a significant increase ( $p < 0.05$ ) in the PCV of VCO treated groups when compared with the positive control. PCV is a measure of the amount of space (volume) occupied by the red blood cells. VCO contains antioxidants which could stabilize the erythrocyte membrane, preventing erythrocyte depletion and thereby leading to an increase in PCV. This result supports the work of Penner et al. (2005) who reported an increase in the PCV of rats treated with VCO. The haemoglobin (Hb) concentration of groups 4, 5 and 6 rats were found to be non-significantly ( $p > 0.05$ ) higher as compared to the negative control; notwithstanding, the Hb concentration of the test groups 4, 5 and 6 rats was found to be significantly ( $p < 0.05$ ) higher than the positive control. Haemoglobin is spilt following haemolysis of the red blood cells caused by free radicals. Free radical scavenging potentials of VCO is probably responsible for the observed increase in the Hb concentration. This finding supports the research of Penner et al. (2005) who observed a decrease in Hb concentration of rats treated with VCO as compared to the normal control. The RBC concentration of groups 4, 5 and 6 rats treated with VCO was found to be significantly ( $p < 0.05$ ) higher than the positive control, while the RBC concentration of group 4, 5 and 6 rats was observed to be non-significantly ( $p > 0.05$ ) when compared with the negative control. This is probably due to the antioxidant vitamin components of VCO which could protect against RBC membrane oxidation by free radicals thereby reducing the breakdown of RBC thus increasing RBC count. This finding supports the reports of Anosike et al.



(2010) who reported the anti-ulcerogenic and membrane stabilization effect of ethanol extract of coconut (*Cocos nucifera*).

The WBC of groups 4, 5 and 6 rats was found to be significantly ( $p < 0.05$ ) higher when compared with the positive control. This is probably due to the antioxidant components of VCO stimulating the immune system to produce more WBC to fight the disease condition thereby increasing WBC count. Coconut (*Cocos nucifera*) was reported to protect several organs against oxidative damage activity as an antioxidant due to high content of L-arginine and vitamin C (Ahmad et al., 2015), thus boosting the immune system and reducing lipid peroxidation.

The LDL-cholesterol assay revealed a visible decrease but was statistical non-significant ( $p > 0.05$ ) in groups 4, 5 and 6 treated with VCO when compared with the positive. LDL-cholesterol (the so called "bad cholesterol") transports lipid particles (e.g. cholesterol, phospholipids and tri-acylglycerols) to extra-hepatic tissues. When LDL particles are oxidized in arterial walls, they are retained by proteoglycans ultimately leading to atherosclerosis and cardiovascular diseases. Lipid peroxidation in arterial cells; therefore, causes an increase in the release of retained LDL cholesterol resulting in an increase in LDL concentration. VCO contains antioxidants which prevent such oxidation; hence, the decrease in LDL concentration. This finding supports the research of Moshira et al. (2016) who reported a significant ( $p < 0.05$ ) decrease in the LDL-cholesterol concentration of rats treated with virgin coconut oil after copper-induced LDL oxidation. There was a significant ( $p < 0.05$ ) decrease in the TAG concentration of the VCO treated groups (4 to 6) when compared with the positive control. This observation of this work is in tandem with the works of Hayatullina et al. (2012) who observed a decrease in TAG concentration after treatment with VCO. Also, as can be observed in Table 5, there was a significant decrease ( $p < 0.05$ ) in the total cholesterol level of treatment groups 5 and 6 when compared with the positive control group; however, group 4 showed no significant difference ( $p > 0.05$ ) in the total cholesterol concentration when compared with the positive control. Nevertheless, these results suggest that the mid and the high doses are more effective when compared with the low dose. Notwithstanding, it is most probable that VCO modulates the removal of cholesterol from the system maybe by stimulating the activity of lecithin-cholesterol acyltransferase (LCAT), which attaches cholesterol molecules in the blood to either VLDL/LDL ( $\alpha$ -LCAT activity) or to the HDL ( $\beta$ -LCAT activity), thereby removing cholesterol and leading to a decrease of the amount of cholesterol in the sera. This result is in agreement with the work of Nevin and Rajamohan (2009) who reported a decrease in cholesterol concentration following VCO treatment.

From Table 6, there was a non-significant ( $p > 0.05$ ) increase or decrease in the activities of ALT, AST and ALP of the treatment groups (4, 5 and 6) as compared to the positive control and the negative control. The gradation in the AST activity of the VCO treated groups was observed to be dose-dependent. This is probably as a result of the MCFA contents of VCO which decrease the stomach pH towards acidity. Alkaline phosphatase functions maximally in alkaline medium and therefore, its activity reduces following VCO treatment. This finding supports the research of Kabara (2014) who observed a non-significant ( $p > 0.05$ ) decrease in the ALP activity of rats treated with VCO after oxidative stress has been induced with cyclophosphamide.

Histological findings revealed that stomach sections of rats in groups 4 and 5 showed moderate widespread mucosal necrosis and ulceration, while that of group 6 rats showed focal area of mucosal ulceration with evidence of healing by fibrosis when compared with the positive control.

The stomach of the animals in the positive control group showed severe ulceration with haemorrhages (H) and inflammatory cells when compared with the normal and standard controls with intact epithelium, gastric glands, and the lamina propria (LP). Treatments with VCO showed some visible effect from the photomicrograph against ulceration showing the decreasing trend of mucosal congestion. The results from this study is in tandem with the work of Amjad and Tahir (2017) where the effect of ethanolic extract of coconut (*C. nucifera*) on aspirin-induced gastric ulcer in albino rats was evaluated.

## Conclusion

The findings of this research revealed that VCO possesses nutraceutical properties and could therefore be used for the treatment of gastric ulcers. However, there is need for more work to be done to ascertain the actual mechanism of action and bioactive compound responsible for its medicinal properties.

## CONFLICT OF INTERESTS

The author has no conflict of interest.

## REFERENCES

- Ahmad Z, Hasham R, Aman NNF, Sarmidi MR (2015) Physico-Chemical and Antioxidant Analysis of Virgin Coconut Oil Using West African Tall Variety. *Journal of Advanced Research in Materials Science* 13(1):1-10.
- Amjad M, Tahir M (2017) Effect of Ethanolic Extract of Coconut (*Cocos nucifera*) on Aspirin-induced Gastric Ulcer in Albino Rats.

- Journal of Gastrointestinal and Digestive System 7(3):2-6.
- Albers JJ, Warmick, GR, Cheng MC (1978). Determination of high density lipoprotein (HDL)-cholesterol. *Clinical Chemical Acta* 13:926-932.
- Allain CC, Poon LS, Chan CSG, Richmond W, Fu P C (1976). Enzymatic determination of serum total cholesterol. *Clinical Chemistry* 20:470-475.
- Anosike CA, Obidoa O, Nwodo OFC, Joshua PE (2010) Anti-Ulcerogenic and Membrane Stabilization Effect of Ethanol Extract of Coconut (*Cocosnucifera*). *Research Journal of Pharmacognosy and Phytochemistry* 2(1):85-88
- Assmann G, Jabs HU, Kohnert U, Nolte W, Schriewer H (1984). Determination of low density lipoprotein (LDL)-cholesterol. *Clinica Chimica Acta* 140:77-83.
- Balogun ME, Oji JO, Besong EE, Ajah A, Michael EM (2013). Anti-ulcer activity of aqueous leaf extract of *Nauclea latifolia* (rubiaceae) on indomethacin-induced gastric ulcer in rats. *African Journal of Biotechnology* 12(32): 5080-5086.
- Cheesbrough M (2000). *District Laboratory Practice in Tropical Countries*, Part 1, UK: Cambridge University Press. pp 299-320.
- Divina DB, Keith RC (2006). *Virgin Coconut Oil Production Manual for Micro- And Village-Scale Processing*. Thammada Press Co. Ltd, Bangkok. pp. 1-80.
- Drury RA, Wallington A, Cameroun SR (1967). In: Carleton's *Histological Techniques*. Oxford University Press, New York pp. 1-420.
- Fabian MD (2014) Lauric Acid is a Medium-Chain Fatty Acid, Coconut Oil is a Medium-Chain Triglyceride. *Philippine Journal of Science* 143(2):157-166.
- Hayatullina Z, Muhammad N, Mohamed N, Soelaiman I (2012). Virgin Coconut Oil Supplementation Prevents Bone Loss in Osteoporosis Rat Model. *Evidence-Based Complementary and Alternative Medicine* 10:1-8.
- Hiroshini A, Toshiharu H, Masahiro SH (1987). An alteration in liver microsomal membrane of the rat following Paracetamol overdose. *Journal of Pharmacy and Pharmacology* 39:1047-1049.
- Ikwebe J, Tatah VS, Ubandoma A, Otokpa JO (2017). Effect of Ethanolic Extracts of Selected Dietary Spices on Gastric Acid Secretion in Wistar Rats. *International Journal of Chemical and Biomedical Science* 3(4):32-38
- Kabara JJ (2014). Health oils from the tree of life (nutritional and health aspects of coconut oil). *Evidence-Based Complementary and Alternative Medicine* 4:1-10.
- Karla EK (2003). Nutraceutical - Definition and Introduction. *American Association of Pharmaceutical Scientist* 5(3):1-2.
- Klein B, Read PA, Babson LA (1960). In vitro determination of alkaline phosphatase in serum or plasma. *Journal of Clinical Chemistry* 6:269-275.
- Kogilavani S, Qodriyah HM, Srijit D, Faizah O (2014). Virgin Coconut Oil (VCO) Decreases the Level of Malondialdehyde (MDA) in the Cardiac Tissue of Experimental Sprague-Dawley Rats Fed with Heated Palm Oil. *Journal of Medical and Bioengineering* 3(2):102-106
- Loomba S, Jothi V (2013). *Cocos Nucifera*: Its properties and contributions to Dentistry. *International Journal of Scientific Study* 1(3):138-140.
- Lorke D (1983). A new approach to practical acute toxicity testing. *Archives of Toxicology* 54:275-287.
- Minkara MS, Ucisik MN, Weaver MN, Merz KM (2014). Molecular Dynamics Study of Helicobacter pylori Urease. *Journal Chemical Theory Computation* 10:1852-1862.
- Mohammad AH, Faizah O, Srijit D, Yusof K, Zar CT, Haji MSQ, Zaiton Z, Adel E, Kogilavani S, Kamsiah J (2014). Effect of consumption of fresh and heated virgin coconut oil on the blood pressure and inflammatory biomarkers: An experimental study in Sprague Dawley rats. *Alexandria Journal of Medicine* 4:1-11.
- Moshira AE, Doaa HA, Tarek K, Mustafa S (2016). Ameliorative Effect of Coconut Oil on Hematological, Immunological and Serum Biochemical Parameters in experimentally infected Rabbits. *Alexandria Journal of Veterinary* 50(1):36-48
- Mouna AA, Norliza M, Ahmad NS, Ima NS (2012). The effects of virgin coconut oil on bone oxidative status in ovariectomised rat. *Evidence-Based Complementary and Alternative Medicine* 10:1-6.
- Nevin KG, Rajamohan T (2004). Beneficial effects of virgin coconut oil on lipid parameters and in vitro LDL oxidation. *Clinical Biochemistry* 37:830-835
- Nevin KG, Rajamohan T (2005) Virgin coconut oil supplemented diet increases the antioxidant status in rats. *Food Chemistry* 99:260-266.
- Nevin KG, Rajamohan T (2008). Influence of virgin coconut oil on blood coagulation factors, lipid levels and LDL oxidation in cholesterol fed Sprague Dawley rats. *European Society for Clinical Nutrition and Metabolism* 3:1-8.
- Nevin KG, Rajamohan T (2009). Wet and dry extraction of Coconut oil: Impact on lipid metabolic and antioxidant status in cholesterol co-administered rats. *Canadian Journal of Physiology and Pharmacology* 87:610-616.
- Ochei E, Kolhaktar F (2008). Method of determination of haematological parameters. *Clinical Chemistry* 23:200-205.
- Penner R, Fedorak RN, Madsen KL (2005). Probiotics and nutraceuticals: Non-medicinal treatments of gastrointestinal diseases. *Current Opinion in Pharmacology* 5:596-603.
- Ramnik S (2003). *Haematology for Students and Practitioners*. Jaypee Brothers Medical Publishers Ltd. EMLA, New Delhi pp. 189-191.
- Reham ME, Amani SA, Gamal AS, Sanaa AK, Saleh IA (2017). Prophylactic and curative anti-ulcerogenic activity and the possible mechanisms of action of some desert plants. *Saudi Pharmaceutical Journal* 25:387-396.
- Reitman S, Frankel S (1957). A colorimetric method for determination of serum glutamate oxaloacetate and glutamic pyruvate transaminase. *American Journal of Clinical Pathology* 28:56-58.
- Schmidt E, Schmidt FW (1963). Determination of serum GOT and GPT. *Enzymologia Biologica et Clinica* 3:1:6.