

## What Disconnection Tells about Motor Imagery: Evidence from Paraplegic Patients

Hatem Alkadhi<sup>1</sup>, Peter Brugger<sup>2</sup>, Sabina Hotz Boendermaker<sup>3</sup>, Gerard Crelier<sup>1</sup>, Armin Curt<sup>3</sup>, Marie-Claude Hepp-Reymond<sup>4</sup> and Spyros S. Kollias<sup>1</sup>

<sup>1</sup>Institute of Neuroradiology, University Hospital Zurich, CH-8091 Zurich, Switzerland, <sup>2</sup>Department of Neurology, University Hospital Zurich, CH-8091 Zurich, Switzerland, <sup>3</sup>Spinal Cord Injury Center, Balgrist University Hospital, CH-8008 Zurich, Switzerland and <sup>4</sup>Institute of Neuroinformatics, University and ETH Zurich, CH-8057 Zurich, Switzerland

**Brain activation during motor imagery has been the subject of a large number of studies in healthy subjects, leading to divergent interpretations with respect to the role of descending pathways and kinesthetic feedback on the mental rehearsal of movements. We investigated patients with complete spinal cord injury (SCI) to find out how the complete disruption of motor efferents and sensory afferents influences brain activation during motor imagery of the disconnected feet. Eight SCI patients underwent behavioral assessment and functional magnetic resonance imaging. When compared to a healthy population, stronger activity was detected in primary and all non-primary motor cortical areas and subcortical regions. In paraplegic patients the primary motor cortex was consistently activated, even to the same degree as during movement execution in the controls. Motor imagery in SCI patients activated in parallel both the motor execution and motor imagery networks of healthy subjects. In paraplegics the extent of activation in the primary motor cortex and in mesial non-primary motor areas was significantly correlated with the vividness of movement imagery, as assessed by an interview. The present findings provide new insights on the neuroanatomy of motor imagery and the possible role of kinesthetic feedback in the suppression of cortical motor output required during covert movements.**

**Keywords:** functional MRI, motor imagery, spinal cord injury

### Introduction

Motor imagery (MI) is defined as mental rehearsal of a motor act without any overt movement execution (ME). There is strong evidence that MI can modify and even improve motor performance (Gandevia, 1999), and many studies have sought to delineate its underlying mechanisms and identify its cortical correlates. Comparisons of brain activation patterns acquired by positron emission tomography and functional magnetic resonance imaging (fMRI) during ME and MI have shown that several cortical and subcortical regions are specifically engaged during MI (Roland *et al.*, 1980; Stephan *et al.*, 1995; Deiber *et al.*, 1998; Luft *et al.*, 1998; Lotze *et al.*, 1999; Gerardin *et al.*, 2000; Johnson *et al.*, 2002; Lafleur *et al.*, 2002; Hanakawa *et al.*, 2003). These regions include at the cortical level the supplementary motor (SMA), the pre-SMA, rostral prefrontal, premotor and posterior parietal areas, and subcortically the anterior portion of the putamen, the caudate nucleus bilaterally and posterolateral aspects of the anterior cerebellar hemispheres. The majority of these regions also participate in motor preparation (Deiber *et al.*, 1996). Some authors emphasize that certain regions are active during both covert motor acts and overt movements (Stephan *et al.*, 1995; Gerardin *et al.*, 2000). To them belong the superior parietal and lateral premotor areas, mainly posterior parts of the putamen and anterior and more medial aspects of

the cerebellum. Several investigations have even reported involvement of the primary motor cortex during MI, but with lower levels of activation when compared to ME (Porro *et al.*, 1996; Roth *et al.*, 1996; Lotze *et al.*, 1999; Nair *et al.*, 2003). The participation of the sensorimotor cortex in MI is also supported by electroencephalographic, magnetoencephalographic and TMS investigations (Beisteiner *et al.*, 1995; Schnitzler *et al.*, 1997; Abbruzzese *et al.*, 1999).

The possibility that the neuronal network involved in ME may also be active during MI raises a number of issues addressing the origin of this activation. (i) The central nervous system may run a template of the movements without activating the motor plant, sharing partly overlapping networks for motor preparation and execution. This model is favored by cognitive neuroscientists (Jeannerod, 1994; Jeannerod and Frak, 1999; Fadiga *et al.*, 1999). (ii) Mental rehearsal may partially activate the descending corticospinal pathway, the spinal machinery and effector muscles (Gandevia *et al.*, 1993, 1997). In line with this hypothesis are the observations that spinal circuits are activated by transcranial magnetic stimulation (TMS) in a similar manner during MI and ME (Bonnet *et al.*, 1997; Kiers *et al.*, 1997; Rossini *et al.*, 1999). This finding, however, is challenged by other studies, showing modulation of the motor cortical excitability without evoking descending volleys to the spinal cord (Kasai *et al.*, 1997; Yahagi and Kasai, 1998; Hashimoto and Rothwell, 1999; Abbruzzese *et al.*, 1999). (iii) Activation during MI may be caused by plastic changes in cortical excitability induced by the absence of somatosensory, in particular kinesthetic, feedback in covert movements. Indeed, recent results (Ziemann *et al.*, 1998) have revealed an increase of motor cortical excitability after experimental deafferentation, confirming thus earlier findings (Brasil-Neto *et al.*, 1993). (iv) The inconsistent and less significant primary motor cortex activation during MI as compared to ME may be explained by the cortico-cortical inhibition required to prevent activation of the peripheral motor apparatus during MI (Porro *et al.*, 1996).

The present study was designed to answer these issues by investigating brain activation in paraplegic patients during MI with fMRI. Patients with traumatic spinal cord injury (SCI) suffer an acutely acquired disconnection of efferent motor and afferent sensory pathways between the lower body parts and the cortical and subcortical structures. The paraplegic condition rules out any subliminal activation of the spinal cord and motor plants from cortical and subcortical origin. Enhanced cortical excitability conveyed by the transient loss of afferent somatosensory input can be also dismissed, but plastic changes due to long-term deafferentation could be revealed. We thus made two predictions. First, the brain activation patterns in the SCI patients during MI should merely reflect the central nervous

dynamical circuit for motor behavior, or template of movements. Second, the comparison between the cortical and sub-cortical activations in healthy subjects and those in paraplegics may give a cue as to the central sources of movement suppression during MI, and/or the plastic changes induced by the paraplegic condition.

Essential to the goals of the present study was the behavioral assessment of the SCI patients. Specifically, we quantified the patients' ability to imagine movements of their disconnected foot, to ensure that brain activity was related to MI and not to an attempt to move (Shoham *et al.* 2001; Sabbah *et al.*, 2002). According to Decety and Boisson (1990) and Gandevia *et al.* (1993), SCI patients are still able to mentally rehearse movements of their disconnected limbs and report movement duration and sensation of effort in the same way as healthy controls. These similarities provide the foundation for comparing brain activation patterns related to MI in SCI patients with those of a healthy population. Furthermore, the quantification of MI vividness allows correlating individual ratings with the quantitative fMRI findings, and thus provides additional characterization of the central structures subserving MI.

## Materials and Methods

### Subjects

Eight paraplegic patients (three female, five male, mean age 31.3 years, range 22–43 years) participated in this study. Chapman and Chapman's (1987) handedness inventory revealed clear right-hand dominance in all patients (mean score 14.0). The mean period following traumatic SCI was 32 months (range 4–76 months). Only patients with chronic SCI were included so that the influence of long-term deafferentation on the ability to internally generate motor images could be investigated. All suffered from complete SCI between T3 and L1, as assessed clinically with the impairment scale of the American Spinal Injury Association (ASIA: A; Maynard *et al.*, 1997) and electrophysiologically by motor evoked potentials (MEP) in the anterior tibial muscle after transcranial magnetic stimulation (TMS) and by recording of somatosensory evoked potentials (SEP) by stimulation of the tibial nerve. Individual clinical data can be found in Curt *et al.* (2002). None had suffered a brain lesion, and all had a normal Glasgow Coma Scale (Teasdale and Jennett, 1974) following SCI. Exclusion criteria included medical or mental illness, substance abuse, and use of medication known to alter cognitive and neurological activity. To assess MI, a structured interview on phantom sensations (Brugger and Regard, 1998; Brugger *et al.*, 2000) was carried out by telephone within 4 weeks after the fMRI sessions. It comprised questions regarding presence, quality, intensity and modifiability of various sensations referred to the disconnected body parts (see Supplementary Material). Among the questions, one was specifically designed for the present study. Participants were asked to take a reclined position and imagine, eyes closed, to perform repetitive flexion/extension movements of the right foot during 30 s. The rate of imagined movements was not specified, but it was stressed that the 'speed of imagined movements should be such that continuous mental monitoring would be guaranteed'. On a seven-point scale (sent to each participant 1 week before the interview), the SCI patients were then required to rate the vividness of these imaginary movements from absent (0) to high (7).

Eight right-handed (mean score 13.1), healthy subjects (four female, four male, mean age 29.6 years, range 26–36 years) with no history of neurological or psychiatric illness were recruited as controls. The ability to kinesthetically imagine movements of their feet was assessed by the Vividness of Motor Imagery Questionnaire (VMIQ; Isaac *et al.*, 1986). Only subjects who had reached the score of 60 or less (possible range, 24–120; best score, 24), thus fulfilling the criterion for vivid kinesthetic MI ability, were included in this study (mean score, 43; range, 38–51).

The study was approved by the Ethics Committee of the Medical Faculty of the University of Zurich, Switzerland. Written informed consent was obtained from all participants according to the Declaration of Helsinki.

### fMRI Tasks

The control subjects were instructed to execute repetitive flexion and extension movements of the right foot at the ankle at a rate of approximately 0.5 Hz. The SCI patients were familiar with the 0.5 Hz rhythm as they had to perform upper limb movements at this rate during the same session prior to the MI experiment (Curt *et al.*, 2002). For the MI condition, both controls and SCI patients were required to imagine themselves performing the same movements without actually executing them. To ensure proper task execution in both SCI patients and healthy subjects, each task was practiced first outside and then inside the magnet bore prior to the scanning procedure. The experimental design consisted of three repetitions of 30 s periods of rest alternating with 30 s periods of ME (controls) or MI (controls and SCI patients). The beginning and end of each task period was verbally transmitted over the scanner intercom system. The experimenters visually controlled the subjects during the task performance and checked for potential movements in the trunk and lower limbs during MI. Assessment of surface EMG during fMRI still lacks the sensitivity to detect small and undesired movements due to gradient-induced artifacts (Dai *et al.*, 2001) and was not performed in this study. Overt motion was never observed during the MI task. In the control population EMG recordings were performed outside of the scanner in a separate experiment after the scanning, to only include subjects without any EMG activity during MI. In an open interview after the fMRI, all participants reported that they had been able to perform the MI task. During the experiments, all individuals had their eyes closed and the light was dimmed in the scanner room.

### Imaging Procedures

Imaging was carried out on a 1.5 T whole body scanner (Signa Horizon; Echo-speed LX General Electric Medical Systems, Milwaukee, WI) equipped with a standard product transmit-receive head coil.  $T_1$ -weighted whole-brain anatomical reference volume data with an isotropic spatial resolution of 1.2 mm were acquired with a 3D spoiled gradient echo sequence [ $T_E$  (echo time) = 9 ms,  $T_R$  (repetition time) = 50 ms]. fMRI was conducted using a gradient-echo echo-planar pulse sequence ( $T_E$  = 40 ms,  $T_R$  = 3750 ms, flip angle 90°) sensitive to blood oxygen level dependent (BOLD) signal. Thirty contiguous, axial slices with a slice thickness of 4 mm covering the entire brain were acquired. The imaging matrix consisted of 128 × 96 data points resulting in a rectangular field-of-view of 256 × 192 and a nominal in-plane resolution of 2 × 2 mm. Series of 48 sequential volumes were acquired for each experiment.

### fMRI Data Analysis

The data analysis and postprocessing were performed offline as follows. To minimize artefacts due to residual head motion, functional volumes were realigned using a rigid-body registration algorithm (Woods *et al.*, 1998). Subsequently, data were spatially filtered using a 3D Gaussian convolution kernel of 4 mm at full-width half-maximum (FWHM). For single subject analysis, normalization into Talairach space was not performed. For the group analysis, all volumes were registered to the Montreal average volumetric data set aligned on the Talairach stereotactic coordinate system (Collins *et al.*, 1994). The statistical analysis of all fMRI data was based on a linear model with correlated errors and was carried out for each data set (Worsley *et al.*, 1996; <http://www.math.mcgill.ca/keith/fmristat>). The design matrix of the linear model was first convolved with a gamma hemodynamic response function (Glover, 1999). Drift was removed by adding polynomial covariates in the frame times, up to degree 3, to the design matrix. Resulting effects and their standard errors were determined on a voxel by voxel basis. In a second step, sessions were combined using a mixed effects linear model with standard deviations taken from the previous analysis (Worsley *et al.*, 1996). A random effects analysis was performed by first estimating the ratio of the random effects variance to the fixed effects variance, then regularizing this ratio by spatial smoothing with a 15 mm FWHM filter. The variance of the effect was then estimated by the smoothed ratio multiplied by the fixed effects variance to achieve higher degrees of freedom. The resulting *t*-statistic images were then thresholded using the minimum given by a Bonferroni correction and random field theory (Worsley *et al.*, 1996). The threshold for significant activation was  $P < 0.05$  with a corresponding *Z*-value of 4.85, corrected for multiple comparisons. For each activation cluster, the volume of activation, the maximum signal intensity, and the geometrical

center of gravity were determined and the location in Talairach coordinates retained. Homogenous distribution in each cluster was assumed for the center of gravity calculation; therefore, all voxels above the significant threshold were weighted uniformly. The anatomical boundaries of all segmented areas were defined according to a previous publication (Kollias *et al.*, 2001). Cerebellar lobule identification was based on the nomenclature of Larsell and Jansen (1972).

### Correlation between Vividness of MI, Brain Activation and Time since SCI

For the SCI patients, non-parametric Spearman rank order correlation coefficients were computed for all segmented areas between the MI vividness ratings and quantitative aspects of the BOLD signal (maximum *t*-value and volume of activation). Additional Spearman rank order correlation coefficients were calculated between the time since SCI and the degree of activation in all segmented areas, and between the time since SCI and the individual vividness ratings. In the healthy population, no correlation coefficients were computed since only subjects with similar VMIQ scores were included (see Materials and Methods).

## Results

### Group Analysis

The patterns of activation were analyzed for both populations to identify the main fields involved in MI, in ME, and the differences between healthy subjects and SCI patients. Table 1 lists all functional areas activated by execution and imagination of foot movements, the corresponding cytoarchitectonic

regions, cluster volumes, Talairach coordinates of their COGs, and maximum *t*-values of the group analyses versus rest (contrasts i, ii and iii).

### (i) Execution of Right Foot Movements Contrasted to Rest in Healthy Controls

Activation was detected in the primary motor foot area, in the primary somatosensory (S1), dorsal premotor (PMd) and superior parietal areas contralaterally, and in the SMA and cingulate motor areas (CMA) bilaterally (Fig. 1*a,b*). No activation in the basal ganglia or in the thalamus was detected (Fig. 1*c*). Additional activation was present in the ipsilateral anterior cerebellar hemispheres (Larsell lobules II-III, Fig. 1*d* and Table 1).

### (ii) Imagination of Right Foot Movements Contrasted to Rest in Healthy Controls

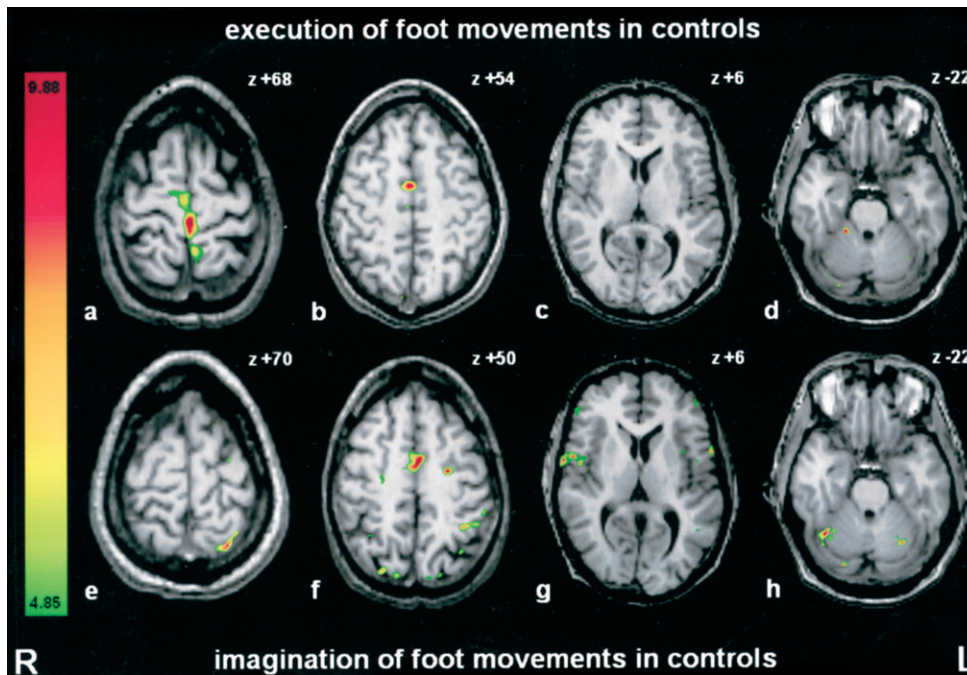
MI of the foot in the controls elicited activation bilaterally in the SMA, CMA, ventral premotor (PMv), PMd, superior parietal and prefrontal areas, secondary somatosensory cortex (S2) and in contralateral (left) inferior parietal areas (Fig. 1*e-g* and Table 1). The group analysis did not reveal any activity in the primary motor cortex, the basal ganglia, or the thalamus (Fig. 1*e,g*). Bilateral cerebellar activation was located more posteriorly and laterally in Larsell lobules H VIIA of the anterior hemispheres (Fig. 1*b*).

**Table 1**

Talairach coordinates, maximum *t*-values and activation volumes for motor execution and imagery in the controls and SCI patients

Functional area (Brodmann area)		Motor execution in controls					Motor imagery in controls					Motor imagery in paraplegics				
		x	y	z	Max. <i>t</i> -value	Volume (mm <sup>3</sup> )	x	y	z	Max. <i>t</i> -value	Volume (mm <sup>3</sup> )	x	y	z	Max. <i>t</i> -value	Volume (mm <sup>3</sup> )
M1	Right															
(4)	Left	-3	-28	67	10.1	2776						-4	-28	71	10.1	2904
S1	Right											7	-37	70	7.3	39
(1, 2, 3)	Left	-8	-38	70	7.8	832						-11	-43	71	8.9	1328
SMA	Right	5	-14	67	6.8	128	8	-6	76	6.3	112	5	-7	65	10.2	2416
(6)	Left	-4	-20	72	6	608	-1	-7	76	6.1	96	-3	-10	65	12.9	2848
Pre-SMA	Right											6	4	64	8.7	1248
(6)	Left											-4	4	68	8.1	720
PMd	Right											51	2	51	6.5	96
(6)	Left	-15	-22	68	8.1	368	-25	-8	60	6	128	-39	-3	56	6.5	512
PMv	Right						56	2	7	6.5	800	58	12	10	7.2	512
(6, 44, 45)	Left						-59	8	11	5.8	144	-55	8	14	6.2	320
CMA	Right	-1	-6	50	5.6	80	2	-3	52	5.5	96	4	8	41	7.1	1056
(6, 24)	Left	3	-6	51	5.7	112	-1	0	51	6	432	-6	-3	41	7.9	1088
Superior	Right						27	-75	52	5.1	48	20	-30	64	5.2	80
Parietal (7)	Left	-12	-47	69	7.5	818	-16	-65	62	7.4	832	-44	-47	50	6.7	1104
Inferior	Right											57	-36	42	5.7	144
Parietal (40)	Left						-43	-44	56	6.3	368	-57	-32	41	5.9	144
S2	Right						65	-31	31	6.5	310	56	-32	34	6.4	528
(40, 43)	Left						-57	-34	34	6.7	432	-63	-22	20	5.4	96
Insula	Right											42	12	6	5.8	200
(13)	Left						-33	23	4	5.3	48	-39	8	0	5.2	80
Prefrontal areas	Right						51	40	4	5.9	144	50	37	17	6.7	836
(46)	Left						-48	45	8	5.1	80	-48	43	12	6.7	352
Prefrontal areas	Right															
(9)	Left											-39	30	36	5.8	128
Thalamus	Right											14	-11	16	6.3	592
	Left											-11	-12	15	6.9	1008
Putamen	Right											21	3	12	6.2	304
	Left											-26	-10	7	5.8	608
Caudate nucleus	Right											20	-7	24	6.2	272
	Left											-16	-12	24	6.2	448
Cerebellum	Right	20	-40	-24	6.2	608						16	-45	-22	9.3	2240
Larsell II-III	Left											-11	-45	-20	6	496
Cerebellum	Right						39	-57	-24	5.2	96	36	-63	-26	8	1296
Larsell H VIIA	Left						-30	-65	-28	5.9	336	-32	-67	-28	7	1600

M1, primary motor cortex; S1, primary somatosensory; SMA, supplementary motor; PMd, premotor dorsal; PMv, premotor ventral; CMA, cingulate motor; S2, secondary somatosensory area. In functional areas with more than one activation cluster, the mean coordinates, the maximum *t*-values and the total volumes are given.



**Figure 1.** Activation patterns during execution (*a-d*) and imagination (*e-h*) of right foot movements in the healthy controls (group analysis). Movement execution activated the contralateral primary motor and somatosensory foot area, the SMA and CMA bilaterally (*a, b*) as well as the ipsilateral anterior cerebellum (Larsell lobules II-III, *d*), while activation in thalamus and basal ganglia was absent (*c*). Imagination of right foot movements activated CMA, PMd, PMv, parietal, and prefrontal areas bilaterally (*e-g*). No activity was detected in the primary motor cortex, in the basal ganglia or the thalamus (*e, g*). Cerebellar activation was bilateral, more posterior and lateral, located in Larsell lobules H VIIA (*h*). Right side on the image corresponds to left hemisphere. z-Coordinates corresponding to Talairach space (Collins *et al.*, 1994). Numbers in the color bar correspond to *t*-values.

### (iii) Imagination of Foot Movements Contrasted to Rest in SCI Patients

This group analysis revealed a significant BOLD signal in the contralateral primary motor and S1 foot representation (Fig. 2*a,b*). The clusters of activation showed no shift into the hand or trunk primary motor area and no spatial spread to adjacent cortical regions. The Talairach coordinates of primary motor cortex activation were similar to those of healthy subjects during motor execution (Table 1). In addition, bilateral fields of activation were present in SMA, pre-SMA, CMA, PMd, PMv, superior and inferior parietal regions, S2, and the insular and prefrontal cortex (Table 1). Strong bilateral subcortical activation was also detected in the putamen, caudate nucleus and thalamus (Fig. 2*d,e*). In the cerebellum activation was found in Larsell lobules II-III mainly ipsilaterally, and symmetrically in both Larsell lobules H VIIA (Fig. 2*c*). In summary, these data suggest that the cortical and subcortical activation patterns in the SCI patients during MI correspond to the sum of the activations obtained during both ME and MI in healthy controls.

### (iv) Imagination of Foot Movements: Contrast between SCI Patients and Controls

To test whether MI in SCI patients elicited the same degree of activation in the same regions as MI in controls, data obtained in healthy subjects were subtracted from those in SCI patients. The resulting fMRI maps showed activation in all cortical and subcortical regions described above (iii). They include the contralateral primary motor and S1 foot representation, and bilaterally the SMA, pre-SMA, CMA, PMd, PMv, superior and inferior parietal regions, S2, and the insular and prefrontal cortex (Fig. 3*a,b*). Further activation was present in the putamen, caudate nucleus, and thalamus bilaterally, in the

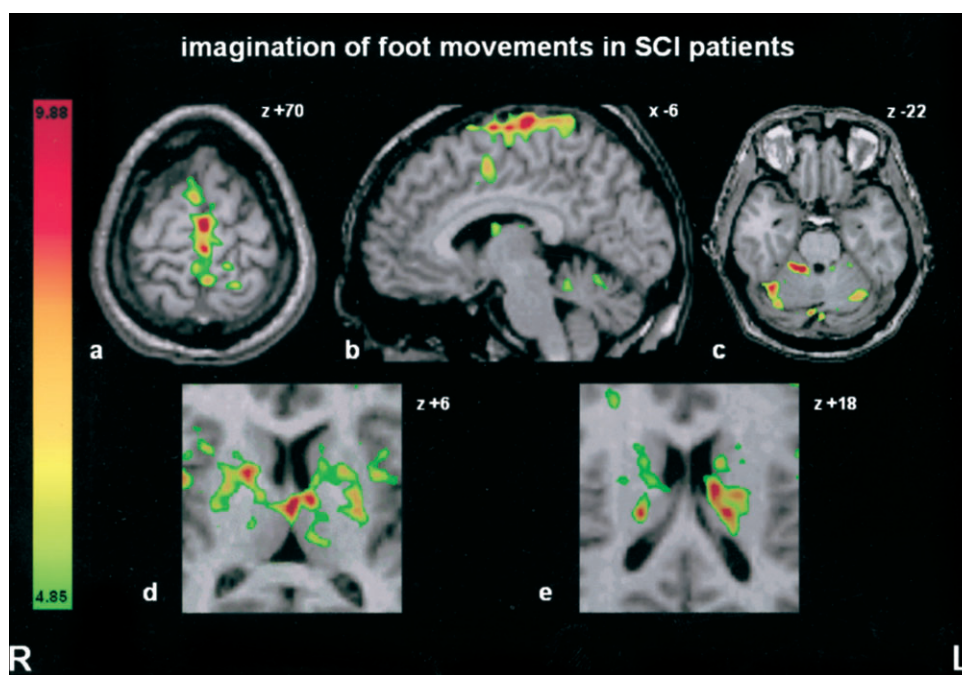
cerebellum in Larsell lobules II-III ipsilaterally, and symmetrically in both Larsell lobules H VIIA (Fig. 3*c-e*). The Talairach coordinates of the COG of these regions are listed in Table 1. This group contrast therefore revealed that the degree of activation in all cortical and subcortical regions active during imagination of foot movements (contrasted with rest, iii) was significantly higher in the SCI patients than in the controls.

### (v) Imagination of Foot Movements: Contrast between Controls and SCI Patients

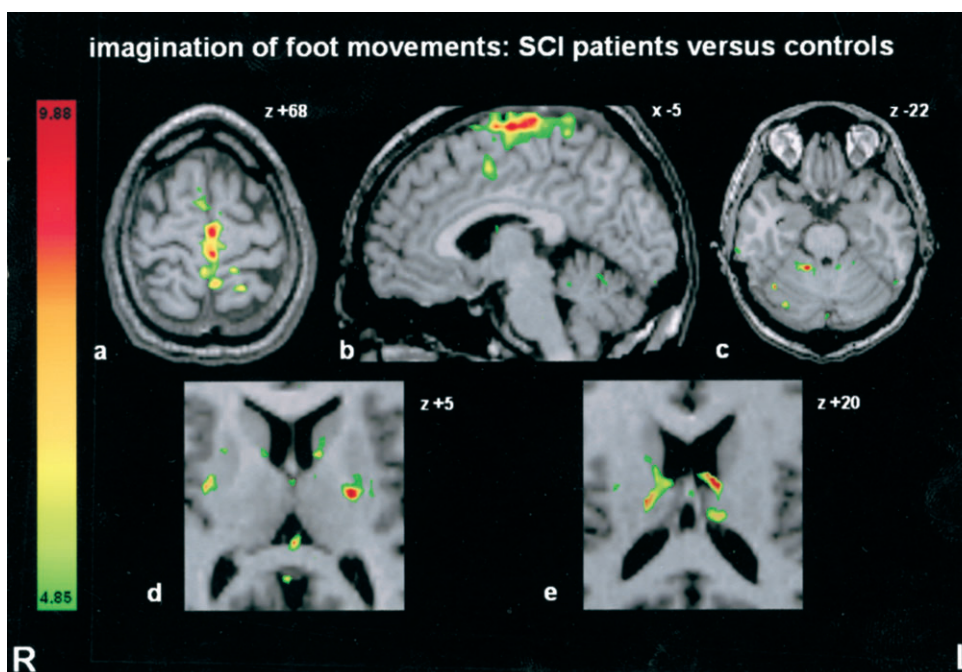
As MI in healthy subjects requires suppression of the peripheral motor apparatus, the subtraction of the MI SCI data from the MI healthy control data should disclose regions specifically involved in MI in the controls. However, this subtraction did not reveal any significant cortical or subcortical activation foci. This demonstrates that no region can be assigned to such a suppression during MI in healthy subjects.

### (vi) Contrast between Imagination in SCI Patients and Execution in Controls

The enhanced activity revealed in previous contrasts (iii and iv) suggests that MI in SCI patients activated central structures in a similar way as ME in controls. To further test this observation, we subtracted the ME data of healthy subjects from those obtained in paraplegics during MI. Main result was that the contralateral primary motor cortex activation during ME was completely subtracted out. Significant activations resulting from this contrast were located in all other cortical areas and subcortical regions listed above (iii) and in Table 1. This finding demonstrates that the degree of activation was significantly higher in the SCI patients during MI than in the controls during ME, in all the regions except the primary motor cortex.



**Figure 2.** Activation patterns during imagination of right foot movements in the SCI patients contrasted with rest (group analysis). The contralateral primary motor foot area was strongly activated (*a, b*). Further activity is seen in the SMA, pre-SMA and CMA bilaterally (*a, b*). Cerebellar activation was present in Larsell lobules II–III, mainly ipsilaterally, and symmetrically in both Larsell lobules H VIIA (*c*). Strong subcortical activation occurred in the bilateral putamen, caudate nucleus, and the thalamus (*d, e*). Same conventions as in Figure 1.



**Figure 3.** Activation patterns during imagination of right foot movements in the SCI patients contrasted to controls (group analysis). This contrast revealed activation foci in the same regions as shown in Figure 2, but to a lesser degree. These included the contralateral primary motor and somatosensory foot area, SMA, pre-SMA and CMA bilaterally (*a, b*). Subcortical activation was present in the cerebellum (Larsell lobules II–III and Larsell lobules H VIIA), and in the bilateral putamen, caudate nucleus, and the thalamus (*c–e*). Same conventions as in Figure 1.

*(vii) Contrast between Execution in Controls and Imagination in SCI Patients*

It was expected that the subtraction of the MI SCI data from the ME control data would reveal some foci of increased activation

in the controls during ME. However, no significantly increased activation in any area could be detected. Together with the previous contrast (vi) this finding confirms that the contralateral primary motor cortex was activated in the controls to the

same degree during ME as in the SCI patients during MI (volumes 2776 versus 2904 mm<sup>3</sup>, both maximum *t*-values 10.1).

### Results of Individual Subjects

In the single subject analysis the correspondence between anatomical structures and the BOLD signals can be determined with higher precision as the single subject data are not normalized into Talairach space, a procedure with inherent inaccuracies. This was of particular interest for the primary motor cortex, S1, and subcortical structures, where the group analysis may have failed to detect activation during MI due to a low signal-to-noise ratio. The results are presented in Table 2, which lists for each region the number of SCI patients with detected activation during MI and of healthy subjects during ME and MI.

Deviations from the group analysis were only found for the healthy controls. Inconsistent activation was present in the putamen, thalamus and cerebellum during ME and in the pre-SMA, thalamus and cerebellum during MI. Activation of the contralateral primary motor foot area during MI occurred in four of the eight controls (mean volume 586 ± 243 mm<sup>3</sup>) and in two in S1 (mean volume 197 ± 64 mm<sup>3</sup>). In contrast, the analysis of the individual SCI patients' data during MI revealed the same fields of activation as the group analysis and did not disclose any additional one. Striking was the clear BOLD signal in the contralateral primary motor cortex in all eight SCI patients and in S1 in seven of them. These activation clusters were located in the primary motor and S1 foot representations, without any shift or spread into hand or trunk representations or other adjacent regions. Moreover, the basal ganglia, thalamus and cerebellum were consistently bilaterally activated.

In the SCI patients, the degree of activation in the primary motor, non-primary motor and subcortical regions did not correlate significantly with the individual delays since SCI (all Spearman rho ≤ 0.553, *P* ≥ 0.15).

### Correlations between MI Vividness Scores, Brain Activation and tie since SCI

Of the seven SCI patients interviewed (one patient refused to take part in the interview), all reported the presence of various phantom sensations. In particular, kinesthetic MI of their deaf-ferented right foot was spared, as indicated by non-zero ratings

of the vividness of imagined movements for each individual participant. The mean vividness rating for the imagined foot movements during the 30 s period was 3.7 (SD 1.6). Correlation coefficients were computed between the MI vividness ratings and quantitative aspects of the BOLD signal (maximum *t*-values and volumes of activation) in all regions with significant activation.

In the primary motor cortex, the individual MI ratings were significantly correlated with the maximum *t*-values (rho = 0.873, *P* < 0.01, see Fig. 4) and a positive trend found with the activated volumes (rho = 0.750, *P* = 0.05). In several non-primary motor areas, the MI vividness ratings correlated significantly with the maximum *t*-values and/or volumes of activation. Positive correlation coefficients were found with the maximum *t*-values in the left SMA (rho = 0.982, *P* < 0.01, Fig. 4) and in the right pre-SMA (rho = 0.856, *P* < 0.05), and with the activated volumes in the left pre-SMA (rho = 0.837, *P* < 0.05, Fig. 4) and left CMA (rho = 0.909, *P* < 0.01). For the latter area, the correlation coefficient was also significant with the maximum *t*-values (rho = 0.782, *P* < 0.05). For some of these regions, the scatter diagrams of the BOLD signal values as a function of MI vividness scores are displayed in Figure 4. The BOLD signal in the other cortical areas and in all subcortical regions did not correlate with the individual MI scores (all rho-values ≤ 0.514, *P* ≥ 0.09). There was no significant correlation between the individual vividness ratings in the SCI patients and the delays since SCI (all Spearman rho ≤ 0.503, *P* ≥ 0.12).

### Discussion

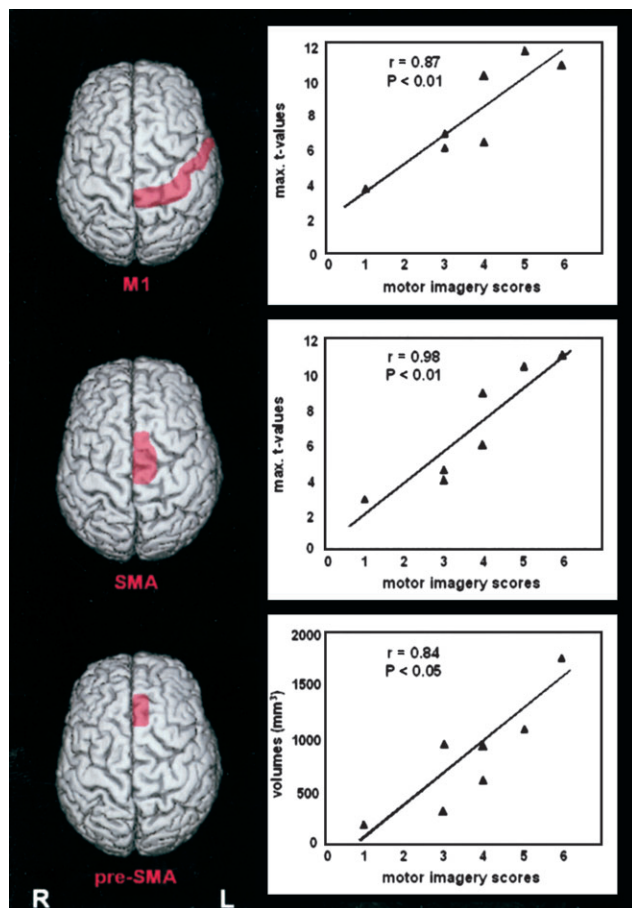
The present study reports for the first time the occurrence of strong and consistent brain activation in a large number of cortical and subcortical regions in SCI patients during MI of their disconnected feet. MI in SCI patients recruited in parallel both the ME and MI networks detected in healthy subjects, with an additional enhancement in the degree of activation. The contralateral primary motor and somatosensory foot representations were consistently activated in SCI patients, in the same location and to the same degree as in controls during ME. Both the group and the individual analysis revealed foci with unexpectedly strong BOLD signal in the putamen, caudate nucleus, thalamus, and cerebellum. A comparable consistency in subcortical activity was never documented in the healthy controls, neither during ME nor during MI. Finally, for the SCI patients the degree of brain activation in the primary motor cortex and in some non-primary motor areas was significantly correlated with the self-rated MI vividness.

### Cortical and Subcortical Correlates of MI in Healthy Subjects

The most common view on MI based on neuropsychological and imaging data postulates that the mental representation of a motor act, its preparation, and actual execution involve similar brain areas (Jeannerod, 1994). The difference between covert and overt activity is manifested at the final motor output level, which must be actively suppressed during MI (Jeannerod and Frak, 1999). This model is supported by the behavioral literature which has reported remarkable parallels between MI and ME in healthy subjects, e.g. the similar amount of time needed to mentally complete a movement (Decety and Michel, 1989), the similar physiological responses associated with physical effort (Decety *et al.*, 1991), and the constraints of MI by the same physical laws that apply to ME (Sirigu *et al.*, 1996). This view is

**Table 2**  
Number of subjects with activation clusters during motor execution and motor imagery

Functional area (Brodmann area)		Controls ( <i>n</i> = 8)		SCI patients ( <i>n</i> = 8)
		Motor execution	Motor imagery	Motor imagery
M1 (4)	Left/right	8/0	4/0	8/0
S1 (1, 2, 3)	Left/right	8/1	2/0	7/1
SMA (6)	Left/right	8/7	7/8	7/7
Pre-SMA (6)	Left/right	0/1	4/5	3/5
PMd (6)	Left/right	6/4	7/4	6/6
PMv (6, 44, 45)	Left/right	6/4	8/8	8/8
CMA (6, 24)	Left/right	7/6	3/4	6/6
Superior parietal (7)	Left/right	6/4	7/4	5/6
Inferior parietal (40)	Left/right	4/7	4/4	7/8
S2 (40, 43)	Left/right	6/8	5/5	7/8
Insula (13)	Left/right	6/4	6/2	6/6
Prefrontal (9, 46)	Left/right	0/0	7/5	7/8
Thalamus	Left/right	0/4	1/5	6/6
Putamen	Left/right	4/3	2/5	8/8
Caudate nucleus	Left/right	0/0	2/4	6/7
Cerebellum Larsell II–III	Left/right	2/8	0/1	4/5
Larsell H VIIA	Left/right	4/2	7/7	6/6



**Figure 4.** Scatter diagrams displaying the degree of activation in three cortical areas as a function of the vividness scores of motor imagery in the paraplegics. The individual motor imagery scores correlated significantly with the maximum *t*-values in the contralateral primary motor cortex (upper row) and left SMA (middle row), and with the volumes of activation in left pre-SMA (lower row).

confirmed by the present findings in healthy controls, as several central structures were recruited in parallel during MI and during ME. These include bilaterally the medial and lateral premotor and superior parietal areas and, to a lesser degree, the contralateral primary motor cortex, the putamen and thalamus. At the same time, our results confirm the existence of the previously described more specialized network underlying MI, involving pre-SMA, prefrontal areas, inferior parietal cortex and, at the subcortical level, the head of the caudate nucleus and Larsell lobules VIIA of the cerebellum bilaterally (Lotze *et al.*, 1999; Gerardin *et al.*, 2000; Hanakawa *et al.*, 2003).

#### **The Effect of SCI on the Activation Patterns during MI**

Despite the large number of behavioral and imaging investigations on MI in healthy subjects only two studies have so far assessed brain activation in SCI patients during mental simulation of foot movements (Lacourse *et al.*, 1999; Sabbah *et al.*, 2002). Sabbah *et al.* (2002) reported inconsistent fMRI activation in the primary motor cortex and in some non-primary motor areas during self-paced MI of the foot in complete SCI patients. On the basis of qualitative comparisons these authors concluded that the MI activation patterns in SCI patients only partly differed from those during ME in healthy subjects and during attempted movements in paraplegics. Lacourse *et al.*

(1999), in an investigation with event-related potentials, reported that the biphasic waveforms appearing prior to and during a button press with the foot in controls were depressed in SCI patients imagining the same movement with their paralyzed limbs. Their conclusion was that chronic deafferentation in the SCI condition leads to changes in cortical activity during MI suggesting weakened inhibitory processes. Both studies are limited by the fact that they focused on selected cortical areas and did not address the high behavioral variability in the performance of MI in both healthy and patient populations.

The present investigation extends these studies in three important aspects. First, the level of primary motor and S1 activation in the SCI patients significantly exceeded that of the controls during MI and even equaled that occurring during the execution itself. Second, we found in the SCI patients strong correlations between the degree of activation in the primary motor cortex and in some non-primary motor areas and the vividness of MI. Third, the comparison with healthy controls revealed an enhancement of activity in the whole central motor neural network, including subcortical regions.

The high degree of activation during MI of the disconnected limbs suggests that some of the observed modifications may be caused by plastic changes, resulting from the chronic lack of somatosensory feedback. Changes in cortical excitability and reorganization in chronic deafferented SCI patients have been demonstrated with TMS (Levy *et al.*, 1990; Topka *et al.*, 1991), and with fMRI (Corbetta *et al.*, 2002; Curt *et al.*, 2002) an increase of activation in the primary motor hand representation without any substantial reorganization of the gross somatotopy has been reported. In patients who had either recovered some motor function or had residual use of their body parts, volitional activation in the primary motor cortex occurred with only minimal somatotopical reorganization (Shoham *et al.*, 2001), in contrast to obvious modifications or spread to adjacent regions in S1 (Corbetta *et al.*, 2002). Effects of transient and long-term deafferentation on the organization and excitability of the motor and sensory cortex are, in contrast, very well documented after amputation in monkeys and humans (Florence and Kaas, 1995; Chen *et al.*, 1998; Ramachandran and Hirstein, 1998; Qi *et al.*, 2000) and during experimental deafferentation by ischemic nerve block in human (Schnitzler *et al.*, 1997; Ziemann *et al.*, 1998). In human, TMS investigations strongly suggest two processes: First, a transient enhancement of excitability with larger motor evoked potentials in the muscles proximal to the ischemic block occurring immediately after experimental deafferentation (Ziemann *et al.*, 1998), and second, a decrease of the motor thresholds in the case of long-term deafferentation in amputees (Chen *et al.*, 1998). Both imply that reduction of intracortical inhibition is involved in plastic changes (Jacobs and Donoghue, 1991).

It is likely that plastic changes in cortico-cortical inhibition caused by the long-term absence of sensory input to the primary motor and somatosensory cortex are the main factor contributing to the strong cortical and subcortical activity disclosed in SCI patients during MI in the present investigation. The occurrence of primary motor cortex activation in amputees imagining movements of their phantom limbs shown by fMRI leads to similar conclusions (Ersland *et al.*, 1996; Lotze *et al.*, 2001).

#### **What Disconnection Tells about MI**

Our findings in complete SCI patients, without any remaining output to the spinal cord and any sensory feedback, provide

strong evidence that MI, as a kinesthetic representation of action, is engaging a central machinery of movement (Jeannerod, 1994). This template includes most central motor structures as well as parietal and prefrontal areas bilaterally (Gerardin *et al.*, 2000), each participating to various degrees to execution and imagination (Hanakawa *et al.*, 2003).

The consistent and strong activation not only of the primary motor cortex, but also of S1 in SCI patients merits some further comments. In our healthy population, S1 activation was only detected at the individual level in two subjects and did not reach the significance level in the group analysis. The inconsistent recruitment of S1 in MI is not a new finding, but has been mentioned in a few fMRI studies (Porro *et al.*, 1996; Gerardin *et al.*, 2000). In our SCI patients, the activation clusters in the primary motor and somatosensory cortex were topographically clearly segregated, both in the individual as well as in the group analysis. They cannot be attributed to feedback from peripheral afferents as the SCI patients were completely paralyzed, and no movement could be detected during MI task performance. This activation rather suggests that the internal rehearsal of movements relies on a kinesthetic memory of the imagined body parts that may still access S1 as well as the primary motor cortex, even many years after SCI. In other sensory modalities, activation of sensory-specific cortex has been reported during retrieval of the sensory information (Frith and Dolan, 1997; Nyberg *et al.*, 2000; Wheeler *et al.*, 2000; Gandhi, 2001). Therefore, the activation of the primary somatosensory and motor cortex may depend on strong top-down processes. The existence of corollary discharges, instructing S1 on the intended movements through cortico-cortical projections even in the absence of sensory input, could be a complementary explanation for the S1 activation during MI. Corollary discharges have been evoked in several situations (for a review, see McCloskey, 1981), and the activation of the primary motor cortex and other motor regions during MI could recruit S1 through such a mechanism.

It was expected that the comparison of MI in healthy and SCI individuals would provide some insight into the structures and processes involved in the volitional movement suppression required in healthy subjects during MI (Jeannerod and Frak, 1999). If specialized brain regions were directly involved in this suppression, the subtraction of the MI activation patterns in SCI patients from those in healthy subjects should disclose potential 'inhibitory' regions. This contrast did not reveal any additional activation in the controls and thus did not confirm an earlier finding of Deiber *et al.* (1998) according to which the inferior frontal cortex would be the region responsible for motor suppression in a visuomotor MI task. In how far inputs arising from the spinal cord and modulating cortical excitability in healthy subjects may play a role in the motor suppression is still an open issue. Investigation in patients only suffering from sensory neuropathy may answer this question.

The comparisons between controls and patients revealed, however, two important new aspects. The first one is that the activation in all regions during MI was weaker in the controls than in SCI patients. The second is that the primary motor cortex was even activated in the SCI patients during MI to a similar degree as in the healthy controls during ME. Both findings strongly support the hypothesis that regions directly or indirectly connected to the spinal cord are actively suppressed in healthy controls during MI to hinder effective activation of the motor apparatus. Porro *et al.* (1996) quantified this effect

for the primary motor cortex and reported a 70% decrease of signal intensity. In contrast, in the paraplegic condition that does not require any movement suppression, such a reduction was not found. The pattern analysis of subcortical activity further supports this hypothesis. Both regions specific for MI, the putamen rostral to the anterior commissure and the head of the caudate nucleus (Gerardin *et al.*, 2000), as well as the somatotopical foot location in the caudal portion of the putamen (Lehericy *et al.*, 1998, Gerardin *et al.*, 2003) were activated. In the cerebellum, regions more specific for MI in the lobules VIIA bilaterally (Lafleur *et al.*, 2002) and the motor foot representation in the ipsilateral lobules II-III (Nitschke *et al.*, 1996) were also simultaneously active. Despite the behavioural assessment for MI performed in this study, we cannot categorically exclude that SCI patients were not able to differentiate between the mere imagination of movements and an attempt to move. However, the emphasis in our instructions on 'continuous mental monitoring' of MI clearly discouraged any focus on movement initiation. We are therefore confident that the high correlations between self-rated imagery vividness and the degree of brain activation in specific regions reflects the neural correlates of the MI process rather than the intention to move.

Similar to our study, Lotze *et al.* (2001) found in upper limb amputees during MI of the phantom hands a significant increase of contralateral primary motor and somatosensory activation. These authors also found a positive correlation between the vividness of imagined phantom hand movements and the BOLD signal intensity in these regions. They interpret this finding by the increased attention directed to the phantom limbs, as suggested by Berlucchi and Aglioti (1997). Some recent studies, demonstrating a clear enhancement in motor cortical and subcortical regions while subjects directed their attention to the required actions (Binkofski *et al.*, 2002; Rowe *et al.*, 2002), give support to this interpretation. The data of our study extend these findings to another patient population and reveal that, in addition to the primary motor cortex, correlations also exist between the MI vividness and the degree of activation in other mesial frontal motor areas bilaterally (SMA, pre-SMA, and CMA). These high correlations lead to the alternative interpretation that some specific non-primary areas are most tightly linked to the ability of mentally rehearsing movements. It is known that these cortical regions are involved in motor planning and preparation (Deiber *et al.*, 1996) as well as in the organization and memorization of movement sequences, shown in monkeys for pre-SMA (Tanji, 2001). In line with our interpretation is the consistent activation of these regions reported in several MI studies (Stephan *et al.*, 1995; Gerardin *et al.*, 2000). With respect to the high correlation found with activation of the primary motor cortex, our investigation also documents that this area is not solely involved in ME but can also be clearly involved in complex tasks engaging cognitive dimensions, as repeatedly demonstrated in behaving primates (Georgopoulos, 2000).

### **Clinical Significance**

The enduring and extensive neural network activation during MI and in particular the remaining strong representation of the disconnected limbs in the primary motor cortex of complete, paraplegic patients may have a high clinical relevance. They fulfill one of the principal physiological requirements for the development of brain-machine interfaces (Nicolelis, 2001;



Shoham *et al.*, 2001; Donoghue, 2002; Cincotti *et al.*, 2003). It should thus be possible to access voluntary control signals during MI and, by the use of neuroprosthetic devices, restore natural movements of paralyzed body parts.

### Supplementary Material

Supplementary material can be found at: <http://www.cercor.oupjournals.org/>

### Notes

This work was supported by the Swiss National Research Program NRP 38 No. 4038-052837/1, by the NCCR on Neural Plasticity and Repair, and by the Swiss National Science Foundation grant No. 31-67168.01.

Address correspondence to Spyros S. Kollias, Institute of Neuroradiology, University Hospital Zurich, Frauenklinikstr. 10, CH-8091 Zurich, Switzerland. Email: [kollias@dmr.usz.ch](mailto:kollias@dmr.usz.ch).

### References

- Abbruzzese G, Assini A, Buccolieri A, Marchese R, Trompetto C (1999) Changes of intracortical inhibition during motor imagery in human subjects. *Neurosci Lett* 263:113-116.
- Beisteiner R, Hollinger P, Lindinger G, Lang W, Berthoz A (1995) Mental representations of movements. Brain potentials associated with imagination of hand movements. *Electroencephalogr Clin Neurophysiol* 96:183-193.
- Berlucchi G, Aglioti S (1997) The body in the brain: neural bases of corporal awareness. *Trends Neurosci* 20:560-564.
- Binkofski F, Fink GR, Geyer S, Buccino G, Gruber O, Shah NJ, Taylor JG, Seitz RJ, Zilles K, Freund HJ (2002) Neural activity in human primary motor cortex areas 4a and 4p is modulated differentially by attention to action. *J Neurophysiol* 88:514-519.
- Bonnet M, Decety J, Jeannerod M, Requin J (1997) Mental simulation of an action modulates the excitability of spinal reflex pathways in man. *Cogn Brain Res* 5:221-228.
- Brasil-Neto JP, Valls-Sole J, Pascual-Leone A, Cammarota A, Amassian VE, Cracco R, Maccabee P, Cracco J, Hallett M, Cohen LG (1993) Rapid modulation of human cortical motor outputs following ischaemic nerve block. *Brain* 116:511-525.
- Brugger P, Regard M (1998) Phantom limbs in congenital tetramelia: a case report. *J Int Neuropsychol Soc* 4:206.
- Brugger P, Kollias SS, Muri RM, Crelier G, Hepp-Reymond MC, Regard M (2000) Beyond re-membering: phantom sensations of congenitally absent limbs. *Proc Natl Acad Sci USA* 97:6167-6172.
- Chapman LJ, Chapman JP (1987) The measurement of handedness. *Brain Cogn* 6:175-183.
- Chen R, Corwell B, Yaseen Z, Hallett M, Cohen LG (1998) Mechanisms of cortical reorganization in lower-limb amputees. *J Neurosci* 18:3443-3450.
- Cincotti F, Mattia D, Babiloni C, Carducci F, Salinari S, Bianchi L, Marciari MG, Babiloni F (2003) The use of EEG modifications due to motor imagery for brain-computer interfaces. *IEEE Trans Neural Syst Rehabil Eng* 11:131-133.
- Collins DL, Neelin P, Peters TM, Evans AC (1994) Automatic 3D intersubject registration of MR volumetric data in standardized Talairach space. *J Comput Assist Tomogr* 18:192-205.
- Corbetta M, Burton H, Sinclair RJ, Conturo TE, Akbudak E, McDonald JW (2002) Functional reorganization and stability of somatosensory-motor cortical topography in a tetraplegic subject with late recovery. *Proc Natl Acad Sci USA* 99:17066-17071.
- Curt A, Alkadhi H, Crelier GR, Boendermaker SH, Hepp-Reymond MC, Kollias SS (2002) Changes of non-affected upper limb cortical representation in paraplegic patients as assessed by fMRI. *Brain* 125:2567-2578.
- Dai TH, Liu JZ, Sahgal V, Brown RW, Yue GH (2001) Relationship between muscle output and functional MRI-measured brain activation. *Exp Brain Res* 140:290-300.
- Decety J, Boisson D (1990) Effect of brain and spinal cord injuries on motor imagery. *Eur Arch Psychiatry Clin Neurosci* 240:39-43.
- Decety J, Michel F (1989) Comparative analysis of actual and mental movement times in two graphic tasks. *Brain Cogn* 11:87-97.
- Decety J, Jeannerod M, Germain M, Pastene J (1991) Vegetative response during imagined movement is proportional to mental effort. *Behav Brain Res* 42:1-5.
- Deiber MP, Ibanez V, Sadato N, Hallett M (1996) Cerebral structures participating in motor preparation in humans: a positron emission tomography study. *J Neurophysiol* 75:233-247.
- Deiber MP, Ibanez V, Honda M, Sadato N, Raman R, Hallett M (1998) Cerebral processes related to visuomotor imagery and generation of simple finger movements studied with positron emission tomography. *Neuroimage* 7:73-85.
- Donoghue JP (2002) Connecting cortex to machines: recent advances in brain interfaces. *Nat Neurosci* 5(Suppl.):1085-1088.
- Ersland L, Rosen G, Lundervold A, Smievoll AI, Tillung T, Sundberg H, Hugdahl K (1996) Phantom limb imaginary fingertapping causes primary motor cortex activation: an fMRI study. *Neuroreport* 8: 207-210.
- Fadiga L, Buccino G, Craighero L, Fogassi L, Gallese V, Pavesi G (1999) Corticospinal excitability is modulated by motor imagery: a magnetic stimulation study. *Neuropsychologie* 37:147-158.
- Florence SL, Kaas JH (1995) Large-scale reorganization at multiple levels of the somatosensory pathway follows therapeutic amputation of the hand in monkeys. *J Neurosci* 15:8083-8095.
- Frith C, Dolan RJ (1997) Brain mechanisms associated with top-down processes in perception. *Philos Trans R Soc Lond B Biol Sci* 352:1221-1230.
- Gandevia SC (1999) Mind, muscles and motoneurons. *J Sci Med Sport* 2:167-180.
- Gandevia SC, Macefield VG, Bigland-Ritchie B, Gorman RB, Burke D (1993) Motoneuronal output and gradation of effort in attempts to contract acutely paralysed leg muscles in man. *J Physiol* 471: 411-427.
- Gandevia SC, Wilson LR, Inglis JT, Burke D (1997) Mental rehearsal of motor tasks recruits alpha-motoneurons but fails to recruit human fusimotor neurons selectively. *J Physiol* 15:259-266.
- Gandhi SP (2001) Memory retrieval: reactivating sensory cortex. *Curr Biol* 11:R32-R34.
- Georgopoulos AP (2000) Neural aspects of cognitive motor control. *Curr Opin Neurobiol* 10:238-241.
- Gerardin E, Sirigu A, Lehericy S, Poline JB, Gaymard B, Marsault C, Agid Y, Le Bihan D (2000) Partially overlapping neural networks for real and imagined hand movements. *Cereb Cortex* 10:1093-1104.
- Gerardin E, Lehericy S, Pochon JB, Tezenas du Montcel S, Mangin JF, Poupon F, Agid Y, Le Bihan D, Marsault C (2003) Foot, hand, face and eye representation in the human striatum. *Cereb Cortex* 13:162-169.
- Glover GH (1999) Deconvolution of impulse response in event-related BOLD fMRI. *Neuroimage* 9:416-429.
- Hanakawa T, Immisch I, Toma K, Dimyan MA, Van Gelderen P, Hallett M (2003) Functional properties of brain areas associated with motor execution and imagery. *J Neurophysiol* 89:989-1002.
- Hashimoto R, Rothwell JC (1999) Dynamic changes in corticospinal excitability during motor imagery. *Exp Brain Res* 125:75-81.
- Isaac A, Marks DF, Russell DG (1986) An instrument for assessing imagery of movement: the vividness of movement imagery questionnaire (VMIQ). *J Mental Imagery* 10:23-30.
- Jacobs KM, Donoghue JP (1991) Reshaping the cortical motor map by unmasking latent intracortical connections. *Science* 251:944-947.
- Jeannerod M (1994) The representing brain: neural correlates of motor intention and imagery. *Behav Brain Sci* 17:187-245.
- Jeannerod M, Frak V (1999) Mental imaging of motor activity in humans. *Curr Opin Neurobiol* 9:735-739.
- Johnson SH, Rotte M, Grafton ST, Hinrichs H, Gazzaniga MS, Heinze HJ (2002) Selective activation of a parietofrontal circuit during implicitly imagined prehension. *Neuroimage* 17:1693-1704.
- Kasai T, Kawai S, Kawanishi M, Yahagi S (1997) Evidence for facilitation of motor evoked potentials (MEPs) induced by motor imagery. *Brain Res* 744:147-150.
- Kiers L, Fernando B, Tomkins D (1997) Facilitatory effect of thinking about movement on magnetic motor-evoked potentials. *Electroencephalogr Clin Neurophysiol* 105:262-268.

- Kollias SS, Alkadhi H, Jaermann T, Crelier G, Hepp-Reymond MC (2001) Identification of multiple nonprimary motor cortical areas with simple movements. *Brain Res Brain Res Rev* 36:185-195.
- Lacourse MG, Cohen MJ, Lawrence KE, Romero DH (1999) Cortical potentials during imagined movements in individuals with chronic spinal cord injuries. *Behav Brain Res* 104:73-88.
- Lafleur MF, Jackson PL, Malouin F, Richards CL, Evans AC, Doyon J (2002) Motor learning produces parallel dynamic functional changes during the execution and imagination of sequential foot movements. *Neuroimage* 16:142-157.
- Larsell O, Jansen J (1972) The comparative anatomy and histology of the cerebellum: the human cerebellum, cerebellar connections, and the cerebellar cortex. Minneapolis, MN: University of Minnesota Press.
- Lehericy S, van de Moortele PF, Lobel E, Paradis AL, Vidailhet M, Frouin V, Neveu P, Agid Y, Marsault C, Le Bihan D (1998) Somatotopical organization of striatal activation during finger and toe movement: a 3-T functional magnetic resonance imaging study. *Ann Neurol* 44:398-404.
- Levy WJ Jr, Amassian VE, Traad M, Cadwell J (1990) Focal magnetic coil stimulation reveals motor cortical system reorganized in humans after traumatic quadriplegia. *Brain Res* 510:130-134.
- Lotze M, Montoya P, Erb M, Hulsmann E, Flor H, Klose U, Birbaumer N, Grodd W (1999) Activation of cortical and cerebellar motor areas during executed and imagined hand movements: an fMRI study. *J Cogn Neurosci* 11:491-501.
- Lotze M, Flor H, Grodd W, Larbig W, Birbaumer N (2001) Phantom movements and pain. An fMRI study in upper limb amputees. *Brain* 124:2268-2277.
- Luft AR, Skalej M, Stefanou A, Klose U, Voigt K (1998) Comparing motion- and imagery-related activation in the human cerebellum: a functional MRI study. *Hum Brain Mapp* 6:105-113.
- Maynard FM Jr, Bracken MB, Creasey G, Ditunno JF Jr, Donovan WH, Ducker TB, Garber SL, Marino RJ, Stover SL, Tator CH, Waters RL, Wilberger JE, Young W (1997) International standards for neurological function classification of spinal cord injury. *Spinal Cord* 35:256-274.
- McCloskey DI (1981) Corollary discharges: motor commands and perception. In: *Handbook of physiology: Section 1. The nervous system* (Brooks VB, ed.), vol. 2, pp. 1415-1447. Bethesda, MD: American Physiological Society.
- Nair DG, Purcott KL, Fuchs A, Steinberg F, Kelso JA (2003) Cortical and cerebellar activity of the human brain during imagined and executed unimanual and bimanual action sequences: a functional MRI study. *Brain Res Cogn Brain Res* 15:250-260.
- Nicolelis MA (2001) Actions from thoughts. *Nature* 409:403-407.
- Nitschke MF, Kleinschmidt A, Wessel K, Frahm J (1996) Somatotopic motor representation in the human anterior cerebellum. A high-resolution functional MRI study. *Brain* 119:1023-1029.
- Nyberg L, Habib R, McIntosh AR, Tulving E (2000) Reactivation of encoding-related brain activity during memory retrieval. *Proc Natl Acad Sci USA* 97:11120-11124.
- Porro CA, Francescato MP, Cettolo V, Diamond ME, Baraldi P, Zuiani C, Bazzocchi M, di Prampero PE (1996) Primary motor and sensory cortex activation during motor performance and motor imagery: a functional magnetic resonance imaging study. *J Neurosci* 16:7688-7698.
- Qi HX, Stepniewska I, Kaas JH (2000) Reorganization of primary motor cortex in adult macaque monkeys with long-standing amputations. *J Neurophysiol* 84:2133-2147.
- Ramachandran VS, Hirstein W (1998) The perception of phantom limbs. The D.O. Hebb lecture. *Brain* 121:1603-1630.
- Roland PE, Larsen B, Lassen NA, Skinhoj E (1980) Supplementary motor area and other cortical areas in organization of voluntary movements in man. *J Neurophysiol* 43:118-136.
- Rossini PM, Rossi S, Pasqualetti P, Tecchio F (1999) Corticospinal excitability modulation to hand muscles during movement imagery. *Cereb Cortex* 9:161-167.
- Roth M, Decety J, Raybaudi M, Massarelli R, Delon-Martin C, Segebarth C, Morand S, Gemignani A, Decors M, Jeannerod M (1996) Possible involvement of primary motor cortex in mentally simulated movement: a functional magnetic resonance imaging study. *Neuroreport* 7:1280-1284.
- Rowe J, Friston K, Frackowiak R, Passingham R (2002) Attention to action: specific modulation of corticocortical interactions in humans. *Neuroimage* 17:988-998.
- Sabbah P de SS, Leveque C, Gay S, Pfefer F, Nioche C, Sarrazin JL, Barouti H, Tadie M, Cordoliani YS (2002) Sensorimotor cortical activity in patients with complete spinal cord injury: a functional magnetic resonance imaging study. *J Neurotrauma* 19:53-60.
- Schnitzler A, Salenius S, Salmelin R, Jousmaki V, Hari R (1997) Involvement of primary motor cortex in motor imagery: a neuro-magnetic study. *Neuroimage* 6:201-208.
- Shoham S, Halgren E, Maynard EM, Normann RA (2001) Motor-cortical activity in tetraplegics. *Nature* 413:793.
- Sirigu A, Duhamel JR, Cohen L, Pillon B, Dubois B, Agid Y (1996) The mental representation of hand movements after parietal cortex damage. *Science* 271:1564-1568.
- Stephan KM, Fink GR, Passingham RE, Silbersweig D, Ceballos-Baumann AO, Frith CD, Frackowiak RS (1995) Functional anatomy of the mental representation of upper extremity movements in healthy subjects. *J Neurophysiol* 73:373-386.
- Tanji J (2001) Sequential organization of multiple movements: involvement of cortical motor areas. *Annu Rev Neurosci* 24:631-651.
- Teasdale G, Jennett B (1974) Assessment of coma and impaired consciousness. A practical scale. *Lancet* 2:81-83.
- Topka H, Cohen LG, Cole RA, Hallett M (1991) Reorganization of corticospinal pathways following spinal cord injury. *Neurology* 41:1276-1283.
- Wheeler ME, Petersen SE, Buckner RL (2000) Memory's echo: vivid remembering reactivates sensory-specific cortex. *Proc Natl Acad Sci USA* 97:11125-11129.
- Woods RP, Grafton ST, Holmes CJ, Cherry SR, Mazziotta JC (1998) Automated image registration: I. General methods and intrasubject, intramodality validation. *J Comput Assist Tomogr* 22:139-152.
- Worsley KJ, Marrett S, Neelin P, Vandal AC, Friston KJ (1996) A unified statistical approach for determining significant signals in images of cerebral activation. *Hum Brain Mapp* 4:58-73.
- Yahagi S, Kasai T (1998) Facilitation of motor evoked potentials (MEPs) in first dorsal interosseous (FDI) muscle is dependent on different motor images. *Electroencephalogr Clin Neurophysiol* 109:409-417.
- Ziemann U, Corwell B, Cohen LG (1998) Modulation of plasticity in human motor cortex after forearm ischemic nerve block. *J Neurosci* 18:1115-1123.