

<https://doi.org/10.22416/1382-4376-2023-33-3-66-75>
UDC 616.36-008.6-07



A 19-year-old Patient with Recurrent Pruritus and Jaundice

Kirill S. Nezhdanov^{1,*}, Elena N. Shirokova², Yuliya O. Shulpekova², Anna S. Ostrovskaya², Maria S. Zharkova², Vladimir T. Ivashkin²

¹ Lomonosov Moscow State University, Moscow, Russian Federation

² I.M. Sechenov First Moscow State Medical University (Sechenov University), Moscow, Russian Federation

Aim: to highlight the importance of broad differential diagnosis and possibility of conversion of benign recurrent intrahepatic cholestasis type 2 into more aggressive clinical phenotype.

Key points. A 19-year-old female patient was admitted to the Clinic with skin pruritus, jaundice, dark urine, clay-colored stool, and general fatigue. Past medical history was significant for recurrent aforementioned symptoms since 3 years old, that relapsed every 1–2 years and were usually ameliorated with conservative therapy. During recent years, frequency of relapses and recovery period increased, at the same time effectiveness of medical therapy decreased. Blood chemistry results revealed an elevation of total bilirubin (up to 634 $\mu\text{mol/L}$), direct bilirubin (up to 354 $\mu\text{mol/L}$), bile acids (up to 510 $\mu\text{mol/L}$) and normal gamma glutamyl transferase level. Workup was negative for viral hepatitis, autoimmune liver diseases, obstructive choledochal lesions, storage diseases, although mutation in gene *ABCB11* was found. Benign recurrent intrahepatic cholestasis type 2 was diagnosed. Following conservative therapy and plasmapheresis, jaundice and skin pruritus significantly diminished, levels of bilirubin and bile acids normalized. Regular follow up, liver biopsy and measures for relapse prevention given clinical features of aggressive phenotype were recommended.

Conclusion. Identification of etiology of cholestatic liver diseases requires broad differential diagnosis. Clinical course of patients with benign recurrent intrahepatic cholestasis may transform into aggressive phenotype, reminiscent of progressive familial intrahepatic cholestasis.

Keywords: cholestasis, benign recurrent intrahepatic cholestasis, progressive familial intrahepatic cholestasis, *ABCB11*, plasmapheresis, ursodeoxycholic acid

Conflict of interest: the authors declare no conflict of interest.

For citation: Nezhdanov K.S., Shirokova E.N., Shulpekova Yu.O., Ostrovskaya A.S., Zharkova M.S., Ivashkin V.T. A 19-year-old Patient with Recurrent Pruritus and Jaundice. Russian Journal of Gastroenterology, Hepatology, Coloproctology. 2023;33(3):66–75. <https://doi.org/10.22416/1382-4376-2023-33-3-66-75>

Пациентка 19 лет с рецидивирующим кожным зудом и желтухой

К.С. Нежданов^{1,*}, Е.Н. Широкова², Ю.О. Шульпекова², А.С. Островская², М.С. Жаркова², В.Т. Ивашкин²

¹ ФГБОУ ВО «Московский государственный университет имени М.В. Ломоносова», Москва, Российская Федерация

² ФГАОУ ВО «Первый Московский государственный медицинский университет им. И.М. Сеченова»

(Сеченовский Университет) Министерства здравоохранения Российской Федерации, Москва, Российская Федерация

Цель исследования: подчеркнуть важность дифференциальной диагностики при холестазах и продемонстрировать возможность перехода доброкачественного рецидивирующего внутрипеченочного холестаза 2-го типа в прогрессирующий фенотип.

Основные положения. Пациентка, 19 лет при поступлении в Клинику предъявляла жалобы на кожный зуд, желтуху, потемнение мочи, посветление кала и общую слабость. Из анамнеза известно, что данные жалобы впервые возникли в возрасте 3 лет, разрешились на фоне консервативной терапии в течение недели и рецидивировали с частотой 1 раз в 1–2 года. В последние несколько лет количество эпизодов обострения и время их разрешения увеличились, снизилась эффективность консервативной терапии. В анализах отмечались гипербилирубинемия (до 634 мкмоль/л), повышение уровня прямого билирубина (до 354 мкмоль/л) и желчных кислот (до 510 мкмоль/л) при нормальных значениях гамма-глутамилтранспептидазы. При обследовании исключены вирусные гепатиты, аутоиммунные заболевания печени, болезни накопления, поражение желчных протоков, выявлена мутация гена *ABCB11*. Установлен диагноз доброкачественного рецидивирующего внутрипеченочного холестаза 2-го типа. На фоне консервативной терапии и плазмафереза отмечен регресс желтухи, кожного зуда, нормализация уровня билирубина, желчных кислот. Планируются скрининговые мероприятия, биопсия печени, противорецидивная терапия с учетом признаков утяжеления течения доброкачественного холестаза.

Заклучение. Холестатические заболевания печени требуют проведения широкого дифференциального диагноза. Течение заболевания у пациентов с доброкачественным рецидивирующим внутрипеченочным холестазом может переходить в более тяжелую форму, характерную для прогрессирующего семейного внутрипеченочного холестаза.

Ключевые слова: холестаз, доброкачественный рецидивирующий внутрипеченочный холестаз, прогрессирующий семейный внутрипеченочный холестаз, *ABCB11*, плазмаферез, урсодезоксихолевая кислота

Конфликт интересов: авторы заявляют об отсутствии конфликта интересов.

Для цитирования: Нежданов К.С., Широкова Е.Н., Шульпекова Ю.О., Островская А.С., Жаркова М.С., Ивашкин В.Т. Пациентка 19 лет с рецидивирующим кожным зудом и желтухой. Российский журнал гастроэнтерологии, гепатологии, колопроктологии. 2023;33(3):66–75. <https://doi.org/10.22416/1382-4376-2023-33-3-66-75>

Patient A., a 19-year-old female was admitted to Clinic with skin pruritus, aggravated at nighttime, jaundice of skin and eyes, dark urine, clay-colored stool and general fatigue. Past medical history revealed similar symptoms initially manifested during childhood, when she was 3 years old (2005). She was admitted to a hospital where viral hepatitis (negative serologic markers of hepatitis A, B and C), autoimmune liver diseases (negative anti-nuclear antibodies (ANA), antimitochondrial antibodies (AMA), smooth muscle antibodies (SMA), antibodies to soluble liver antigen/liver-pancreas (SLA/LP), liver kidney microsomal antibodies (LKM)) and hereditary storage diseases (normal serum ceruloplasmin, 24-h urinary copper, alpha-1 antitrypsin and iron turnover) were excluded. The results of liver ultrasound, upper endoscopy and computed tomography of abdomen with contrast enhancement were unrevealing. Laboratory results reported a drastic elevation of total bilirubin up to 200 $\mu\text{mol/L}$ (normal values – up to 21 $\mu\text{mol/L}$), direct bilirubin – up to 125 $\mu\text{mol/L}$ (normal values – up to 6.0 $\mu\text{mol/L}$), and normal levels of liver aspartate and alanine aminotransferases (AST, ALT) and gamma glutamyl transpeptidase (GGT). Synthetic liver function was preserved (total protein and albumin within reference values) and no coagulation abnormalities were noted (normal international normalized ratio (INR) and prothrombin index). Full blood count and urinalysis were also unremarkable. At that time, she was diagnosed with cholestatic hepatitis of uncertain aetiology, treated medically with supportive therapy and improved within one week with regression of jaundice, pruritus and bilirubin levels normalization.

Differential diagnosis of cholestasis in children is broad and includes not only traditional causes of cholestatic hepatitis in adults (viral hepatitis, autoimmune liver diseases, drug induced liver injury), but also specific bile duct diseases (biliary atresia, choledochal cyst, neoplasia), endocrine disorders (hypothyroidism, hypopituitarism) and hereditary storage diseases (tyrosinemia, galactosemia, sphingolipidoses, mucopolysaccharidoses, peroxisomal diseases) [1]. Among the most prevalent causes

of cholestasis in young children (cholestasis in newborn will not be discussed) are hereditary storage diseases, infections (viral hepatitis, adenovirus, cytomegalovirus, toxoplasma), biliary diseases and idiopathic cholestasis (in up to 25 % of all cases) [2]. Considering the age of symptoms manifestation in our patient we should exclude both adults' and children's cholestasis causes. Apart from that, in the first place, we must distinguish between intrahepatic and extrahepatic cholestasis, the latter triggered by bile ducts obstruction [3]. In our patient bile duct obstruction by liver ultrasound (although magnetic resonance cholangiopancreatography was not conducted), viral and autoimmune hepatitis, hereditary storage diseases were excluded and there was no stigma of hereditary diseases. Blood workup revealed cholestasis with predominantly direct hyperbilirubinemia and normal GGT, AST and ALT values. Therefore, our patient had intrahepatic cholestasis with normal GGT values, which might have helped with the right diagnosis already at the time of first admission and will be discussed later. However, her condition was interpreted as idiopathic cholestasis.

Future disease course was characterized by similar exacerbations of cholestasis with direct hyperbilirubinemia, normal GGT, AST, ALT values and jaundice with pruritus once every 1–2 years until the year 2015. During every exacerbation viral hepatitis, autoimmune liver diseases and storage diseases were excluded, MRCP with normal intra- and extrahepatic bile ducts was conducted several times. In 2015 laparoscopic liver biopsy was performed, which revealed “intrahepatic, intracellular cholestasis and acute cholangitis in resolution stage”. Starting from 2015 ursodeoxycholic acid (UDCA) in dose 15 mg/kg/day was prescribed, although our patient did not take it on a regular basis. Subsequent disease course was highlighted by increased frequency of exacerbations, higher levels of total bilirubin (up to 400–500 $\mu\text{mol/L}$) during cholestasis and longer recovery periods. In 2017 a proposition of a genetic basis of disease was suggested and genetic analysis for mutations in *ABCB11* gene, associated with benign recurrent intrahepatic

cholestasis (BRIC) type 2 and progressive familial intrahepatic cholestasis (PFIC) type 2, was positive.

One of the most important diagnostic clinical clues of cholestasis in children and adults is GGT levels, which allows distinction of cholestasis with normal GGT levels (BRIC, PFIC1–2, inborn defects of bile acid synthesis, Dubin – Johnson and Rotor syndromes, USP35 cholestasis, arthrogyriposis – renal dysfunction – cholestasis) and increased GGT levels (biliary atresia, Alagille syndrome, sclerosing cholangitis, alpha-1 antitrypsin deficiency, PFIC 3, cystic fibrosis, viral hepatitis, drug induced liver injury, citrin deficiency, etc.) [4]. Every exacerbation of cholestasis in our patient was characterized by direct hyperbilirubinemia and normal GGT values, which substantially narrows differential diagnosis down to hereditary intrahepatic cholestasis. The results of liver biopsy were also required to exclude storage and metabolic diseases (specifically inclusions in macrophages), congenital fibrosis. Thereafter MRCP confirmed patency of bile ducts and diagnosis of intrahepatic cholestasis. The essential diagnostic part was genetic evaluation for mutations in genes, associated with hereditary cholestatic diseases [5, 6]. Transport proteins of bile acids and other molecules, associated with hereditary intrahepatic cholestasis are presented in Figure 1. Genetic evaluation allows confirmation of diagnosis and conduction of differential diagnosis among other forms of hereditary intrahepatic cholestasis. Identification of mutated genes and cholestasis type provides valuable information, predicting possibility of response to medical therapy, prognosis, risk of hepatocellular carcinoma (HCC) and orthotopic liver transplantation (OLT) necessity [7]. Our patient had mutations in the ABCB11 gene, associated with BRIC2 and PFIC2. Discussion of clinical diagnosis is provided below.

During ordinary bout of cholestasis with jaundice and pruritus our patient A. was admitted to the Clinic for medical therapy, liver function evaluation, confirmation of diagnosis, prognosis, and further treatment determination.

Anamnesis vitae and anamnesis morbi were unremarkable: patient A. was born in 2002, lived in favourable socio-economic conditions without any milestone lags or significant diseases throughout childhood, except for rubella and chickenpox, did not consume alcohol or smoke and didn't have any allergies. Menarche was at the age of 13, menstrual cycle was non-regular, 32–42 days with heavy menses, nulligravida. She did not recall any chronic diseases in her family – mother of 48 years old and father of 52 years old were healthy, grandparents also did not have any liver diseases.

When considering a possibility of hereditary cholestatic diseases, the crucial part in patient evaluation is careful meticulous history taking, with special attention to growth retardation during childhood and family history. Hereditary cholestatic diseases might cause growth retardation, which serves as an important clinical clue and influences prognosis [8]. The results of the studies demonstrated that children with growth retardation have less favourable prognosis in comparison with children with normal development. Hereditary metabolic and storage diseases, cholestatic diseases usually follow autosomal-recessive pattern of inheritance, which signifies a manifestation of a disease in parents or in children [9]. Our patient did not have any milestones delays, which confirms a benign disease course, and has an unremarkable family history, which indicates a recessive pattern of inheritance.

Physical examination revealed stable general status, jaundiced dried skin and mucous membranes, marks from scratches on an anterior surface of right and left shins. BMI – 24 kg/m², temperature – 36,6 °C, no peripheral lymphadenopathy. Cardiovascular examination was unremarkable with normal S1, S2 and rhythm, no murmurs or rubs, heart rate – 75 bpm, and blood pressure – 118/80 mmHg. Pulmonary auscultation was also unremarkable with normal breathing sounds and clear lungs bilaterally, respiratory rate – 16 per minute. The abdomen was soft, non-tender in all quadrants during palpation, non-distended, liver size within normal limits, no splenomegaly and ascites, negative peritoneal signs. Stool was clay-colored, regular, 3–4 by Bristol scale, no pathologic inclusions. No dysuria signs with unremarkable kidney percussion.

Therefore, considering implementation of BRIC criteria, proposed by A. Velimir et al. (Table 1), anamnesis morbi, preserved synthetic liver function and results of the genetic investigation (mutation of ABCB11 gene) our patient was initially diagnosed with benign recurrent intrahepatic cholestasis type 2 [10].

During admission full blood count, coagulation parameters, urinalysis and stool studies were unremarkable. Complete metabolic panel revealed increased levels of total bilirubin 185 umol/L (normal levels – up to 21 umol/L), direct bilirubin – 88 umol/L (normal levels – up to 5.1 umol/L), bile acids – 120 umol/L (normal levels – up to 10 umol/L), AST – 49 U/L (normal levels – up to 34 U/L), ALT – 64 U/L (normal levels – up to 49 U/L) with normal values of GGT, albumin, ceruloplasmin, lactate dehydrogenase (LDH), total cholesterol and iron turnover.

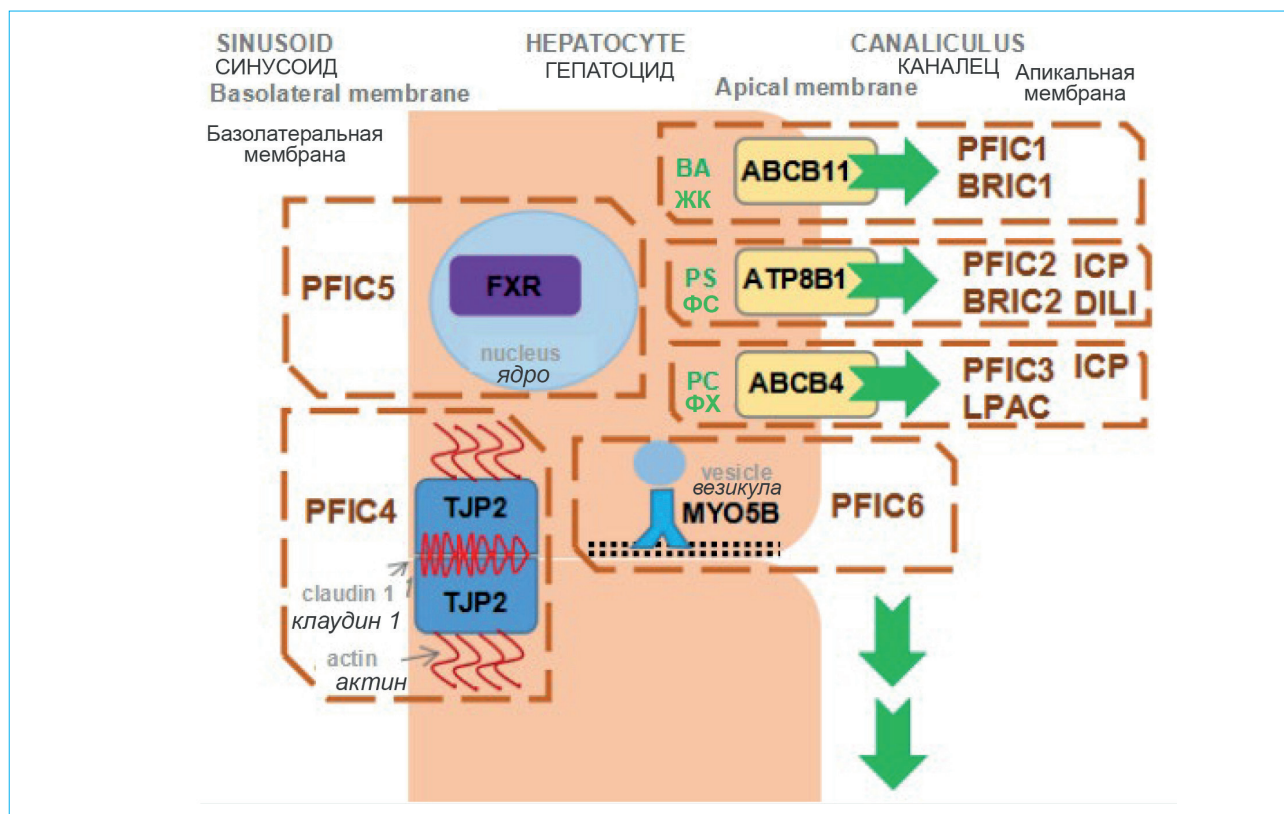


Figure 1. Transport proteins of bile acids, bilirubin and other substances, which together comprise the bile, and diseases, associated with them. *ABCB11* – ATP-binding cassette, sub-family B member 11; *ATP8B1* – ATPase Phospholipid, Transporting 8B1; *ABCB4* – ATP-binding cassette, sub-family B member 4; TJP2 – tight junction protein 2; FXR – farnesoid X receptor; MYO5B – myosin V type protein. Diseases, associated with transporters and other proteins, highlighted by dotted frames. PFIC – progressive familial intrahepatic cholestasis; BRIC – benign recurrent intrahepatic cholestasis; ICP – intrahepatic cholestasis of pregnancy; LPAC – low phospholipid associated cholestasis; DILI – drug induced liver injury; BA – bile acids; PS – phosphatidylserine; PC – phosphatidylcholine

Рисунок 1. Белки-транспортеры желчных кислот, билирубина и других веществ, входящих в состав желчи, и связанные с ними заболевания. *ABCB11* (ATP-binding cassette, sub-family B member 11), *ATP8B1* (ATPase Phospholipid Transporting 8B1), *ABCB4* (ATP-binding cassette, sub-family B member 4) – белки-транспортеры желчных кислот, фосфатидилсерина и фосфатидилхолина соответственно; TJP2 (tight junction protein 2) – белок, входящий в состав плотного контакта между клетками; FXR (farnesoid X receptor) – ядерный рецептор желчных кислот, регулирующий активность генов; MYO5B (myosin VB) – транспортный белок миозин. Пунктирной рамкой обозначены заболевания, связанные с транспортерами и другими белками. PFIC – прогрессирующий семейный внутрипеченочный холестаз; BRIC – доброкачественный рецидивирующий внутрипеченочный холестаз; ICP – внутрипеченочный холестаз беременных; LPAC – холелитиаз, ассоциированный с низкими фосфолипидами; DILI – лекарственно-индуцированное поражение печени; ЖК – желчные кислоты; ФС – фосфатидилсерин; ФХ – фосфатидилхолин

Abdominal ultrasound demonstrated insignificant liver enlargement with increased parenchymal echogenicity, normal diameter of portal and splenic veins and no ascites. More than that no esophageal varices were identified on upper endoscopy, gastric and duodenal mucosa was unaltered, Vater's papilla looked normal, though a little duodenogastric bile reflux was noted.

Differential diagnosis of cholestatic syndrome should be guided not only by an increase in alkaline phosphatase and GGT, but also by other markers of jaundice – bilirubin fractions

predominance and levels of bile acids. In particular, patients with BRIC usually have primarily direct hyperbilirubinemia with elevation of bile acids, caused by alteration of bile acid transporters. Interestingly, patients with PFIC too have increased values of direct bilirubin and bile acids, though in bile acid synthesis defects levels of bile acids usually stays normal or diminishes [11]. Nonetheless, some patients with BRIC have increased levels of indirect bilirubin, which prompts exclusion of other aetiologies. Indirect hyperbilirubinemia may be caused by

Table 1. Diagnostic criteria of benign recurrent intrahepatic cholestasis (all criteria should be fulfilled)
Таблица 1. Критерии диагноза доброкачественного рецидивирующего внутрипеченочного холестаза (требуется соблюдение всех критериев)

Diagnostic criteria of benign recurrent intrahepatic cholestasis Критерии диагноза доброкачественного рецидивирующего внутрипеченочного холестаза
<ul style="list-style-type: none"> – at least two episodes of jaundice separated by a symptom-free interval lasting several months to years; – laboratory values consistent with intrahepatic cholestasis; – severe pruritus secondary to cholestasis; – liver histology demonstrating centrilobular cholestasis; – normal intrahepatic and extrahepatic bile ducts confirmed by cholangiography; – absence of factors known to be associated with cholestasis. <ul style="list-style-type: none"> – не менее двух эпизодов желтухи с асимптоматичным периодом от месяцев до года; – лабораторная картина холестаза; – выраженный кожный зуд; – отсутствие структурной патологии внутри- и внепеченочных желчных протоков по МРХПГ; – центролобулярный холестаз по гистологии; – отсутствие других причин, объясняющих холестаз.

increased production of bilirubin (in haemolysis autoimmune or Coombs-negative, related to hemoglobinopathies, fermentopathies, erythrocyte membrane defects), impaired bilirubin uptake (congestive heart failure, vascular malformations) and altered conjugation of bilirubin in liver (Gilbert's syndrome and Crigler – Najjar syndrome type 1 and 2) [6]. In adult patients primarily anaemia with increased reticulocyte index of more than 2.5, increased LDH, decreased haptoglobin, abnormal erythrocytes (schistocytes, spherocytes) and hemosiderinuria [12]. Our patient during exacerbation episodes never had any signs of haemolysis, as in current admission. Most probably, indirect hyperbilirubinemia might be explained by transient hepatocyte and transport protein dysfunction, associated with bilirubin metabolism. Apart from that, high levels of bilirubin may destabilize erythrocyte membrane and cause haemolysis [13].

Consequently, considering anamnesis morbi, patient's complaints, results of physical examination and additional methods of evaluation, in accordance with the guidelines on diagnostics and treatment of cholestasis by Russian Gastroenterological Association (RGA) in conjunction with Russian Society for the Study of the Liver Diseases (RSSLD) [4] and guidelines on management of cholestatic liver diseases by European Association for the Study of the Liver (EASL) [14], our patient was diagnosed with benign recurrent intrahepatic cholestasis type 2 (BRIC2).

Supportive therapy and UDCA 750 mg/day were initiated on admission. However, despite aforementioned therapy during first days of admission skin pruritus and jaundice substantially increased, which prompted management with plasmapheresis. It took 6 sessions of plasmapheresis for almost complete resolution of symptoms and only after the 4th session a positive

dynamic in clinical (skin pruritus and jaundice) and laboratory (bilirubin, bile acids) parameters became obvious. It should be noted that during admission maximal levels of total bilirubin was 634 $\mu\text{mol/L}$, direct bilirubin – 354 $\mu\text{mol/L}$, bile acids – 510 $\mu\text{mol/L}$, transient coagulation disorders (INR – 1.57) which suggested severity of BRIC2 exacerbation episode. Dynamics of major clinical and laboratory parameters during hospitalization are depicted in Figure 2. After plasmapheresis cessation, UDCA, and supportive therapy completion our patient was discharged in a satisfactory condition.

Based on the results of the studies of our colleagues, therapy in BRIC should focus on pruritus alleviation with UDCA, cholestyramine, rifampicin and, if ineffective, nasobiliary drainage [15]. PFIC therapy is usually more aggressive, where bypass operations and OLT might be a necessity [16]. Considering our patient had intensifying jaundice and pruritus with an elevation of cholestatic biochemical activity we decided to conduct a plasmapheresis, which, with concurrent medical therapy, resulted in symptoms improvement. Further treatment is listed below.

Discussion

Hereditary intrahepatic cholestasis comprises a group of diseases characterized by mutation in genes, associated with function of bilirubin and bile acids transport proteins, that results in recurrent cholestatic bouts with hyperbilirubinemia with primarily direct hyperbilirubinemia and elevation in bile acids [15]. This group includes BRIC type 1 and 2, PFIC types 1–6 and other rare diseases (cholestasis in Greenland Eskimo) [17]. Hereditary intrahepatic cholestasis rarely encountered in general population, inherited via autosomal-recessive pathway, and usually manifest

in childhood [4]. Patients with BRIC almost always have benign clinical course with no permanent liver damage, whereas patients with PFIC will inevitably develop liver cirrhosis and require bile duct bypass surgery or OLT [18]. Some patients with PFIC have extrahepatic manifestations, such as diarrhea, pancreatitis in PFIC type 1 and cholelithiasis in PFIC type 2 [19].

BRIC is a subtype of hereditary cholestatic diseases and is characterized by recurrent episodes of skin pruritus, jaundice, and direct hyperbilirubinemia with bile acid elevation without development of liver fibrosis and cirrhosis. It should be noted that GGT levels are usually within normal limits. The disease usually manifests in newborns and young children (as in our patient), which justifies broad differential diagnosis with other cholestatic diseases in children [20].

Although BRIC usually does not cause severe fibrosis and cirrhosis, there are some case reports of transformation of BRIC into more aggressive phenotype, taking into account similar genetic basis. For example, in one study authors describe

BRIC transformation after 15–20 years from the diagnosis [21]. The authors declared fibrosis and cirrhosis development by histological analysis, despite the fact that initially patients' parenchyma was normal. Several patients eventually required surgery and/or OLT, meanwhile the rest of them were treated medically. In another study the authors describe the case of BRIC transformation into more aggressive phenotype, typical for PFIC [22]. Interestingly, in all these works, authors stressed out that patients with phenotype transformation from "benign" to "progressive" had unique mutations in genes. Nonetheless, diagnostic significance of these mutations is uncertain.

It is well known that fibrosis and cirrhosis during progression from BRIC to PFIC may develop due to prooxidant dose-dependant effect of bilirubin in hepatocytes, that induces lipid peroxidation cascade and hepatocyte apoptosis [23]. Bile acids may too have toxic effects by triggering necrosis and apoptosis of hepatocytes, stellate cells conversion into myofibroblasts and activation of the latter with growth factors, Toll-like receptors

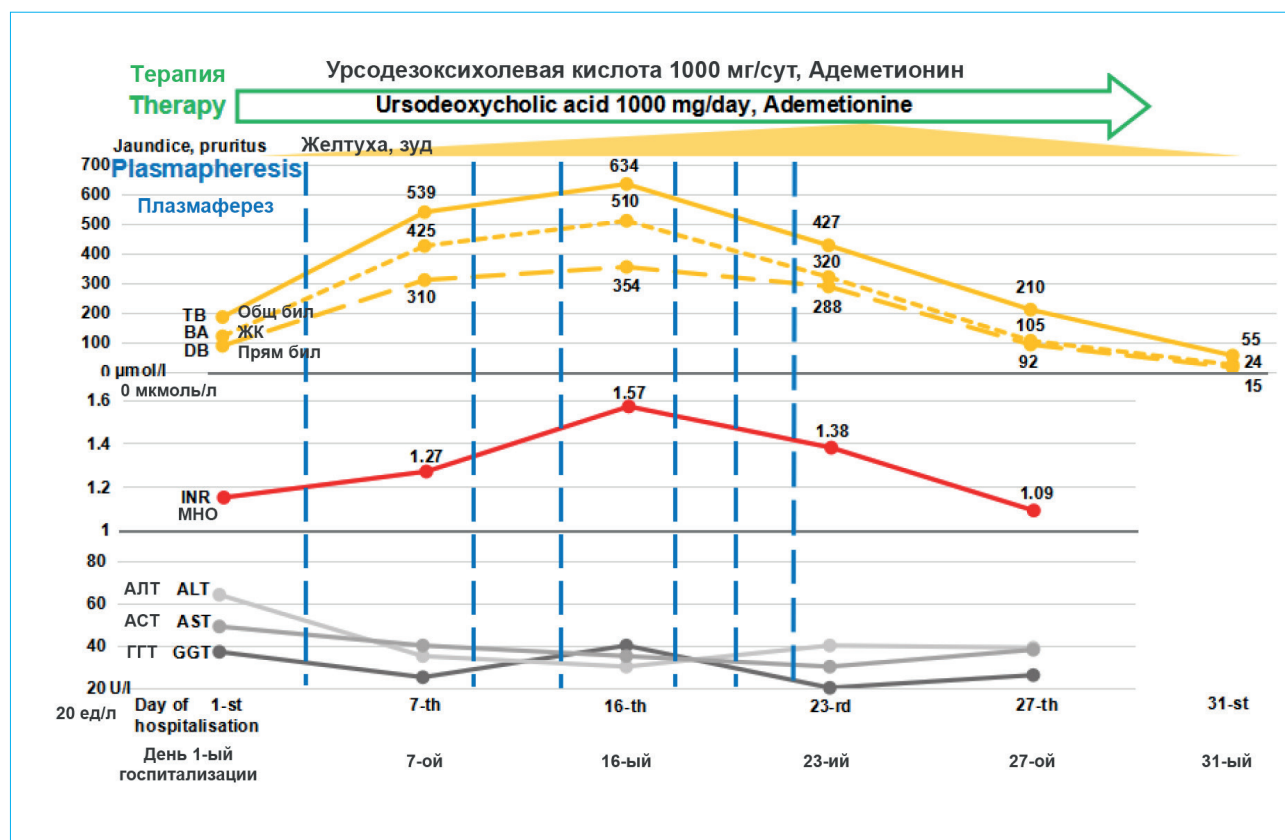


Figure 2. Major clinical and laboratory parameters during admission. TB – total bilirubin; BA – bile acids; DB – direct bilirubin; INR – international normalized ratio; ALT – alanine aminotransferase; AST – aspartate aminotransferase; GGT – gamma glutamyl transferase

Рисунок 2. Динамика основных клинических и лабораторных параметров в ходе госпитализации. Общ. бил. – общий билирубин; ЖК – желчные кислоты; Прямы. бил. – прямой билирубин; МНО – международное нормализованное отношение; АЛТ – аланинаминотрансфераза; АСТ – аспаратаминотрансфераза; ГГТ – гамма-глутамилтранспептидаза

and fibrogenesis [24]. Therefore, BRIC and PFIC may represent the spectrum of the same disease but with different severity. It might be promising to identify criteria of phenotype progression and risk factors, predicting transformation of the phenotype into progressive one in patients with BRIC.

Considering increase in severity and frequency of exacerbations (up to 2 bouts per year), more protracted resolution of exacerbations with transient coagulopathy (including current admission), intensification of skin pruritus and higher levels of bilirubin during exacerbations (600 $\mu\text{mol/L}$ during current admission), ineffectiveness of standard medical therapy and plasmapheresis necessity, we suspect transformation of BRIC into more aggressive phenotype resembling PFIC. Interestingly, since diagnosis of BRIC in 2005 till transformation of phenotype 15 years passed, that complies with studies results [21].

Future medical tactic is provided below:

– regular screening: implementation of abdominal ultrasound and alpha-fetoprotein analysis every 6 months for liver neoplasm screening, taking into account patients with PFIC2 and ABCB11 mutations may have an increased hepatocellular carcinoma risk;

– liver biopsy execution during remission period for evaluation of fibrotic changes and future prognosis.

In accordance with the clinical guidelines on diagnostics and treatment of cholestasis of RGA in collaboration with RSSLD, EASL guidelines therapy with UDCA was initiated, with future discussion on combined treatment with cholestyramine + UDCA [4, 14], taking into account published results of long-term remission on this therapy [25, 26];

– continuous intake of UDCA (hydrophilic bile acid) 15 mg/kg/day. It is suggested that UDCA exerts positive effects via choleric (by post-transcription mechanics, increasing synthesis and inclusion in membrane transport proteins), cytoprotective (by modifying bile mixture, lowering hydrophobic bile acids and their damage), antiapoptotic (by apoptosis suppression in mitochondria) and gut microbiota modification (by decreasing inflammatory markers) actions [27, 28]. On top of it, there are some positive published results of UDCA management in hereditary cholestasis [29];

– long-term cholestyramine (ion exchange resin) treatment is planned in the future with maximal tolerated dose in pruritus exacerbations. Cholestyramine, while binding most of bile acids, prevents enterohepatic circulation of bile acids, which in excessive amounts contribute to hepatocyte dysfunction, jaundice, and skin pruritus deterioration [30, 31]. More than that, some published studies with positive outcomes advocate for cholestyramine treatment [32].

Conclusion

We submitted an original case with representation of broad differential diagnosis of cholestatic syndrome, description of transmission from “benign” intrahepatic cholestasis phenotype to more aggressive, “malignant” phenotype more reminiscent of progressive intrahepatic cholestasis and its therapy. Our clinical case stresses the importance of vast differential diagnosis of cholestatic syndrome, demonstrates the significance of regular follow up and compliance with the guidelines on diagnostics and treatment of cholestasis by RGA in conjunction with RSSLD.

References / Литература

1. *Brumbaugh D., Mack C.* Conjugated hyperbilirubinemia in children. *Pediatr Rev.* 2012;33(7):291–302. DOI: 10.1542/pir.33-7-291
2. *Karpen S.J.* Pediatric cholestasis: Epidemiology, genetics, diagnosis, and current management. *Clin Liver Dis (Hoboken).* 2020;15(3):119–5. DOI: 10.1002/cld.895
3. *Вольнец Г.В., Намазова-Баранова Л.С., Потанов А.С., Георгян А.И., Смирнов И.Е., Никитин А.В. и др.* Особенности ранней диагностики прогрессирующего семейного внутрипеченочного холестаза. *Российский педиатрический журнал.* 2016;19(6):332–8. [Volynets G.V., Namazova-Baranova L.S., Potanov A.S., Gevorgyan A.K., Smirnov I.E., Nikitin A.V., et al. Features of early diagnosis of progressive familial intrahepatic cholestasis (PFIC). *Russian Pediatric Journal.* 2016;19(6):332–8 (In Russ.)]. DOI: 10.18821/1560-9561-2016-19-6-332-338
4. *Ивашкин В.Т., Широква Е.Н., Маевская М.В., Павлов Ч.С., Шифрин О.С., Маев И.В. и др.* Клинические рекомендации Российской гастроэнтерологической ассоциации и Российского общества по изучению печени по диагностике и лечению холестаза. *Российский журнал гастроэнтерологии, гепатологии, колопроктологии.* 2015;2(25):41–57. [Ivashkin V.T., Shirokova E.N., Mayevskaya M.V., Pavlov Ch.S., Shifrin O.S., Maev I.V., et al. Clinical guidelines of the Russian gastroenterological association and the Russian society on study of the liver on diagnostics and treatment of cholestasis. *Russian Journal of Gastroenterology, Hepatology, Coloproctology.* 2015;2(25):41–57 (In Russ.)].
5. *Alrefai W.A., Gill R.K.* Bile acid transporters: Structure, function, regulation and pathophysiological implications. *Pharm Res.* 2007;24(10):1803–23. DOI: 10.1007/s11095-007-9289-1
6. *Feverly J.* Bilirubin in clinical practice: A review. *Liver Int.* 2008;28(5):592–605. DOI: 10.1111/j.1478-3231.2008.01716.x
7. *Mehta S., Kumar K., Bhardwaj R., Malhotra S., Goyal N., Sibal A.* Progressive familial intrahepatic cholestasis: A study in children from a Liver Transplant Center in India. *J Clin Exp Hepatol.* 2022;12(2):454–60. DOI: 10.1016/j.jceh.2021.06.006
8. *Baker A., Kerkar N., Todorova L., Kamath B.M., Houwen R.H.J.* Systematic review of progressive familial intrahepatic cholestasis. *Clin Res Hepat Gastroenterol.* 2019;43(1):20–36. DOI: 10.1016/j.clinre.2018.07.010
9. *Pampols T.* Inherited metabolic rare disease. In: Posada De La Paz M., Groft S.C. (Eds). Rare diseases epidemiology. *Advances in Experimental Medicine and Biology.* 2010;686:397–431. DOI: 10.1007/978-90-481-9485-8_23
10. *Luketic V.A., Shiffman M.L.* Benign recurrent intrahepatic cholestasis. *Clin Liver Dis.* 1999;3(3):509–28. DOI: 10.1016/s1089-3261(05)70083-0
11. *Chen HL, Wu SH., Hsu SH., Liou BY., Chen HL., Chang MH.* Jaundice revisited: Recent advances in the diagnosis and treatment of inherited cholestatic liver diseases. *J Biomed Sci.* 2018;25(1):75. DOI: 10.1186/s12929-018-0475-8
12. *Phillips J., Henderson A.C.* Hemolytic anemia: Evaluation and differential diagnosis. *Am Fam Physician.* 2018;98(6):354–61.
13. *Brites D., Silva R., Brito A.* Effect of bilirubin on erythrocyte shape and haemolysis, under hypotonic, aggregating or non-aggregating conditions, and correlation with cell age. *Scand J Clin Lab Invest.* 1997;57(4):337–49. DOI: 10.3109/00365519709099407
14. *European Association for the Study of the Liver.* EASL Clinical Practice Guidelines: Management of cholestatic liver diseases. *J Hepatol.* 2009;51(2):237–67. DOI: 10.1016/j.jhep.2009.04.009
15. *Stapelbroek J.M., van Erpecum K.J., Klomp L.W.J., Houwen R.H.J.* Liver disease associated with canalicular transport defects: Current and future therapies. *J Hepatol.* 2010;52(2):258–71. DOI: 10.1016/j.jhep.2009.11.012
16. *Masahata K., Ueno T., Bessho K., Kodama T., Tsukada R., Saka R., et al.* Clinical outcomes of surgical management for rare types of progressive familial intrahepatic cholestasis: A case series. *Surg Case Reports.* 2022;8(1):10. DOI: 10.1186/s40792-022-01365-1
17. *Vinayagamorthy V., Srivastava A., Sen Sarma M.* Newer variants of progressive familial intrahepatic cholestasis. *World J Hepatol.* 2021;13(12):2024–38. DOI: 10.4254/wjh.v13.i12.2024
18. *Bull L.N., Thompson R.J.* Progressive familial intrahepatic cholestasis. *Clin Liver Dis.* 2018;22(4):657–69. DOI: 10.1016/j.cld.2018.06.003
19. *Amer S., Hajira A.* A comprehensive review of Progressive Familial Intrahepatic Cholestasis (PFIC): Genetic disorders of hepatocanalicular transporters. *Gastroenterology Res.* 2014;7(2):39–43. DOI: 10.14740/gr609e
20. *Folvik G., Hilde O., Helge G.O.* Benign recurrent intrahepatic cholestasis: Review and long-term follow-up of five cases. *Scand J Gastroenterol.* 2012;47(4):482–8. DOI: 10.3109/00365521.2011.650191
21. *van Ooteghem N.A.M., Klomp L.W.J., van Berge-Henegouwen G.P., Houwen R.H.J.* Benign recurrent intrahepatic cholestasis progressing to progressive familial intrahepatic cholestasis: Low GGT cholestasis is a clinical continuum. *J Hepatol.* 2002;36(3):439–43. DOI: 10.1016/S0168-8278(01)00299-9
22. *Pawlikowska L., Strautnieks S., Jankowska I., Czubkowski P., Emerick K., Antoniou A., et al.* Differences in presentation and progression between severe FIC1 and BSEP deficiencies. *J Hepatol.* 2011;53(1):170–8. DOI: 10.1016/j.jhep.2010.01.034
23. *Bianco A., Dvořák A., Capková N., Gironde C., Tiribelli C., Furger C., et al.* The extent of intracellular accumulation of bilirubin determines its anti- or pro-oxidant effect. *Int J Mol Sci.* 2020;21(21):8101. DOI: 10.3390/ijms21218101
24. *Pereira T.N., Walsh M.J., Lewindon P.J., Ramm G.A.* Paediatric cholestatic liver disease: Diagnosis, assessment of disease progression and mechanisms of fibrogenesis. *World J Gastrointest Pathophysiol.* 2010;1(2):69–84. DOI: 10.4291/wjgp.v1.i2.69
25. *Koukouliti E., Ziagaki A., Weber S.N., Lamert F., Berg T.* Long-term colestyramine treatment prevents cholestatic attacks in refractory benign re-

- current intrahepatic cholestasis type 1 disease. *Hepatology*. 2021;74(1):522–4. DOI: 10.1002/hep.31671
26. Düll M.M., Kremer A.E. Newer approaches to the management of pruritus in cholestatic liver disease. *Curr Hepatol Reports*. 2020;19(2):86–95. DOI: 10.1007/s11901-020-00517-x
27. Beuers U. Drug insight: Mechanisms and sites of action of ursodeoxycholic acid in cholestasis. *Nat Clin Pract Gastroenterol Hepatol*. 2006;3(6):318–28. DOI: 10.1038/ncpgasthep0521
28. Kim D.J., Yoon S., Ji S.C., Yang J., Kim Y.K., Lee S., et al. Ursodeoxycholic acid improves liver function via phenylalanine/tyrosine pathway and microbiome remodelling in patients with liver dysfunction. *Sci Rep*. 2018;8(1):11874. DOI: 10.1038/s41598-018-30349-1
29. Suzuki H., Arinaga-Hino T., Sano T., Mihara Y., Kusano H., Mizuochi T., et al. Case report: A rare case of benign recurrent intrahepatic cholestasis-type 1 with a novel heterozygous pathogenic variant of *ATP8B1*. *Front Medicine (Lausanne)*. 2022;9:891659. DOI: 10.3389/fmed.2022.891659
30. Rust C., Sauter G.H., Oswald M., Büttner J., Kullak-Ublick G.A., Paumgartner G., et al. Effect of cholestyramine on bile acid pattern and synthesis during administration of ursodeoxycholic acid in man. *Eur J Clin Invest*. 2000;30(2):135–9. DOI: 10.1046/j.1365-2362.2000.00606.x
31. Kriegermeier A., Green R. Pediatric cholestatic liver disease: Review of bile acid metabolism and discussion of current and emerging therapies. *Front Med (Lausanne)*. 2020;7:149. DOI: 10.3389/fmed.2020.00149
32. Kumar P., Charaniya R., Ahuja A., Mittal S., Sahoo R. Benign recurrent intrahepatic cholestasis in a young adult. *J Clin Diagn Res*. 2016;10(6):OD01–2. DOI: 10.7860/JCDR/2016/18917.7924

Information about the authors

Kirill S. Nezhdanov* — Internal Medicine Physician, Gastroenterologist, Postgraduate, Faculty of Medicine, Lomonosov Moscow State University.
Contact information: cyril.nezhdanov@gmail.com; 117192, Moscow, Lomonosovsky ave., 27, build. 1.
ORCID: <https://orcid.org/0000-0001-9558-363X>

Elena N. Shirokova — Dr. Sci. (Med.), Professor at the Department of Propaedeutics of Internal Diseases, Gastroenterology and Hepatology, I.M. Sechenov First Moscow State Medical University (Sechenov University).
Contact information: shirokova_e_n@staff.sechenov.ru; 119435, Moscow, Pogodinskaya str., 1, bld. 1.
ORCID: <https://orcid.org/0000-0002-6819-0889>

Yulia O. Shulpekova — Cand. Sci. (Med.), Associate Professor at the Department of Propaedeutics of Internal Disease, Gastroenterology and Hepatology, I.M. Sechenov First Moscow State Medical University (Sechenov University).
Contact information: shulpekova_yu_o@staff.sechenov.ru; 119435, Moscow, Pogodinskaya str., 1, bld. 1.
ORCID: <https://orcid.org/0000-0002-5563-6634>

Anna S. Ostrovskaya — Physician of the Department of Hepatology, Vasilenko Clinic of Internal Disease Propaedeutics, Gastroenterology and Hepatology, I.M. Sechenov First Moscow State Medical University (Sechenov University).
Contact information: ostrovskaya_a_s@staff.sechenov.ru; 119435, Moscow, Pogodinskaya str., 1, bld. 1.
ORCID: <https://orcid.org/0000-0002-9152-1279>

Сведения об авторах

Нежданов Кирилл Сергеевич* — врач-терапевт, гастроэнтеролог, аспирант кафедры внутренних болезней факультета фундаментальной медицины ФГБОУ ВО «Московский государственный университет имени М.В. Ломоносова».
Контактная информация: cyril.nezhdanov@gmail.com; 119192, г. Москва, Ломоносовский пр., 27, корп. 1.
ORCID: <https://orcid.org/0000-0001-9558-363X>

Широкова Елена Николаевна — доктор медицинских наук, профессор кафедры пропедевтики внутренних болезней, гастроэнтерологии и гепатологии ФГАОУ ВО «Первый Московский государственный медицинский университет им. И.М. Сеченова» (Сеченовский Университет) Министерства здравоохранения Российской Федерации.
Контактная информация: shirokova_e_n@staff.sechenov.ru; 119435, г. Москва, ул. Погодинская, 1, стр. 1.
ORCID: <https://orcid.org/0000-0002-6819-0889>

Шульпекова Юлия Олеговна — кандидат медицинских наук, доцент кафедры пропедевтики внутренних болезней, гастроэнтерологии и гепатологии ФГАОУ ВО «Первый Московский государственный медицинский университет им. И.М. Сеченова» (Сеченовский Университет) Министерства здравоохранения Российской Федерации.
Контактная информация: shulpekova_yu_o@staff.sechenov.ru; 119435, г. Москва, ул. Погодинская, 1, стр. 1.
ORCID: <https://orcid.org/0000-0002-5563-6634>

Островская Анна Сергеевна — врач отделения гепатологии Клиники пропедевтики внутренних болезней, гастроэнтерологии, гепатологии им. В.Х. Василенко ФГАОУ ВО «Первый Московский государственный университет им. И.М. Сеченова» (Сеченовский Университет) Министерства здравоохранения Российской Федерации.
Контактная информация: ostrovskaya_a_s@staff.sechenov.ru; 119435, г. Москва, ул. Погодинская, 1, стр. 1.
ORCID: <https://orcid.org/0000-0002-9152-1279>

* Corresponding author / Автор, ответственный за переписку

Maria S. Zharkova — Cand. Sci. (Med.), Head of the Department of Hepatology, Vasilenko Clinic of Internal Disease Propaedeutics, Gastroenterology and Hepatology, I.M. Sechenov First Moscow State Medical University (Sechenov University).

Contact information: zharkovamaria@mail.ru;
119435, Moscow, Pogodinskaya str., 1, bld. 1.
ORCID: <https://orcid.org/0000-0001-5939-1032>

Vladimir T. Ivashkin — Dr. Sci. (Med.), Academician of the Russian Academy of Sciences, Professor, Head of the Department of Internal Disease Propaedeutics, I.M. Sechenov First Moscow State Medical University (Sechenov University)

Contact information: ivashkin_v_t@staff.sechenov.ru;
119435, Moscow, Pogodinskaya str., 1, bld. 1.
ORCID: <https://orcid.org/0000-0002-6815-6015>

Жаркова Мария Сергеевна — кандидат медицинских наук, заведующая отделением гепатологии Клиники пропедевтики внутренних болезней, гастроэнтерологии, гепатологии им. В.Х. Василенко ФГАОУ ВО «Первый Московский государственный медицинский университет им. И.М. Сеченова» (Сеченовский Университет) Министерства здравоохранения Российской Федерации.

Контактная информация: zharkovamaria@mail.ru;
119435, г. Москва, ул. Погодинская, 1, стр. 1.
ORCID: <https://orcid.org/0000-0001-5939-1032>

Ивашкин Владимир Трофимович — доктор медицинских наук, академик РАН, профессор, заведующий кафедрой пропедевтики внутренних болезней, гастроэнтерологии и гепатологии ФГАОУ ВО «Первый Московский государственный медицинский университет им. И.М. Сеченова» (Сеченовский Университет) Министерства здравоохранения Российской Федерации.

Контактная информация: ivashkin_v_t@staff.sechenov.ru;
119435, г. Москва, ул. Погодинская, 1, стр. 1.
ORCID: <https://orcid.org/0000-0002-6815-6015>

Submitted: 31.05.2022 Accepted: 31.10.2022 Published: 30.06.2023
Поступила: 31.05.2022 Принята: 31.10.2022 Опубликовано: 30.06.2023