

ARTHROSCOPIC LATARJET PROCEDURE: SAFETY EVALUATION IN CADAVERS

MAURO EMILIO CONFORTO GRACITELLI¹, ARNALDO AMADO FERREIRA NETO¹, EDUARDO BENEGAS¹, EDUARDO ANGELI MALAVOLTA¹, EDWIN EIJI SUNADA¹, JORGE HENRIQUE ASSUNÇÃO¹

ABSTRACT

Objective: To evaluate the safety of arthroscopic Latarjet procedure in cadavers. **Methods:** Twelve cadaveric shoulders underwent arthroscopic Latarjet procedure in our laboratory for arthroscopy, by four different surgeons. Following surgery, the specimens were subjected to radiographic examination and evaluated by an independent examiner. Nineteen parameters were evaluated, including the coracoid graft fixation, positioning and angulation of the screws, neurological damage and integrity of tendons. **Results:** Four procedures were considered to be satisfactory, with no difference among the surgeons. The mean angulation of the screws was 27.2°. The subscapularis

splitting was, on average, 17.8mm from the upper edge. The coracoid graft was properly positioned relative to equator of the glenoid in 11 cases. There was no injury to the axillary or musculocutaneous nerves. The main complications were: interposition of soft tissue, suprascapular nerve injury, articular deviation of the graft, diastasis and conjoined tendon injury. **Conclusion:** The arthroscopic Latarjet procedure is a complex technique in which each step must be precise to reduce the risk of complications. Our study showed a high risk of failure of the procedure. **Level of Evidence IV, Case Series.**

Keywords: Shoulder dislocation. Surgical procedures, operative. Arthroscopy.

Citation: Gracitelli MEC, Ferreira Neto AA, Benegas E, Malavolta EA, Sunada EE, Assunção JH. Arthroscopic Latarjet procedure: safety evaluation in cadavers. *Acta Ortop Bras*. [online]. 2013;21(3):139-43. Available from URL: <http://www.scielo.br/aob>.

INTRODUCTION

Nowadays, arthroscopy is the method used most often to treat recurrent anterior dislocation of the shoulder. However, in glenoid bone lesions above 25%, the Bankart procedure with arthroscopic approach presents a high rate of recurrence.¹ The treatment of choice in these situations is the Bristow or Latarjet surgical procedure, performed using the open technique, which consists of the transfer of the coracoid process to the anterior edge of the glenoid.^{2,3} Success in the performance of the Latarjet surgery depends on several factors,⁴ such as the positioning of the coracoid graft below the glenoid equator and its parallelism with the articular surface.

The Latarjet procedure using the arthroscopic approach is a new treatment method for recurrent anterior dislocation of the shoulder. This technique, originally described by Lafosse et al.,⁵ makes it possible to associate the advantages of arthroscopy with those of the Latarjet procedure. However, this method presents a high degree of technical difficulty, and was described by just a few authors.⁵⁻⁷ Nourissat et al.⁸ report good results in an anatomical study, in which they performed the procedure through mini-incisions assisted by arthroscopy. There are no studies evaluating the potential complications and

anatomical parameters of the procedure carried out entirely via the arthroscopic approach in cadavers.

The primary goal of this study was to determine the safety of the arthroscopic Latarjet procedure in cadavers, evaluating the correct positioning of the coracoid process, the integrity of the anatomical structures and complications. The secondary goal was to evaluate the reproducibility of the procedure, comparing the results between four shoulder surgeons.

MATERIAL AND METHODS

Twelve arthroscopic Latarjet procedures were performed in the arthroscopy laboratory of our institution, using cadavers. Four orthopedic shoulder surgeons carried out the procedures. They all had experience in performing arthroscopies and in the open Latarjet surgery, averaging 11.75 year of practice (ranging from 5 to 20 years). However, none of them had previous experience with the performance of the arthroscopic Latarjet procedure. Each surgeon operated on three specimens.

None of the pieces presented deformities or fractures of the coracoid process. The operations were performed using standard arthroscopic material and a special guide to fix the coracoid process, developed in our institution. (Figure 1)

All the authors declare that there is no potential conflict of interest referring to this article.

1. *Institute of Orthopedics and Traumatology of Hospital das Clínicas da Faculdade de Medicina da Universidade de São Paulo, São Paulo, SP, Brazil.*

Study conducted at LIM 41 – Laboratory of Medical Investigation of the Musculoskeletal System of the Department of Orthopedics and Traumatology of the School of Medicine of Universidade de São Paulo, São Paulo, SP, Brazil.

Mailing address: Rua Ovídio Pires de Campos, 333. Instituto de Ortopedia e Traumatologia - Diretoria Clínica, São Paulo, SP, Brazil. 05403-010. mgracitelli@gmail.com

Article received on 8/16/2012 and approved on 9/29/2012.



Figure 1. Guide used for transfer and fixation of the coracoid graft on the glenoid.

The specimens used presented all the muscles around the shoulder girdle, the whole scapula, the clavicle, the acromioclavicular and glenohumeral joints and the humeral diaphysis. They were placed in “beach chair” position, using a support device. The average age of the donors was 56.6 years (47 to 71 years). The average height was 180 cm (170 to 180 cm), with an average weight of 71.2 kg (60 to 100 kg), and all the cadavers were male. The procedure was carried out in accordance with the technique described by Lafosse et al.⁵ It consists of five main stages: (a) exposure and preparation of the coracoid, (b) division of the subscapularis, (c) osteotomy on the coracoid; (d) transfer of the coracoid with the fixation guide, and (e) fixation of the coracoid.

After performing the surgery, the samples were dissected by an independent examiner (a shoulder surgeon who had not participated in the surgical procedure) and were submitted to radiographies in axillary lateral view. Anatomical and radiographic parameters were analyzed using a handheld pachymeter graduated in millimeters. Nerve injuries were classified as: contact, stretch, partial injury or complete injury. Tendon injury was classified as: minimal injury (<10%), partial injury (>10%) or complete. The parameters and the distances measured are described in Table 1.

Cases with the following characteristics were considered satisfactory: absence of neurological lesions, absence of tendon lesions, appropriate graft height, appropriate tilt of the screws in the axillary view (<15°), absence of diastasis and absence of articular deviation of the graft. (Figure 2)

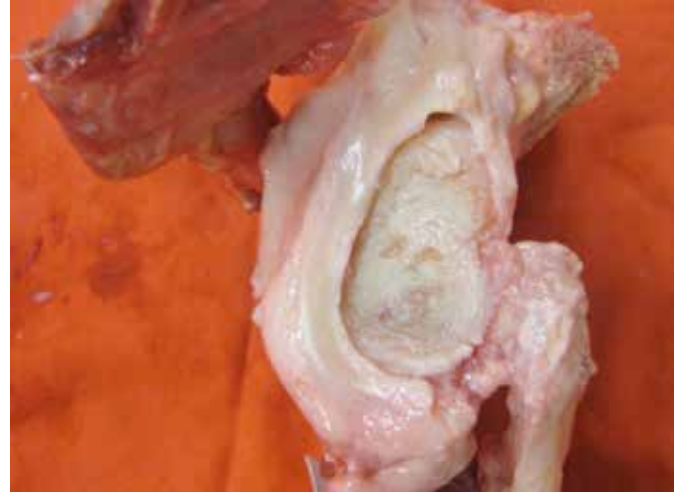

Figure 2. Image of anatomical piece after dissection. Case considered satisfactory.

Statistical analysis

A descriptive analysis (means and standard deviations) was used to the anatomical parameters and the surgical time. The neurological and tendon integrity were expressed in percentage. The correlations between cases with complications and with satisfactory results, in relation to the surgeon who performed the operation, were made through the Chi-squared test, with a significance level of 5%.

RESULTS

Four surgeries were considered satisfactory (25%). The average duration of the procedure was 137 minutes (60 to 180 minutes). Each surgeon performed a procedure adequately and there was no variation between the criteria considered satisfactory ($p = 1.00$). The number of cases with complications did not vary between the surgeons either ($p = 0.986$). Two surgeons successfully performed the first procedure and the others the third. The measurements taken are described in Table 2 and the complications found in Table 3.

Radiographic results

The radiographic evaluation in the axillary lateral view showed that the average angulation of the screws in relation to the glenoid articular line was 26.1° (2° to 66°) for the upper screw and 28.3° (2° to 70°) for the lower screw. (Figure 3)

Dissection

The average length of the coracoid process graft was 23.8 mm (18 to 32 mm). The total height of the subscapularis tendon was 37.8 mm (31 to 45 mm). (Figure 4) The division of the subscapularis tendon was performed at an average distance of 17.8 mm (12 to 24 mm) from its upper edge and 20 mm (7 to 27 mm) from its lower edge. Injury to the upper edge of the subscapularis tendon occurred in one case (8.3%).

The positioning of the coracoid in relation to the glenoid equator was considered appropriate in 11 cases (91.7%). The lower limit of the graft was, on average, in the five o'clock position (three to six hours) and the upper limit in the three o'clock position (one to four hours).

Table 1. Parameters evaluated.

Parameters evaluated
1. Diameter of coracoid
2. Length of coracoid
3. Distance between axillary nerve and medial dissection of the subscapularis
4. Distance between medial dissection of the subscapularis and musculocutaneous nerve
5. Integrity or signs of traction of the axillary nerve
6. Integrity or signs of traction of the musculocutaneous nerve
7. Integrity of conjoined tendon
8. Integrity of subscapularis tendon
9. Release of pectoralis minor tendon
10. Height of longitudinal division of the subscapularis in relation to the upper and lower extremity of the subscapularis

Table 2. Measurement of the parameters evaluated.

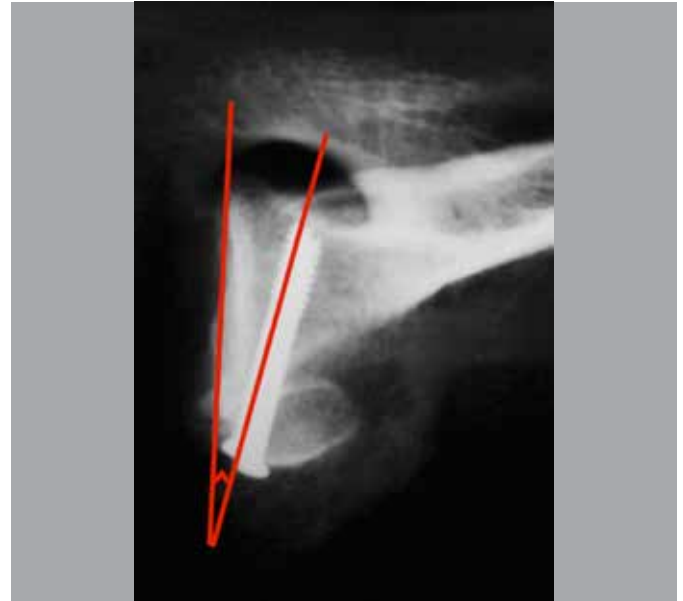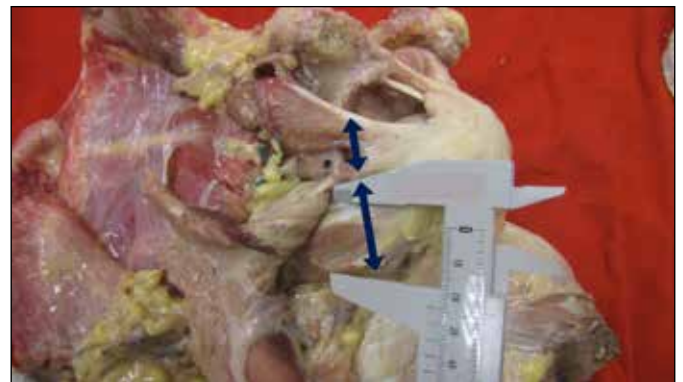Parameter	Mean	Minimum	Maximum	Sd
Length of coracoid	23.8 mm	18 mm	32 mm	4.22 mm
Diameter of coracoid	14.9 mm	11 mm	18 mm	2.50 mm
Distance between axillary nerve and medial dissection of the subscapularis	8.7 mm	0 mm	18 mm	6.40 mm
Distance between medial dissection of the subscapularis muscle and musculocutaneous nerve	10.8 mm	3 mm	20 mm	5.70 mm
Height of longitudinal division of the subscapularis in relation to the upper extremity of the subscapularis	17.8 mm	12 mm	24 mm	3.66 mm
Height of longitudinal division of the subscapularis in relation to the lower extremity of the subscapularis	20 mm	7 mm	27 mm	5.97 mm
Position of the bone graft in relation to the glenoid equator (upper/lower edge)	3h/5h	1h/3h	4h/6h	0.92h/0.81h
Graft diastasis in relation to the glenoid (distance between graft and glenoid)	1.13 mm	0 mm	3 mm	1.42 mm
Distance between the screw on the posterior edge of the glenoid and the suprascapular nerve.	7 mm	0 mm	21 mm	7.33 mm
Position of the screws in relation to the coracoid – Radiographic evaluation (Axillary)	27.2°	2°	68°	19.58°

Table 3. Complications.

Complications	n	%
Contact with axillary nerve	0	0
Contact with musculocutaneous nerve	0	0
Contact with or injury to suprascapular nerve	2	16.7
Injury to conjoined tendon	3	25
Injury to insertion of subscapularis tendon (upper edge)	1	8.3
Incomplete release of pectoralis minor tendon	2	16.7
Interposition of soft tissues between the coracoid graft and the glenoid	3	25
Diastasis between the coracoid graft and the glenoid	5	41.7
Protruding screws in the posterior wall of the glenoid neck	5	41.7
Lateral deviation of the coracoid graft	3	25

The average distance between the graft and the articular surface was described as positive when positioned medial to the joint and negative when positioned laterally. (Figure 5) Lateral deviation of the coracoid process occurred in three cases (25%), in which part of the graft was prominent over the articular edge of the glenoid. In four cases (33.3%), the coracoid was positioned medially. In five cases (41.7%), the graft was parallel to the anterior glenoid edge, without lateral or medial articular deviation. Excluding the three cases positioned laterally, the average distance was 1.22mm (0 to 6mm).

Soft tissue interposition between the coracoid and the glenoid (labrum or capsule) was observed in three cases (25%). Diastasis between the graft and the anterior glenoid wall occurred in five

**Figure 3.** Radiography in axillary lateral view: evaluation of the tilt of the screws in relation to the glenoid axis.**Figure 4.** Divulsion of the subscapularis tendon and measurement of the thickness of the upper and lower portions of the tendon.

cases (41.7%). The average distance was 2.7mm (2 to 3 mm). In five cases (41.7%) the screws surpassed the posterior glenoid wall, with an average distance of 7 mm (variation: 0 to 21 mm) from the suprascapular nerve. In one case, the upper screw came into contact with the nerve, and in another the nerve was stretched (16.7%). (Figure 6)

There were no injuries to the axillary nerve or to the musculocutaneous nerve. The average distances between the medial division of the subscapularis and the axillary and musculocutaneous nerves were 8.7 mm (0 to 18 mm) and 10.8 mm (3 to 20 mm), respectively.

Transverse partial injury to the origin of the conjoined tendon occurred in two cases, extending over more than 50% (16.7%). In one case there was minimal injury (8.3%). None of the cases presented complete injury. In two cases (16.7%), the release of the pectoralis minor from the medial edge of the coracoid process was incomplete. In one case (8.3%), the coracoid process sustained a fracture at its base when the osteotomy was performed.

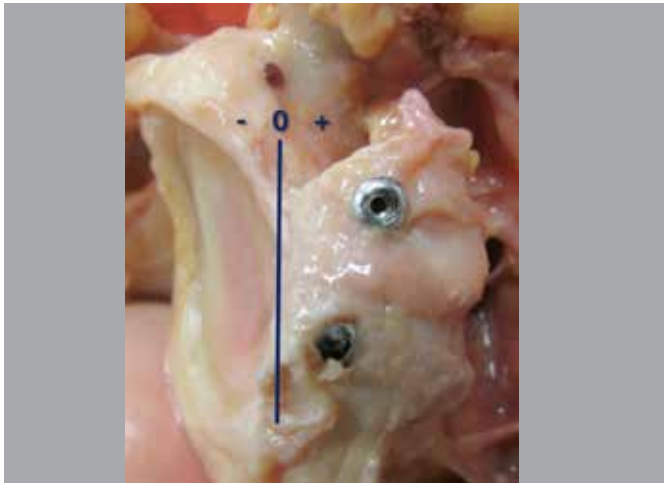


Figure 5. Position of the coracoid graft in relation to the sagittal axis of the glenoid.

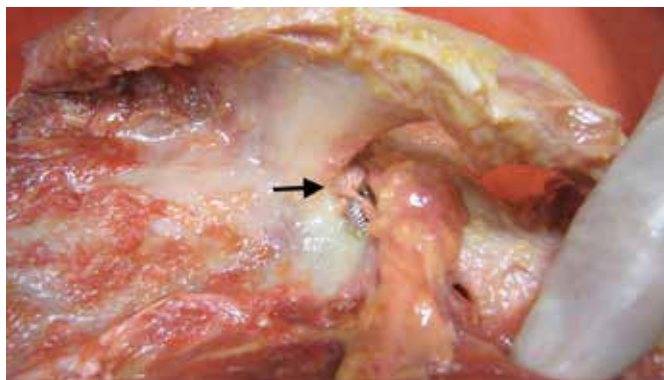


Figure 6. Suprascapular nerve injury caused by the coracoid fixation screw (arrow).

DISCUSSION

The arthroscopic Latarjet procedure is a new and complex technique that is under development.⁵⁻⁷ Our anatomical study demonstrates the potential complications of this procedure when performed by surgeons without previous experience with this surgery.

The descriptive analyses of each parameter and complication were described. A categorical definition of success of the procedure was used to increase the study generalization, and stringent parameters were used to determine the success of the procedure. The choice of these parameters was based on long-term studies that defined the principles of the Latarjet surgery.^{4,9-12} Among the main factors related to appropriate positioning, the most important are: positioning of the coracoid below the glenoid equator, minimum medial deviation of the graft, screw fixation on a maximum slope of 15° in relation to the glenoid articular line and stable fixation of the coracoid, without diastasis.^{4,10} We also included the absence of neurological or tendon injuries as important parameters. As a result of this definition, only four cases could be defined as appropriate. Graft diastasis and articular deviation were the most common problems in the cases of failure, present in five (62.5%) and three cases (37.5%), respectively. Both problems were the cause of three of the eight cases of failure. Lateral deviation of

the coracoid process could be resolved through partial resection with the shaver, but this was not done to avoid the bias of the anatomical evaluation.

Inappropriate screw tilt was present in seven (87.5%) of the inappropriate procedures and in all the cases with diastasis and lateral deviation. It also occurred in all the cases with contact of the nerve with the protruding screws.

Obtaining the correct screw tilt (below 15°) is necessary to allow an appropriate position of the coracoid and a stable fixation,^{4,10} and this was the most complex step in our casuistry. Lafosse and Boyle⁷ demonstrate through the computed tomography analysis that the average tilt of the screws was 29° (2 to 50°). In our study, the average tilt of the screws was 27.2°. It is possible to position the screws parallel to the articular surface of the glenoid in open surgery by retracting the pectoralis major medially through the deltopectoral approach. This retraction is not possible in the arthroscopic Latarjet, and the inferior portal "I" described by Lafosse et al.⁵ should not be medial to the glenoid surface to avoid injury to the axillary nerve. According to the study of Marsland and Ahmed¹³ the positioning of a thread parallel to the anterior portion of the glenoid poses a high risk of injury to the neurovascular structures. Boileau et al.⁶ described an alternative technique for coracoid fixation, in which a special guide was positioned through the posterior portal, using the glenoid surface as a reference for the screw positioning. Moreover, the authors used a more medial portal (east portal) through the pectoralis major to insert the coracoid graft and to fasten it to the glenoid. This method allowed a good positioning of the bone graft in 89% of the patients.⁶ The vertical position of the coracoid was appropriate in our study in 11 cases (91.7%), similar to that observed by Nourissat et al.⁸ and Lafosse and Boyle.⁷ Hovelius et al.¹⁴ reported that 36% of the grafts in the open procedures were in a high position, and that this should be avoided.

In an anatomical study similar to ours, Nourissat et al.⁸ performed the Bristow procedures by means of mini-incisions, assisted by the arthroscopy, using five cadavers and placing the coracoid in a vertical position. In contrast with our study, the results showed satisfactory position and appropriate fixation of the coracoid in all the cases, without neurovascular injuries. The insertion of a single screw drilled previously through an open incision, and the use of a device to position the graft parallel to the glenoid surface, favored the appropriate positioning of the graft. However, the authors had a smaller sample size, the radiographs were not used to gauge the screw tilt, the drilling of the posterior glenoid wall was not described, the parameters for satisfactory results were not as rigorous as in our study and reproducibility between different surgeons was not evaluated. The main limitation of our study is the small number of procedures for each surgeon, which limits the conclusions concerning the reproducibility and the learning curve of the procedure. The guide used has limitations, as it was developed as a test instrument. And no glenoid bone lesion was created, which may cause more difficulty in placing the coracoid in the appropriate position.

However, it is the first to evaluate the safety parameters of a Latarjet procedure performed completely arthroscopically by different surgeons and on cadavers. This variability allowed the evaluation of the early learning curve of this surgery, increasing

the external validity of the results. Anatomical parameters were studied that were blindly evaluated by an independent evaluator. The definition of success of the procedure was based on studies with a long follow-up time.

Our study was not intended to compare the open and arthroscopic procedures, and we cannot reach any conclusions about possible benefits of the arthroscopic technique. Theoretical benefits include the diagnosis of associated lesions,¹⁵ better evaluation of the coracoid position and resection of any residual articular deviation. The ability to convert an arthroscopic Bankart repair into a bone block procedure if the intraoperative findings show a glenoid lesion above 25% is another possible advantage of this technique.

Potential complications with the arthroscopic Latarjet were described and the fixation of the bone graft proved to be the most difficult stage of the process. Therefore, future surveys

should be aimed at evaluating guides and fixation techniques designed to improve coracoid and screw positioning. Our study draws attention to the fact that even experienced shoulder surgeons must practice this technique on cadavers, and must critically evaluate their results before using it on patients.

CONCLUSIONS

With the technique employed in this study, the arthroscopic Latarjet procedure showed a high rate of potential failure due to the difficulty in achieving the technical objectives considered necessary for the clinical success of the procedure. The main difficulties were in relation to the positioning and fixation of the coracoid process. The technical difficulty, long learning curve, need for specific guides for coracoid positioning and the potential risks of injury to anatomical structures are the main challenges of the arthroscopic Latarjet procedure.

REFERENCES

1. Burkhart SS, De Beer JF. Traumatic glenohumeral bone defects and their relationship to failure of arthroscopic Bankart repairs: significance of the inverted-pear glenoid and the humeral engaging Hill-Sachs lesion. *Arthroscopy*. 2000;16(7):677-94.
2. Burkhart SS, De Beer JF, Barth JR, Cresswell T, Roberts C, Richards DP. Results of modified Latarjet reconstruction in patients with anteroinferior instability and significant bone loss. *Arthroscopy*. 2007;23(10):1033-41.
3. Latarjet M. [Treatment of recurrent dislocation of the shoulder]. *Lyon Chir*. 1954;49(8):994-7.
4. Hovelius L, Sandström B, Saebö M. One hundred eighteen Bristow-Latarjet repairs for recurrent anterior dislocation of the shoulder prospectively followed for fifteen years: study II—the evolution of dislocation arthropathy. *J Shoulder Elbow Surg*. 2006;15(3):279-89.
5. Lafosse L, Lejeune E, Bouchard A, Kakuda C, Gobezie R, Kochhar T. The arthroscopic Latarjet procedure for the treatment of anterior shoulder instability. *Arthroscopy*. 2007;23(11):1242.e1-5.
6. Boileau P, Mercier N, Roussanne Y, Thélou CE, Old J. Arthroscopic Bankart-Bristow-Latarjet procedure: the development and early results of a safe and reproducible technique. *Arthroscopy*. 2010;26(11):1434-50.
7. Lafosse L, Boyle S. Arthroscopic Latarjet procedure. *J Shoulder Elbow Surg*. 2010;19(2 Suppl):2-12.
8. Nourissat G, Nedellec G, O'Sullivan NA, Debet-Mejean A, Dumontier C, Sautet A, et al. Mini-open arthroscopically assisted Bristow-Latarjet procedure for the treatment of patients with anterior shoulder instability: a cadaver study. *Arthroscopy*. 2006;22(10):1113-8.
9. Allain J, Goutallier D, Glorion C. Long-term results of the Latarjet procedure for the treatment of anterior instability of the shoulder. *J Bone Joint Surg Am*. 1998;80(6):841-52.
10. Hovelius L, Sandström B, Sundgren K, Saebö M. One hundred eighteen Bristow-Latarjet repairs for recurrent anterior dislocation of the shoulder prospectively followed for fifteen years: study I—clinical results. *J Shoulder Elbow Surg*. 2004;13(5):509-16.
11. Singer GC, Kirkland PM, Emery RJ. Coracoid transposition for recurrent anterior instability of the shoulder. A 20-year follow-up study. *J Bone Joint Surg Br*. 1995;77(1):73-6.
12. Spoor AB, de Waal Malefijt J. Long-term results and arthropathy following the modified Bristow-Latarjet procedure. *Int Orthop*. 2005;29(5):265-7.
13. Marsland D, Ahmed HA. Arthroscopically assisted fixation of glenoid fractures: a cadaver study to show potential applications of percutaneous screw insertion and anatomic risks. *J Shoulder Elbow Surg*. 2011;20(3):481-90.
14. Hovelius L, Akemark C, Albrektsson B, Berg E, Körner L, Lundberg B, et al. Bristow-Latarjet procedure for recurrent anterior dislocation of the shoulder. A 2-5 year follow-up study on the results of 112 cases. *Acta Orthop Scand*. 1983;54(2):284-90.
15. Arrigoni P, Huberty D, Brady PC, Weber IC, Burkhart SS. The value of arthroscopy before an open modified Latarjet reconstruction. *Arthroscopy*. 2008;24(5):514-9.