Received: 20th February 2015 Accepted: 13th May 2015 Conflicts of Interest: None
Source of Support: Nil

Review Article

Cone Beam Computed Tomography-Dawn of A New Imaging Modality in Orthodontics

J Mamatha[1], K R Chaitra[2], Renji K Paul[3], Merin George[4], J Anitha[5], Bharti Khanna[6]

Contributors:
[1]Senior Lecturer, Department of Orthodontics Dentofacial Orthopaedics, MR Ambedkar Dental College and Hospital, Bengaluru, Karnataka, India; [2]Senior Lecturer, Department of Orthodontics and Dentaofacial Orthopaedics, MR Ambedkar Dental College and Hospital, Bengaluru, Karnataka, India; [3]Reader, Department of Orthodontics and Dentofacial Orthopaedics, St. Gregorios Dental College, Kerala, India; [4]Senior Lecturer, Deparment of Oral Medicine and Radiology, Mar Baselios Dental College, Kerala, India; [5]Post Graduate Student, Department of Oral Medicine and Radiology, MR Ambedkar Dental College and Hospital, Bangalore, Karnataka, India; [6]Post Graduate Student, Department of Orthodontics and Dentaofacial Orthopaedics, MR Ambedkar Dental College and Hospital, Bengaluru, Karnataka, India.

Correspondence:
Dr. Mamatha J. Department of Orthodontics and Dentaofacial Orthopaedics, MR Ambedkar Dental College and Hospital, Bengaluru, Karnataka, India. Email: mamathagiri@yahoo.com

How to cite the article:
Mamatha J, Chaitra KR, Paul RK, George M, Anitha J, Khanna B. Cone beam computed tomography-dawn of a new imaging modality in orthodontics. J Int Oral Health 2015;7(Suppl 1):96-99.

Abstract:
Today, we are in a world of innovations, and there are various diagnostics aids that help to take a decision regarding treatment in a well-planned way. Cone beam computed tomography (CBCT) has been a vital tool for imaging diagnostic tool in orthodontics. This article reviews case reports during orthodontic treatment and importance of CBCT during the treatment evaluation.

Key Words: Cone beam computed tomography, diagnosis, orthodontics

Introduction

Imaging is the most important and frequently used diagnostic tool in dentistry.[1] Correct diagnosis is vital for proper treatment. Although the history and clinical examination are of prime importance when evaluating patients, the use and evolution of non-invasive technology from two-dimensional (2D) X-ray modalities to three-dimensional (3D) cone beam computed tomography (CBCT), for imaging is increasingly becoming popular.[2] CBCT was first developed for use in angiography. In 1998, Mozzo *et al*. reported the first CBCT unit developed specifically for dental use, the NewTom 9000 (Quantitative Radiology, Verona, Italy). Other similar devices introduced at around that time included the Ortho-CT, which was renamed the 3DX (J. Morita Mfg Corp, Kyoto, Japan) multi-image micro-CT in 2000. In 2003, Hashimoto *et al* reported that the 3DX CBCT produced better image quality with a much lower radiation dose than the newest multidetector row helical CT unit (1.19 mSvvs 458 mSv per examination).[3] The CBCT imaging technique is based on a cone-shaped X-ray beam that is centered on a 2D detector, and the beam performs one rotation around the object, producing a series of 2D images. The images are reconstructed in a 3D data set using a modification of the original cone-beam algorithm developed by Feldkamp *et al.* in 1984.[4] CBCT images from the craniofacial region are often acquired at a higher resolution than conventional CT. In addition, these systems are more compact than conventional CT systems, which make them more practical for use in dental offices.[5] Currently CBCT has a wide range of clinical applications and can be used for maxillofacial surgical treatment planning, assessing impacted teeth prior to surgical extractions, temporomandibular joint analysis, orthodontics, airway assessment, periodontics, bone level evaluation, implantology, endodontic assessment, diagnosis and treatment planning.[6]

CBCT in Orthodontics

The present article is aimed to throw light on the usefulness of CBCT imaging in cases on impacted teeth. CBCT imaging can offer an insight into the impacted teeth ranging from etiology of impaction through the treatment phase and the final treatment. There are various bone diseases that increase the density of the bone surrounding the tooth which may cause impaction, such as fibrous dysplasia, and syndromes associated with multiple supernumerary teeth such as Gardner's syndrome.[6,7] The most common site for single supernumerary teeth is in the maxillary incisor area, and multiple supernumerary teeth occur most frequently in the premolar region, usually in the mandible.[6]

Review of articles has shown that effective doses for digital panoramic radiographs range from 5.5 to 22.0 μSv, when the salivary glands are considered 2.4-6.2 μSv without while digital cephalometric radiographs have effective doses of 2.2 to 3.4 μSv with salivary glands, 1.6 to 1.7 μSv without.[8-12]

Therefore, OPG will expose the patient to 7.5 to 25.4 μSv effective dose (with salivary glands). This is in relation with an average annual natural background radiation dose in the United States of 3.0 mSv (3000 μSv).[13] Data have been published on four of the large field-of-view systems: the NewTom 9000 (QR, Verona, Italy), NewTom 3G, CB MercuRay (Hitachi Medical Systems, Tokyo, Japan), and the i-CAT (Imaging Sciences International, Hatfield, PA).[14,15] Few cases at our department are a testimony to the usefulness of CBCT and how it changes

our treatment plan. CBCT imaging has became an vital role in the field of orthodontics for diagnosis and treatment planning for both adult and pediatric patients.[15] This imaging modality has been used in the assessment of facial growth, airway, disturbances of tooth eruption and cephalometric analysis, safe insertion of mini screw implants (for anchorage) and proximity to vital structures can greatly aid complicated orthodontic case management, for complicated tooth movement predictability and for evaluation of impacted canines, other impacted teeth, root resorption, fractured roots, temperomandibular joint degenerative changes, cleft lip and palate.[16]

Case 1

A 21-year-old non growing male patient named Praveen reported with a complaint of a highly placed tooth and space in the front region (Figure 1). He reported a history of trauma at the age of 6 years when he suffered a blow to the deciduous maxillary incisors, from the front in a superior and posterior direction. On clinical examination, he was found to have a Class I skeletal base relation (Figure 2), Angle's Class I malocclusion. Orthopantomogram (OPG) showed the absence of root wrt 11 (Figure 3). It was decided that the case required further evaluation with CBCT as the blow was directed classically in the direction likely to cause dilaceration. On CBCT examination, it was found that the right maxillary central incisor had a root that is in contact with the root of the right maxillary lateral incisor (Figure 4).

This finding led to a complete change in the treatment plan. The initial plan to extract the central incisor was changed into a conservative mode of fixed orthodontic mechanotherapy wherein cantilever mechanics could be used to bring the central incisor into alignment.

Case 2

1. A 24-year-old non-growing female patient named Snehal Jain (Figure 5) with average growth pattern is diagnosed as a case of skeletal Class I jaw relationship, bilateral end-on canine relation, with proclined upper anteriors, an overjet of 10 mm and overbite of 8 mm, missing 26 and 46, lower arch crowding with orthognathic profile, competent lips with straight divergence (Figure 6).
2. With the history, clinical examination and radiographic records (Figure 7) it was decided to proceed with fixed mechanotherapy. In the second quadrant, it was decided to use second molar as the anchor unit and maintain space for replacement of first molar by prosthesis after completion of orthodontic treatment. In the fourth quadrant, it was decided to close the edentulous space with respect to missing first molar by mesialization of second and third molars.

A need was sought to obtain CBCT (Figure 8) to have a clear picture of the relation of second and third molars in the second quadrant. It proved to be the game changer indeed as the treatment plan shifted from simple orthodontic mechanics to the use of temporary anchorage devices.

3D images obtained from CBCT showed the third molar to be lying perpendicular to the second molar with the root of both being intertwined. Use of the second molar as the anchor unit could have jeopardized the prognosis of both first and second molars due to root resorption once the orthodontic forces were applied. It was thus, decided to use temporary anchorage device

Figure 1: Extra-oral.

Figure 2: Intra-oral.

Figure 3: Orthopantomogram.

or mini-implant in the second quadrant to obtain absolute anchorage from the bone.

Case 3

1. A 14-year-old growing female patient named Divya (Figure 9) is diagnosed as a case of skeletal class II jaw relationship with average growth pattern, class I molar relation bilaterally, with a decreased overjet and deep bite, with retroclined upper anteriors by 1 mm and retroclined lower anteriors by 2 mm (Figure 10) straight profile, and anterior divergence.

From the current radiographic records such as the OPG (Figure 11) and the intra oral periapical radiograph, we could infer the presence of an impacted premolar but no information could be obtained regarding the root region. No information could be obtained regarding the root proximity of the canine that was highly placed labial to the lateral incisor. A CBCT (Figure 12) was recorded, and it was confirmed the presence of root for the

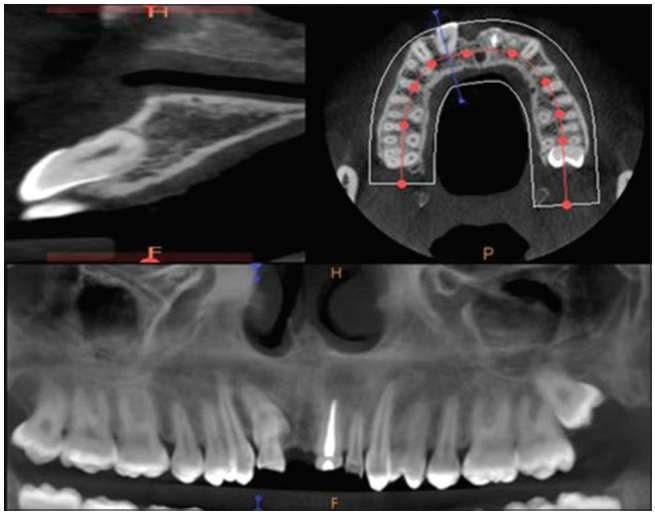

Figure 4: Cone beam computed tomography.

Figure 5: Extra-oral image.

Figure 6: Intra-oral image.

Figure 7: Orthopantomogram.

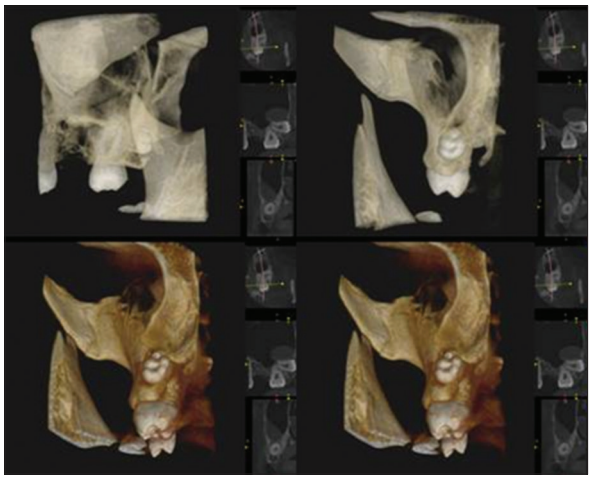

Figure 8: Cone beam computed tomography.

Figure 9: Extra-oral image.

Figure 10: Intra-oral image

Figure 11: Orthopantomogram.

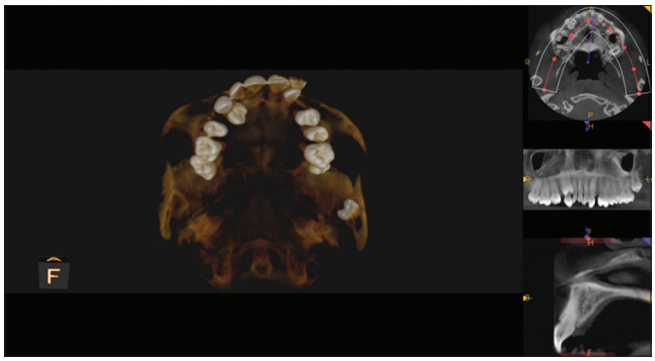

Figure 12: Cone beam computed tomography.

impacted premolar. It was confirmed the close proximity of the roots of the canine and lateral incisor which could have resulted in resorption of the roots if proper diagnosis and precautions were not taken, which is attributed to the advent of CBCT.

Conclusion

It is enormously imperative for any clinician to remain in touch with the latest innovations in the field of one's expertise and apply the same for the benefit of patient care. CBCT is one such recent advancement in the field of dentistry that has many clinical applications including in orthodontics. One should learn, adapt and use this imaging modality in clinical practice.

References

1. Jacobs R. Dental cone beam CT and its justified use in oral health care. JBR-BTR 2011;94(5):254-65.
2. Makhija PG, Makhija P. Integrating cone beam computed tomography (CBCT) in dentistry-Review. Bhavnagar Univ J Dent 2013;3(1):49-55.
3. Quereshy FA, Savell TA, Palomo JM. Applications of cone beam computed tomography in the practice of oral and maxillofacial surgery. J Oral Maxillofac Surg 2008;66(4):791-6.
4. De Vos W, Casselman J, Swennen GR. Cone-beam computerized tomography (CBCT) imaging of the oral and maxillofacial region: A systematic review of the literature. Int J Oral Maxillofac Surg 2009;38(6):609-25.
5. Alshehri MA, Alamri H, Alshalhoub M. Applications of CBCT in dental practice a literature review. Dent News 2011;25(2):1-8.
6. White SC, Pharoah MJ. Oral Radiology: Principles and Interpretation, 6th ed. Philadelphia: Mosby; 2004.
7. Mah JK, Danforth RA, Bumann A, Hatcher D. Radiation absorbed in maxillofacial imaging with a new dental computed tomography device. Oral Surg Oral Med Oral Pathol Oral Radiol Endod 2003;96(4):508-13.
8. American Academy of Oral and Maxillofacial Radiology. Clinical recommendations regarding use of cone beam computed tomography in orthodontics. Position statement by the American Academy of Oral and Maxillofacial Radiology. Oral Surg Oral Med Oral Pathol Oral Radiol 2013;116(2):238-57.
9. McDonald RE, Avery DR, Dean JA. Dentistry for the Child and Adolescent, Philadelphia: Mosby; 2004.
10. Ericson S, Kurol PJ. Resorption of incisors after ectopic eruption of maxillary canines: A CT study. Angle Orthod 2000;70(6):415-23.
11. Gijbels F, Jacobs R, Bogaerts R, Debaveye D, Verlinden S, Sanderink G. Dosimetry of digital panoramic imaging. Part I: Patient exposure. Dentomaxillofac Radiol 2005;34(3):145-9.
12. Ludlow JB, Davies-Ludlow LE, Brooks SL. Dosimetry of two extraoral direct digital imaging devices: NewTom cone beam CT and Orthophos Plus DS panoramic unit. Dentomaxillofac Radiol 2003;32(4):229-34.
13. Gijbels F, Sanderink G, Wyatt J, Van Dam J, Nowak B, Jacobs R. Radiation doses of indirect and direct digital cephalometric radiography. Br Dent J 2004;197(3):149-52.
14. Visser H, Rödig T, Hermann KP. Dose reduction by direct-digital cephalometric radiography. Angle Orthod 2001;71(3):159-63.
15. Frederiksen NL. Health physics. In: White SC, Pharoah MJ, (Editors). Oral Radiology, Principles and Interpretation, 5th ed. St Louis: Mosby; 2004.
16. Ludlow JB, Davies-Ludlow LE, Brooks SL, Howerton WB. Dosimetry of 3 CBCT devices for oral and maxillofacial radiology: CB Mercuray, NewTom 3G and i-CAT. Dentomaxillofac Radiol 2006;35(4):219-26.