

Grand Rounds Vol 5
Speciality: Vascular surgery
Article Type: Case Report
DOI: 10.1102/1470-5206.2005.0002
© 2005 e-MED Ltd

Acute occlusion of the aorta following bilateral aortoiliac procedures

Muzzafer Chaudery[†] and Frank Cross[‡]

[†] *St Bartholomew's and The Royal London School of Medicine, London, UK*

[‡] *St. Bartholomew's and The Royal London NHS Trust, Whitechapel Road, London E1 1BB, UK*

Date accepted for publication 10 December 2004

Abstract

Percutaneous transluminal angioplasty is a very common procedure and it is considered quite a safe and effective technique. We present a case of a patient who developed acute occlusion of the aorta and iliac vessels following bilateral aortoiliac angioplasty. There have been cases reported of acute iliac and femoral occlusion following bilateral aortoiliac angioplasty but so far there has not been a reported case of acute occlusion of the aorta following aortic and bilateral iliac procedures.

Keywords

Vascular occlusion; aorta; balloon angioplasty; bilateral; aortoiliac; iliac; femoral.

[Abstract](#)

[Keywords](#)

[Case report](#)

[Discussion](#)

[Teaching points](#)

[References](#)

[Figure 1](#)

[Figure 2](#)

[Figure 3](#)

[Figure 4](#)

[Figure 5](#)

[Home Page](#)

[Title Page](#)

[◀◀](#) [▶▶](#)

[◀](#) [▶](#)

[Go Back](#)

[Full Screen](#)

[Close](#)

[Quit](#)

GR

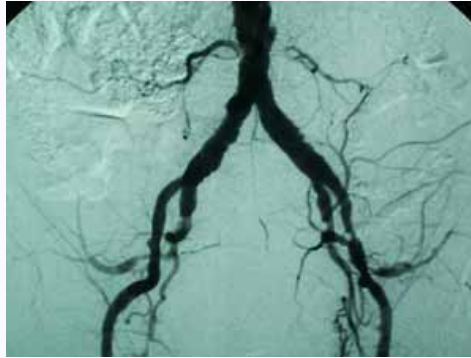

Fig. 1. This shows early disease of the aortic bifurcation in 2000.

Case report

A 74-year-old caucasian male with a 4-year history of severe bilateral buttock and leg claudication that had confined him to his home was admitted for bilateral iliac angioplasty. He had undergone previous angiography in 2000 (Fig. 1) but no treatment was carried out at that time. His risk factors included hypertension and smoking. He was also known to have bilateral renal artery stenoses leading to chronic renal failure and he had a carotid artery stenosis. On examination, his feet were pale with some hair loss on the medial aspects of the lower legs; there were no ulcers. His femoral pulses were palpable bilaterally but were weak and there were no distal pulses. His angiogram (Fig. 2) showed that the aorta was stenosed proximal to the bifurcation and there were multiple stenoses in the external iliac arteries bilaterally. Angioplasty of the aorta and both external iliac arteries was then undertaken. The procedure was successful, but complicated by bilateral iliac artery dissection (Fig. 3), which required treatment with the placement of stents (Figs 4 and 5).

[Abstract](#)

[Keywords](#)

[Case report](#)

[Discussion](#)

[Teaching points](#)

[References](#)

[Figure 1](#)

[Figure 2](#)

[Figure 3](#)

[Figure 4](#)

[Figure 5](#)

[Home Page](#)

[Title Page](#)

◀ ▶

◀ ▶

[Go Back](#)

[Full Screen](#)

[Close](#)

[Quit](#)

GR

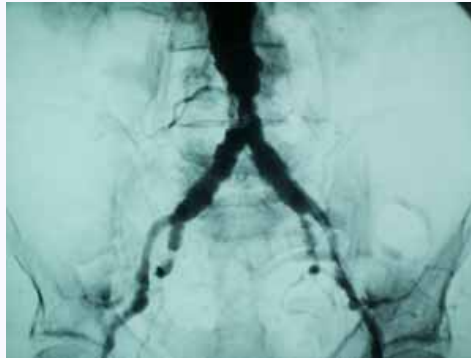


Fig. 2. Disease progression is clearly seen, with an aortic stenosis as well as iliac disease. An access guidewire is seen in the left common iliac artery and lower aorta.

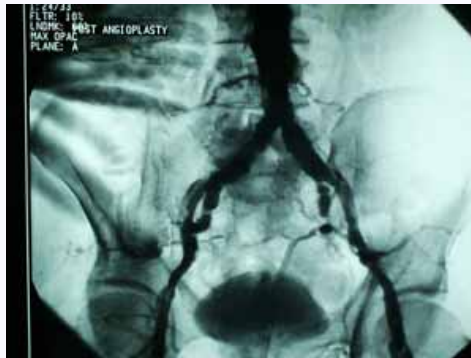

Fig. 3. The appearances following aortic and bilateral iliac angioplasty. Intimal flaps can clearly be seen in the external iliac arteries.

Abstract

Keywords

Case report

Discussion

Teaching points

References

[Figure 1](#)

[Figure 2](#)

[Figure 3](#)

[Figure 4](#)

[Figure 5](#)

[Home Page](#)

[Title Page](#)

◀◀ ▶▶

◀ ▶

[Go Back](#)

[Full Screen](#)

[Close](#)

[Quit](#)

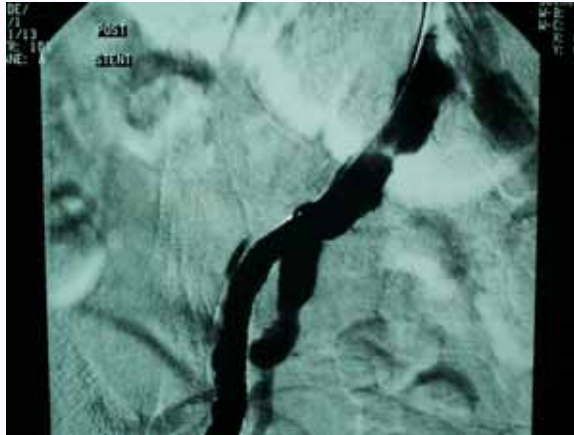


Fig. 4. Satisfactory appearance after insertion of a 9-mm right iliac artery stent.

The following day he developed features of severe bilateral leg ischaemia with severe back pain in the lumbar region and paraesthesia of the left leg. On examination, the femoral pulses were palpable but again the distal pulses were not. He was reviewed that evening by the consultant on call, who diagnosed aortic thrombosis. The severity of his condition was explained to his family and there was a plan for urgent femoral thrombectomy. However, the patient deteriorated rapidly and it became clear that he would not survive any procedure. He was managed with palliative care and passed away soon after.

Discussion

There have been reported cases of acute iliac and femoral occlusion following bilateral aortoiliac angioplasty^[1-3]. In one study, 147 angioplasties were performed for stenoses or

[Abstract](#)

[Keywords](#)

[Case report](#)

[Discussion](#)

[Teaching points](#)

[References](#)

[Figure 1](#)

[Figure 2](#)

[Figure 3](#)

[Figure 4](#)

[Figure 5](#)

[Home Page](#)

[Title Page](#)

[◀](#) [▶](#)

[◀](#) [▶](#)

[Go Back](#)

[Full Screen](#)

[Close](#)

[Quit](#)

GR

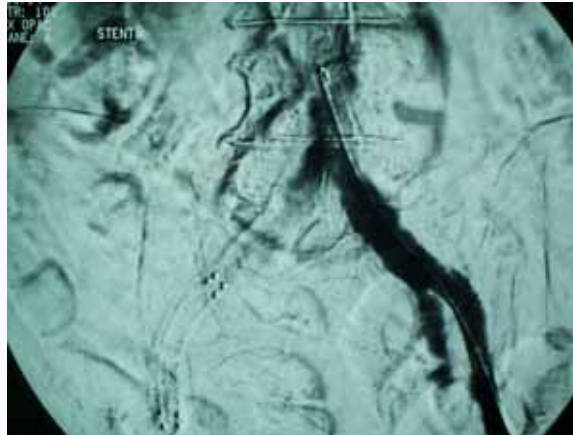


Fig. 5. Satisfactory appearance after insertion of a 9-mm left iliac stent.

occlusion above the inguinal ligament, with three reported cases of immediate occlusion of the femoral artery^[1]. In another study, 159 transluminal angioplasties were performed in 135 patients with arterial occlusive disease of the lower limb. Two early occlusions were observed after iliac angioplasty^[2]. Both studies clearly demonstrate that acute occlusion of the iliac and femoral arteries can occur in a small minority of patients following angioplasty.

Like any other procedure, percutaneous transluminal angioplasty is known to have a range of complications and these are well documented. Puncture site complications tend to be common, the most frequent being haematoma. In one study where 453 angioplasties were performed, the most important complication was acute occlusion of the arterial lumen attributed to acute thrombosis (2%)^[4]. Pseudoaneurysm formation and vessel rupture are considered rare but they do happen^[5,6]. Even rarer reported complications include an air embolus due to possible balloon rupture^[7] and an inflated balloon being

Abstract

Keywords

Case report

Discussion

Teaching points

References

Figure 1

Figure 2

Figure 3

Figure 4

Figure 5

Home Page

Title Page

◀◀ ▶▶

◀ ▶

Go Back

Full Screen

Close

Quit

GR

entrapped within a calcified coronary stenosis while the distal portion of the balloon remained inflated even after attempted deflation^[8].

This case discusses a rare complication: acute occlusion of the aorta following bilateral aortoiliac angioplasty. The lesson that can be learnt from this case is the importance of careful monitoring of the patient after angioplasty and acting rapidly if there is any suspicion of acute occlusion. Unfortunately, this patient did deteriorate very quickly despite a quick diagnosis.

Teaching points

Arterial balloon angioplasty is not as safe as we are tempted to assume, and occlusion, especially if it occurs in the aorta, can lead to death. Careful postoperative monitoring is essential.

References

1. Lancashire MJ, Torrie EP, Galland RB. Percutaneous angioplasty in a district general hospital: impact and implications. *J R Coll Surg Edinb* 1992; 37: 183-6. [MEDLINE Abstract](#)
2. Clement C, Costa-Foru B, Vernon P, Nicaise H. Transluminal angioplasty performed by the surgeon in lower limb arterial occlusive disease: one hundred fifty cases. *Ann Vasc Surg* 1990; 4: 519-27. [MEDLINE Abstract](#)
3. Murakami R, Korogi Y, Hirai T, Hamatake S, Ikushima I, Takahashi M. Totally occluded iliac arteries: long-term results of percutaneous transluminal angioplasty. *Radiat Med* 1998; 16: 25-30. [MEDLINE Abstract](#)
4. Gardiner Jr GA, Meyerovitz MF, Stokes KR, Clouse ME, Harrington DP, Bettmann MA. Complications of transluminal angioplasty. *Radiology* 1986; 159: 201-8. [MEDLINE Abstract](#)

[Abstract](#)[Keywords](#)[Case report](#)[Discussion](#)[Teaching points](#)[References](#)[Figure 1](#)[Figure 2](#)[Figure 3](#)[Figure 4](#)[Figure 5](#)[Home Page](#)[Title Page](#)[Go Back](#)[Full Screen](#)[Close](#)[Quit](#)

5. Formichi M, Raybaud G, Benichou H, Ciosi G. Rupture of the external iliac artery during balloon angioplasty: endovascular treatment using a covered stent. J Endovasc Surg 1998; 5: 37-41. [MEDLINE Abstract](#)
6. Castaneda F, Wright JD, Mendez A. Angioplasty-induced pseudoaneurysm successfully treated with a Palmaz stent. A case report. Angiology 1995; 46: 1021-5. [MEDLINE Abstract](#)
7. Kahn JK, Hartzler GO. The spectrum of symptomatic coronary air embolism during balloon angioplasty: causes, consequences, and management. Am Heart J 1990; 119: 1374-7. [MEDLINE Abstract](#)
8. Breisblatt WM. Inflated balloon entrapped in a calcified coronary stenosis. Cathet Cardiovasc Diagn 1993; 29: 224-8. [MEDLINE Abstract](#)

[Abstract](#)[Keywords](#)[Case report](#)[Discussion](#)[Teaching points](#)[References](#)[Figure 1](#)[Figure 2](#)[Figure 3](#)[Figure 4](#)[Figure 5](#)[Home Page](#)[Title Page](#)[Go Back](#)[Full Screen](#)[Close](#)[Quit](#)