MEDICAL SCIENCE MONITOR

CLINICAL RESEARCH

e-ISSN 1643-3750
© Med Sci Monit, 2013; 19: 276-282
DOI: 10.12659/MSM.883888

Received: 2012.10.15
Accepted: 2013.01.10
Published: 2013.04.17

Quality of the voice after injection of hyaluronic acid into the vocal fold

Authors' Contribution:
Study Design A
Data Collection B
Statistical Analysis C
Data Interpretation D
Manuscript Preparation E
Literature Search F
Funds Collection G

ABCD 1,2 Agata Szkiełkowska
BDEF 1 Beata Miaśkiewicz
D 3 Marc Remacle
E 1 Paulina Krasnodębska
G 1,2 Henryk Skarżyński

1 Audiology and Phoniatrics Clinic, Institute of Physiology and Pathology of Hearing, Warsaw, Poland
2 Audiology and Phoniatrics Faculty, Fryderyk Chopin University of Music, Warsaw, Poland
3 Department of Otorhinolaryngology – Head and Neck Surgery, University of Louvain at Mont-Godinne, Belgium

Corresponding Author: Agata Szkiełkowska, e-mail: a.szkielkowska@ifps.org.pl
Source of support: The Institute of Physiology and Pathology of Hearing covered all expenses incurred during the study

Background: Voice disorders resulting from glottic insufficiency are a significant clinical problem in everyday phoniatric practice. One method of treatment is injection laryngoplasty. Our study aimed to assess the voice quality of patients treated with hyaluronic acid injection into the vocal fold.

Material/Method: We studied 25 patients suffering from dysphonia, conducting laryngological and phoniatric examination, including videostroboscopy and acoustic voice analysis, before the operation and 1, 3, and 6 months later.

Results: In all cases there was complete or almost complete glottic closure after the operation. One month after the procedure, videostroboscopic examination revealed reappearance of vocal fold vibration in 8 cases; after 3 months this had risen to 15 cases. Perceptual voice quality (as assessed by the GRBAS scale) in patients with glottic insufficiency was improved. The most significant improvement was obtained 1 month after surgery (p=0.0002), and within the next months further statistically significant improvements (p=0.000002) were noted. Multidimensional voice analysis showed statistically significant and rapid improvement in frequency parameters, especially vFo. Other parameters were also improved 3 and 6 months after surgery.

Conclusions: Injection of hyaluronic acid into the vocal fold improves phonatory functions of the larynx and the quality of voice in patients with glottic insufficiency. It may be a safe and conservative method for treatment of voice disorders. Hyaluronic acid injection to the vocal fold is an easy, effective, and fast method for restoration of good voice quality.

Key words: **injection laryngoplasty • videostroboscopy • hyaluronic acid • glottis insufficiency • vocal fold paralysis • acoustic analysis**

Full-text PDF: http://www.medscimonit.com/download/index/idArt/883888

Indexed in: [Current Contents/Clinical Medicine] [SCI Expanded] [ISI Alerting System] [ISI Journals Master List] [Index Medicus/MEDLINE] [EMBASE/Excerpta Medica] [Chemical Abstracts/CAS] [Index Copernicus]

Background

Voice disorders resulting from glottic insufficiency are a common clinical problem in everyday phoniatric practice. Asthenic, breathy, weak voice, hoarseness and vocal fatigue are characteristics of this kind of dysfunction. A reduced dynamic range of the voice is also found. During phonation, hyperactivity of the laryngeal and neck muscles occurs as a result of compensation. Such voice disorders are the result of presbyphonia, unilateral vocal fold paralysis, glottic insufficiency in functional dysphonia, or vocal fold scar or sulcus.

Injection laryngoplasty is a treatment for glottic insufficiency. Vocal fold injection was first described by Brunings in 1911 [1] and implemented by Arnold in the 1960's. When considering material for injection, one has to consider the following factors: availability, costs, tolerance by the patient, resistance to resorption, ease of use, and complete biocompatibility [2]. Over the last few decades surgeons have used various augmentation materials, including Teflon, bovine collagen, autologous collagen, homogenic collagen, calcium hydroxylapatite, and autologous fat. Recently, cross-linked hyaluronic acid became more popular in phonosurgery, as it does not induce any inflammatory responses in the vocal fold area. Hyaluronic acid is one of the natural components of Reinke's space, and after injection provides viscoelasticity of the superficial layer of the lamina propria. It remains stable after injection into the vocal fold. Initial research indicated that hyaluronic acid attracts fibroblasts, which generate new collagen and extracellular matrix macromolecules, resulting in endogenous soft tissue augmentation [3–6].

This study assessed voice quality in patients who were surgically treated with injection of hyaluronic acid into the vocal fold.

Material and Methods

This study included 25 patients (14 males, 11 females) suffering from dysphonia. Age ranged from 36 to 76 years (mean 56.6 years). Patients reported hoarseness, weak, husky voice, difficulties in speaking long sentences, voice breaks, neck pain, and sore throat while speaking. All patients were referred for injection laryngoplasty, specifically, augmentation of hyaluronic acid into the vocal fold.

The cause of glottic insufficiency was functional dysphonia in 8 patients, presbyphonia in 2 patients, scar and vocal fold atrophy in 3 patients, sulcus vocalis in 2 patients, and unilateral vocal fold paralysis in 10 patients (Table 1).

All patients underwent laryngological and phoniatric examination. Preoperative and postoperative assessments were based on videostrobolaryngoscopy using EndoStrob DX Xion 327 equipment [7]. The examination included assessment of glottic closure, quality of vocal fold vibration (symmetry, regularity, amplitude, mucosal wave), and differences in the position of the vocal folds. Videostroboscopic examination of all patients during voice tasks confirmed the existence of a glottal gap. The shape of the gap depended on the type of pathology: shape was longitudinal in vocal fold paralysis, spindle-shaped in presbyphonia, vocal fold atrophy or sulcus, and irregular in vocal fold scar. Vocal fold vibrations were not seen on the paralyzed side, whereas vibration and amplitude remained stable (within the norm) on the opposite, correctly functioning fold. The amplitude of vibration was increased in cases of presbyphonia and hypofunctional dysphonia.

The glottic gap width during phonation was the most important selection criterion for treatment by injection of hyaluronic acid into the vocal fold.

Patients' voices were assessed with the GRBAS scale of the Japanese Society of Logopedics and Phoniatrics. The scale, first proposed by Hirano in 1981, evaluates parameters such as grade of hoarseness (G), voice roughness (R), voice breathiness (B), asthenic voice (A), and strained voice (S). Each parameter is estimated on a 4-grade scale (from 0 to 3) to describe the intensity. The results are presented as follows: G0–G3, R0–R3, B0–B3, A0–A3, and S0–S3. Measurements were made by 2 trained phoniatricians and their scores were averaged.

The objective acoustic voice analysis was performed with a KAY Elemetrics Computerized Lab version 4300 B. Three samples of the sustained vowel "a" were used for analysis, and were recorded with an AKG microphone positioned 3 cm from the mouth. Software from KAY Elemetrics, the Multidimensional Voice Program (MDVP), was used to obtain voice quality. We calculated average fundamental frequency, parameters describing short and long-term frequency perturbation (Jitt, RAP, PPQ, sPPQ, vFo), parameters assessing short- and long-term amplitude perturbations (Shimm, APQ, sAPQ, vAm), and noise-related parameters (NHR, SPI).

Follow-up examinations, including perceptive voice assessment (GRBAS), videostroboscopy, and acoustic measurements of patients' voices, were conducted 1, 3, and 6 months after surgery. Statistical analysis was done to compare changes in preoperative and postoperative voice using Student's *t* test. A p value of less than 0.05 was considered indicative of a statistically significant difference.

Surgical procedure

Microsurgical procedures were performed under general anesthesia (jet ventilation) using suspension laryngoscopy.

Indexed in: [Current Contents/Clinical Medicine] [SCI Expanded] [ISI Alerting System] [ISI Journals Master List] [Index Medicus/MEDLINE] [EMBASE/Excerpta Medica] [Chemical Abstracts/CAS] [Index Copernicus]

Table 1. Characteristics of the group (*n*=25).

Patient No	Gender	Age (year)	Observation period (months)	Etiology	Side of pathology
1.	M	36	8	Paralysis of vocal fold	Left
2.	M	44	6	Paralysis of vocal fold	Left
3.	K	64	8	Paralysis of vocal fold	Left
4.	K	51	6	Paralysis of vocal fold	Right
5.	M	76	8	Presbyphonia	Bilateral
6.	M	73	7	Presbyphonia	Bilateral
7.	K	43	8	Scar and atrophy of vocal fold	Bilateral
8.	K	58	8	Scar and atrophy of vocal fold	Left
9.	K	49	6	Scar and atrophy of vocal fold	Bilateral
10.	K	57	8	Insufficientia glottis	Bilateral
11.	K	54	8	Insufficientia glottis	Bilateral
12.	K	54	7	Insufficientia glottis	Right
13.	K	63	6	Insufficientia glottis	Bilateral
14.	K	58	6	Insufficientia glottis	Bilateral
15.	M	69	7	Insufficientia glottis	Bilateral
16.	M	41	6	Paralysis of vocal fold	Left
17.	K	37	6	Paralysis of vocal fold	Left
18.	K	46	7	Paralysis of vocal fold	Right
19.	M	48	6	Paralysis of vocal fold	Left
20.	M	20	6	Paralysis of vocal fold	Left
21.	K	54	8	Paralysis of vocal fold	Left
22.	M	21	6	Insufficientia glottis, sulcus vocalis	Bilateral
23.	K	53	6	Insufficientia glottis	Bilateral
24.	K	54	8	Insufficientia glottis	Right
25.	K	42	7	Insufficientia glottis, sulcus vocalis	Right

Surgiderm 24 XP hyaluronic acid (Allergan) was used for the injection. The augmentation was performed with a 25 gauge (0.5 mm) laryngeal needle as close to the deep layer of the lamina propria as possible.

In the case of unilateral vocal fold paralysis, the main injection must be made anteriorly to the vocal process. Further injections should be located laterally and medially. If filling of Reinke's space is needed, injection should be at the mid-point of the vocal fold. In scar and sulcus vocalis, the procedure consisted of 2 stages. The first stage included CO_2 laser-assisted dissection of the epithelium (Acuspot Micromanipulator, Sharplan) at the level of the adherent area. The second stage was hyaluronic acid augmentation to correct the deficit. In the case of bilateral sulcus, the injection was symmetrical. In other cases the location of the injection depended on individual indications. In patients with presbyphonia, glottic insufficiency, and vocal fold atrophy in functional dysphonia, the hyaluronic acid was injected into Reinke's space, as close to the vocal ligament as possible, to correct the vocal fold volume and relocate the free edge to the midline. The amount of hyaluronic acid used depended on the indication and on the estimation of the glottic gap, and ranged between 0.2 and 0.8 ml per side [8,9].

Indexed in: [Current Contents/Clinical Medicine] [SCI Expanded] [ISI Alerting System] [ISI Journals Master List] [Index Medicus/MEDLINE] [EMBASE/Excerpta Medica] [Chemical Abstracts/CAS] [Index Copernicus]

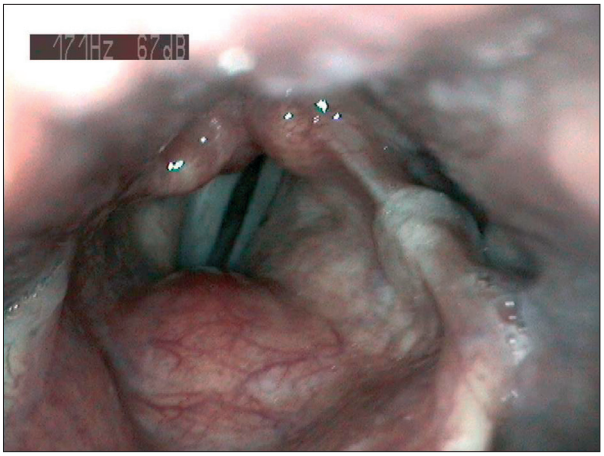

Figure 1. Videostroboscopy of unilateral vocal fold paralysis before surgery.

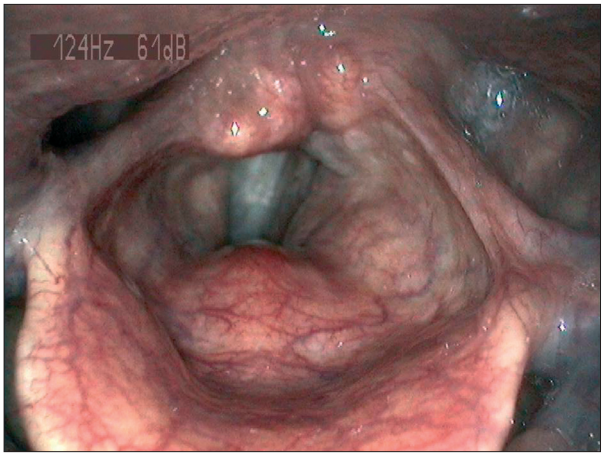

Figure 2. Videostroboscopy of unilateral vocal fold paralysis after surgery.

In the postoperative period, antibiotics were administered for 6 days and the voice rested for 2 days, although patients with scars were given strict vocal rest for 8 days. The program of care after hyaluronic acid augmentation was provided by the Audiology and Phoniatrics Clinic of the Institute of Physiology and Pathology of Hearing. After the operation, patients were included in a voice rehabilitation program for 3 months (1 visit per week) [10].

Results

After the operation we obtained complete or almost complete glottic closure in all cases (Figures 1, 2). One month after the procedure, videostroboscopic examination revealed recurrence of vocal fold vibrations in 8 cases (6 patients with irregular and 2 patients with regular vibrations). After 3 months vocal fold vibrations occurred in 15 cases and after 6 months 23 cases were seen. Lack of vibrations at 6 months was observed in only 2 cases (a case of unilateral paralysis and a vocal fold scar). Videostroboscopic evaluation performed 1, 3, and 6 months after surgery did not show any significant resorption of hyaluronic acid in the vocal fold that could affect the shape and efficiency of the glottis.

The injection laryngoplasty method improved the patients' perceptual voice quality, as assessed by the GRBAS scale. Every single parameter examined decreased in intensity (Table 2) over each period of postoperative observation (1, 3, and 6 months). The most significant improvement was obtained 1 month after surgery (p=0.0002). Over the next few months, further statistically important improvements (p=0.000002) were noted. Finally, voice stabilization was achieved. Differences in GRBAS parameters before and after surgery were statistically significant for each evaluated period. The largest differences were observed 6 months after augmentation (Figure 3). Analysis of single parameters showed that the best results were obtained with the G parameter (hoarseness) and B parameter (breathiness). The G parameter had improved after 1 month of follow-up (p=0.000044) and after 6 months the p-level was $<10^{-7}$. The R parameter (roughness) significantly changed after 1 month postoperatively, and after 6 months the p level was 0.0002. The B parameter, which indirectly describes the degree of phonation closure, improved significantly during the first month after surgery ($p \leq 10^{-5}$), and then stabilized after 6 months. The A parameter improved in all patients during the whole observation period, reaching the highest significance 3 months after surgery ($p<10^{-6}$). The S parameter (strain) achieved the greatest improvement and stabilization 6 months after surgery (p=0.000056).

Voice acoustic examinations revealed improvements in the acoustic structure of the voice in all patients after injection (Table 3).

The most significant and rapid improvements were obtained within the group of frequency parameters, especially the vFo parameter (fundamental frequency variation), which before the surgery was 3.02% and 3 months after surgery was 2.21%, with a significance level of p=0.028. The other parameters describing frequency disorders reached statistically important improvement 3 and 6 months after surgery (Figures 4, 5).

All parameters describing amplitude perturbation, such as Shim, APQ, sAPQ, and vAm, showed statistically significant improvement after 6 months postoperatively.

In the group of parameters describing noise components, results improved over time. The most rapid statistically significant improvement (p=0.0016) was obtained 1 month after surgery in the soft phonation index (SPI). This parameter is a good indicator of the vocal fold adduction during phonation.

Indexed in: [Current Contents/Clinical Medicine] [SCI Expanded] [ISI Alerting System] [ISI Journals Master List] [Index Medicus/MEDLINE] [EMBASE/Excerpta Medica] [Chemical Abstracts/CAS] [Index Copernicus]

Table 2. Mean values of GRBAS parameters before surgery and 1, 3, and 6 months afterwards.

Patient No	Before microsurgery					1 month after					3 months after					6 months after				
	G	R	B	A	S	G	R	B	A	S	G	R	B	A	S	G	R	B	A	S
1.	2	2	1	1	2	1	1	1	1	0	1	1	0	0	0	0	1	1	1	0
2.	2	2	1	0	2	2	2	1	0	3	1	2	1	0	1	1	2	1	0	1
3.	2	2	2	2	2	1	1	1	0	1	2	2	1	1	1	1	2	1	1	1
4.	1	1	2	2	1	1	1	1	1	0	1	1	1	1	0	1	0	0	0	0
5.	2	2	1	0	2	1	1	1	0	1	0	1	0	0	0	0	1	0	0	0
6.	2	3	2	2	1	1	1	1	0	2	2	2	1	0	1	1	1	0	0	1
7.	3	3	2	2	2	1	2	1	1	1	1	2	1	1	1	1	2	1	1	2
8.	3	3	1	2	2	2	3	1	0	2	2	3	1	0	2	2	2	1	1	1
9.	2	1	1	0	1	1	1	1	1	0	1	1	1	1	0	2	1	1	0	1
10.	3	2	2	2	2	2	2	1	1	1	1	2	1	1	1	1	1	1	1	1
11.	2	2	2	1	2	1	2	1	1	1	1	2	1	1	2	1	2	1	1	1
12.	2	2	1	2	1	1	2	1	1	2	1	2	1	1	1	1	1	1	1	1
13.	2	3	2	2	2	2	2	1	1	2	1	2	1	1	2	1	2	1	1	1
14.	2	2	2	1	3	2	2	1	1	2	2	2	1	1	3	1	2	1	1	1
15.	1	2	1	1	1	1	1	1	1	2	1	1	1	1	1	1	1	1	1	1
16.	1	2	1	1	1	1	1	0	0	0	1	1	0	0	0	1	1	0	0	0
17.	1	1	2	2	1	1	0	0	1	0	1	0	0	1	0	1	0	0	0	1
18.	2	2	2	2	2	1	1	1	0	1	1	1	1	0	1	1	1	1	1	0
19.	3	3	3	1	2	1	2	1	1	1	1	1	1	1	0	1	1	1	1	1
20.	1	1	3	1	1	1	1	1	1	1	1	1	1	1	0	1	1	1	0	0
21.	2	1	2	2	1	1	0	1	0	0	1	0	1	0	0	1	0	0	0	0
22.	1	1	1	1	1	2	1	0	0	1	2	1	0	0	1	1	1	0	0	1
23.	1	1	1	0	1	0	1	0	0	1	0	1	0	0	1	0	1	0	0	1
24.	1	1	2	1	1	1	1	0	0	1	1	1	0	0	1	1	1	0	0	1
25.	3	2	1	1	3	2	2	0	0	2	1	1	0	0	1	1	0	0	0	1

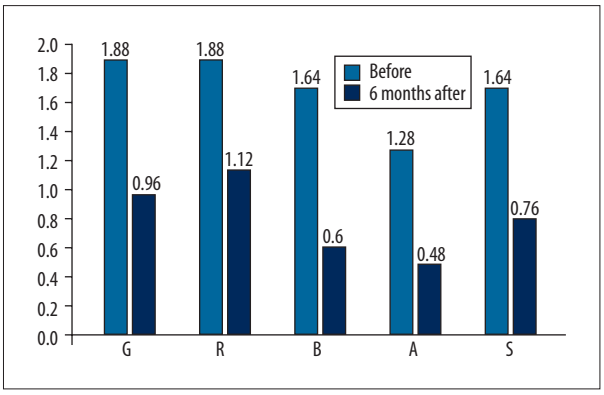

Figure 3. Perceptual voice analysis (GRBAS scale) before surgery and 6 months afterwards.

An increased soft phonation index is characteristic of patients diagnosed with incomplete glottic closure. However, the NHR parameter (describing noise to harmonic ratio) and the voice turbulence index (VTI) showed gradual improvements but did not reach statistical significance. Stabilization of the noise parameter indexes confirmed improvement of vocal fold adduction and reduction of glottic gap after hyaluronic acid injection.

Discussion

The results obtained in the present study indicate that application of hyaluronic acid augmentation to the vocal fold in cases having insufficient glottic closure provides good and very good voice quality and speeds rehabilitation of the voice. Satisfactory glottic closure was obtained after surgery in all cases. The satisfactory outcomes were confirmed by video-stroboscopic assessment and objective acoustic examination of the voice. The patients selected for this surgical treatment

Indexed in: [Current Contents/Clinical Medicine] [SCI Expanded] [ISI Alerting System] [ISI Journals Master List] [Index Medicus/MEDLINE] [EMBASE/Excerpta Medica] [Chemical Abstracts/CAS] [Index Copernicus]

Table 3. Mean values of acoustic parameters from MDVP analysis before surgery and 1, 3, and 6 months afterwards.

Observation period	MDVP mean values												
	Jita (us)	Jitt (%)	RAP (%)	PPQ (%)	sPPQ (%)	vFo (Hz)	ShdB (dB)	Shim (%)	APQ (%)	sAPQ (%)	vAm (%)	NHR	SPI
Before surgery	90.95	1.87	1.09	1.11	1.39	3.02	0.62	6.52	4.80	7.28	24.17	0.20	15.99
After 1 mth	80.28	1.70	0.90	0.94	1.09	2.34	0.53	5.46	4.15	6.35	18.75	0.18	10.62
After 3 mth	69.19	1.44	1.05	0.95	1.24	2.21	0.57	5.52	4.18	6.33	18.60	0.16	10.99
After 6 mth	59.27	1.12	0.82	0.81	0.92	1.78	0.47	5.07	3.46	4.87	14.18	0.15	11.24

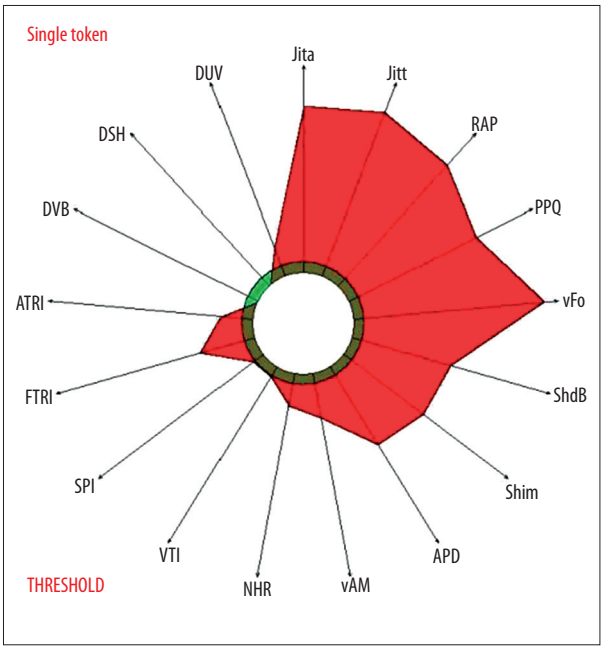

Figure 4. Unilateral vocal fold paralysis before surgery shown using MDVP.

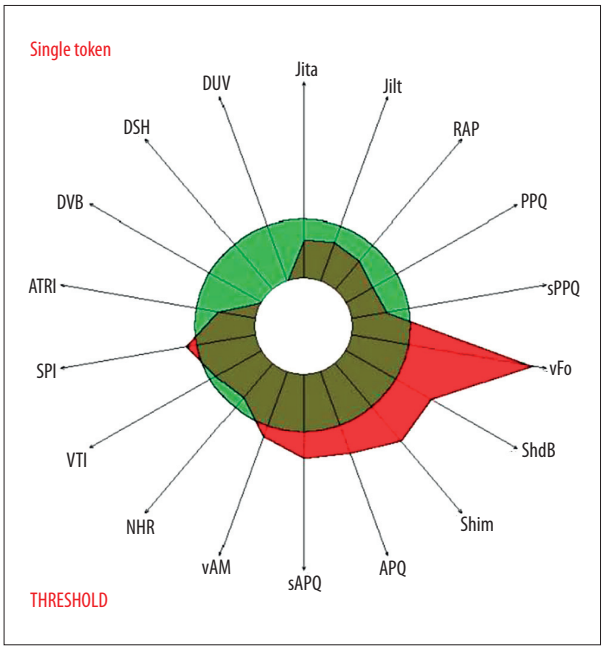

Figure 5. Unilateral vocal fold paralysis after surgery shown using MDVP.

had reported voice disorders of about 2 years duration. All patients had a medical history of attempts at phoniatric rehabilitation without satisfactory voice quality improvement. As recommended by a range of clinical centers, the patients were told to rest their voice in the postoperative period and were given voice therapy for 3 months after the surgery [8].

The study group showed immediate improvement in voice quality after the treatment, although better results were achieved after 3 months. After 6 months, full stabilization of voice had occurred, and this was statistically significant, as well as being noticeable to the patients themselves. In perceptual assessment of the voice, all parameters improved after surgery, but only in 3 cases was hoarseness (described by the G parameter) totally eliminated. We attribute this to bad habits and abnormal voice production. Both were present and escalated in the preoperative period; they ultimately had an impact on the final outcome. For most of the patients, this functional factor was at work during the whole follow-up period, and as a compensational mechanism it affected the treatment. In a few cases it prevented satisfactory voice outcomes. The most difficult group was those patients with coexisting ventricular dysphonia. The best postoperative voice outcomes were noted in patients with unilateral vocal fold paralysis, which is consistent with literature reports [9,11,12]. The criteria for patient selection for surgery should verify that there is a coexisting functional change within the vocal pathway. Some authors note that the best results are obtained in cases of a phonatory gap smaller than 3 mm [2]. Our previous experience indicates that the size of the phonatory gap is a significant factor, but localization of the gap is also important. In the presented material, a return of vibratory movement in patients with oval glottic gap (maximum opening in the middle part of the glottis) was seen first.

Indexed in: [Current Contents/Clinical Medicine] [SCI Expanded] [ISI Alerting System] [ISI Journals Master List] [Index Medicus/MEDLINE] [EMBASE/Excerpta Medica] [Chemical Abstracts/CAS] [Index Copernicus]

During the whole 8-month follow-up period, no adverse inflammatory reactions within vocal folds or laryngeal structures were found. There were no signs of hyaluronic acid resorption or voice deterioration. Interestingly, the opposite effect was seen: month by month, the patients' voices became more stable and normal within the acoustic structure. The literature indicates that hyaluronic acid injected into Reinke's space has the ability to stimulate growth of new connective tissue – collagen, fibroblasts, and hyaluronic acid – providing long-term filling and elasticity of the vocal fold [13]. In comparison to other implantable materials such as autologous fat, Teflon, collagen, or calcium hydroxylapatite, hyaluronic acid seems to be quite resistant to resorption [2,14,15]. As reported by other authors, resorption of hyaluronic acid takes about 6–12 months. Biocompatibility and resistance to resorption, ease of the injection method, and, above all, a long-term functional vocal result, proves that hyaluronic acid augmentation into the vocal fold is effective and safe.

Conclusions

In patients suffering from glottic insufficiency, injection of hyaluronic acid into the vocal fold significantly improves phonatory function of the larynx and quality of voice.

Augmentation of the vocal fold with hyaluronic acid is an effective and voice-improving method, restoring speech production. It may be a safe alternative to the conservative methods of treatment used in rehabilitation of voice disorders.

Hyaluronic acid injection to the vocal fold is an easy, effective, and fast method of restoring good voice quality.

References:

1. Molteni G, Bergamini G, Ricci-Maccarini A et al: Auto-crosslinked hyaluronan gel injections in phonosurgery. Otolaryngol Head Neck Surg, 2010; 142: 547–53
2. King M, Simpson B: Modern augmentation for glottic insufficiency. Curr Opin Otolaryngol Head Neck Surg, 2007; 15: 153–58
3. Lau DP, Lee GA, Wong SM et al: Injection laryngoplasty with hyaluronic acid for unilateral vocal cord paralysis. Randomized controlled trial comparing two different particle sizes. J Voice, 2010; 24: 113–18
4. Rosen CA, Gartner-Schmidt J, Casiano R et al: Vocal fold augmentation with calcium hydroxylapatite: Twelve-month report. Laryngoscope, 2009; 119: 1033–41
5. Song PC, Sung CK, Franco RA Jr: Voice outcomes after endoscopic injection laryngoplasty with hyaluronic acid stabilized gel. Laryngoscope, 2010; 120(Suppl.4): S199
6. Perazzo PS, Duprat Ade C, Lancellotti CL: Histological behavior of the vocal fold after hyaluronic acid injection. J Voice, 2009; 23: 95–98
7. Szkiełkowska A, Miaśkiewicz B, Krasnodębska P et al: The Videostrobokymography in phoniatric practice. Otolaryngol Pol, 2012; 66(3): 214–18
8. Remacle M, Lawson G: Results with collagen injection into the vocal folds for medialization. Curr Opin Otolaryngol Head Neck Surg, 2007; 15: 148–52
9. Arviso L, Johns M, Mathison C, Klein A: Long-Term Outcomes of Injection Laryngoplasty in Patients With Potentially Recoverable Vocal Fold Paralysis. Laryngoscope, 2010; 120: 2237–40
10. Mau T: Factors associated with voice therapy outcomes in the treatment of presbyphonia. Laryngoscope, 2010; 120: 1181–87
11. Friedman A, Burns J, Heaton J, Zeitels S: Early Versus Late Injection Medialization for Unilateral Vocal Cord Paralysis. Laryngoscope, 2010; 120: 2042–46
12. Reiter R, Brosch S: Laryngoplasty with Hialuronic Acid In Patients With Unilateral Vocal Fold Paralysis. J Voice, 2012; 26(6): 785–91
13. Kimura M, Nito T, Sakakibara KI et al: Clinical experience with collagen injection of the vocal fold: A study of 155 patients. Auris Nasus Larynx, 2008; 35: 67–75
14. Gillspie MB, Dozier TS, Day TA et al: Effectiveness of calcium hydroxylapatite paste in vocal fold rehabilitation. Ann Otol Rhinol Laryngol, 2009; 118(8): 546–51
15. Fang T, Li H, Gliklich R et al: Outcomes of Fat Injection Laryngoplasty in Unilateral Vocal Cord Paralysis. Arch Otolaryngol Head Neck Surg, 2010; 136(5): 457–62

Indexed in: [Current Contents/Clinical Medicine] [SCI Expanded] [ISI Alerting System] [ISI Journals Master List] [Index Medicus/MEDLINE] [EMBASE/Excerpta Medica] [Chemical Abstracts/CAS] [Index Copernicus]