

# Electrophysiological End Point for Catheter Ablation of Atrial Fibrillation Initiated From Multiple Pulmonary Venous Foci

Michel Haïssaguerre, MD; Pierre Jaïs, MD; Dipen C. Shah, MD; Stéphane Garrigue, MD; Atsushi Takahashi, MD; Thomas Laverigne, MD; Méléze Hocini, MD; Jing Tian Peng, MD; Raymond Roudaut, MD; Jacques Clémenty, MD

**Background**—The end point for catheter ablation of pulmonary vein (PV) foci initiating atrial fibrillation (AF) has not been determined.

**Methods and Results**—Ninety patients underwent mapping during spontaneous or induced ectopy and/or AF initiation. Ostial PV ablation was performed by use of angiograms to precisely define targeted sites. Success defined by elimination of AF without drugs was correlated with the procedural end point of the abolition of distal PV potentials. A total of 197 arrhythmogenic PV foci (97%)—single in 31% and multiple in 69%—and 6 atrial foci were identified. A discrete radiofrequency (RF) application eliminated the PV potentials in 9 PV foci, whereas 2 foci from the same PV required RF applications at separate sites in 19 cases. In others, a wider region was targeted with progressive elimination of ectopy. In 49 patients, multiple sessions were necessary owing to recurrent or new ectopy. The clinical success rates were 93%, 73%, and 55% in patients with 1, 2, and  $\geq 3$  arrhythmogenic PV foci. Recovery of local PV potential and the inability to abolish it were significantly associated with AF recurrences (90% success rate with versus 55% without PV potential abolition). PV stenosis was noted acutely in 5 of 6 cases, remained unchanged at restudy, and was associated with RF power  $>45$  W.

**Conclusions**—Multiple PV foci are involved in initiation of AF, and elimination of PV muscle conduction is associated with clinical success. (*Circulation*. 2000;101:1409-1417.)

**Key Words:** atrial fibrillation ■ catheter ablation ■ electrophysiology

The pulmonary veins (PVs) have been shown to trigger paroxysms of atrial fibrillation (AF), and radiofrequency (RF) ablation of these foci can eliminate AF.<sup>1-5</sup> However, the efficacy of ablation is limited by a high percentage of recurrences and the unknown frequency of venous stenosis, and the end point of successful ablation, particularly in patients with scant ectopy, has not been defined. The present study was prospectively performed to assess these issues.

## Methods

### Patient Characteristics

The study population consisted of 90 consecutive patients (Table 1). Thirty-seven had  $>700$  ectopies per day (Figure 1).

### Electrophysiological Study

The study was performed as described previously with the use of 2 or 3 electrode catheters and after confirmation of the absence of intracardiac thrombi by transesophageal echocardiography.<sup>5</sup> The left atrium (LA) and PVs were explored through either a patent foramen ovale (19 patients) or a transseptal catheterization. Selective PV angiography was performed by hand injection of 5 to 10 mL of contrast with an NIH catheter and displayed during the procedure.

Heparin was titrated to maintain a partial thromboplastin time of 60 to 90 seconds (control, 30 seconds).

In patients with few ectopies or sustained AF necessitating cardioversion, 2 steerable ablation catheters (with different curves) were used to map the PVs simultaneously. When few ectopies were observed, the following provocative maneuvers were performed: vagal maneuvers, including carotid sinus massage, deep breathing, and Valsalva; slow-rate atrial pacing (bursts of 3 to 10 stimuli at 100 to 200 bpm for postpause ectopy); isoproterenol infusion (2 to 4  $\mu\text{g}/\text{min}$ ); high-rate pacing; and their combinations. If long-lasting AF was induced, internal ( $n=6$ ) or external electrical cardioversions were performed, sometimes followed by AF reinitiation. ATP injection (20 to 80 mg) or saline infusion (500 mL in 15 minutes) was tried in 4 patients each. A swallowing maneuver was a reproducible mode of induction in 1 patient.

Mapping was performed in  $\geq 2$  sites in the superior PV(s) either sequentially or simultaneously and thereafter in the inferior veins (Figures 2 and 3). If the earliest activity could not be traced from any PV, both atria were mapped.

### Definition of an Arrhythmogenic PV

An arrhythmogenic PV<sup>4,5</sup> was defined on the basis of documented ectopy—single or multiple and with or without conduction to the LA. During sinus rhythm, double or multiple potentials were

Received June 18, 1999; revision received October 1, 1999; accepted October 12, 1999.

From the Hôpital Cardiologique du Haut-Lévêque, Bordeaux-Pessac, France.

Presented in part at the 20th Annual NASPE Meeting, Toronto, Canada, May 12 to 15, 1999.

Correspondence to Professeur Michel Haïssaguerre, Hôpital Cardiologique du Haut-Lévêque, Ave de Magellan, 33604 Bordeaux-Pessac, France.

© 2000 American Heart Association, Inc.

*Circulation* is available at <http://www.circulationaha.org>

TABLE 1. Patient Characteristics

	Value	Range
Clinical characteristics		
Sex, M/F	73/17	
Age, y	51±12	26–80
Duration of AF, y	5±5	1–24
Unsuccessful drugs,* n	5±2	1–9
Structural heart disease,† n	17	
Previous embolic episode, n	8	
Hypertension, n	12	
Diabetes, n	4	
Sinus pauses >4 s, n	4	
Echocardiographic parameters		
End-diastolic LV diameter, mm	51±6	34–70
End-systolic LV diameter, mm	32±6	21–55
LV shortening, %	36±8	22–57
Anterior-posterior LA dimension, mm	39±7	25–55
Inferior-superior LA dimension, mm	53±9	30–67
Medial-lateral LA dimension, mm	38±6	27–57
Inferior-superior RA dimension, mm	48±8	30–68
Medial-lateral RA dimension, mm	36±7	21–55
Preprocedural AF duration, min/24 h	447±449	0–1440

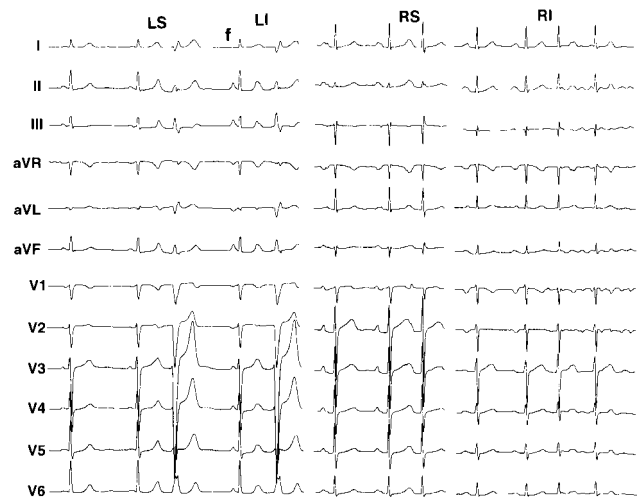
LV indicates left ventricular; RA, right atrial.

\*Amiodarone in 62 patients.

†Dilated or hypertrophic cardiomyopathy in 7 patients, myocardial infarction in 5, mitral valve regurgitation in 4, and atrial septal defect in 1.

recorded in a progressively later temporal sequence, synchronous with the first (right PVs) or second (left PVs) half of the P wave (Figure 3). The first low-frequency potential reflected activation of the adjacent atrium. The latest high-frequency potentials indicated PV muscle potentials (PVPs). The ostial PVPs were sometimes not obvious in the left PVs because of the superimposed LA potential during sinus rhythm; however, pacing of the distal coronary sinus (or LA appendage) allowed their separation and thus easy recognition of PVP (Figure 4).

During ectopy from an arrhythmogenic PV, there was a reversal in activation sequence, from the distal PV trunk (source) to the ostium and LA (exit), with the PVP preceding the LA potential. Ectopic discharges with the shortest coupling interval were not conducted to the LA producing isolated PVP confined within the PV (Figures 2



**Figure 1.** ECG (12-lead) showing typical P on T ectopy originating from LS, LI, RS, and RI pulmonary veins. RIPV focus initiates AF episode (right). P wave marked F is fusion between sinus rhythm and LS ectopic discharge.

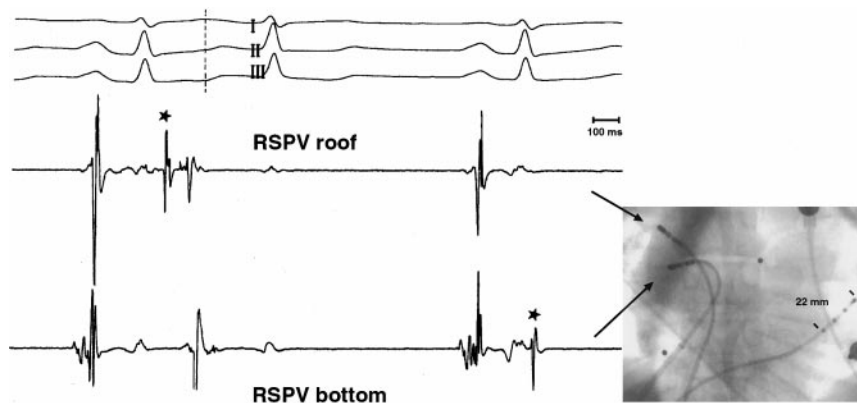
and 3). They were recognized as a PVP coincident with or just after the ventricular electrogram and could be distinguished from a potential of ventricular origin by their spontaneous disappearance (intermittent PVP) or suppression during atrial pacing.

Conversely, if the explored PV was not the origin of ectopy, it was “passively” activated as in sinus rhythm with a proximal-to-distal sequence and a PVP after or fusing with the LA potential. Multiple foci in the same PV were defined by the presence of  $\geq 2$  different sources and exits at opposite locations of the PV perimeter (eg, roof and bottom) demonstrated by selective PV angiography.

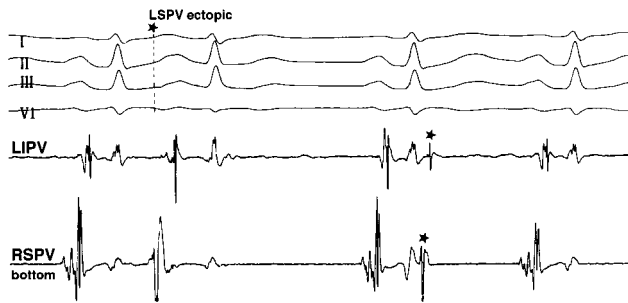
### Ablation Procedure

RF ablation of atrial foci was performed at the site of earliest activation. RF ablation of arrhythmogenic PV was performed within 15 mm of the PV ostium; the exact location depended on catheter stability. This was thought to be safer (vis-à-vis the risk of PV stenosis) than more distal applications in smaller veins. The perimeter of the PV ostium was mapped to localize the ostial sector showing the earliest activity during ectopy, and the highest and sharpest PV potential was first targeted for ablation. Subsequent RF applications were performed if needed at contiguous sites showing PVP. The end point was elimination of ectopy, spontaneous or induced by provocative maneuvers, and elimination of PV muscle conduction (during sinus rhythm) distally to the ablation site(s) on the basis of either abolition or dissociation of distal PVP. To assess capture of the LA, local pacing was performed from these sites.

RF energy was delivered at the distal electrode of the thermocouple-equipped catheter (target, 50°C) with a power limit of



**Figure 2.** Two different sources of ectopy. Cinefluorogram shows catheters in RSPV (roof and floor) and coronary sinus. First and third beats are sinus beats; second is ectopic beat originating from RSPV roof as indicated by early local PV spike potential (\*). RSPV bottom is activated later (passively). After third beat, “concealed” ectopic discharge originating from RSPV bottom captures neither roof nor atria.



**Figure 3.** In sinus rhythm (first beat), fractionated electrograms are recorded from 2 veins with initial far-field atrial component followed by late sharper PV component, electrograms being early (with respect to P wave) in RSPV and late in LIPV. Activation during ectopic (second beat) is relatively late and passive in both veins; ie, local PV component does not precede atrial component, indicating that this ectopic discharge originates from third site, in this case, LSPV. After second sinus beat, sharp-spike discharges that are not followed by atrial deflection (concealed ectopy) are noted in both PVs \*.

45 to 50 W in the first 35 patients. Because of the occurrence of several acute PV stenoses (see later), a maximal power limit of 25 to 30 W was subsequently set for the last 55 patients. If >1 PV was arrhythmogenic, the PV producing the most repetitive ectopy and/or initiating AF was first targeted; then, RF energy was delivered in a second PV after angiographic verification of the unchanged patency of the first one. PV angiography was performed at the end of ablation in all but 4 patients (technical problems). PV stenosis was defined as a diameter reduction of >50%. Repeated PV angiography was performed >1 month later in 58 patients.

Patients were discharged beyond the third day under oral anticoagulant. In the event of recurrent AF, all patients were advised to undergo a new study, and ablation was performed if there was no PV stenosis. The procedure was considered a success when the AF episodes were totally eliminated without antiarrhythmic drugs both clinically and on Holter recordings. Any suggestive but undocumented symptoms were attributed to AF recurrence. Anticoagulants were interrupted 3 months after successful elimination of AF unless there were other risk factors.

### Statistical Analysis

Continuous variables are expressed as group mean $\pm$ SD and compared with the use of a Kruskal-Wallis or Student's *t* test. Noncon-

tinuous variables were compared by use of the  $\chi^2$  or Fisher's exact test. Statistical significance was selected at  $P < 0.05$ .

## Results

In 4 patients, initiation and maintenance of AF were due to a rapidly firing focus with a persistent distal-to-proximal PV activation sequence during AF (focal AF). The remaining patients had focally initiated AF with a short burst of focal discharges initiating typical intra-atrial fibrillation, which continued independently.

### Mapping of Triggering Ectopic Beats

In 58 patients, provocative maneuvers were needed to elicit ectopy (Table 2). Sustained AF required electrical external or internal cardioversions in 38 patients.

Ectopy originating from a single PV was found in 27 patients, 2 in 22, 3 in 29, and 4 in 11, for a total of 197 arrhythmogenic PVs in 89 patients, and from the atrial muscle in 6 patients (right atrium in 1, atrial septum in 1, and posterior LA in 4). A single arrhythmogenic PV was associated with female sex, younger age, less frequent and shorter AF paroxysms, and smaller atrial dimensions (Table 3).

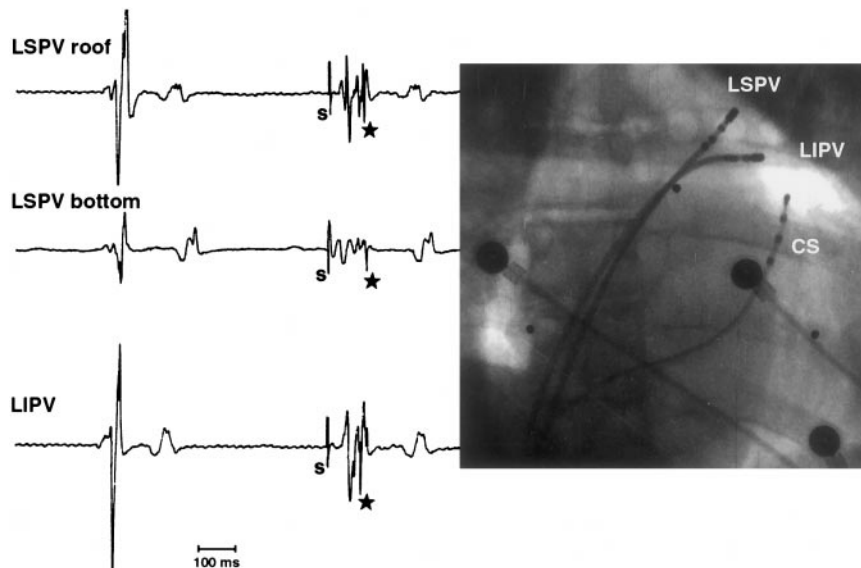
### RF Ablation of Foci Initiating AF

#### Atrial Foci

One patient (patient 11) had a single atrial focus and underwent 3 ablation sessions because of 2 recurrences after ablation. Five patients had atrial foci in addition to arrhythmogenic PV; ablation was successful in 3 and failed in 2 because of insufficient ectopy.

#### Frequently Discharging PV Foci

Mapping of ectopy from 9 PVs (4 left inferior PVs [LIPVs], 3 right inferior PVs [RIPVs], 1 right superior PV [RSPV], and 1 left superior PV [LSPV]) showed a discrete source from the ostium of a venous branch and a discrete exit at the ostium of the venous trunk reflected by a localized (which disappeared with small catheter movements on either side) continuum of the PVP-LA potential. Ectopy was abruptly eliminated by a



**Figure 4.** Local left PV potentials are not always obvious during sinus rhythm and may require pacing from within distal coronary sinus (CS) to be revealed. Cine frame shows catheters placed in LSPV, LIPV, and coronary sinus. Bipolar tracings show 1 sinus beat followed by paced beat from distal coronary sinus. In each case, although electrograms during sinus rhythm do not show evident local PV potentials, characteristic sharp potential (\*) distinct from initial far-field potential is recorded during pacing. S indicates stimulation artefact.

**TABLE 2. Electrophysiological and Ablation Data of Ectopy**

	LSPV (n=62)	RSPV (n=63)	LIPV (n=58)	RIPV (n=14)	Atrial (n=6)
PV ostial diameter, mm	16±3	16±3	15±3	13±4	
Mapping conditions, No. of patients					
Spontaneous ectopy	22	21	23	6	3
Provoked ectopy	40	42	35	8	3
Vagal maneuvers	4	4	1	1	...
Isoproterenol	21	27	15	4	3
Postpacing	6	3	7	1	...
Others	9	8	12	2	...
Electrophysiological data					
Nonconducted ectopy, n	26	37	23	8	1
Nonconducted bigeminy, n	19	29	17	6	1
Repetitive ectopy, n	38	44	41	8	3
Initiation of AF, n	30	32	32	6	3
Discharge only in burst, n	1	3	7	0	0
Earliest PVP relative to P-wave onset, ms	104±41	105±41	100±35	82±22	37±11
Ablation data					
RF delivery duration, min	10±6	10±8	7±6	6±7	7±7
Maximal RF power, W	32±10	32±10	28±11	29±9	40±13
RF application ≥45 W*	13	12	10	2	2

\*Number of patients who received ≥1 RF application >45 W.

discrete RF ablation, which abolished the ostial and corresponding distal (site activated later into the venous branch) PVP during sinus rhythm (Figure 5).

In 19 PVs (9 LIPVs, 6 LSPVs, and 4 RSPVs), there were 2 sources of ectopy from different PV branches associated with 2 distinct ostial exits necessitating ablation at separate points of the ostium (Figure 6). This produced abrupt disappearance of targeted ectopies and sequentially eliminated the ostial and distal PVPs in each corresponding venous branch.

In the remaining PVs, mapping of the ostium during ectopy showed synchronous local activation in a large sector of the venous perimeter (Figure 7). Correspondingly, during sinus rhythm, PVPs were recorded in a large part of the ostium ranging from one quarter to the full circumference. In 14, differing activation times during ectopy suggested various ectopy sources or activation courses. Sequential RF applications at the ostium produced a progressive decrease in ectopies or an initial disappearance of repetitive followed by that of isolated ectopy; the first applications commonly produced exacerbation of ectopies. Ablation eliminated progressively the local PVPs, usually requiring 2 or 3 series of RF applications along the entire sector (Figure 8). A progressive prolongation of the LA-PVP conduction time (both locally and distally) was observed during sinus rhythm, and ablation at the remaining site(s) without atrial-PVP delay (gap like continuum electrogram) resulted in abrupt disappearance of local and distal PVPs, indicating disconnection. An abrupt reappearance of local and distal PVPs was noted in 19 patients, and reablation as described above was successfully performed.

In 9 patients, after ablation, residual isolated ectopies were found to originate at the atrial edge of the PV ostium (instead

of inside the PV), indicating a modification of the source of earliest activity as a result of RF delivery and necessitating additional RF applications.

#### **Patients With Insufficient PV Ectopy**

In 12 patients, only 1 to 5 ectopies were noted despite multiple provocative maneuvers; however, this was sufficient to identify the arrhythmogenic PV. RF applications were performed during sinus rhythm or distal coronary sinus pacing at the sites exhibiting PVPs, resulting in total elimination of the distal PVPs (Figure 9).

In 8 other patients, PV ectopy immediately produced sustained AF, which recurred after repeated cardioversions (5±2). In 5 patients, a circumferential PV ostial ablation was performed during AF, and progressive abolition of the PVP (sharpest potentials) could be seen distally inside the PV; after a new cardioversion, AF did not reappear, and additional RF applications abolished the residual PVP during sinus rhythm. In the last 3 patients, amiodarone (300 to 600 mg) was infused and ablation was performed after conversion in sinus rhythm.

#### **Reablation and Final Mapping Results**

A total of 155 ablation sessions were performed: 1 in 41 patients, 2 in 36, 3 in 10, and 4 in 3, for total procedure duration and fluoroscopy times of 278±154 and 82±44 minutes, respectively (149±71 and 45±21 minutes per session).

At the end of the first session, ectopy was persistent in 9 patients, and all had early recurrences of AF. Of the remaining 81, 40 (50%) had recurrent AF. These 49 patients underwent 1 to 3 (total, 65) reablation sessions. During these

**TABLE 3. Characteristics of Patients With Single Versus Multiple Arrhythmogenic PVs**

	Single PV (n=27)*	Multiple PV (n=62)	P
Clinical characteristics			
Sex, M/F	16/11	56/6	<0.001
Age, y	44±11	53±11	0.008
Duration of AF, y	4±4	6±5	NS (0.07)
AF maximal duration within 8 days before ablation, min	356±389	911±1029	0.006
Frequency of episodes, daily/every 2 days/weekly, n	12/6/9	46/7/9	0.04
Preprocedural AF duration on Holter, min/24 h	210±271	567±477	<0.001
Structural heart disease, n (%)	5 (19)	12 (19)	NS
Echocardiographic parameters, mm			
Anterior-posterior LA dimension	36±6	40±7	0.008
Inferior-superior LA dimension	49±7	54±8	0.009
Medial-lateral LA dimension	36±6	38±6	NS
Inferior-superior RA dimension	43±6	51±8	0.007
Medial-lateral RA dimension	34±6	37±7	NS
Procedural data			
PV diameter, mm	16±3	16±4	NS
PV distribution, LS/RS/LI/RI, n	8/11/7/1	54/52/51/14	NS
Multiple procedures, n (%)	8 (30)	41 (66)	<0.001
Cardioversion required, n (%)	7 (26)	31 (50)	0.02
Total duration, min	169±86	325±154	<0.001
Fluoroscopy time, min	49±26	97±43	<0.001
RF duration, min	12±9	23±12	<0.001

RA indicates right atrial.

\*Patient 11 with a single atrial focus is not included.

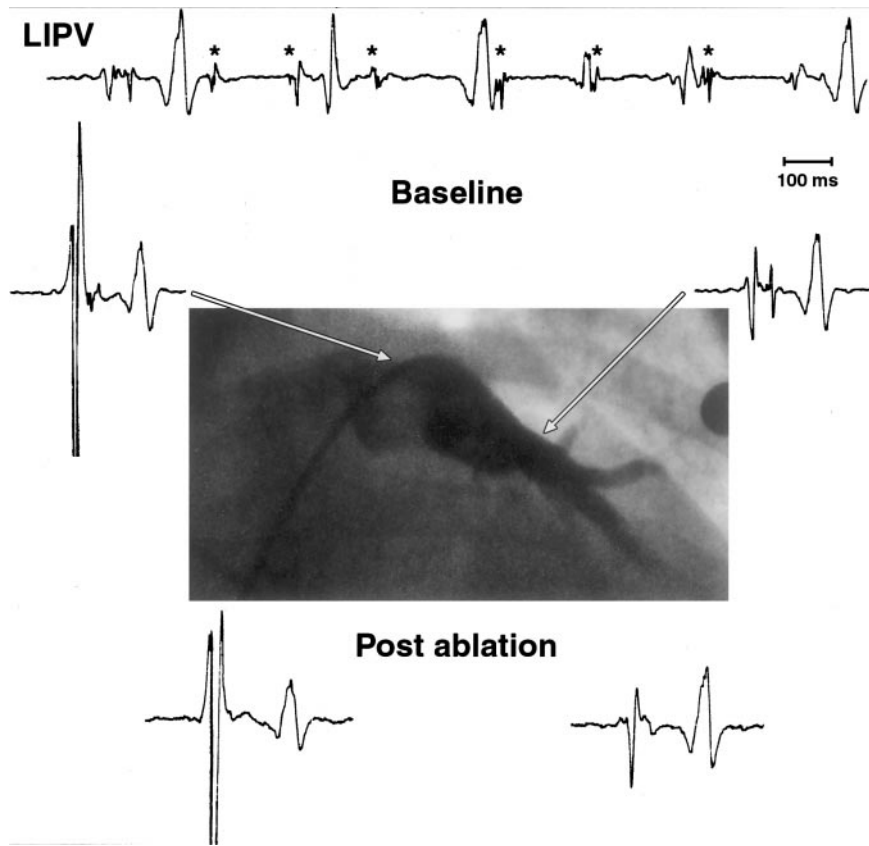
sessions, mapping showed that the ectopy was related to the persistence or recovery of a previously targeted PVP in 24, originated from another part of a previously targeted PV in 12, originated from a different PV in 21, and was related to combinations of the above in 8. The recovered PVP was delayed and thus obvious during sinus rhythm; it was present (ostially and distally) at a discrete area in 9 patients and abolished with a single RF application (Figure 10). In 4, it disappeared intermittently by simple mechanical catheter pressure. Sequential RF applications were needed in others to eliminate PVPs.

After all ablation, mapping in 96 PVs showed preservation of the distal PVP. Local PV pacing from the area with PVP, even when it was very discrete, could capture the LA. All PVPs were eliminated in 86 PVs or dissociated in 15 (superior) PVs; pacing could not capture the LA.

### Safety

Air embolism during catheter exchange was responsible for transient ECG changes in 5 patients. A transient bradycardia occurred in 3 patients during LSPV ablation. Patient 11 developed a hemopericardium that was percutaneously drained during the first ablation session. One patient had an episode of binocular blurred vision for 2 minutes without thrombus visible at transesophageal echocardiography. One patient developed a reversible ischemic neurological deficit 36 hours after ablation.

Angiograms performed just after ablation in 86 patients revealed a narrowing of the ostium in 5 ablated PVs; in an additional patient who received a single RF application at 30 W, the angiogram performed 5 minutes later showed stenosis of a 6-mm-diameter branch. PV angiograms (n=115, including all those not angiographically studied just after ablation) ≥1 month after ablation (mean, 5±4 months) demonstrated a persistent similar stenosis in these PVs plus an additional case that had not had an angiography just after ablation. Thus, a total of 6 ablated PVs (3%) had stenosis of the PV trunk: 1 patient had a double PV stenosis (RSPV and LIPV) and 4 had a single PV stenosis (3 LIPV and 1 LSPV). All stenoses were located at the most distal ablation site in the PV trunk. The mean gradient across the stenosis was 4±2 mm Hg (range, 2 to 7 mm Hg), but no patient had pulmonary hypertension. However, 2 had symptoms: 1 described dyspnea during strong effort, and 1 patient developed hemoptysis and pleural effusion 1 week after interruption of warfarin (3 months after ablation). PV thrombosis demonstrated by spiral CT scan subsided after 2 weeks of heparin; a repeated scan showed only PV stenosis. Stress tests in 4 of 5 patients showed an unchanged performance relative to their peak effort before ablation. Analysis showed that the prevalence of PV trunk stenosis was the highest for LIPV (7% of LIPV versus 1.5% of all other PVs, *P*<0.05) and when the maximal delivered RF power reached 45 W (5 of 37 versus 1 of 160, *P*<0.01).



**Figure 5.** Example of discrete arrhythmogenic triggering substrate within LIPV. Tracing (top) shows AF initiation by rapid train of discharges (\*) from distal LIPV. Mapping during sinus rhythm revealed local PVP at roof extending deep into vein (arrows). Ablation at roof eliminated arrhythmia and spike both at ostium and distally, signifying discrete nature of this tissue.

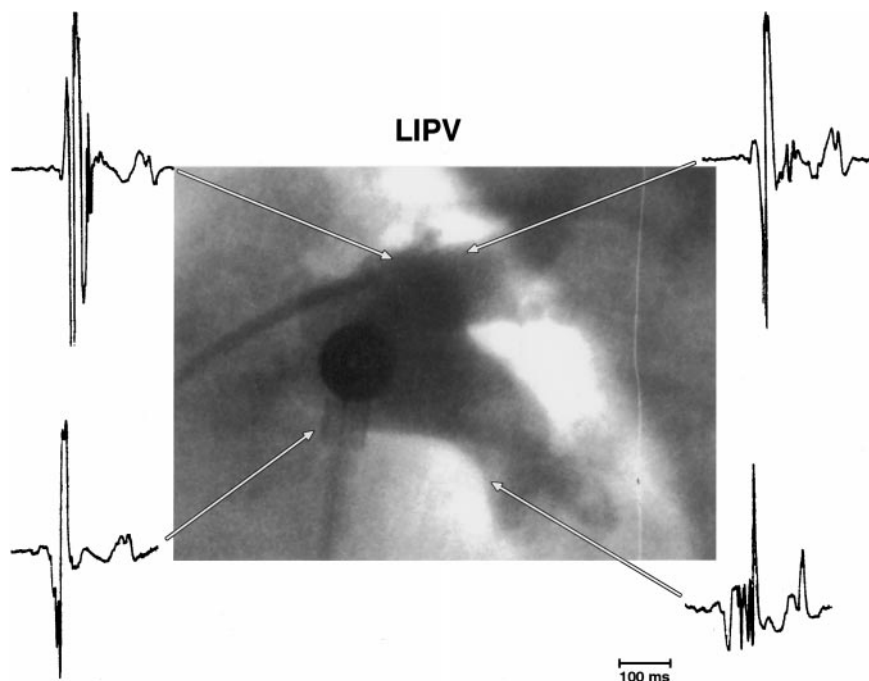
No ostial PV stenosis was observed with a RF power limit of 30 W, including after circumferential ablation.

**Final Outcome**

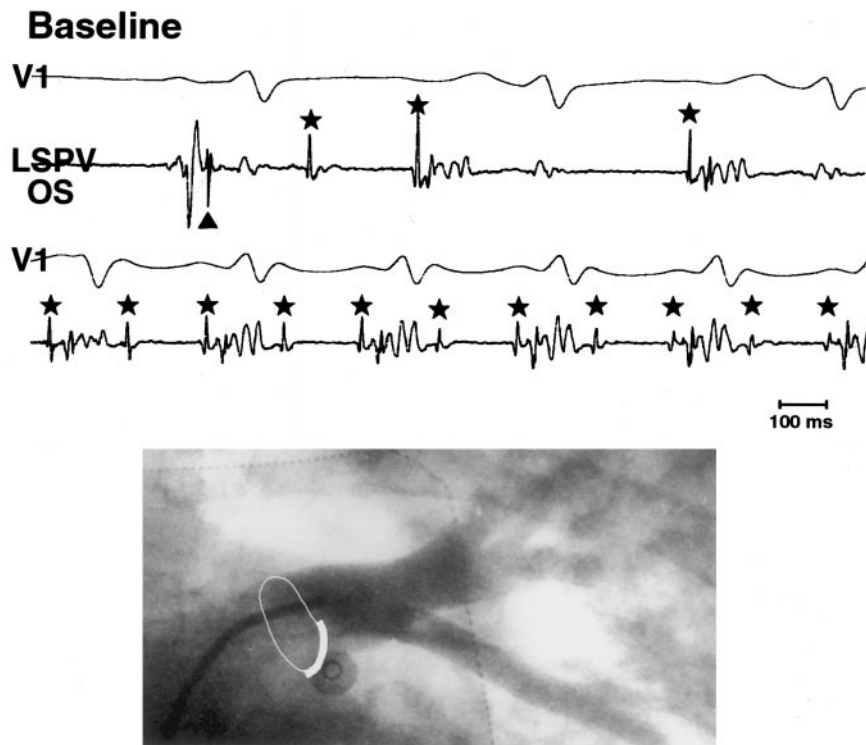
With a mean follow-up of  $8 \pm 5$  months after discharge, AF was completely eliminated in 64 patients (71%) without antiarrhythmic drugs (success group), and anticoagulants

were interrupted in 52. The other 26 patients were prescribed a drug that was ineffective before ablation, resulting in total elimination of AF in 12.

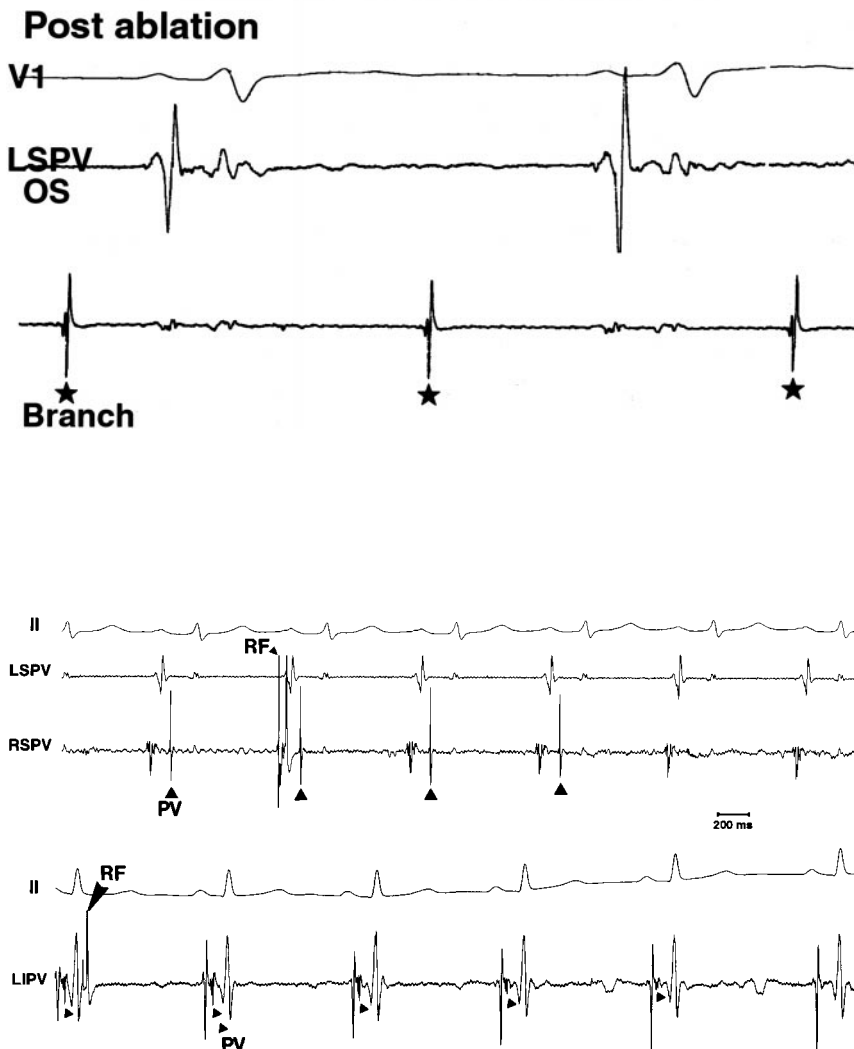
Table 4 compares the variables according to outcome. The presence of a single arrhythmogenic PV and successful elimination of PVPs were significant predictors of success. The success rate was 90% (36 of 40) when PVPs were



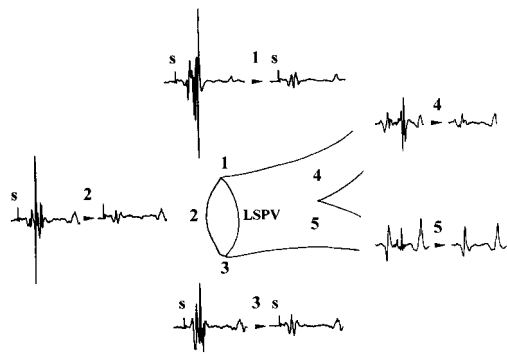
**Figure 6.** LIPV angiogram and electrograms during sinus rhythm showing late potentials distally within both branches. Sharp potential could be followed up to ostium; it is visible at roof and can be discerned at bottom (fusing with LA potential). Ablation at roof of ostium eliminated PVP only in superior branch. Further ablation at bottom of ostium eliminated activity extending into inferior branch. Thus, there appeared to be dual-input connection to LIPV.



**Figure 7.** Sustained regular atrial tachycardia from LSPV with various degrees of exit block, mainly 2:1. First tracing shows characteristic sequence of activation during sinus rhythm, with atrial activation preceding PVP (arrowhead) followed by 3 discharges (\*) from PV, 2 of which are conducted to atria. During sustained tachycardia (second tracing), there is 2:1 exit block from within LSPV. Ablation limited to bottom sector of PV ostial (OS) perimeter (angiogram frame) terminated arrhythmia, and postablation mapping showed that local PV activity was dissociated distally (\*) at slow rate.



**Figure 8.** Two examples of elimination of PV activity by RF delivery. In both examples, within 3 to 4 beats after onset of RF delivery (downward-pointing arrowhead), PV activity (upward-pointing arrowhead) is seen to disappear.



**Figure 9.** Circumferential ostial ablation of LSPV performed during distal coronary sinus stimulation (S) to highlight PVP. RF applications progressively eliminated PVP, as shown in central diagram (3 ostial sites numbered 1, 2, and 3), as well as distally (4 and 5) where PVP was obvious in sinus rhythm.

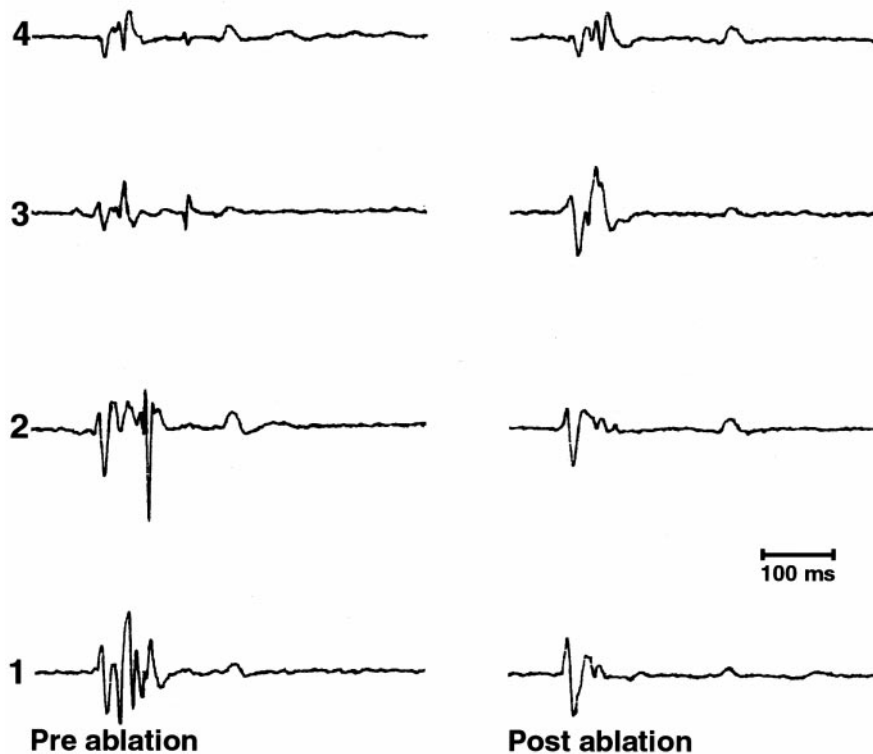
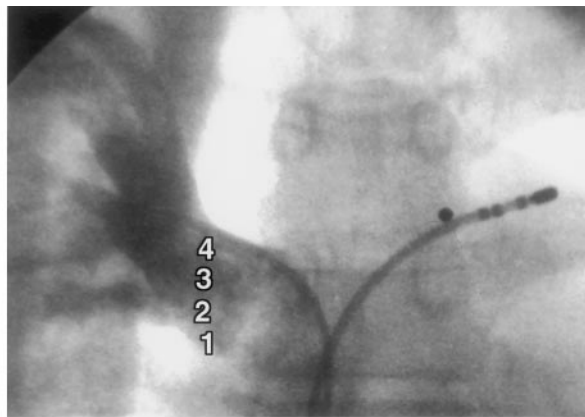
eliminated in all arrhythmic PVs and 55% (27 of 49) when PVPs were still persistent in  $\geq 1$  arrhythmic PVs.

### Discussion

This study describes the results of electrophysiologically directed curative treatment for paroxysmal AF targeting the initiating triggers. It demonstrates plurifocal sources within the PV, a significant extent of local arrhythmic tissue, and better clinical outcome with the interruption of all conduction from the PV.

### Multiple Sources of Ectopy

The study population included consecutively referred patients with drug-resistant paroxysmal AF without selection criteria, thus covering a broad range of situations encountered clinically. Spontaneous ectopy was absent in most patients, and the average AF duration was variable, ranging from 0 to 24 h/d. Spontaneous or provoked AF paroxysms were initiated



**Figure 10.** Focal ablation at bottom of ostium of RSPV eliminated recurrent arrhythmia (after previous ablation) and PVPs. Catheter positions used to record preablation electrograms are shown at top. Fractionated continuum is noted at bottom of ostium, and on mapping progressively more cranially, PVP is progressively delayed. Ablation at site 1 eliminated all evidence of PV electrical activity, as shown from same sites after ablation.



TABLE 4. Comparison of Variables According to Ablation Outcome

	Successes (n=64)	Failures (n=26)	P
Clinical characteristics			
Sex, M/F	49/15	24/2	NS
Age, y	51±10	51±10	NS
Duration of AF, y	5.8±5.2	4.9±4	NS
Structural heart disease, n	14	3	NS
Preprocedural AF duration, min/24 h	366±420	648±469	0.009
Anterior-posterior LA dimension, mm	38±7	41±6	NS
Inferior-superior LA dimension, mm	52±9	54±8	NS
Results			
No. of arrhythmogenic PVs (single/multiple)	25/38*	2/24	0.003
Distal PVP, (abolished/present), n	36/27*	4/22	0.002

\*Patient 11 with a single focus is not included.

similarly by sudden trains of focal discharges, with some PV foci, notably from the LIPV, discharging only in bursts and without isolated ectopy. The prevalence of multiple arrhythmogenic PVs was high (69%), perhaps because of wide inclusion criteria, greater mapping experience, the use of provocative maneuvers with simultaneous exploration of different PV, and repeated electrophysiological studies in cases of recurrence. Moreover, multiple sources of AF in the same PV or even a focal source “wandering” to the atrial edge of the PV were observed. Multiple arrhythmogenic PVs were associated with older age, longer AF duration, and larger atrial dimensions.

### Electrophysiologically Guided Ablation

Ablation guided by mapping ectopy was limited by its unpredictability, its inconsistent inducibility, and the risk of inducing AF requiring cardioversion. In patients with few ectopies, the arrhythmogenic PV could still be readily identified, and then all PVPs were ablated in sinus rhythm at the ostium, possibly eliminating multiple potential foci in the same trunk. LA or distal coronary sinus pacing separated the LA and PVPs, facilitating PVP identification notably in the left PV.

The results indicate that elimination of the PVPs correlated better with clinical success than the acute suppression of arrhythmias. However, it should be noted that a successful outcome could be observed without complete PVP elimination and that some “unsuccessfully” treated patients were remarkably improved with a previously ineffective drug. The PVP reflects activation of muscular LA bands extending into the PV with longitudinal, oblique, or complex courses and ending in a cul-de-sac or even looping back in the LA.<sup>1-3</sup> The source, its course within the pulmonary vein, and its exit into the LA may all be considered appropriate individual targets for ablation. The PVP was recorded over a broader area proximally but with great variability. Therefore, a few seconds of energy application was sufficient at some proximal

sites to eliminate downstream PV muscle activity, whereas wide or repeated RF applications were required in most others. PV disconnection was demonstrated by either dissociated or abolished distal PVP and confirmed by the inability to capture the LA by pacing from the PV. On the other hand, the inability to abolish the arrhythmogenic PVP or its recovery (even in a very discrete area and with a prolonged conduction time) was associated with recurrence of AF. This occurred obviously more frequently for multiple PVs, representing a challenge both in terms of efficacy and safety that may be overcome with the use of more appropriate mapping and ablation catheters.

PV stenosis occurred in 5 patients; however, all had no pulmonary hypertension, so no treatment was required. With the limitation of RF power to <30 W, acute and late PV stenosis was not observed at the ostium (although it occurred in a branch), but a longer follow-up is needed for confirmation. Given this uncertainty, a curative AF procedure based on PV ablation that uses current technologies should be reserved for patients with frequent drug-resistant paroxysmal AF who are exposed to the thromboembolic and hemodynamic risks of persistent arrhythmia and its inherent increased morbidity and mortality.

### References

- Nathan H, Eliakim M. The junction between the left atrium and the pulmonary veins: an anatomic study of human hearts. *Circulation*. 1966; 34:412-422.
- Ito M, Arita M, Saeki K, Tanoue M, Fukushima I. Functional properties of sinocaval conduction. *Jpn J Physiol*. 1967;17:174-189.
- Zipes DP, Knope RF. Electrical properties of the thoracic veins. *Am J Cardiol*. 1972;29:372-376.
- Jaïs P, Haïssaguerre M, Shah DC, Chouairi S, Gencel L, Hocini M, Clémenty J. A focal source of atrial fibrillation treated by discrete radiofrequency ablation. *Circulation*. 1997;95:572-576.
- Haïssaguerre M, Jaïs P, Shah DC, Takahashi A, Hocini M, Quiniou G, Garrigue S, Le Mouroux A, Le Métayer P, Clémenty J. Spontaneous initiation of atrial fibrillation by ectopic beats originating in the pulmonary veins. *N Engl J Med*. 1998;339:659-666.

## Electrophysiological End Point for Catheter Ablation of Atrial Fibrillation Initiated From Multiple Pulmonary Venous Foci

Michel Haïssaguerre, Pierre Jaïs, Dipen C. Shah, Stéphane Garrigue, Atsushi Takahashi, Thomas Lavergne, Méléze Hocini, Jing Tian Peng, Raymond Roudaut and Jacques Clémenty

*Circulation*. 2000;101:1409-1417

doi: 10.1161/01.CIR.101.12.1409

*Circulation* is published by the American Heart Association, 7272 Greenville Avenue, Dallas, TX 75231

Copyright © 2000 American Heart Association, Inc. All rights reserved.

Print ISSN: 0009-7322. Online ISSN: 1524-4539

The online version of this article, along with updated information and services, is located on the World Wide Web at:

<http://circ.ahajournals.org/content/101/12/1409>

**Permissions:** Requests for permissions to reproduce figures, tables, or portions of articles originally published in *Circulation* can be obtained via RightsLink, a service of the Copyright Clearance Center, not the Editorial Office. Once the online version of the published article for which permission is being requested is located, click Request Permissions in the middle column of the Web page under Services. Further information about this process is available in the [Permissions and Rights Question and Answer](#) document.

**Reprints:** Information about reprints can be found online at:  
<http://www.lww.com/reprints>

**Subscriptions:** Information about subscribing to *Circulation* is online at:  
<http://circ.ahajournals.org/subscriptions/>