

# VERTICAL RIB EXPANSION FOR THORACIC INSUFFICIENCY SYNDROME - INDICATIONS AND TECHNIQUE

†KAI-UWE LEWANDROWSKI, MD, ‡ROBERT M. CAMPBELL, JR., MD, AND †JOHN B. EMANS, MD

†DEPARTMENT OF ORTHOPAEDIC SURGERY, CHILDREN'S HOSPITAL, HARVARD MEDICAL SCHOOL, BOSTON, MA

‡CHRISTUS SANTA ROSA CHILDREN'S HOSPITAL, SAN ANTONIO, TX

## ABSTRACT

This paper describes the preliminary experience at Children's Hospital, Boston in the application of a vertical expandable prosthetic titanium rib (VEPTR) implant for the treatment of thoracic insufficiency syndrome (TIS) and congenital spinal deformity. The term thoracic insufficiency syndrome was first introduced in 1993 by Campbell<sup>1</sup> to describe the inability of the thorax to satisfactorily support lung growth, respiratory function or spine development due to congenital and acquired chest wall, spine and other syndromic deformities. Examples of TIS include unilateral hypoplastic thorax and spinal deformity associated with combined congenital scoliosis and rib fusions, and bilateral restrictive thoracic hypoplasia associated with Jeune syndrome (asphyxiating thoracic dysplasia) or Jarcho-Levin Syndrome (multiple vertebral and rib fusion anomalies). Conventional spinal arthrodesis for progressive congenital spinal deformity may exacerbate thoracic insufficiency by stopping growth of an already short spine. Moreover, there is no standard treatment for the usually fatal TIS associated with Jeune or Jarcho-Levin syndromes. Campbell and coworkers<sup>2</sup> pioneered the use of expansion thoracoplasty and VEPTR chest wall distraction to treat TIS. The initial procedure consists of one or more opening wedge thoracostomies and insertion of one or more VEPTR devices, one of which may include a spinal distraction hook (hybrid VEPTR device). The thoracostomies of the hemithorax are expanded maximally at the initial procedure and the devices are placed to stabilize the correction. Repeated surgeries to lengthen the VEPTR are performed on an outpatient basis at appropriate intervals to further correct deformities of the thorax and spine. The device and procedure are still under investigational protocol, but preliminary results<sup>2</sup> suggest that expansion thoracostomy and use of a VEPTR device directly

treats segmental hemi-thoracic hypoplasia by lengthening and expanding the constricted hemithorax, and indirectly treats scoliosis without the need for spine fusion, with probable benefit for the underlying lung. Experience thus far suggests that this procedure is an alternative to early arthrodesis for some severe and complex congenital spinal and chest wall deformities, and may be an effective surgical treatment for TIS associated with Jarcho-Levin, Jeune and other constrictive thorax syndromes.

## I. INTRODUCTION

### I.1 THORACIC INSUFFICIENCY SYNDROME

Thoracic Insufficiency Syndrome (TIS) has been defined by Campbell *et al.*<sup>2</sup> as the inability of the thorax to support normal respiration or lung growth. TIS can be associated with severe malformations of the chest, spine or ribs that result in small thoracic volumes and inadequate lung development, thoracic stiffness and lack of compliance, or prior iatrogenic alterations of spine or thorax resulting in respiratory insufficiency.<sup>6,7</sup> Normally the spine and ribs act together as a dynamic biomechanical structure, which can only work efficiently at respiration within certain parameters.<sup>3,4</sup> When a significant deformity of the thoracic cage exists, it changes the dynamics of this system, and can interfere with normal respiration and lung development. Severely compromised respiratory function in the growing child is typically associated with failure to thrive, as well as the need for frequent hospitalizations associated with respiratory infections.<sup>5</sup> Although some TIS patients may appear to do well during early childhood, as body mass increases the fixed thoracic volume may prove insufficient in later childhood or adulthood.<sup>6</sup> The contribution of early spinal fusion to TIS is not well documented, but is strongly suggested by experience. A recent preliminary radiographic review (Campbell and Emans, unpublished data)<sup>8</sup> of eight Children's Hospital patients who underwent spine fusion at age 5 years or younger was undertaken as a pilot analysis for a related study. Average followup after fusion was 12 years, and all patients had reached maturity. Thoracic spine length averaged 50 percent of normal, as would be expected from spine fusion performed early in growth. However, mean transverse diameter of the thorax at maturity was only 19.3 cm, or approximately 50 percent of published normal values. None of these patients had pre-existing chest wall abnormalities. Some patients may have had coexistent restrictive lung disease. Two additional patients with thoracic hypoplasia following early spine fusion developed severe respiratory insufficiency. The first patient, age 16 years,

Kai-Uwe Lewandrowski, MD is a Clinical Fellow in Orthopaedic Surgery at Harvard Medical School.

Robert Campbell, MD is an Assistant Professor in Orthopaedic Surgery at University of Texas Health Science Center at San Antonio, TX

John B. Emans, MD is an Associate Professor in Orthopaedic Surgery at Harvard Medical School.

Address correspondence to:

John Emans, MD  
Department of Orthopaedic Surgery  
The Children's Hospital  
300 Longwood Avenue  
Boston, MA 02115

has a vital capacity of 20 percent predicted and requires chronic nasal oxygen and intermittent ventilator support. The second patient had a thoracic spinal height of only 13 cm with a thoracic width of 18.5 cm at age 19. At age 22, her vital capacity was 20 percent predicted, and she developed respiratory insufficiency with CO<sub>2</sub> retention. At age 25, she died of respiratory infection. This preliminary review suggests that young children undergoing spine fusion for scoliosis may go on to develop severe thoracic hypoplasia, associated restrictive lung disease and respiratory insufficiency in young adulthood.

## 2. SURGICAL INDICATIONS

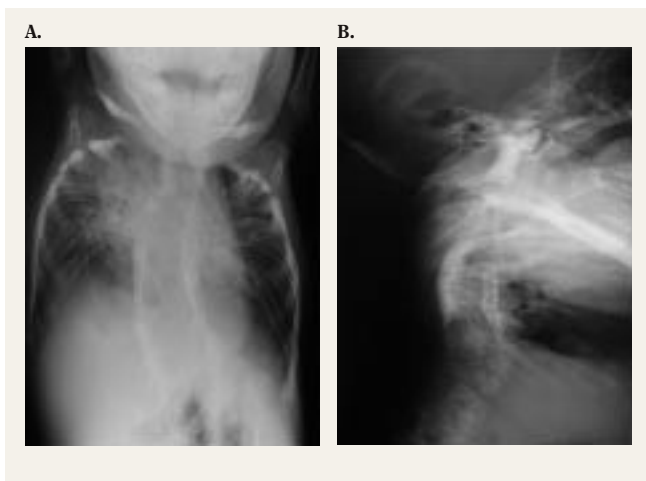
### 2.1 RIB FUSION AND PROGRESSIVE SCOLIOSIS

In normal patients, the thoracic spine is maintained in a state of equilibrium by balance of opposing forces from the ribs. Imbalance in these areas can result in spinal deformities. Rib fusion and scoliosis often occur together in patients with congenital skeletal deformities. Congenitally fused ribs typically cause curvature of the spine toward the area of involvement. In some cases, rib fusion can also occur following thoracotomy.<sup>9,10</sup>

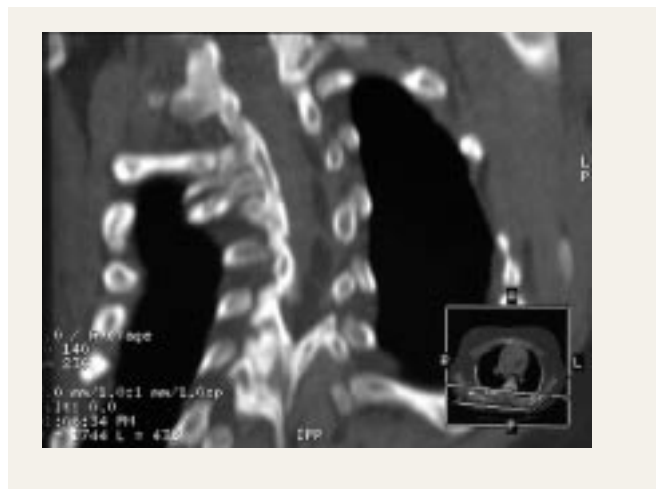
A study of patients with widespread thoracic congenital scoliosis treated with fusion found that patients with rib fusion had a significant reduction in pulmonary vital capacity values at follow-up.<sup>11</sup> Regardless of which deformity occurs first, the combination of scoliosis and rib fusion can severely restrict the thorax and not allow the lungs to develop properly.

### 2.2. HYPOPLASTIC THORAX SYNDROME

Hypoplastic thorax refers to underdevelopment of the chest. It is commonly observed in rare congenital conditions, such as Jeune's Syndrome, achondroplasia, Ellis van Crevald Syndrome, Jarcho-Levin Syndrome (Figure 1), and VACTERL syndrome (Figure 2). The estimated incidence is 1 in 125,000 births for Jeune's Syndrome,<sup>13</sup> and 1 to 4 in 25,000 births for achondroplasia.<sup>14</sup> No incidence figures have been reported in the literature for Ellis van Crevald Syndrome or Jarcho-Levin Syndrome.



**Figure 1.** AP and lateral chest radiograph of patient with Jarcho-Levin syndrome at 2 months of age shows crab-like chest appearance and limited bilateral lung aeration and multiple rib and vertebral body abnormalities.



**Figure 2.** CT-scan of a 2-year old with VACTERL syndrome and progressive congenital lordeo-scoliosis with bilaterally diminished lung volumes and hypoplastic hemithorax. Multiple rib and vertebral body anomalies are present including a bony postero-lateral bar and concave rib fusions. Conventional treatment of this problem would be by anterior and posterior spinal fusion, which likely would halt the progressive curvature, but further shorten an already short thoracic spine and contribute to hypoplastic thorax and respiratory insufficiency (TIS). Alternatively, expansion thoracostomies and insertion of VEPTR device with repetitive distraction offers control of the progressive curve during growth while expanding the hemi thorax and encouraging lung growth. Ultimately spinal fusion would probably be needed, but preferably at an older age, after more spine, lung and thoracic growth was achieved.

Only 43 cases of Jarcho-Levin Syndrome have been reported in the literature.<sup>12</sup> Jarcho-Levin Syndrome has been described as a lethal autosomal recessive form of short dwarfism. Also called spondylothoracic dysostosis, it is characterized by extensive vertebral and chest-wall abnormalities, including a symmetric “crab-like” chest that is caused by the ribs crowding and fusing at their origin at the spine and fanning out along their lengths. Patients affected with Jarcho-Levin Syndrome can have various numbers and shapes of ribs as well as vertebral segmentation defects consisting of fusion or absence of vertebrae, hemivertebrae, and butterfly vertebrae. Mild scoliosis, secondary to the multiple hemivertebrae, is present in most patients. The existence of multiple bony abnormalities of the thoracic cavity can cause marked respiratory compromise and lead to death.<sup>12</sup>

The condition is seen in two forms: mild and serious. The dominant type, known as *spondylocostal dysostosis*, seems to be a milder abnormality and patients may have an essentially normal life span although death at infancy has been reported. In contrast, the severe form of this condition is the autosomal recessive type and tends to be a more lethal form of the syndrome, with death due to respiratory insufficiency commonly occurring within the first 2 years of life.<sup>12</sup>

Jeune's Syndrome is an autosomal recessive skeletal disorder with major manifestations in the thoracic cage.<sup>14-22</sup> The narrow bell-shaped chests and short horizontal ribs seen in children born with Jeune's Syndrome often result in early deaths due to respiratory failure.<sup>18, 20, 21</sup> Some patients with a mild form of the syndrome survive infancy, but develop progressive renal failure later in their childhood. A total of 93 juvenile cases involving respiratory problems have been compiled.<sup>14-22</sup> Of these 93 cases, 51 patients had died at

the time the articles were submitted for publication. Deaths occurred from before birth (1 elective abortion, 1 stillborn) until the age of 4 years 2 months.

### 2.3. FLAIL CHEST

In flail chest, the chest wall is destabilized either due to congenital causes (e.g., rib agenesis), acquired causes (e.g., separation of thoracopagus conjoined twins, resection of ribs because of tumor), or trauma. Reportedly, 1 in 300 births has some sort of congenital chest deformity.<sup>31</sup> However, only 42 known cases of congenital flail chest have been described in children under the diagnosis of “Cerebro-costalmandibular Syndrome.”<sup>25</sup> Children with this syndrome display rib gaps causing a very narrow thorax, hollow chest and other deformities. Among the 42 juvenile cases reported in the literature, 33 had associated respiratory difficulty, and 25 died. No reconstruction or other intervention was described, nor was there long-term follow-up on the survivors. Another study presents data on 18 children with congenital chest wall deformities or malformations of various degrees of severity.<sup>26</sup> Of these 18 children, 15 were either stillborn or neonatal deaths.

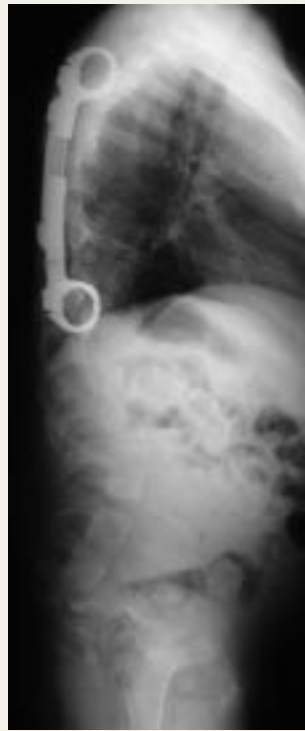Thoracopagus conjoined twins may be separated surgically if they have independent hearts and great vessels. The obvious result is a large chest wall defect in one or both individuals. Although the literature estimates 50% survival for all separated conjoined twins,<sup>27</sup> mortality figures for separated twins with such chest defects have not been identified.

Resection of pediatric chest wall tumors typically necessitates the removal of several ribs, resulting in a large chest wall defect.<sup>28</sup> The long-term result of such extensive surgery is scoliosis, which curves toward the side of the rib resection. Scoliosis has been reported in 90 to 100% of patients who underwent thoracoplasty (surgical rib resection).<sup>28</sup> The scoliosis is progressive, and the younger the patient is at the time of resection, the more severe the progression.

Walton et al.<sup>29</sup> reviewed the case histories of 11 patients (five adults and six children) who presented with scoliosis after multiple rib resection for several disorders. All 11 cases developed progressive scoliosis with concavity directed toward the side of the rib resection, and the younger the age at the time of rib resection, the more severe the progression. The rate of progression was greatest during the first ten years after rib resection. The five patients who presented as adults were treated in several ways, with only one requiring spine fusion. However, five of the six children required spine fusion to prevent progression of scoliosis. Despite these surgical interventions, scoliosis towards the prior rib resection resulted in all cases.

### 3. THE TITANIUM RIB IMPLANT

The titanium rib<sup>2,6,31</sup> is an implantable, expandable prosthetic device used in conjunction with opening wedge thoracostomy to accomplish an expansion thoracoplasty. The Vertical Expansion Prosthetic Titanium Rib (VEPTR) implant is a sliding titanium construct, roughly rectangular in cross-section with two standard curvatures, both conforming to the



**Figure 3.** The VEPTR device is shown implanted in a child multiple congenital vertebral anomalies and progressive scoliosis. The implant's curvature conforms to the shape of the thoracic cage. The rod is placed vertically along the chest wall by attaching each end to healthy ribs above and below the opening wedge thoracostomies.

**Figure 4.** Vertical Expansion Prosthetic Titanium Rib (VEPTR) Device consisting of extensible titanium rod/sleeve constructs of varying length. Two radii of curvature are available for different applications to conform to or modify the surface contour of the thoracic cage. Ring-like capturing devices (rib cradle and end cap) on each end are placed around one or two healthy ribs above and below the expansion thoracostomies for chest expansion. The basic configuration consists of superior cradle, cradle end halves, cradle locks or rib sleeve, inferior cradle, or lumbar extension, and distraction locks. The inferior cradle may be replaced with a lumbar extension rod/hook combination to act as a spinal distraction device (hybrid device). With growth, the rod/sleeve is extended (distracted) through a small incision. When maximum length is achieved, the rod/sleeve is replaced with a longer construct.



shape of the thoracic cage into which it is being implanted. The construct is placed vertically along the chest wall by attaching each end to healthy ribs above and below the site of abnormality (Figure 3). In addition to distracting and expanding the chest wall, it may act as a protective internal splint over areas where ribs are missing. The implanted VEPTR device can also indirectly apply distraction to the spinal column, controlling or improving spinal deformity.

As shown in figure 4, the VEPTR consists of the:

- superior cradle
- cradle end halves
- cradle locks
- rib sleeve
- inferior cradle, or lumbar extension
- distraction locks
- low profile lamina hook, or sacral ala hook and connector (if lumbar extension is used)
- 2.37mm rod for the attachment of osteotomized ribs to the VEPTR device in patients with Hypoplastic Thorax Syndrome dependent upon whether or not a lumbar extension is used.

The superior and inferior sections of this device each consist of two pieces, a cradle and cradle end half. The semicircular end of the cradle can be adjusted to different angles (0°, 30° right, and 30° left) to accommodate patient anatomy, and is connected to the cradle end half by a cradle lock to encase the rib. The cross-section of the proximal ends of the rib cradles is “T-shaped” for enhanced strength. The superior cradle and inferior cradle (or lumbar extension) attach to the rib sleeve by distraction locks. The rib sleeve is the central section of the construct. It serves as a track into which the cradles slide. The hole in the rib sleeve lines up with one of the blind holes on the rib cradle. The position of the inferior cradle assembly along the rib sleeve depends on the desired length of the overall rib prosthesis construct.

### **3.1 IMPLANTATION AND ASSEMBLY**

The superior cradle is placed over the patient’s upper rib(s) and secured together with a cradle lock, encasing the healthy rib(s). The rib sleeve slides onto the proximal end of the superior cradle and is secured with a distraction lock. The inferior cradle slides into the rib sleeve and is positioned and secured on the lower healthy rib(s). The inferior cradle is distracted to the desired length, and the rib sleeve and inferior cradle are secured together with a distraction lock.

In situations where scoliosis extends into the lumbar spine, a lumbar extension can be used in place of the inferior rib cradle and cradle end half. The distal portion of the lumbar extension is a 6.0mm straight rod that allows for attachment to the lumbar spine with a low profile spinal hook. When attachment to the lumbar lamina is not possible, a sacral ala hook is attached to the lumbar extension with a connector, and the device is positioned on the patient’s sacrum.

## **4. SURGICAL TECHNIQUE**

### *Patient Positioning*

The patient is placed in a lateral decubitus position with thorax and preferably the entire arm prepped and draped free. Monitor leads for somatosensory potentials are attached.

### *Exposure*

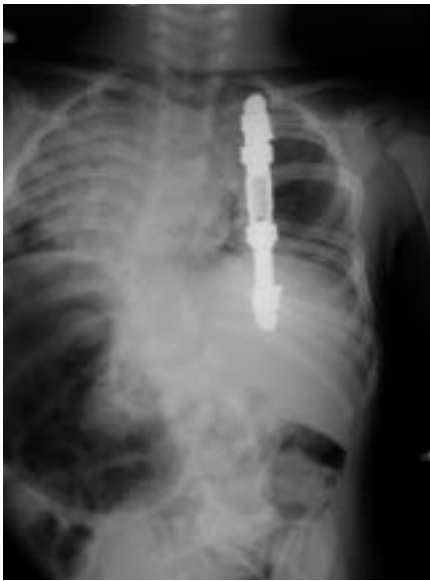The exposure is designed to allow access to the entire chest wall for device placement and expansion opening wedge thoracostomy. Repeat exposures for rod lengthening will be needed, and the incision must be planned with this in mind. When a hybrid device is needed, a separate short midline spinal incision is used for placement of the spinal hook. The “J” shaped skin incision starts as proximally as needed in the interval between scapula and spine, extends distally as far as needed and then curves gently anteriorly. The medial flap of the skin incision is mobilized medially to permit a more medial muscular incision. A laterally based flap of all the muscles attached to the scapula is developed and retracted anteriorly and laterally, exposing the bony chest wall. The proximal and distal extent of this flap depends upon the location of planned thoracostomy and device placement. Dissection should be extraperiosteal, preserving vascular supply to the ribs and leaving intercostal muscles and vessels as intact as possible. A medially based flap of paraspinal muscle is elevated to provide exposure down to the transverse processes of the spine. Cephalad and caudad placement sites for the superior and inferior rib cradles and cradle end halves are chosen. The upper cradle should generally not involve the first rib, nor pass anterior to the middle scalene muscle to avoid endangering the brachial plexus and vascular supply to the arm. The lower cradle should not end on unstable or “floating” ribs. When ribs are small or hypoplastic, the cradles and cradle end halves should encompass two ribs. Usually the device is placed as far posterior, close to the spine as possible, expanding the chest and controlling typical lordo-scoliotic deformity. More than one VEPTR device may be needed with devices placed at approximately 4 cm intervals.

### *Cephalad Implant Insertion*

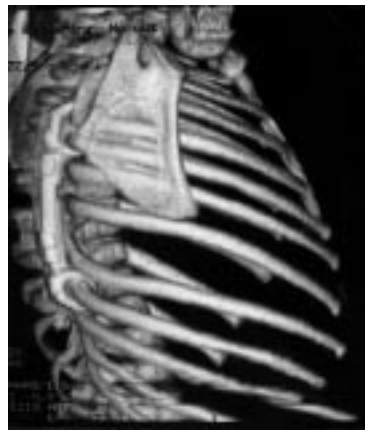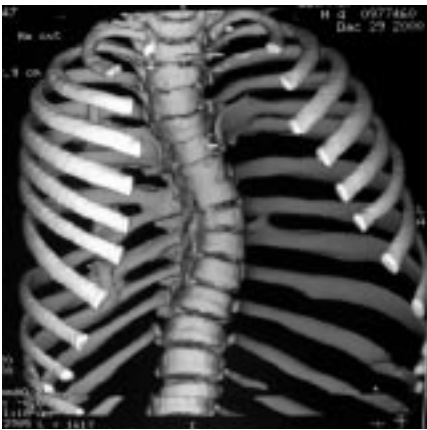An incision approximately 1.5 cm is made under the superior osseous rib where the prosthesis is to be attached; the medial periosteum is carefully elevated with a Freer elevator. The orientation of the first rib to the rest of the thorax is used to determine the appropriate superior cradle angulation required (30 degrees right, left or 0 degrees). The Cradle Trial is used here to prepare the interval for the Superior Cradle. The Superior Cradle is then threaded in the interval between the periosteum and the osseous rib and then rotated into its longitudinal position. Next the Cradle End Half is threaded over the top of the rib through the same interval and snapped into the Superior Cradle using a Cradle Lock Forcep loaded with a Cradle Lock to encase the rib.

### *Caudal Implant Insertion*

The procedure for implantation for the distal portion of the prosthesis proceeds in the same manner. The longitudinal alignment of the device should be chosen to obtain the best



**Figure 5.** In this child with VACTERL, fused ribs resulted in progressive scoliosis which was treated with two opening wedge expansion thoracostomies of the concave hemithorax with primary lengthening by a chest wall distractor.



**Figure 6.** Three-dimensional CT-reconstructions are shown demonstrating multiple fused ribs, and vertebral anomalies resulting in progressive scoliosis which was treated with a VEPTR (Figure 6A). Thorax expansion is evident in figure 6B after thoracoplasty and opening wedge thoracostomy of the concave hemithorax with primary lengthening by a chest wall distractor.

perpendicular orientation of attachment to both the proximal and distal ribs. Either a neutral or 30 degree rotation is available for alignment of the cradle construct in relationship to the Rib Sleeve. If a Superior Cradle is required more anteriorly, it is recommended that it be placed on a more inferior rib anteriorly so that it is distal to the neurovascular bundle. Once all the Superior Cradles are in place, they can be rotated around the osseous ribs away from the chest wall defect for inspection of the underlying lung.

#### **Expansion Thoracoplasty Techniques**

Enlargement and lengthening of the constricted hemithorax and indirect control of spinal curvature is achieved by one or multiple opening wedge thoracostomies. If a congenital chest wall defect is present, the remaining soft tissues may be incised in line with the ribs to allow an opening wedge. If there are bony fusions of ribs, as commonly present with congenital spinal anomalies and constricted hemithorax (Figures 5 and 6), fused ribs are separated with an oscillating saw, protecting the underlying parietal pleura, and opening wedge thoracostomy produced in the newly created interval between

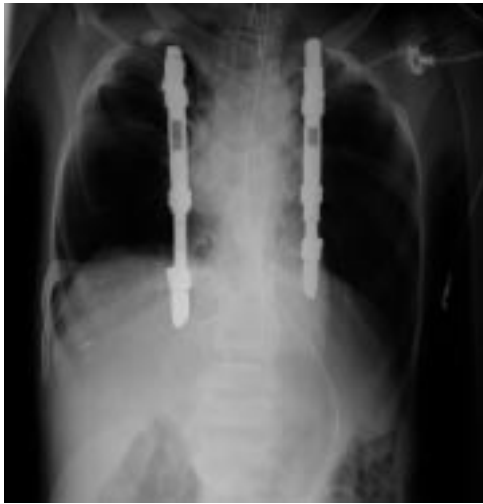previously fused ribs. Where there are multiple contiguous rib fusions, ribs may be divided into groups and opening wedge thoracostomies performed between groups. Posteriorly the thoracostomy must extend back to the transverse processes to permit expansion between adjacent ribs. Confluent bony bars joining ribs medial to transverse processes should be resected down to the vertebral column. Anteriorly, the thoracostomy must extend to near the costal cartilage to permit free expansion of the thoracostomy interval. The thoracostomy is spread slowly to allow the intact parietal pleura to stretch. If the pleura is torn, artificial pleura of Gore-Tex sheeting is placed loosely over the underlying lung and sutured at the periphery of the thoracostomy to parietal pleura, leaving enough material for present and future expansion. A chest tube is placed in the chest cavity and brought through to the skin.

Once the desired correction of the hemithorax deformity is achieved, the assembled VEPTR devices are implanted unexpanded, then tensioned 0.5 cm to stabilize it. Excessive initial distraction may lead to premature cutout of the device, but correction and expansion are easiest to achieve at the initial procedure. Intubation and ventilatory support are typically required for several days postoperatively. Patients usually are hospitalized for 7 to 10 days. To accommodate later growth of the thorax, the devices are lengthened through 3cm incisions in out-patient surgery, two to three times a year. When the expandability of the device has been exhausted, they are replaced by surgery on an outpatient basis.

#### **5. INVESTIGATIONAL PROTOCOL**

The titanium rib implant and the expansion thoracoplasty procedures made possible by its use were developed by Campbell and coworkers<sup>2</sup> at Christus Santa Rosa Children's Hospital in San Antonio, TX. The devices were first implanted in 1989. A subsequent FDA sponsored feasibility study was conducted involving 33 patients; the safety and efficacy data collected during this study has enabled the surgical technique and the study methodology to evolve as well as allowing important clinical endpoints to be more clearly defined. These results, which suggest that the VEPTR is safe and effective for infant and juvenile TIS patients and are likely superior to alternate therapies currently available, form a basis for a multicenter clinical currently underway.

The multi-center protocol includes a regimented study methodology, which is designed to be nonrandomized. Participating centers include Christus Santa Rosa Children's Hospital in San Antonio, Boston Children's Hospital and Children's Hospital of Pittsburgh. Boston Children's Hospital and Children's Hospital of Pittsburgh have enrolled 10 patients to date. Pre-operative evaluation includes pulmonary and general surgical evaluation, 3-D CT scan and standardized thoracic measurements. Long-term follow-up data will be collected by evaluating all patients annually after the immediate



**Figure 7.** The VEPTR implant and expansion thoracostomies were used bilaterally to enlarge a small thorax in a child with Jarcho-Levin syndrome and

two-year evaluation until the final enrolled patient has been followed for two years. During the follow-up period, expansion or replacement of components of the VEPTR will be necessary to accommodate the patient's growth, and/or to further correct spinal or thoracic deformity. Patients will serve as their own control in that efficacy parameters will be measured and analyzed post-operatively in comparison to baseline values.

### 5.1 CURRENT INCLUSION CRITERIA

To be enrolled in the study, the patient must be six months of age or older, up to skeletal maturity as defined by closure of the epiphyseal plates of the long bones and fusion of the iliac apophysis to the underlying iliac crest (Risser sign +5). The primary indication of Thoracic Insufficiency Syndrome is clinically and radiographically defined as (1) Flail Chest Syndrome (congenital chest wall defect, acquired surgical chest wall defect, chest wall tumor resection, surgical separation of conjoined twins, traumatic flail chest), (2) Congenital restrictive chest wall syndrome, (3) severe rib fusion with progressive thoracic scoliosis without vertebral anomalies, (4) moderate rib fusion with secondary chest wall constriction by progressive thoracic congenital scoliosis (thoracogenic scoliosis) (5) hypoplastic thorax syndromes (Jeune's syndrome, Achondroplasia, Ellis van Crevald syndrome, Jarcho-Levine syndrome), (6) progressive spinal deformity (scoliosis/kyphosis) in patients without rib anomaly in patients of age 10 years or younger, (7) progressive thoracic congenital scoliosis with absence of rib fusion, (8) progressive scoliosis of neurogenic or idiopathic origin, and (9) primary progressive Thoracic Insufficiency Syndrome (progression of chest wall malformation, or worsening pulmonary insufficiency).

### 5.2 EXPECTED OUTCOMES












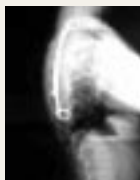




The goal of this prosthetically aided widening of the chest is to facilitate lung growth and to ultimately counteract, prevent or reverse thoracic insufficiency. Additional goals include stabilization of the spinal and clinical deformity, preservation of thoracic spine growth potential, with the overall objective being improvement of volume, symmetry and function of the thorax, and maintenance of these improvements during growth.

### 6. CHILDREN'S HOSPITAL EXPERIENCE







The VEPTR device is currently being used investigational to treat patients with thoracic insufficiency syndrome. At Children's Hospital in Boston, the majority of the nine patients who have received the VEPTR implant were treated for congenital scoliosis or a short thorax (Table 1). Although follow up is currently limited, preliminary results of the patients with thoracic insufficiency syndrome secondary to progressive scoliosis enrolled at this institution seem to corroborate findings of an earlier feasibility study.<sup>30</sup> All nine primary and both secondary patients treated at Boston Children's Hospital underwent one or more expansion opening wedge thoracostomies of the concave hemithorax with primary lengthening by the VEPTR device with further secondary lengthening at 4 to 6-month intervals. The current average thoracic spinal height increase is 0.8 cm/year. Complications observed included device cutout through the rib, which was managed by extending the device to the adjacent rib below, and transient neurapraxia of the upper extremity. Two patients with severe Jarcho-Levin syndrome for whom surgical treatment was planned died of respiratory insufficiency while awaiting enough growth to permit expansion thoracostomy and insertion of the smallest available VEPTR device (Table 1, case *AL* and case *RJ*).

### 7. CONCLUSIONS

Expansion thoracoplasty using the Vertical Expansion Prosthetic Titanium Rib implant (VEPTR) as a chest wall distractor is currently being performed at the Christus Santa Rosa Children's Hospital in San Antonio, Texas, the Boston Children's Hospital and Children's Hospital in Pittsburgh. An initial review of the procedure appears to indicate that VEPTR expansion thoracoplasty is successful in directly treating segmental hemithorax hypoplasia from fused ribs, addressing thoracic insufficiency syndrome by lengthening and expanding the constricted hemithorax, indirectly correcting scoliosis in the young child without the need for spine fusion, with probable benefit to the underlying lung. Further study of the method and clinical result will indicate how the VEPTR-system can be further materially improved.

Table 1 Demographic Patient Data and Implantation Sites					
Patient	Age [Years]	Diagnosis	Implantation Site	PA View	Lateral View
GK	1.2	VATERCL, congenital scoliosis, spinal anomalies	T4-T10, left		
LZ	2.4	Progressive congenital scoliosis	T3-L2 left, T4-T8 left		
LR	4.1	Congenital scoliosis	T5-T9 right		
MS	1.6	Congenital kyphoscoliosis	T4-T7 right, T4-T8 right, then T3-T9 left and T3-T10 left		
RS	3.3	Congenital Scoliosis due to rib fusion with Thoracic insufficiency syndrome			
SE	10	Thoracogenic scoliosis, rib fusion, restricted pulmonary volume	T4-T9 right		
TK	1	Congenital scoliosis	T4-T8 left		
WC	2.2	VATERCL, congenital scoliosis, right rib fusion	T2-T5 right		

**Table 1 Cont. Demographic Patient Data and Implantation Sites**

Patient	Age [Years]	Diagnosis	Implantation Site	PA View	Lateral View
YH	3.3	Congenital scoliosis, rib fusion, TIS	T4-T7 left		
AL	1.6	Jarcho-Levin syndrome, severe tracheal stenosis	Died awaiting enough growth to permit thoracostomy, insertion of VEPTR		
RJ	0.9	Jarcho-Levine syndrome, severe caudal regression syndrome	Died awaiting enough growth to permit thoracostomy, insertion of VEPTR		



## References

1. **Campbell RM.** 1993. Personal communication to K.U. Lewandrowski and John Emans.
2. **Campbell RM., Smith MD, Mayes TC, Mangos JA, Willey-Courand, DB, Surber, J.** The treatment of thoracic insufficiency syndrome associated with scoliosis and fused ribs, Presented at the American Association of Orthopaedic Surgery, March 2000, Orlando, FL.
3. **Tepper, RS, Morgan WJ, Cota K, et al.** Physiologic growth and development of the lung during the first year of life. *Am Rev Respir Dis* 1986;134:513-9.
4. **Harding CO, Green CG, Perloff WH, et al.** Respiratory complications in children with spondyloepiphyseal dysplasia congenita. *Pediatr Pulmonol* 1990;9:49-54.
5. **Hull D and Barnes ND.** Children with small chests. *Arch Dis Child* 1974;47:12-19.
6. **Dimeglio A.** Growth of the spine before age 5 years. *J Pediatr Orthop*, Part B, 1993;1:102-7.
7. **Damsin JP, Cazeau C and Carlouz H.** Scoliosis and fused ribs. A case report. *Spine* 1997;22:1030-2.
8. **Campbell RM. and Emans JB,** Personal communication.
9. **Wong-Chung J, France J, Gillespie R.** Scoliosis caused by rib fusion after thoracotomy for esophageal atresia: report of a case and review of the literature. *Spine* 1992;17:8514.
10. **Garcia VF, Seyfer AE, Graeber GM.** Reconstruction of congenital chest-wall deformities. *Surg Clin North Am* 1989;69:1103-18.
11. **Day GA, et al.** Pulmonary functions in congenital scoliosis. *Spine* 1994;19:1027-31.
12. **Mooney JF, Emans JB.** Progressive kyphosis and neurologic compromise complicating spondylothoracic dysplasia in infancy (Jarcho-Levin syndrome). *Spine* 1995;20:1938-42.
13. **Copeland-Fields LD, et al.** Discharge planning: pediatric case study of Jeune's asphyxiating thoracic dystrophy. *Crit Care Nurse* 1995;5:61-70.
14. **Giorgi PL, et al.** Mild form of Jeune syndrome in two sisters. *Am J Med Genet* 1990;35:280-2.
15. **Phillips CI, Stokoe NL, Bartholomew RS.** Asphyxiating thoracic dystrophy (Jeune's disease) with retinal aplasia: a sibship of two. *J Pediatr Ophthalm Strabismus* 1979;16:279-83.
16. **Fruchter Z, Enzchescu I.** Asphyxiating thoracic dystrophy (Jeune's syndrome) Radiological Findings. *Romanian Med Rev* 1970;14:46-50.
17. **Airede AK.** Asphyxiating thoracic dystrophy (Jeune's disease): a case report. *East Afr Med J* 1994;71:67-9.
18. **Davis JT, et al.** Lateral thoracic expansion for Jeune's asphyxiating dystrophy: a new approach. *Ann Thorac Surg* 1995;60:694-6.
19. **Skiptunas SM, Weiner S.** Early prenatal diagnosis of asphyxiating thoracic dysplasia (Jeune's syndrome)—value of fetal thoracic measurement. *J Ultrasound Med* 1987;6:41-3.
20. **Tahemia AC, Stamps P.** Jeune syndrome (asphyxiating thoracic dystrophy). Report of a case, a review of the literature, and an editors commentary. *Clin Pediatr* 1977;16:903-8.
21. **Todd, DW, Tinguely SJ, and Norberg WJ.** A thoracic expansion technique for Jeune's asphyxiating thoracic dystrophy. *J Pediatr Surg* 1986;21:161-3.
22. **Whitley CB, et al.** Direct hyperbilirubinemia and hepatic fibrosis: a new Presentation of Jeune syndrome (asphyxiating thoracic dystrophy). *Am J Med Genet Suppl* 1987;3:211-20.
23. **Singh M, et al.** Hydrocephalus in asphyxiating thoracic dystrophy. *Am J Med Genet* 1988;29:391-5.
24. **Garcia VF, Seyfer AE, Graeber GM.** Reconstruction of congenital chest-wall deformities. *Surg Clin North Am* 1989;69:1103-18.
25. **Plötz FB, et al.** Cerebro-Costo-Mandibular syndrome. *Am J Med Genet* 1996;62:286-92.
26. **Day GA Upadhyay SS, Ho EK, Leong JC, Ip M.** Pulmonary functions in congenital scoliosis. *Spine* 1994;19:1027-31.
27. **Simpson JS.** Separation of conjoined thoracopagus twins, with the report and additional case. *Can J Surg* 1969;12:89-96.
28. **Kawakainin, et al.** Scoliosis secondary to rib resection. *J Spinal Disord* 1994;7:522-7.
29. **Gellert K, Agnes A, Benhidjeb T, Zanow J Muller JM.** Surgical therapy of malignant thoracic wall tumors. *Chirurg* 1995;66:1220-3.
30. **Reid CS, et al.** Cervicomedullary compression in young patients with achondroplasia: value of comprehensive neurologic and respiratory evaluation. *J Pediatr* 1987;110:522-30.
31. **Grass PJ, Soto AV and Araya HP.** Intermittent distracting rod for correction of high neurologic risk congenital scoliosis. *Spine* 1997;22:1922-7.