

# Uveitis in cats

**Nicola Parry BSc MSc BVSc MRCVS Dip ACVP**

TUFTS UNIVERSITY CUMMINGS SCHOOL OF VETERINARY MEDICINE, 200 WESTBORO ROAD,  
NORTH GRAFTON, MASSACHUSETTS, 01536

**Federica Maggio DVM DipACVO**

TUFTS V.E.T.S, 525 SOUTH STREET, WALPOLE, MA 02081

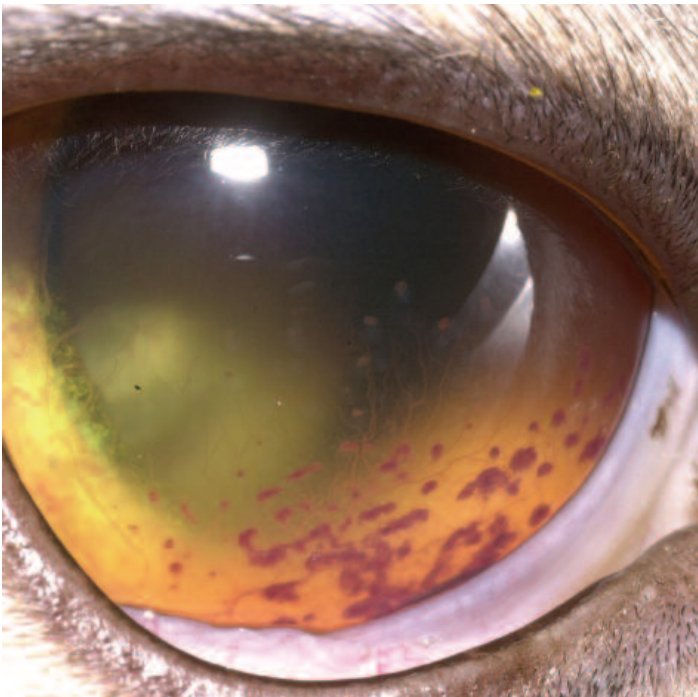
This article, the second in a two-part series on uveitis in small animals, outlines the more common causes and diagnosis of this condition in cats. The reader is referred to the first article for a review of the uveal tract and general information about the pathogenesis and treatment of uveitis in small animals.

## INTRODUCTION

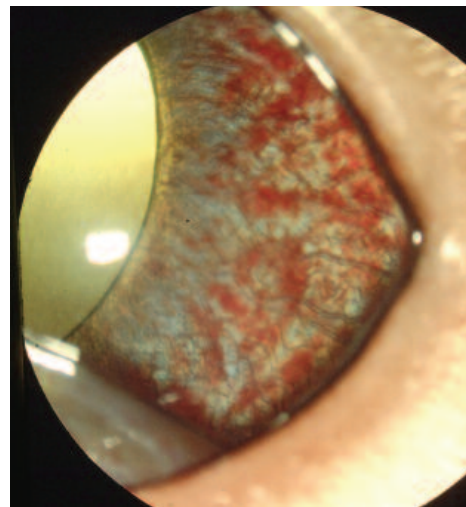
Uveitis is one of the most frequent and significant ophthalmic diseases in cats. As discussed in the first article, intraocular inflammation is predominantly triggered by tissue and vascular damage with subsequent release of inflammatory mediators and breakdown of the blood-ocular barrier, so the rich blood supply of the uveal tract makes it a prime target for disease originating elsewhere in the body. It must be remembered that regardless of aetiology, all cases of uveitis are a consequence of the host's immune response that produces most of the intraocular pathology, although some of the intraocular pathology could be caused by the physical injury in the case of trauma-induced uveitis.

The clinical signs of uveitis in cats are similar to those in dogs (see previous article). Uveitis is a

painful condition and acute cases may involve blepharospasm, photophobia, squinting and excessive lacrimation. Signs are frequently bilateral, but may be unilateral depending on the aetiology. Conjunctival hyperaemia, corneal oedema, aqueous flare, keratic precipitates (KPs) (Fig. 1) (aggregates of inflammatory cells attached to the ventral corneal endothelium) which tend to settle ventrally and therefore need to be carefully looked for behind the third eyelid; and hypopyon (as mentioned later under FIP) are commonly seen. As in dogs, fibrin or red blood cells (hyphaema) may leak into the anterior chamber as a result of the blood ocular barrier breakdown. Iris colour often becomes darker and duller as a result of vascular dilation, neovascularisation of the anterior surface of the iris (rubeosis iridis) (Fig. 2) and/or infiltration of the iris stroma by inflammatory or neoplastic cells: these changes in cats are more easily identified than in dogs, since the feline iris is usually



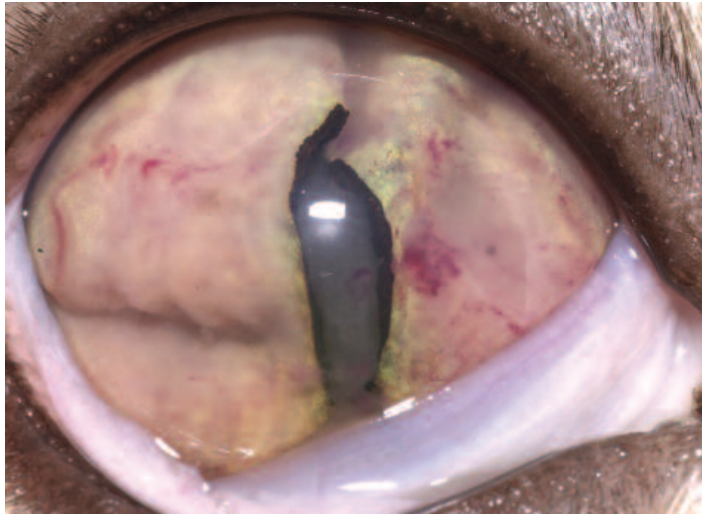
**Fig. 1:** Several hyporeflexive cellular deposits ('keratic precipitates') are attached to the ventral corneal endothelium. Superficial corneal vascularisation is also visible.



**Fig. 2:** Diffuse neovascularisation on the iris surface (rubeosis iridis) associated with uveal vascular congestion.

lighter in colour than the canine one. Such infiltrates of inflammatory or neoplastic cells may change iris shape and mobility, while fibrinous exudate may cause the iris to adhere to the lens (posterior synechiae) (Fig. 3). In combination with inflammatory cell infiltrates, these synechiae may block the iridocorneal drainage angle resulting in secondary glaucoma. As a result of the action of prostaglandins on the sphincter iris muscle, on uveal outflow and aqueous humour production, miosis, anisocoria and decreased intraocular pressure are also frequent presentations. Inevitably, however, intraocular pressure may also be increased in cats that

develop glaucoma secondary to uveitis. Intermediate uveitis or 'pars planitis' is characterised by a collection of inflammatory cells visible on the posterior lens capsule and/or in the anterior vitreous, often with a 'snow banking' effect. It has been frequently associated with intraocular inflammation secondary to FIV.



**Fig. 3:** Severe chronic anterior uveitis: the whole iris is distorted by cellular infiltrates and fibrin strands on the iris surface. Iridial neovascularisation and haemorrhages are also present. A cataract is visible through the pupil.

The breakdown of the blood-ocular barrier at the level of the retinal vessels and retinal pigmented epithelium is responsible for the posterior ocular signs of fluid leakage and infiltration of cells or infectious agents. Subsequently retinal oedema and detachment, chorioretinitis, haemorrhages and optic neuritis are common ocular findings.

Although the pathogenesis and general clinical signs of feline uveitis are similar to those in dogs, cats often appear to be more resistant to pain and mask signs of discomfort until the ocular signs are extremely advanced and severe. In addition, initial clinical findings can be subtle and their detection may benefit from the use of specific instrumentation such as the biomicroscope. For example, it is not unusual for a relatively clinically quiet eye to have microscopic and almost undetectable KPs on the ventral corneal endothelium which may be easily missed unless specifically looked for. Even ocular redness, due to conjunctival hyperaemia or ciliary flush (one of the most common signs of uveitis in dogs) may be less apparent in cats. As in dogs, however, chronic uveitis in cats is responsible for severe secondary intraocular findings such as synechiae, iris bombe, glaucoma, retinal atrophy and phthisis bulbi.

According to a 1991 retrospective study of cats with anterior uveitis, secondary glaucoma was a common sequel to ocular inflammation, being present in up to 46% of patients either at the time of initial diagnosis or on follow-up examinations, and was found to a higher degree in cases of idiopathic anterior uveitis.

Lens luxation as a sequel to severe and chronic glaucoma was found in fewer patients. Secondary lens cataractous change is frequently reported in cases of feline chronic uveitis, possibly as a result of the influence of the inflammatory agents on lens metabolism. Since glaucoma, cataract and lens luxation are relatively uncommon as primary conditions in the feline population, the detection of any of these pathologies in cats should always prompt the investigation of concomitant uveal inflammation.

### DIAGNOSIS

As discussed in the first article, intraocular inflammation is diagnosed primarily as a result of observation of ocular signs. Careful ocular examination, together with intraocular pressure measurement and fluorescein staining, is the main diagnostic tool for diagnosis. The collection of an accurate history is extremely important: feline infectious peritonitis (FIP) most commonly affects younger animals, while toxoplasmosis and FIV/FelV-related signs tend to be more common in active outdoor cats. Even if intraocular signs are not pathognomonic for a specific disease, they may suggest certain diseases (see below).

Once a diagnosis of anterior and/or posterior and/or intermediate uveitis is reached, every effort should be made to identify a cause of the condition. A complete physical examination along with any relevant diagnostic tests, ideally a complete blood count, serum biochemistry panel and urinalysis, as well as specific serological tests for the most common infectious causes of feline uveitis, as outlined later, should be performed. Further diagnostics (such as thoracic radiographs and abdominal ultrasound, as well as fine needle aspiration or biopsy of bone marrow or any masses) may be necessary to rule out systemic involvement in neoplastic or infectious cases. Ocular ultrasound is also indicated in cases of intraocular neoplasia or haemorrhage that may interfere with visualisation of the ocular structures.

Unfortunately despite intensive diagnostic efforts, often the aetiology of uveitis remains undetermined and such cases are designated as idiopathic. Frustratingly, correlation of ocular signs with serological or other laboratory data for a specific infectious aetiology is not always straightforward, because detection of antibodies against infectious agents does not necessarily indicate active infection; antibodies to various organisms are found in healthy cats (e.g. reported prevalences include 30–50% for *Toxoplasma gondii*, 25–80% for feline coronavirus, 75–93% for *Bartonella* spp., and 10–31% for feline herpesvirus).

To further confound the situation, coinfections may arise: FIV positive cats may develop uveitis secondary to other opportunistic agents, such as *T. gondii* or *Cryptococcus neoformans* as a result of viral-induced immunodeficiency. FelV and *T. gondii* coinfections have also been described.

Consequently in many disease situations (such as FIP, feline leukaemia/lymphoma, toxoplasmosis, intraocular tumours and most systemic mycoses) cytological or histopathological confirmation (via aqueo/vitreocentesis or biopsy respectively) may be required to reach a definitive diagnosis. Inevitably, the extent of such diagnostic investigations may be limited by cost and owner compliance.

### DIFFERENTIAL DIAGNOSES

Uveitis can arise secondary to many diseases in cats, and can be classified by pathogenesis (Table 1):

**Exogenous causes (external to the eye)** include **ocular trauma** (road traffic accidents are the most

common cause of blunt ocular trauma in cats; ocular surgery can also be causative), and **corneal-related causes** (such as ulceration or sequestra) since reflex uveitis can accompany corneal or ocular surface insult, caused by trigeminal nerve feedback initiating iridocyclitis as well as miosis and ciliary spasm.

**Endogenous causes (from within the eye, or associated with systemic disease or haematogenous dissemination)** are by far the more common cause of uveitis in cats. Causes include **infectious agents** (numerous organisms are implicated, depending on geographic location), **neoplasia**, **systemic/metabolic disease**, or **immune-mediated disease**.

**TABLE 1: Causes of feline uveitis**

#### EXOGENOUS CAUSES

- Ocular trauma:**
- Penetrating injury
  - Blunt injury (road traffic accidents)
- Corneal-related:** **Reflex uveitis, e.g. corneal trauma or ulceration**

#### ENDOGENOUS CAUSES

##### Infectious causes (vary according to geographic location):

- Viruses**
- FIP
  - FeLV
  - FIV
  - FHV-1
- Bacteria**
- *Mycobacterium* spp.
  - *Bartonella* spp.
  - *Leishmania* spp.
- Protozoa**
- *Toxoplasma gondii*
- Fungi:**
- *Cryptococcus neoformans*
  - *Blastomyces dermatitidis*
  - *Histoplasma capsulatum*
  - *Coccidioides immitis*
  - *Candida* spp
- Parasites**
- *Toxocara cati*
  - *Dirofilaria immitis*
  - Fly larvae (e.g/ *Cuterebra* spp)

- Systemic/Metabolic disease**
- Systemic hypertension
  - Septicaemia

- Immune-mediated** Periarteritis nodosa

- Neoplasia**
- Primary ocular tumours:
- Melanoma
  - Post-traumatic sarcoma
  - Ciliary epithelial tumours
- Secondary neoplasia:
- Lymphoma
  - Metastatic disease (adenocarcinoma)
  - Local invasion of extraocular tumours

- Lens-induced**
- Phacolytic e.g. resorption of hypermature cataracts
  - Phacoclastic e.g. lens trauma

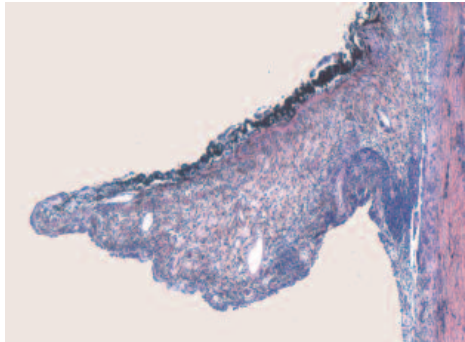
- Toxic/Drug-induced**
- Intraocular miotic agents (e.g. pilocarpine)

- Circulatory**
- Polycythaemia
  - Hypergammaglobulinaemia or hyperviscosity syndrome

- Idiopathic**
- Diagnosis by exclusion of above causes  
Likely immune-mediated

### Idiopathic uveitis

In cats as well as dogs, an underlying cause for uveitis may not always be identified (especially in older cats in which the uveitis had been present chronically). Where a definitive cause cannot be determined by ocular findings, haematological or serological testing, a diagnosis of idiopathic anterior uveitis (IAU) is made. According to one retrospective histopathological study of 158 feline globes, the most common morphological feature of IAU was lymphoplasmacytic inflammation of the uveal tissues (Fig. 4) (suggesting an immune-mediated process).



**Fig. 4:** Increased cellularity in the iris stroma due to chronic lymphoplasmacytic inflammation.

The incidence of IAU compared to infectious uveitis in cats, varies greatly according to different literature reports. In a 1991 review of 53 cases of anterior uveitis, IAU was reported in 70% of cats, whereas, in a seroepidemiological study performed around the same time, 90% of 93 cases of uveitis showed seropositivity to one or more infectious agents (*T. gondii*, FeLV, FIV and feline coronavirus).

### Infectious agents

Although numerous infectious agents are implicated in feline uveitis (see Table 1), the most common include:

- **Feline infectious peritonitis (FIP)(Feline coronavirus - FeCoV)**

FIP is one of the most common causes of uveitis in cats. Typically it is more common in younger cats or those in multi-cat households, and the outcome of infection depends on the host's immune response. Although uveitis can arise in association with the wet (effusive), and dry (granulomatous) forms of this disease, it is more commonly associated with the dry form (a consequence of a partial cell-mediated host immune response). Some cases of dry FIP may present as uveitis in the absence of overt evidence of concurrent systemic disease. More often, though, cats with dry FIP present with neurological signs.

Ocular lesions are usually bilateral but not necessarily symmetrical. The predominant ocular finding is bilateral granulomatous anterior uveitis, with frequent so called 'mutton fat' KPs (also common in FeLV positive patients). These specific KPs are composed of large, yellowish corneal endothelial inflammatory cell deposits. Posterior

lesions often manifest as perivascular cuffs and chorioretinitis. Retinal detachment due to choroidal exudation, and optic neuritis may develop.

In FIP deposition of immune complexes in blood vessel walls causes a vasculitis. Leaky blood vessels allow exit of inflammatory cells and fibrin into the chambers of the eye, with resultant hypopyon and keratic precipitates. These ocular features are not pathognomonic for FIP, however. To make a definitive diagnosis would require biopsy of affected tissues obtained at postmortem examination or from a surgical biopsy - necrotising vasculitis with pyogranulomatous inflammation seen microscopically in the eye is highly suggestive and supports a diagnosis based on the presence of suggestive clinical signs.

Even in systemically ill cats, this condition remains notoriously difficult to diagnose since an elevated FeCoV titre may indicate infection with avirulent strains. Systemic signs vary and are often non-specific, including pyrexia, lethargy, anorexia and weight loss. Clinically, a combination of certain parameters may be highly suggestive of FIP (extremely high feline coronavirus high antibody titre, elevated globulin levels [in plasma or effusions], elevated levels of serum alpha-1 acid glycoprotein, cytological features of pleural or abdominal effusions [predominantly macrophages and neutrophils] and haematological changes [non-regenerative anaemia, lymphopaenia and often neutrophilia with a left shift]).

- **Feline leukaemia virus (FeLV):**

Although uveitis is the most frequent ocular lesion associated with FeLV infection, this virus is not a major cause of feline ocular disease (less than 2% of clinically affected FeLV positive cats have eye lesions). FeLV infection more frequently affects younger cats. Ocular involvement alone is uncommon, although ocular lesions may present alone as an early manifestation of multicentric lymphoma. Ocular lesions associated with FeLV relate to the ability of the virus to cause immunosuppression, haematological changes (retinal haemorrhage and degeneration arise as a consequence of severe anaemia) and in particular uveal tract lymphoma. Approximately 70% of cats with lymphoma are FeLV positive, and it is believed that all cases of uveitis in FeLV positive cats are related to intraocular lymphoma. FeLV associated lymphoma typically arises in the anterior uveal tract. Signs vary from iris thickening, to severely infiltrative and disruptive iridal masses and severe hypopyon. Iris dyscoria (abnormally shaped pupil) occurs secondary to neoplastic infiltration or as a consequence of FeLV-related neurological effects on the autonomic nervous system (Feline Spastic Pupil Syndrome). Uveitis may result as a direct consequence of the tumour invading the uveal tract, as well as secondary to immune-complex deposition. Posterior segment lesions occur less commonly. In-house diagnostic

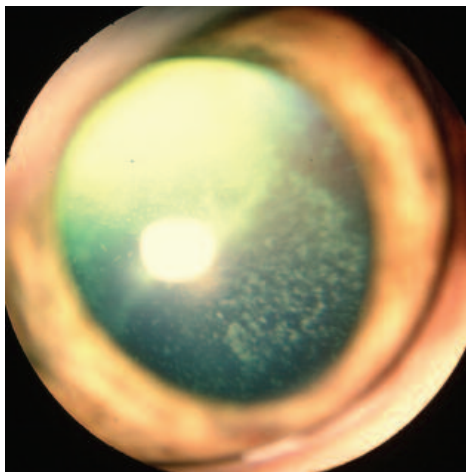


serological kits are widely used for diagnosis of FeLV infection, although a negative test should always be backed up with a laboratory test where the clinical signs are suspicious of FeLV infection.

- **Feline immunodeficiency virus (FIV):**

Many cases of feline uveitis are associated with FIV infection. This lentivirus most commonly infects free-roaming adult cats, and since it is frequently transferred through bite wounds, intact outdoor male cats are overrepresented. It can affect all regions of the eye, and although ocular lesions mostly include aqueous flare, iridal hyperaemia, posterior synechiae and cataracts, uveitis may develop as a consequence of direct viral action or secondary to viral-induced neoplastic transformation (FIV infection has also been reported to be associated with lymphoma). Pars planitis, appearing as white punctate cellular infiltrates in the anterior vitreous ('snow banking') (Fig. 5) has been identified in FIV positive cats. Microscopically there may be a lymphoplasmacytic perivascular uveal inflammatory cell infiltrate.

Recurrent or chronic uveitis occurs more commonly with FIV infection, and although uveitis may only be mild, it may be exacerbated by co-infection (as a consequence of FIV-induced immunosuppression) with *T. gondii*. Ocular signs rarely occur alone in association with FIV infection, and other manifestations, especially haematological (anaemia, lymphopenia) are frequently also present. In-house diagnostic serological kits are widely used for diagnosis of FIV infection, but may give false negative results.



**Fig. 5:** Pars planitis: several scattered cellular deposits are visible, attached to the posterior lens capsule.

- **Toxoplasma gondii:**

Felids represent the only definitive hosts for *Toxoplasma gondii*, an intracellular protozoan parasite with worldwide distribution. Although prevalence of *T. gondii* in the general cat population is suspected to be relatively high, significant clinical disease due to this organism is rare. When it does arise it is often associated with reactivation of latent infection due to

immunosuppression (reported as a consequence of FIV infection, as well as associated with immunosuppressive therapy following renal transplantation). Ocular manifestations are more common in chronic toxoplasmosis than with acute disease. The condition may be unilateral or bilateral, and although all regions of the uveal tract can be affected, anterior uveitis is the most common clinical sign, unlike in people, where a pathognomonic retinochoroiditis is the most frequent ocular lesion.

Ocular infection occurs as a result of haematogenous dissemination of sporozoites released from ingested cysts or sporulated oocysts. Lesions include chorioretinitis (seen as focal dark spots in the tapetal fundus, and white or grey spots in the nontapetal fundus). Microscopically, organisms may be seen in the retina associated with areas of necrosis and granulomatous inflammation (inflammatory cells include a mixture of macrophages, neutrophils, plasma cells and lymphocytes). The pathogenesis of uveitis involves direct cytotoxic effect of the microorganism and subsequent granulomatous inflammation of the uveal tract, as well as immune-mediated reactions to the parasite. It is unclear, however, why some cats exposed to infection develop ocular disease and some do not.

Although IgA, IgG and IgM titres to the organism have been demonstrated in many cats with *Toxoplasma*-induced uveitis, detection of serum antibodies cannot be used alone to document ocular toxoplasmosis. Paired serum samples taken 2–4 weeks apart for toxoplasmosis or evaluation of the Witmer-Goldmann coefficient (the 'C value') to compare serum and aqueous humor antibody concentrations for *T. gondii* (or for feline herpesvirus and *Bartonella* spp.) have been used. Although these tests better correlate the presence of uveitis to a specific agent, interpretations of the results are often inconclusive. Detection of *T. gondii* DNA by PCR test in aqueous humour of infected cats has, however, proven useful.

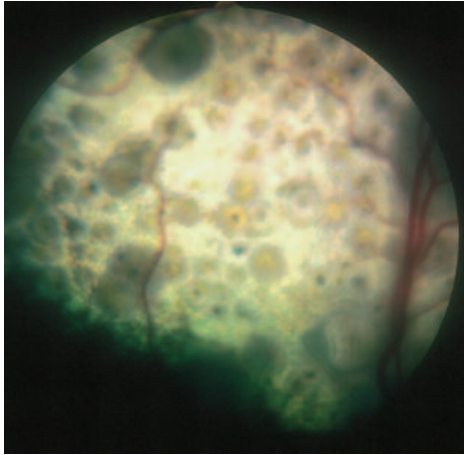
- **Fungal disease**

Systemic fungal infections cause uveitis but are rare, and their importance depends on geographical location. With increasing pet travel, practitioners should be aware of these organisms as potential causes of feline uveitis.

The most common cause of ocular fungal infection in the cat is *Cryptococcus neoformans* (Fig 6). The choroid is the main structure affected, but anterior uveitis may arise secondary to the posterior segment inflammation. Clinical signs of the anterior segment range from mild to severe, and include KPs and fibrin accumulation in the anterior chamber. Posterior signs are usually characteristic, although not pathognomonic, with multiple, irregular dark grey lesions on the dorsal tapetum and white spots on the ventral retina, varying greatly in size, and sometimes causing retinal detachment. The second most common

ocular sign in feline cryptococcosis is optic neuritis. Microscopically, organisms may be seen (mostly in the choroid, subretinal spaces and vitreous cavity, and rarely in the anterior chamber) with or without associated inflammatory cell infiltrates (macrophages, lymphocytes, plasma cells and neutrophils).

Other even more rarely reported causes include *Histoplasma capsulatum*, *Blastomyces dermatitidis* (Figs. 7 and 8), *Coccidioides immitis* and *Candida albicans*. Choroiditis is the most frequent ocular manifestation of these conditions.



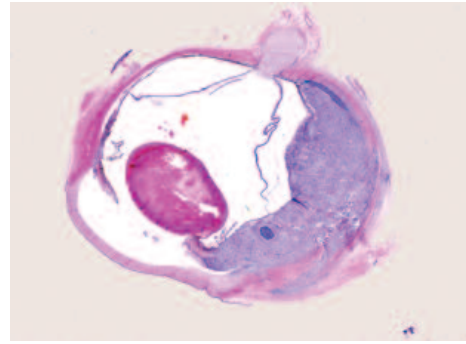
**Fig. 6:** Multifocal hyporeflective lesions on the dorsal tapetum of a cat with active chorioretinitis due to *Cryptococcus neoformans*.

All of these fungal organisms enter the body via the respiratory tract ultimately reaching the eye after crossing the blood-ocular barrier. Ocular manifestations are usually bilateral but not necessarily symmetrical. Typically, however, ocular lesions do not occur in isolation, but are associated with systemic signs. The prognosis varies according to the degree of dissemination and major organ involvement. Long-term systemic anti-fungal treatment (up to 4-6 months) is usually warranted.

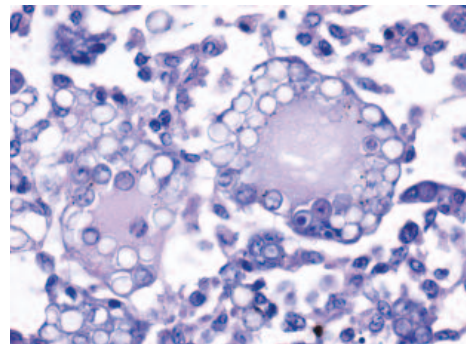
#### • Other

Bacterial uveitides in cats are rare, but have been reported in association with mycobacterial infections. *Leishmania* and *Bartonella* spp. have also been implicated. In humans *Bartonella* spp. is responsible for a wide range of clinical signs, including an almost pathognomonic neuroretinitis. This bacterium has been linked to intraocular inflammation in dogs, and even more recently has been reported in association with feline anterior uveitis through identification of antibodies to the organism in the aqueous humor of affected cats. It is likely that a high percentage of the so-called IAU cases may be related to this organism. Unfortunately, since a high percentage of healthy cats are positive to *Bartonella* (as evidenced by serum antibodies, PCR and blood culture), laboratory investigation is often inconclusive. Bartonellosis should be included as a differential diagnosis for IAU, especially in chronic

cases or those not responding to traditional anti-inflammatory treatment. Appropriate antibiotic treatment for this disease could be recommended in such cases.



**Fig. 7:** Marked effacement of the uveal tract due to inflammation and yeast organisms in a cat infected with *Blastomyces dermatitidis*.



**Fig. 8:** High magnification view of *Blastomyces* yeast organisms within multinucleate giant cells.

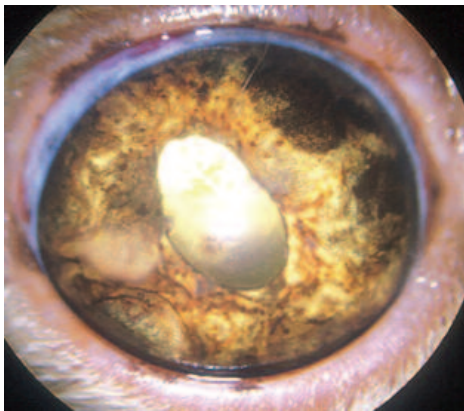
Other reported infectious causes include feline herpesvirus-1 (FHV-1) (more commonly causes keratitis, but also shown to be a cause of uveitis), as well as some rare parasitic causes (*Toxocara cati*, *Dirofilaria immitis* and fly larvae).

#### Neoplasia

Intraocular neoplasia is an important cause of uveitis in cats and can be primary ocular, or secondary metastatic. Breakdown of the blood-ocular barrier (due to necrosis of neoplastic tissue and neovascularisation) is responsible for the signs of uveitis. The most common primary intraocular neoplasms of cats are anterior uveal melanoma and intraocular sarcoma, with ciliary epithelial tumours arising less frequently. Intraocular sarcomas, ciliary body adenocarcinomas, and melanomas have malignant characteristics and may grow rapidly, extending out of the globe by invasion of the filtration angle, aqueous collecting veins, optic nerve, or sclera.

Diffuse iris melanoma is the most common primary neoplasm arising in the feline uveal tract and typically arises on the anterior aspect of the iris and usually does not extend into the posterior uvea. Iris melanoma is often malignant in cats (compared to mostly benign in dogs), and enucleation is usually recommended. Several intraocular signs (anterior

uveitis, dyscoria, pigment dispersion and glaucoma) (Fig. 9) may be indicative of melanoma compared to benign melanosis (a common, benign aging phenomenon, caused by increased iridal pigmentation). Invasion of the ciliary body stroma by neoplastic cells is usually considered a poor prognostic indicator. In such cases, affected cats experience a reduced survival time and may die of metastatic disease.



**Fig. 9:** Diffuse uveal anterior melanoma: the iris is abnormally shaped due to neoplastic pigmented cellular infiltrates. Dyscoria and posterior synechiae are also present.

The second most common neoplasm in the feline eye is intraocular sarcoma, a type of malignant intraocular neoplasm. It is frequently associated with a history of ocular trauma and considered to arise from malignant transformation of lens epithelial cells and therefore associated with previous lens trauma, sometimes as long as 10 years before the appearance of a growth. Most of these tumours tend to present as fibrosarcomas but other mesenchymal neoplasms may arise, including osteosarcoma and leiomyosarcoma. These tumours typically occupy the posterior iris and are locally invasive, expanding diffusely into the posterior chamber, retina, and choroid. Extraorbital invasion is common and the lens is usually destroyed. They have the potential to metastasise, and prognosis is usually poor even following enucleation of the affected eye.

Secondary neoplasia in the eye can arise as a result of metastasis from other sites, for example in cases of lymphoma (the most common ocular metastatic tumour in cats) or metastatic adenocarcinoma. Alternatively secondary neoplasia may arise as a consequence of invasion of contiguous extraocular tumours (e.g. squamous cell carcinoma). A rare and aggressive form of angioinvasive pulmonary carcinoma has also been recently described in cats. The clinicopathological features of this disease involved dramatic metastatic invasion of the choroid by neoplastic cells, with subsequent ischaemic necrosis and retinal degeneration.

Clinical manifestations of intraocular neoplasia may vary but usually include visible masses, hypotony, hyphaema, secondary glaucoma, leukocoria, iridal

colour and shape changes, and retinal detachment. Histopathology of the enucleated eye, however, is usually necessary to reach a definitive diagnosis.

### Systemic/metabolic disease

Uveitis is often described as a feature of systemic hypertension (such as in cases of feline hyperthyroidism, chronic renal failure or in primary hypertension). However, although findings such as aqueous flare, hyphaema, retinal and vitreal haemorrhages and retinal detachments are common in hypertensive cats, they are not a direct result of anterior uveal inflammation or immune-mediated damage, and therefore do not represent a true uveitis. Instead, these changes result from mechanical and secondary degenerative damage to the integrity of the ocular vessels due to sustained, elevated blood pressure. Nevertheless, topical anti-inflammatory treatment is usually still warranted in cases of anterior iridal involvement in hypertensive cats.

### TREATMENT

The reader is referred to the first article on canine uveitis (UK Vet Vol 12 No 2) for discussion on the general treatment of uveitis. In summary, topical corticosteroidal and mydriatic/cycloplegic treatment is indicated in every case of intraocular inflammation, provided that the corneal epithelium is intact and free of infectious disease. Cats may be extremely sensitive to the effects of topical atropine (with hypersalivation, drooling and head shaking commonly seen) in part due to the extreme bitterness of the drug, as it easily reaches the mouth through the nasolacrimal pathway. Topical tropicamide or atropine ointment can be successful alternative treatments in cats, and these are generally well tolerated. As already reported, glaucoma may occur secondary to chronic uveitis, in which case any mydriatic and cycloplegic agents are contraindicated, since they contribute to increase in intraocular pressure.

The preferred method of treating inflammation of the posterior segment, is through systemic corticosteroids since therapeutic drug concentrations cannot be reached in the choroid and retina with topical alternatives. The association between systemic infectious diseases and chorioretinitis should be considered when administering such drugs due to their possible immunosuppressive action which may lead to worsening of the disease course.

Treatment of the underlying cause, where it can be identified, and appropriate systemic antimicrobial therapy are warranted in every case of concurrent systemic disease. Treatment of the specific infectious and neoplastic diseases is beyond the scope and aim of this article, and the reader is therefore referred to the relevant textbooks and journal articles.

### SUMMARY

In cats, uveitis with or without chorioretinitis is one

of the most frequent and significant ophthalmic diseases. It can frequently arise secondary to systemic pathologies and may be infectious in origin, where it may even present as an early and only indicator of the disease.

Consequently in systemically ill cats, the underlying disease is the most likely origin of the condition, and an infectious aetiology should be ruled out. Since ocular findings in all cases of infectious uveitis are similar, other pertinent clinical and historical information must be considered to achieve a definitive diagnosis. The diagnostic workup may include complete blood count, biochemistry profile, and serological testing for infectious diseases that may be prevalent in the region. Idiopathic anterior uveitis is still diagnosed in a large percentage of cases, but this diagnosis can only be made as a result of careful elimination of all other possible causes.

A thorough diagnostic work-up is therefore necessary in such cases, and prompt diagnosis of possible underlying infectious processes is important for accurate diagnosis, prognosis and appropriate therapeutic decision-making.

#### FURTHER READING

- COLITZ C. M. (2005) Feline uveitis: diagnosis and treatment. *Clin Tech Small Anim Pract May*; 20(2):117-120.
- DAVIDSON M. G., ENGLISH R. V. (1998) Feline ocular toxoplasmosis. *Vet Ophthalmol.* 1(2-3):71-80.
- DAVIDSON M. G., NASISSE M. P., ENGLISH R. V., WILCOCK B. P., JAMIESON V. E. (1991) Feline anterior uveitis: a study of 53 cases. *J Am Anim Hosp Assoc* 27(1):77-83.
- GLAZE M. B., GELATT K. N. (1999) Feline Ophthalmology. In: *Veterinary Ophthalmology* 3rd ed (ed. Gelatt K.N.). Lippincott Williams & Wilkins, Philadelphia, pp997-1052.
- GOULD D. (2001) The Eye. In: *BSAVA Manual of Canine and Feline Infectious Diseases* 1st ed (ed. Ramsey I., Tennant B.). Blackwell Publishing, Oxford, pp251-264.

**CPD**

**CONTINUING PROFESSIONAL  
DEVELOPMENT SPONSORED BY  
CEVA ANIMAL HEALTH**

*These multiple choice questions are based on the above text. Answers appear on page 99.*

- 1. The most common primary neoplasm arising in the feline uveal tract is:**
  - a. Trauma-induced sarcoma
  - b. Iridociliary adenoma
  - c. Medulloepithelioma
  - d. Lymphoma
  - e. Melanoma
  
- 2. Which sequel(s) is (are) common in cases of feline uveitis:**
  - a. Iris bombe
  - b. Glaucoma
  - c. Cataract
  - d. Posterior synechia
  - e. All of the above
  
- 3. The most common clinical sign of ocular toxoplasmosis is:**
  - a. Posterior uveitis
  - b. Anterior uveitis
  - c. Glaucoma
  - d. Retinal detachment
  - e. Cataract
  
- 4. The most common secondary intraocular neoplasm in cats is:**
  - a. Iridociliary adenocarcinoma
  - b. Choroidal melanoma
  - c. Squamous cell carcinoma
  - d. Lymphoma
  - e. Intraocular sarcoma

